



A retrospective cohort study on the significance of preoperative radiological evaluation of lumbar degenerative diseases for surgical reference

Xiaowen Liu[#], Yang Hou[#], Hongyang Shi, Tianyi Zhao, Chenxi Sun, Jiangang Shi, Guodong Shi

Department of Orthopaedic Surgery, Changzheng Hospital, Second Military Medical University, Shanghai, China

Contributions: (I) Conception and design: Y Hou, X Liu, G Shi; (II) Administrative support: G Shi, J Shi; (III) Provision of study materials or patients: T Zhao, C Sun; (IV) Collection and assembly of data: X Liu, H Shi; (V) Data analysis and interpretation: X Liu, J Shi; (VI) Manuscript writing: All authors; (VII) Final approval of manuscript: All authors.

[#]These authors contributed equally to this work and should be considered as co-first authors.

Correspondence to: Dr. Guodong Shi, PhD. Department of Orthopaedic Surgery, Changzheng Hospital, Second Military Medical University, No. 415 Fengyang Rd., Shanghai 200003, China. Email: shigd8888@163.com.

Background: Radiography has low radiation exposure and the ability to acquire information. Due to its cost-effectiveness and availability, preoperative radiographic imaging examination is considered to be a valuable method to evaluate the condition of patients with spinal disease. The aim of this cohort study is to analyze the impact of evaluating preoperative X-rays on the surgical management of lumbar degenerative diseases (LDD).

Methods: We reviewed 49 patients with LDD underwent single-level posterior instrumented lumbar fusion (PILF) between November 2017 and October 2022 in this cohort study. The median iliac angle (MIA), iliac crest height, intervertebral facet joint degeneration, lumbosacral angle (LSA), L5/S1 intervertebral space angle (ISA), intervertebral foramen height (IFH) and intervertebral space height (ISH) were measured on preoperative radiographs. In addition, operative time, intraoperative blood loss and postoperative complications were used to evaluate the surgical management. Correlation analysis was used to determine the correlation between preoperative radiographic presentation and surgical managements. Multivariate linear regression analysis was used for determination of risk factors for surgical management.

Results: Correlation analysis showed that the median iliac angle, height of iliac crest, lumbosacral angle and intervertebral facet joint degeneration were significantly correlated with surgical managements ($P < 0.05$). Height of iliac crest, intervertebral facet joint degeneration and lumbosacral angle were positively correlated with surgical management. Meanwhile, MIA was negatively correlated with surgical management. No significant difference was found between the IFH, ISA, ISH and surgical managements in posterior lumbar surgery ($P > 0.05$). After multiple linear regression analysis, height of iliac crest, median iliac angle and intervertebral facet joint degeneration were independent influence factors for the single-level lumbar surgical managements.

Conclusions: Some variables measured in radiograph shows that height of iliac crest, median iliac angle and intervertebral facet joint degeneration have a potential influence on surgical managements. The lumbosacral angle was positively associated with surgical management, but it was not statistically significant in multiple linear regression analysis ($P > 0.05$). The above measurements in plain film can reflect the surgical procedure and have some guiding implications for the operation.

Keywords: Radiography; surgical management; median iliac angle; intervertebral facet joint degeneration; height of iliac crest

Submitted Dec 20, 2022. Accepted for publication Apr 25, 2023. Published online Jun 09, 2023.

doi: 10.21037/qims-22-1414

View this article at: <https://dx.doi.org/10.21037/qims-22-1414>

Introduction

Lumbar degenerative disease (LDD) is one of the most common types of spine diseases, which include spinal stenosis, lumbar spondylolisthesis, lumbar disc herniation, and degenerative scoliosis, etc. (1-3). Posterior instrumented lumbar fusion is a standard and widely accepted surgery for treating LDD when conservative measures have failed for ≥ 6 months (4,5). Numerous scholars have proposed risk factors that may influence the surgical procedures and postoperative outcomes of the spine, such as body mass index (BMI), subcutaneous fat thickness, iliac crest height, number of levels fused, and so on, but a consensus has not been formed (6,7).

Advances in medical imaging allow us to visualize spinal disease severity preoperatively (8). Imaging can effectively reflect the severity of spinal disease and guide clinical management. Using the correct imaging modality, such as radiograph, computed tomography (CT) and magnetic resonance imaging (MRI) during the diagnostic workup can play a crucial role in the evaluation of the spinal surgical managements and may subsequently aid in preoperative planning (9). Previous MRI and CT are valuable in the diagnosis and treatment of spinal disease (10-12). However, the major disadvantages of MRI and CT are being more expensive and time-consuming than X-ray (13,14). This limits the value of both in evaluating surgical procedures. As a routine imaging examination for evaluating various spinal conditions, plain radiography can effectively reflect the surgical management of lumbar surgery (15). To our knowledge, no previous published studies have determined the relationship between preoperative radiographic imaging and surgical management. Due to the convenience of radiological examination, this study aims to explore the correlation between variables measured on preoperative X-ray and surgical management of patients with LDD. We present this article in accordance with the STROBE reporting checklist (available at <https://qims.amegroups.com/article/view/10.21037/qims-22-1414/rc>).

Methods

This cohort study was conducted in accordance with the

Declaration of Helsinki (as revised in 2013). The study protocol was approved by the Medical Institutional Review Board of Shanghai Changzheng Hospital, and every patient had signed the informed consent form before participating in this study.

Our study reviewed 49 patients with LDD who underwent posterior instrumented lumbar fusion (PILF) in Shanghai Changzheng Hospital between November 2017 and October 2022. PILF surgery was defined as posterolateral fusion with the use of pedicle screw constructs, including PLIF and transforaminal lumbar interbody fusion (TLIF) (6). This study included 30 patients with lumbar disc herniation, 13 patients with spinal stenosis, and 6 patients with lumbar spondylolisthesis. Of the 49 patients included in this study, 27 patients underwent TLIF, and the other 22 patients underwent PLIF surgery. The mean age of the patients was 43.1 years (ranging from 16 to 74 years) and women account for 47% of all patients. There were no excluded cases in this study. Patient characteristics are summarized in *Table 1*. They met the following inclusion criteria: (I) L5/S1 single-level posterior lumbar surgery. (II) All procedures were done by the same senior clinician (GDS). (III) Plain radiographs in all patients were obtained preoperatively. Exclusion criteria included: (I) comorbid serious underlying diseases (such as diabetes mellitus, history of stroke, taking some medicines that can easily lead to bleeding like aspirin or warfarin); (II) BMI >35 kg/m²; (III) revision surgery of lumbar spine; (IV) spinal trauma; (V) spinal tumor; (VI) pediatric spinal surgery; (VII) spondylolysis. Two evaluators independently screened the patients' information by adopting the unified inclusion and exclusion criteria. In case of any disagreement, it was resolved through discussion or with the assistance of a third researcher.

The follow-up examinations were performed on the 10th day, and then at 1-month follow-ups. The subsequent follow-up examinations were performed at 3-month intervals. At each follow-up visit, patients were required to receive a telephone interview and complete an assessment questionnaire.

All patients provided standing posterior-anterior and lateral X-ray films before surgery. Radiographic variables analyzed included median iliac angle (MIA), iliac crest

Table 1 Patient characteristics

Characteristics	Value
Total	49
Age (years)	43.1±13.9
Sex	26 males, 23 females
Operation time (min)	84.84±26.31
Blood loss (mL)	230.8±61.06
Preoperative VAS	7.31±1.228
Postoperative VAS at 10th day of follow-up	1.69±0.652 ^a
Preoperative ODI	69.14±10.618
Postoperative ODI at 10th day of follow-up	37.88±10.066 ^b
Complications	
Cerebrospinal fluid leakage	2
Postoperative symptoms worsen	5
Neurological deterioration	1
Cage migration	1

The value is presented as means ± SD. ^a, compared to preoperative VAS, P<0.05; ^b, compared to preoperative ODI, P<0.05. VAS, visual analog scale; ODI, Oswestry Disability Index.

height, intervertebral facet joint degeneration, lumbosacral angle (LSA), LS/S1 intervertebral space angle (ISA), intervertebral foramen height (IFH) and intervertebral space height (ISH). (I) Median iliac angle: the angle between the line connecting the highest point of the iliac crest and the posterior superior iliac spine and the central sacral vertical line (CSVL). CSVL was defined as a straight line passing through the midpoint of the upper edge of S1 and perpendicular to the horizontal ground (16-18). The median iliac angle was averaged between the left and right sides (*Figure 1A*). (II) Height of iliac crest: on anteroposterior radiograph of the lumbar spine, the height of the iliac crest was the distance between the intercrestal line and the top middle point of the sacral vertebral body (*Figure 1B*) (7). (III) Lumbosacral angle: lumbosacral angle is defined as the angle along the superior endplate of S1 relative to the horizontal plane (19). (IV) L5/S1 intervertebral space angle: the angle between the upper and lower endplate of the intervertebral space (20). (V) Intervertebral space height: the mean of anterior and posterior ISH (20,21). (VI) Intervertebral foramen height: the distance between the lower margin of the superior pedicle and vertebral body connection and the upper margin of the inferior pedicle and vertebral body

connection (20). ISA, ISH and IFH are shown in *Figure 1C*. (VII) Degenerative grading of intervertebral facet joint: intervertebral facet joint degeneration was divided into three types based on radiographic imaging, type I: the intervertebral facet joint showed no degeneration and the joint space was normal; type II: the intervertebral joint shows moderate hyperplasia and the joint space becomes blurred but still visible; type III: the intervertebral joint shows severe hyperplasia and sclerosis, and the joint space is indistinguishable (*Figure 2*). Type II and type III are defined as intervertebral facet joint degeneration. In order to reduce interobserver and intraobserver errors, two independent orthopedic surgeons evaluated the data obtained from radiographs.

The reasons for difficulties in spinal surgery are wide in range and include pathological/anatomical conditions of the spine (8). The Oswestry Disability Index (ODI) scores and visual analog scale (VAS) scores were observed preoperatively and postoperatively. The surgical management was evaluated on basis of the operation duration, intraoperative blood loss volume and postoperative complications. Complications, including cerebrospinal fluid leakage, postoperative symptoms worsen, neurological deterioration and cage migration, were recorded. If the variable measured on radiographs was associated with operative time and blood loss volume simultaneously (P<0.05), then we considered this variable can influence spinal surgical management.

The correlations between the above measured variables from radiographic imaging and the surgical management were analyzed using spearman rank correlation test. P value <0.05 was considered statistically significant. Validity and reliability of degenerative grading of intervertebral facet joint were assessed using kappa (κ) analysis. Meanwhile, the inter-rater reliability was assessed using the intraclass correlation coefficient (ICC) for other radiographic measurements including MIA, height of iliac crest, LSA, ISA, ISH, IFH. For the analysis of statistical differences between the three types of LDD, we used a completely random analysis of variance (ANOVA). Multivariate linear regression was performed for data analysis to identify influencing factors of surgical management. Statistical analysis was conducted using R version 4.0 (R Foundation for Statistical Computing, Vienna, Austria) and IBM SPSS Statistics version 26.0 (IBM Corp., Armonk, NY).

Results

There was a significant improvement in the patients'

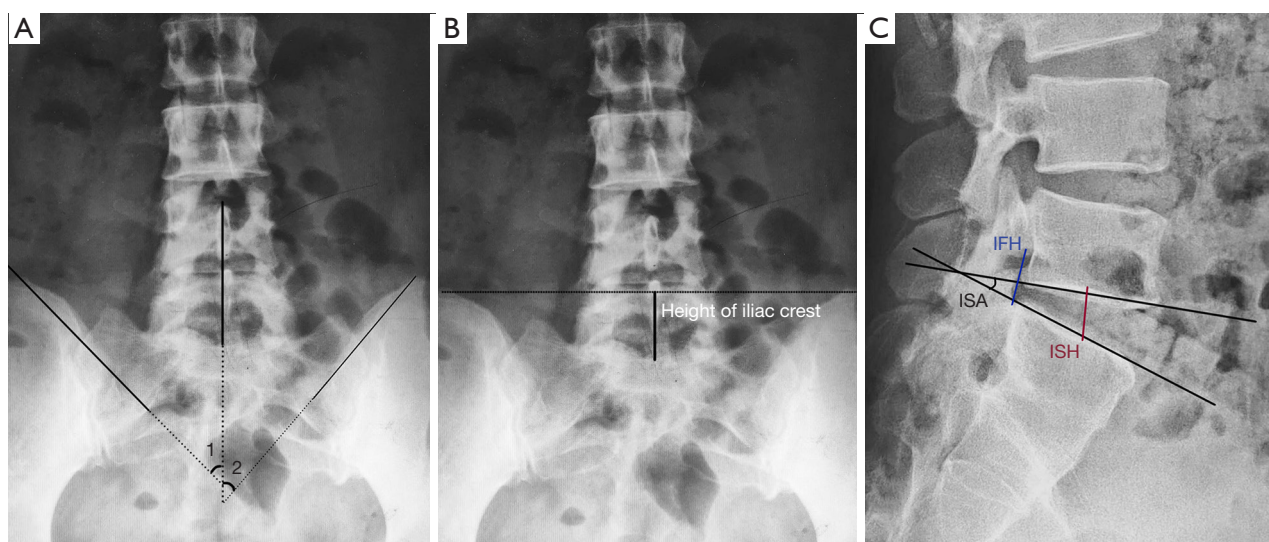


Figure 1 Measurement of the different radiographic variables. (A) Median iliac angle. (B) Height of iliac crest. (C) L5/S1 ISA, IFH and ISH. ISA, intervertebral space angle; IFH, intervertebral foramen height; ISH, intervertebral space height.

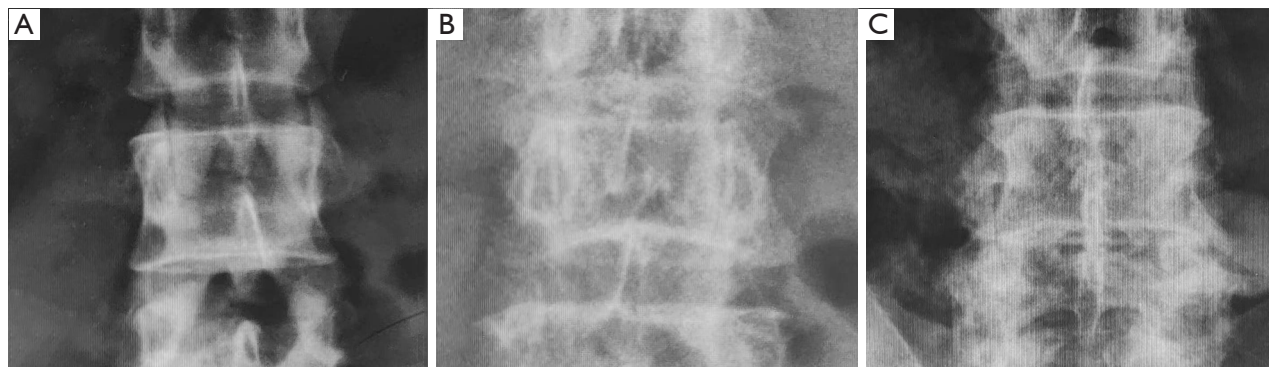


Figure 2 Sample figure of intervertebral facet joint degeneration grading. (A) Type I; (B) type II; (C) type III.

pain levels and functional activity levels over 10 days. As demonstrated in *Table 1*, the VAS and ODI scores significantly improved from 7.3 ± 1.2 preoperatively to 1.7 ± 0.7 postoperatively, and from 69.1 ± 10.6 preoperatively to 37.9 ± 10.1 postoperatively ($P < 0.05$). The average operation time for group was 85 ± 26 minutes and mean blood loss during operation was 231 ± 61 mL. In addition, there were 2 patients presenting with cerebrospinal fluid leakage, 5 patients with postoperative symptoms worsen, 1 patient with neurological deterioration, and 1 patient with cage migration.

After a completely random ANOVA, we found that there were no statistical differences between the type of LDD and clinical outcome in terms of operation time and estimated

blood loss volume ($P > 0.05$).

The results of the correlation analysis between parameters measured on radiographs and operative time are shown in *Table 2*. In this study, the median iliac angle (MIA), as a previously undescribed concept, had a negatively strong correlation with operative time. Other statistically significant variables, such as height of iliac crest, lumbosacral angle and intervertebral facet joint degeneration were positively associated with the surgical duration. However, we did not find statistical difference of measurement including ISA, ISH and IFH.

Correlation analysis between variables and estimated blood loss are shown in *Table 3*. We found that MIA, height of iliac crest, lumbosacral angle and intervertebral facet

Table 2 Correlation coefficients and statistical difference of parameters measured on radiographs (operation time)

Parameters	Correlation coefficient (r)	P value
Median iliac angle (MIA)	-0.6302	<0.001*
Iliac crest height	0.452	0.001*
Lumbosacral angle (LSA)	0.3335	0.02*
Intervertebral facet joint degeneration	0.3113	0.03*
LS/S1 intervertebral space angle (ISA)	0.165	0.26
Intervertebral foramen height (IFH)	0.0854	0.56
Intervertebral space height (ISH)	-0.0347	0.81

*, this variable was statistically significant ($P < 0.05$).

Table 3 Correlation coefficients and statistical difference of parameters measured on radiographs (estimated blood loss)

Parameters	Correlation coefficient (r)	P value
Median iliac angle (MIA)	-0.5817	<0.001*
Iliac crest height	0.4445	0.001*
Lumbosacral angle (LSA)	0.2923	0.04*
Intervertebral facet joint degeneration	0.3573	0.01*
LS/S1 intervertebral space angle (ISA)	0.191	0.19
Intervertebral foramen height (IFH)	0.1071	0.46
Intervertebral space height (ISH)	-0.0267	0.86

*, this variable was statistically significant ($P < 0.05$).

joint degeneration were correlated with blood loss volume. ISA, ISH and IFH still showed no statistical significance in intraoperative bleeding.

For the degenerative grading of intervertebral facet joint, kappa was used to analyze validity and reliability. The results revealed high validity ($\kappa=0.85$) and reliability ($\kappa=0.88$). In addition, inter-rater reliability is high for MIA (ICC 0.88), height of iliac crest (ICC 0.92), LSA (ICC 0.95), ISA (ICC 0.94), ISH (ICC 0.95), IFH (ICC 0.96).

Multivariate linear regression analysis showed that some variables, such as MIA, height of iliac crest and intervertebral facet joint degeneration, were statistically significantly associated with operative time and blood loss volume simultaneously (Tables 4,5). Therefore, we considered these variables can influence spinal surgical management.

Discussion

Lumbar degenerative disease is one of the most common

disorders affecting the lumbar spine (22). An increasing number of people who suffer from LDD undergo posterior instrumented lumbar fusion surgery worldwide (23). However, how to evaluate the surgical management of PILF remains controversial. With the development of imaging technology, it plays an increasingly important role in the diagnosis and treatment of lumbar degenerative diseases (24). Compared with CT or MRI, X-ray photographs are cost-effective and easily accessible. It has low radiation exposure and the ability to acquire information, making them an indispensable tool for spine evaluation (25,26). In addition, radiographs can show the alignment of the spine and provide an overview of the anatomy of the bone (27). We further identify several variables that may help to stratify patients according to preoperative radiographic imaging and therefore improve surgical management and long-term prognosis.

Anatomy of the lumbar spine: the erector spinae are gradually divided, from inside to outside, into three columns of longitudinal muscles that are juxtaposed (28). However,

Table 4 The multiple linear regression analysis between the measured variables from radiographic imaging and the operative time

Independent variable	Regression coefficient	95% confidence interval	P value
Median iliac angle (MIA)	-1.3345	-1.829 to -0.8399	<0.001*
Iliac crest height	0.8432	0.3339 to 1.3525	0.001*
Intervertebral facet joint degeneration	14.3092	3.0352 to 25.5832	0.003*
Lumbosacral angle (LSA)	-0.1392	-0.788 to 0.5097	0.91

*, this variable was statistically significant ($P < 0.05$).

Table 5 The multiple linear regression analysis between the measured variables from radiographic imaging and estimated blood loss

Independent variable	Regression coefficient	95% confidence interval	P value
Median iliac angle (MIA)	-2.7151	-3.8911 to -1.5392	<0.001*
Iliac crest height	2.0765	0.8654 to 3.2877	0.01*
Intervertebral facet joint degeneration	44.635	17.8267 to 71.4433	0.001*
Lumbosacral angle (LSA)	-0.4015	-1.9444 to 1.1414	0.95

*, this variable was statistically significant ($P < 0.05$).

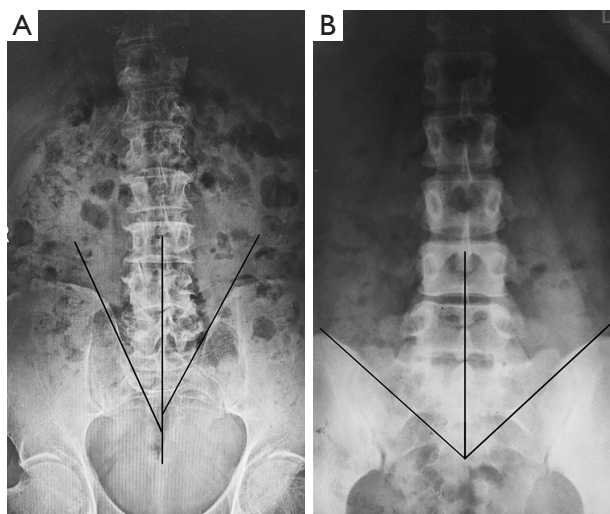


Figure 3 A comparison of the different MIA. (A) The small MIA. (B) The large MIA. MIA, median iliac angle.

in the lumbar spine, the erector spinae contain the iliocostal muscle laterally (musculus iliocostalis lumborum) versus the longissimus medially (musculus longissimus thoracis), of which the latter is much stronger (29,30). Musculus latissimus dorsi, musculus iliocostalis lumborum, musculus longissimus thoracis, musculus multifidus and musculus quadratus lumborum are all distributed within this region of the median iliac angle (31,32). For people with large median

iliac angle, it is easy to pull the muscles to the outside to obtain a good surgical vision, which facilitates the operation and reduces the difficulty of the operation (Figure 3). We propose the concept of median iliac angle for the first time. This variable, the median iliac angle observed on preoperative X-ray, is one such factor that influences the surgical procedure.

In the present study, we found that the iliac crest height also had a correlation with surgical management. Due to the obstruction of bony structures at the posterior border of the iliac crest (33), people with a high iliac crest often led to the difficulties of intraoperative muscles traction and limited surgical field of view, which in turn increases surgical difficulty. We need to point out that there is some correlation between the height of the iliac crest and the median iliac angle. Iliac crest height was generally higher in those with a smaller median iliac angle. However, the above two variables had different mechanisms to influence the surgical management. Intraoperative muscle traction was difficult in patients with high iliac crest due to the obstruction of bone at the posterior border of the iliac crest. People with a small MIA mainly affect the range of intraoperative muscle traction.

We firstly proposed a degenerative grading of intervertebral facet joint based on preoperative X-ray, which was different from Weishaupt grading under CT and MRI (34). This classification was convenient for the clinicians to analyze

intervertebral facet joint degeneration. Since one of the most critical steps in lumbar spine surgery is the decompressive procedure, it was often necessary to bite off the intervertebral facet joint while protecting the nerve or dura from being injured. The higher the degeneration grade, the more difficult the intraoperative facet joint bite, the greater the operation time and blood loss, and the corresponding increase in the incidence of nerve root injury and cerebrospinal fluid leakage. Intraoperative pedicle screw placement is also difficult in patients with facet joint degeneration. Therefore, degeneration of the facet joints will undoubtedly make the surgical management become difficult (35). In the present study, Intervertebral facet joint degeneration was the most significant variable affecting the spinal surgical management, which was consistent with our envisioned results.

In correlation analysis, we found a positive correlation between the lumbosacral angle and surgical management. With a large LSA, the lumbar spine tends to be deeper, which can add difficulty to the exposure process and limit surgical space. In multivariate analysis, the lumbosacral angle was not statistically significant, thus more original studies are needed to explore whether the lumbosacral angle can affect the surgical management.

However, this article has many limitations. The study subjects included in this study are patients who underwent L5-S1 single-level posterior instrumented lumbar fusion surgery. However, there is no explanation as to whether preoperative radiographic variables in multi-level lumbar spine surgery are related to surgical management, which limits the universality of this article. In addition, the number of cases included in this study is 49, which is relatively small. Further research should expand the sample size to increase the persuasiveness of the study. We are already preparing a study on the relationship between preoperative radiographic imaging and surgical management for a large sample size and multi-level posterior instrumented lumbar fusion surgery.

Conclusions

In the present study, variables measured on radiographs including height of iliac crest, median iliac angle and intervertebral facet joint degeneration have a potential influence on surgical management. For patients with LDD, careful preoperative evaluation of X-ray could be of great significance for improving the surgical effect.

Acknowledgments

Funding: None.

Footnote

Reporting Checklist: The authors have completed the STROBE reporting checklist. Available at <https://qims.amegroups.com/article/view/10.21037/qims-22-1414/rc>

Conflicts of Interest: All authors have completed the ICMJE uniform disclosure form (available at <https://qims.amegroups.com/article/view/10.21037/qims-22-1414/coif>). The authors have no conflicts of interest to declare.

Ethical Statement: The authors are accountable for all aspects of the work in ensuring that questions related to the accuracy or integrity of any part of the work are appropriately investigated and resolved. This cohort study was conducted in accordance with the Declaration of Helsinki (as revised in 2013). The study protocol was approved by the Medical Institutional Review Board of Shanghai Changzheng Hospital and every patient had signed the informed consent form before participating in this study.

Open Access Statement: This is an Open Access article distributed in accordance with the Creative Commons Attribution-NonCommercial-NoDerivs 4.0 International License (CC BY-NC-ND 4.0), which permits the non-commercial replication and distribution of the article with the strict proviso that no changes or edits are made and the original work is properly cited (including links to both the formal publication through the relevant DOI and the license). See: <https://creativecommons.org/licenses/by-nc-nd/4.0/>.

References

1. Zhou C, Xia H, Yin J, Zheng Y. Three-dimensional gait quantitative analysis in postoperative rehabilitation of lumbar degenerative diseases: a self-controlled before-after study. *Am J Transl Res* 2021;13:6913-20.
2. Harakuni T, Iwai H, Oshima Y, Inoue H, Kitagawa T, Inanami H, Koga H. Full-Endoscopic Lumbar Interbody Fusion for Treating Lumbar Disc Degeneration Involving Disc Height Loss: Technical Report. *Medicina (Kaunas)* 2020;56:478.

3. Pietton R, Vialle R, Laurent R, Skalli W, Vergari C, Langlais T. Changes in quantitative elastography assessment of the adjacent lumbar disc after segmental fixation of the spine: a case description of a burst fracture of L4. *Quant Imaging Med Surg* 2022;12:2184-8.
4. Zhao H, Gao H, Zhou C, Qian S, Yuan Y, Xue W, Qian J. A randomized controlled trial with ≥ 5 years of follow-up comparing minimally invasive and open transforaminal lumbar interbody fusion in disc herniation at single level. *Exp Ther Med* 2019;17:3614-20.
5. Atlas SJ, Keller RB, Robson D, Deyo RA, Singer DE. Surgical and nonsurgical management of lumbar spinal stenosis: four-year outcomes from the maine lumbar spine study. *Spine (Phila Pa 1976)* 2000;25:556-62.
6. Gupta VK, Zhou Y, Manson JF, Watt JP. Radiographic spine adipose index: an independent risk factor for deep surgical site infection after posterior instrumented lumbar fusion. *Spine J* 2021;21:1711-7.
7. Wang YL, Wang XY, Fang BD, Chi YL, Xu HZ, Wu LJ, Lin ZK. L5-S1 disc degeneration and the anatomic parameters of the iliac crest: imaging study. *Eur Spine J* 2015;24:2481-7.
8. Soh E, Karmakar MK. Assessment of the spine with CT and MRI prior to interspinous/interlaminar spinal procedures: a pictorial review. *Br J Radiol* 2013;86:20130066.
9. Harada GK, Siyaji ZK, Younis S, Louie PK, Samartzis D, An HS. Imaging in Spine Surgery: Current Concepts and Future Directions. *Spine Surg Relat Res* 2019;4:99-110.
10. Houghton KM. Review for the generalist: evaluation of pediatric hip pain. *Pediatr Rheumatol Online J* 2009;7:10.
11. Leng S, Zhao K, Qu M, An KN, Berger R, McCollough CH. Dynamic CT technique for assessment of wrist joint instabilities. *Med Phys* 2011;38 Suppl 1:S50.
12. Hwang EJ, Jung JY, Lee SK, Lee SE, Jee WH. Machine Learning for Diagnosis of Hematologic Diseases in Magnetic Resonance Imaging of Lumbar Spines. *Sci Rep* 2019;9:6046.
13. Wu Y, Ma Y, Liu J, Du J, Xing L. Self-Attention Convolutional Neural Network for Improved MR Image Reconstruction. *Inf Sci (N Y)* 2019;490:317-28.
14. Masuda T, Funama Y, Kiguchi M, Imada N, Oku T, Sato T, Awai K. Radiation dose reduction based on CNR index with low-tube voltage scan for pediatric CT scan: experimental study using anthropomorphic phantoms. *Springerplus* 2016;5:2064.
15. Lai ZH, Sá Dos Reis C, Sun Z. Effective dose and image optimisation of lateral lumbar spine radiography: a phantom study. *Eur Radiol Exp* 2020;4:13.
16. Zhang RF, Liu K, Wang X, Liu Q, He JW, Wang XY, Yan ZH. Reliability of a new method for measuring coronal trunk imbalance, the axis-line-angle technique. *Spine J* 2015;15:2459-65.
17. Sangole A, Aubin CE, Labelle H, Lenke L, Jackson R, Newton P, Stokes IA; . The central hip vertical axis: a reference axis for the Scoliosis Research Society three-dimensional classification of idiopathic scoliosis. *Spine (Phila Pa 1976)* 2010;35:E530-4.
18. Zhuang Q, Zhang J, Wang S, Yang Y, Lin G. How to select the lowest instrumented vertebra in Lenke type 5 adolescent idiopathic scoliosis patients? *Spine J* 2021;21:141-9.
19. Nguyen HS, Doan N, Shabani S, Baisden J, Wolfla C, Paskoff G, Shender B, Stemper B. Upright magnetic resonance imaging of the lumbar spine: Back pain and radiculopathy. *J Craniovertebr Junction Spine* 2016;7:31-7.
20. Du X, She Y, Ou Y, Zhu Y, Luo W, Jiang D. Oblique Lateral Interbody Fusion versus Transforaminal Lumbar Interbody Fusion in Degenerative Lumbar Spondylolisthesis: A Single-Center Retrospective Comparative Study. *Biomed Res Int* 2021;2021:6693446.
21. Yang F, Wang Y, Ma Y, Hu X, Li X, Ma Z, He X, Gao Y, Yang Y, Kang X. Single-segment central lumbar spinal stenosis: Correlation with lumbar X-ray measurements. *J Back Musculoskelet Rehabil* 2021;34:581-7.
22. Ganesan S, Jayabalan V, Kumar V, Kailash K. Clinical and Radiological Outcomes of Modified Mini-Open and Open Transforaminal Lumbar Interbody Fusion: A Comparative Study. *Asian Spine J* 2018;12:544-50.
23. Gong J, Luo L, Liu H, Li C, Tang Y, Zhou Y. How Much Benefit Can Patients Acquire from Enhanced Recovery After Surgery Protocols with Percutaneous Endoscopic Lumbar Interbody Fusion? *Int J Gen Med* 2021;14:3125-32.
24. Benkirane S, Saadi H, Serji B, Mimouni A. Uterine necrosis following a combination of uterine compression sutures and vascular ligation during a postpartum hemorrhage: A case report. *Int J Surg Case Rep* 2017;38:5-7.
25. Thakkar RS, Malloy JP 4th, Thakkar SC, Carrino JA, Khanna AJ. Imaging the postoperative spine. *Radiol Clin North Am* 2012;50:731-47.
26. Hu Z, Vergari C, Gajny L, Liu Z, Lam TP, Zhu Z, Qiu Y, Man GCW, Yeung KH, Chu WCW, Cheng JCY, Skalli W. Comparison of 3D and 2D characterization of spinal geometry from biplanar X-rays: a large cohort study. *Quant Imaging Med Surg* 2021;11:3306-13.

27. Shikhare SN, Singh DR, Peh WC. Variants and pitfalls in MR imaging of the spine. *Semin Musculoskelet Radiol* 2014;18:23-35.
28. Sions JM, Elliott JM, Pohlig RT, Hicks GE. Trunk Muscle Characteristics of the Multifidi, Erector Spinae, Psoas, and Quadratus Lumborum in Older Adults With and Without Chronic Low Back Pain. *J Orthop Sports Phys Ther* 2017;47:173-9.
29. Kalichman L, Klindukhov A, Li L, Linov L. Indices of Paraspinal Muscles Degeneration: Reliability and Association With Facet Joint Osteoarthritis: Feasibility Study. *Clin Spine Surg* 2016;29:465-70.
30. Crisco JJ 3rd, Panjabi MM. The intersegmental and multisegmental muscles of the lumbar spine. A biomechanical model comparing lateral stabilizing potential. *Spine (Phila Pa 1976)* 1991;16:793-9.
31. Stark H, Fröber R, Schilling N. Intramuscular architecture of the autochthonous back muscles in humans. *J Anat* 2013;222:214-22.
32. Delp SL, Suryanarayanan S, Murray WM, Uhlir J, Triolo RJ. Architecture of the rectus abdominis, quadratus lumborum, and erector spinae. *J Biomech* 2001;34:371-5.
33. Chen KT, Wei ST, Tseng C, Ou SW, Sun LW, Chen CM. Transforaminal Endoscopic Lumbar Discectomy for L5-S1 Disc Herniation With High Iliac Crest: Technical Note and Preliminary Series. *Neurospine* 2020;17:S81-7.
34. Berg L, Thoresen H, Neckelmann G, Furunes H, Hellum C, Espeland A. Facet arthropathy evaluation: CT or MRI? *Eur Radiol* 2019;29:4990-8.
35. Chen HT, Hsu CC, Lu ML, Chen SH, Chen JM, Wu RW. Effects of Combined Use of Ultrasonic Bone Scalpel and Hemostatic Matrix on Perioperative Blood Loss and Surgical Duration in Degenerative Thoracolumbar Spine Surgery. *Biomed Res Int* 2019;2019:6286258.

Cite this article as: Liu X, Hou Y, Shi H, Zhao T, Sun C, Shi J, Shi G. A retrospective cohort study on the significance of preoperative radiological evaluation of lumbar degenerative diseases for surgical reference. *Quant Imaging Med Surg* 2023;13(8):5100-5108. doi: 10.21037/qims-22-1414