



Prenatal Diagnosis of Triploidy in Fetus with Unexpected Chromosomal Translocation of Maternal Origin

Ajinkya Jadhav,  Yamini Jadhav*,  Vidya Bhairi,  Rukaiya Ansari, 
Premkumar Torane,  Krutika Patil 

Clinical Cytogenetics Department, Lilac Insights Pvt. Ltd., Navi Mumbai, (Maharashtra), India.

Article type: ABSTRACT

Case Report

Triploidy is a lethal chromosomal abnormality. Fetuses with triploid condition have a tendency to die in early conception and very few survive to term. In this study, we report the prenatal diagnosis of fetal triploidy with unexpected chromosomal translocation. A 27 years old women was referred to our clinical cytogenetic department due to history of previous conceptus with intrauterine growth retardation at 21-22 weeks of gestation and in present pregnancy, the quadruple marker screen test had suggested a high risk for Trisomy 18 with the risk >1:50. The study was performed on the amniotic fluid and peripheral blood samples received at the clinical cytogenetics department. The interphase FISH and conventional karyotype methods were followed. The prenatal diagnosis using an amniotic fluid sample found a triploid fetus with unexpected balanced chromosomal translocation: 69, XXX,t(2;9)(q11.2;p22)x2. Later the origin of translocation was confirmed by parental chromosomal study. Cytogenetic analysis showed the presence of translocation involving chromosome 2 and 9 in the mother which confirms the maternal origin of translocation in fetal triploidy. Prenatal diagnosis of fetal triploidy with balanced translocation of maternal origin is a rare finding. In present study, the triploidy arises from the failure to expel the second polar body. It is important to perform prenatal fetal imaging with ultrasound at 18-22 weeks to identify any fetal anomalies or intrauterine growth retardation which is associated with triploidy.

Received:

2022.01.24

Revised:

2023.08.16

Accepted:

2023.08.20

Keywords: Prenatal diagnosis, fetal abnormality, amniocentesis, balanced translocation, aneuploidy detection, genetic counseling

Cite this article: Jadhav A et al. Prenatal Diagnosis of Triploidy in Fetus with Unexpected Chromosomal Translocation of Maternal Origin. *International Journal of Molecular and Cellular Medicine*. 2023; 12(1):81-85. DOI: 10.22088/IJMCM.BUMS.12.1.81

*Corresponding Author: Yamini Jadhav

Address: Clinical Cytogenetics Department, Lilac Insights Pvt. Ltd., Navi Mumbai, (Maharashtra), India.

E-mail: yamini.jadhav@lilacinsights.com



© The Author(s).

Publisher: Babol University of Medical Sciences

This work is published as an open access article distributed under the terms of the Creative Commons Attribution 4.0 License (<http://creativecommons.org/licenses/by-nc/4>). Non-commercial uses of the work are permitted, provided the original work is properly cited.

Introduction

Triploidy is a lethal chromosomal abnormality with a double chromosomal contribution from one parent to the conceptus. The occurrence of triploidy was about 2-3% of pregnancies (1-3). Triploidy frequently ends in early spontaneous pregnancy loss between 7th and 17th week of gestation (4) and rarely results in the birth of an abnormal fetus.

There are two different mechanisms for triploidy: when the extra haploid set of chromosomes from father is involved, it is called diandric and when it is from mother, it is called digynic. Diandry is most commonly due to a diploid sperm that is simultaneous fertilization of the ovum by two sperm, fertilization with a diploid sperm, and this diploid state results from nondisjunction in spermatogenesis. Digyny is usually due to diploid egg, this diploid state would result from nondisjunction at meiosis I or meiosis II of the fertilization of a primary oocyte (2).

Based on the parental origin of triploidy, it is grouped into two types. Type I is associated with diandry where a fetus with moderate growth retardation, normal or microcephalic head and enlarged placenta with partial hydatidiform mole is observed. Type II is associated with digyny where a fetus with severe growth retardation, macrocephaly, uneven development of body parts mainly growth retardation of limbs and trunks and very small non-molar placenta is observed (1, 3-6).

Materials and methods

The study was performed on the amniotic fluid and peripheral blood samples received at clinical cytogenetics department. The interphase FISH and conventional karyotype methods were followed. The written informed consent was obtained from participants for publication of the details of their medical case and any accompanying images.

Interphase FISH

The Fluorescence in-situ hybridisation (FISH) study was performed on amniotic fluid. The assay employed the XA AneuScore II assay kit probes from Metasystems, Germany comprising the XA 13/18/21 and XA X/Y mix of specific probes allows detecting copy number variation of chromosomes 13, 18, 21, X and Y. FISH probes were hybridized on to two different slides (13/18/21) and (X/Y) and the analysis was performed by two analysts as per international guidelines counting 50 nuclei per probe.

Conventional Karyotype

The amniotic fluid sample was processed for long term culture. 72 hours of stimulated culture was done on peripheral blood samples of father and mother. The GTG banding was done as per standard protocol (7). For each case, a minimum of 20 metaphases were analysed. Karyotype nomenclature was designated as per an international system for human cytogenomic nomenclature i.e. ISCN 2016 (8).

Case Report

Amniocentesis had been performed in view of previous concepts with intrauterine growth retardation at 21-22 weeks of gestation and in present pregnancy, the quadruple marker screen test had suggested a high risk for Trisomy 18 with the risk >1:50. The amniocentesis was done at 22 weeks of gestation. The mother's

age at the time of conception was 27 years whereas father was 32 years old. The fluorescence in situ hybridization and cytogenetic study on amniotic fluid was done. The FISH report showed the triploid fetus in all the cells analyzed and the cultured amniotic fluid sample showed abnormal triploid karyotype along with two reciprocal translocations between long arm of chromosome 2 and short arm of chromosome 9: 69,XXX,t(2;9)(q11.2;p22)x2 (Figure 1).

To rule out the origin of the translocation, chromosomal study was done for both the parents. The karyotype report of the father was found to be 46, XY. The mother had an abnormal 46, XX, t(2;9)(q11.2;p22) karyotype. Two translocated chromosomes in the fetus, is indicative of the triploidy arising from the failure to expel the second polar body.

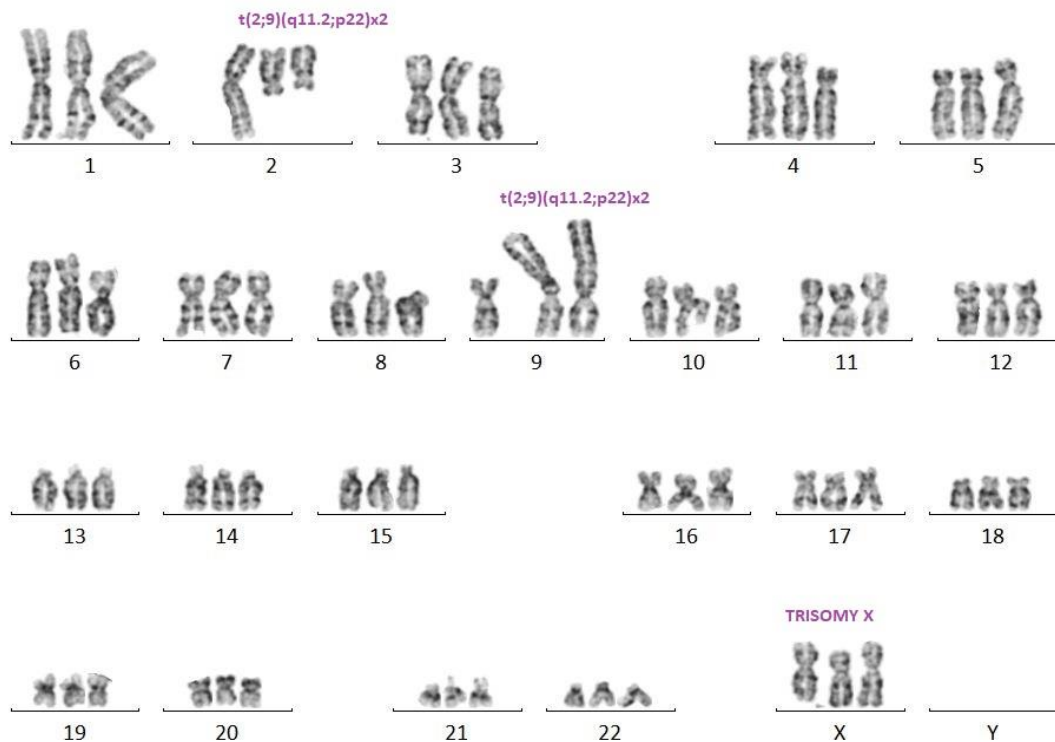


Fig.1. A GTG banded karyotype of the fetus 69,XXX,t (2;9)(q11.2;p22)x2.

Discussion

Triploidy is a common lethal chromosomal abnormality that occurs mostly as a spontaneous pregnancy loss or stillbirth and very rarely in live born infants. The triploid concepts aborting at the embryonic stage are mostly digynic in origin whereas at the fetal stage are diandric (1).

The incidence of triploidy at 11 to 14th week ultrasound scan is approximately 0.03% (3, 6, 9, 10) and at 16 to 20th week is approximately 0.02% (3, 10). The incidence of triploidy condition in live born infants is approximately 1:10000 (3, 9).

Early detection of triploidy in pregnancy is important because of risk of complications such as persistent trophoblastic disease and preeclampsia. The early detection is helpful for reducing the emotional burden of carrying a fetus with lethal fetal anomalies.

The true mosaicism in triploidy is a rare event (2). Ultrasound study detects abnormalities present in triploid fetus. The triploid fetuses are usually small due to severe intrauterine growth retardation and also they have various serious birth defects such as facial abnormalities, micrognathia, cleft lip, syndactyly of toes, syndactyly of the third and fourth fingers, cardiac defects, neural tube defect, genital anomalies, brain anomalies, dysplastic cranial bones, defects of limb and kidney (1, 4, 11).

Triploidy is a lethal genetic condition. The extra haploid set of chromosomes can be paternal origin or maternal origin. In the present study, we report that the mother with normal phenotype was the carrier of t(2;9): 46,XX,t(2;9)(q11.2;p22). The prenatal diagnosis of present pregnancy confirmed the fetal karyotype as triploidy along with the balanced autosomal reciprocal translocation inherited from mother: 69, XXX, t(2;9)(q11.2;p22)mat x2. It confirms the digynic condition of the triploid fetus. Prenatal diagnosis of fetal triploidy with balanced translocation is a rare finding.

Most conceptions with triploid condition end in first trimester spontaneous abortion. Rochon et al (12) presented a triploid conceptus with maternal chromosomal translocation involving chromosome 6 and 14 in fibroblast culture study. A mother was 22 years old with a history of G5P0A4 with a complaint of threatened abortion at 8th week of gestation. Cooper et al (13) studied a small intact amniotic sac containing a macerated fetus who was non molar, 3 mm and resorbing. The karyotype study showed triploidy with balanced translocation- 69, XXX, t(13;18)(q11;p11). The balanced translocation was inherited from the mother.

Live born infant with the triploid condition in rare events and presented with lethal conditions. There are a small number of reports of live born infants with triploid condition, Hashimoto et al (14) presented a case of triploid infant- 69,XXY that survived for an unexpected long term period of >250 days. The baby was delivered at 33 weeks 4 days because of severe fetal growth retardation. Iliopoulos et al (15) reported an infant with triploidy-69, XXX who survived for 164 days. The fetal development was normal until the 26th week of gestation, during the 30th week the head was larger in size and in the 34th week the amniotic fluid was reduced. The baby was delivered at 39th week and showed asymmetric head, low set ears, flat nasal bridge, small palpebral fissures.

Sarno et al (16) reported a rare case of complete placental/fetal discordance. Cytogenetic study of chorionic villi samples showed a triploid karyotype whereas the amniotic fluid sample and fetal blood sample showed normal diploid karyotype. The pregnancy outcome is the birth of a normal newborn. Such a possibility necessitates consideration where triploidy on chorionic villi samples accompany a normal ultrasound report.

It is important to perform prenatal fetal imaging with ultrasound at 18-22 weeks to identify any fetal anomalies or intrauterine growth retardation which is associated with triploidy. Hence it is recommended to perform the amniocentesis if any fetal anomalies are found. The present study results are helpful for genetic counseling.

Acknowledgement

The authors acknowledge the help and support of Lilac Insights Pvt. Ltd., Navi Mumbai, India and Dr. Jayaram Kadandale- Department of Clinical and Molecular Cytogenetics, Centre for Human Genetics, Bangalore, (Karnataka), India for the study.

References

1. McFadden DE, Robinson WP. Phenotype of triploid embryos. *J Med Genet* 2006;43:609-12.
2. Gardner RJM, Sutherland GR, Schaffer LG. *Chromosome Abnormalities and Genetic Counseling*. 4th ed. New York, NY: Oxford University Press; 2012; 287-289.
3. Lugthart MA, Horenblas J, Kleinrouweler EC, et al. Prenatal sonographic features can accurately determine parental origin in triploid pregnancies. *Prenat Diagn* 2020;40:705-14.
4. Kolarski M, Ahmetovic B, Beres M, et al. Genetic Counseling and Prenatal Diagnosis of Triploidy During the Second Trimester of Pregnancy. *Med Arch* 2017;71:144-7.
5. Baumer A, Balmer D, Binkert F, et al. Parental origin and mechanisms of formation of triploidy: a study of 25 cases. *Eur J Hum Genet* 2000;8:911-7.
6. Spencer K, Liao AW, Skentou H, et al. Screening for triploidy by fetal nuchal translucency and maternal serum free beta-hCG and PAPP-A at 10-14 weeks of gestation. *Prenat Diagn* 2000;20:495-9.
7. Priest J.H. Prenatal chromosome diagnosis and cell culture. In: Margaret JB, editor. *The ACT cytogenetics laboratory manual*. New York: Raven press. 1991. pp. 149–204.
8. McGowan-Jordan J, Simons A, Schmid M. *ISCN 2016: an international system for human cytogenomic nomenclature (2016)*. (No Title) 2016.
9. Engelbrechtsen L, Brondum-Nielsen K, Ekelund C, et al. Detection of triploidy at 11-14 weeks' gestation: a cohort study of 198 000 pregnant women. *Ultrasound Obstet Gynecol* 2013;42:530-5.
10. Barken SS, Skibsted L, Jensen LN, et al. Diagnosis and prediction of parental origin of triploidies by fetal nuchal translucency and maternal serum free beta-hCG and PAPP-A at 11-14 weeks of gestation. *Acta Obstet Gynecol Scand* 2008;87:975-8.
11. Silan F, Gungor ANC, Urfali M, et al. Triploidy/Diploidy Mosaicism, Diandry and Uniparental Isodisomy: Fetus with Omphalocele and Contracted Finger. *Fam Med Sci Res* 2015;4:2.
12. Rochon L, Vekemans MJ. Triploidy arising from a first meiotic non-disjunction in a mother carrying a reciprocal translocation. *J Med Genet* 1990;27:724-6.
13. Cooper PJ, Towe C, Crolla JA. A balanced whole arm reciprocal translocation resulting in three different adverse pregnancy outcomes. *J Med Genet* 1993;30:417-8.
14. Hashimoto S, Igarashi L, Kobayashi M, et al. Case Report Long-term Extrauterine Survival in a Triploid Infant: A Review of the Clinical Features of Live-born Infants with Triploidy. *HK J Paediatr (new series)* 2018;23:298-301.
15. Iliopoulos D, Vassiliou G, Sekerli E, et al. Long survival in a 69,XXX triploid infant in Greece. *Genet Mol Res* 2005;4:755-9.
16. Sarno AP, Jr., Moorman AJ, Kalousek DK. Partial molar pregnancy with fetal survival: an unusual example of confined placental mosaicism. *Obstet Gynecol* 1993;82:716-9.