

Bilateral Superficial Serratus Anterior Plane Block in a Pediatric Patient for Post-operative Analgesia Undergoing ASD Repair Via Median Sternotomy- A Case Report

Prabhat Tewari, Kushal Hajela, Syed Shabbir Ahmad

Department of Anaesthesiology, SGPGIMS, Lucknow, Uttar Pradesh, India

ABSTRACT

Serratus Anterior fascial plane (SAP) block is a high-volume interfascial plane block that has been used in adult patients in cardiac surgery with good postoperative pain relief. We report a case of a 9 year old female child who underwent ostium secundum atrial septum defect closure and was given bilateral SAP block. The patient was extubated within 4 hours of surgery and was pain free in the postoperative period without the use of any opioids.

Keywords: Bilateral SAP block, cardiac surgery, pediatric patient

Address for correspondence: Dr. Prabhat Tewari, Department of Anesthesiology SGPGIMS, Lucknow, 226014 India.

E-mail: ptewari123@yahoo.co.in

Submitted: 29-Aug-2021 **Revised:** 16-Sep-2021 **Accepted:** 17-Sep-2021 **Published:** 21-Jan-2022

INTRODUCTION

Interfascial plane blocks are gradually gaining in popularity as adjunctive approach for pain relief in the postoperative period after cardiac surgery resulting in decrease in the requirement of opioids, thereby facilitating early mobilization and discharge.^[1] The use of these high volume blocks is still very limited in the pediatric age group. We describe here the use of bilateral superficial SAP block in a small child with remarkable results that resulted in a very quick recovery and discharge from ICU with in a day.

CASE REPORT

A 9-year-old female patient weighing 20 kg having recurrent upper respiratory tract infection and failure to gain weight was diagnosed by 2D echocardiography as 17 mm large ostium secundum type of atrial septum defect (ASD) with left to right >2:1 shunt. She was posted for intracardiac

repair on cardiopulmonary bypass. Informed consent was obtained from the parents. In the operating room, after the application of basic anesthetic monitoring and insertion of the peripheral intravenous cannula, the patient was induced with injection etomidate 0.3 mcg/kg, inj. Fentanyl 2 mcg/kg and maintained with isoflurane, inj. vecuronium 0.1 mg/kg and a continuous infusion of propofol.

The Transesophageal Echocardiography probe (iE33; PHILIPS; Bothell, WA 98041-3003, made in the United States) was inserted and the preoperative diagnosis was confirmed. The right atria and ventricle were dilated and there was no other anomaly. The patient was put on CPB after bicaval cannulation. Antegrade cardioplegia with St. Thomas solution was given and the heart was arrested. The right atrium was opened and the penny-shaped ASD was closed directly without

This is an open access journal, and articles are distributed under the terms of the Creative Commons Attribution-NonCommercial-ShareAlike 4.0 License, which allows others to remix, tweak, and build upon the work non-commercially, as long as appropriate credit is given and the new creations are licensed under the identical terms.

For reprints contact: WKHLRPMedknow_reprints@wolterskluwer.com

How to cite this article: Tewari P, Hajela K, Ahmad SS. Bilateral superficial serratus anterior plane block in a pediatric patient for post-operative analgesia undergoing ASD repair via median sternotomy- A case report. *Ann Card Anaesth* 2022;25:116-8.

Access this article online	
Quick Response Code:	Website: www.annals.in
	DOI: 10.4103/aca.aca_113_21

the use of any patch. The sternotomy was closed after heparin reversal with protamine and proper hemostasis was achieved.

After the conclusion of surgery, we used a 20 gauge, 100 mm (Stimuplex Ultra 360; B BRAUN) needle using an ultrasound machine (FUJIFILM Sonosite, Inc. Bothel, WA 98021 USA) and a high-frequency linear probe (10–12 MHz) to perform a superficial serratus anterior fascial plane (SAP) block.

SAP block was given first on the left side and then on the right. The hand was extended to demarcate the mid-axillary line. The whole area was properly painted and draped. The probe was placed in the axilla in a longitudinal plane and gradually moved caudally with the pointer facing cranially. The sonoanatomy of the region was identified and then the probe was gradually shifted caudally in the same plane slightly placing it obliquely to have the proper view of ribs and serratus anterior muscle (SAM) over it [Figure 1]. The ribs were counted and the block was given to the fifth rib. The plane between the serratus muscle and the latissimus dorsi muscle was identified and opened with hydrodissection. At the correct plane, we injected a total dose of 7.5 mL of 0.2% ropivacaine on each side keeping the total dose at 1.5 mg per kg. The patient was then shifted to the intensive care unit (ICU) and was extubated within 4 hours. The patient's dynamic pain assessment was done by incentive spirometry, her Visual Analogue Scale was 2 which was reduced to 0 after a single dose of injection paracetamol 250 mg iv. The patient did not complain of any pain and discomfort at rest. During the subsequent 24 hours, the patient required no rescue analgesic and was discharged from the ICU.

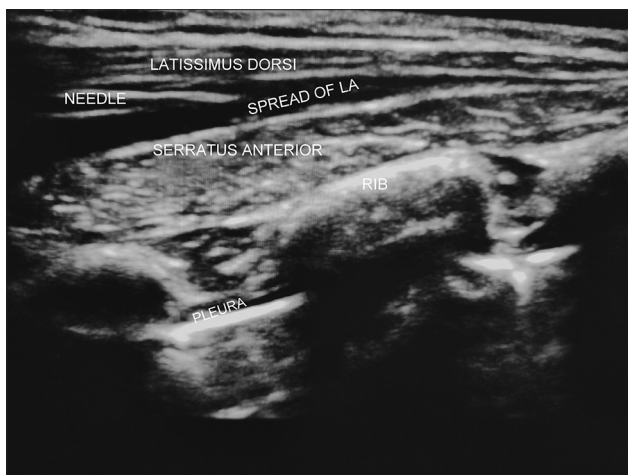


Figure 1: Sonoanatomy of the region showing needle lying between the fasciae of the Latissimus Dorsi and Serratus Anterior muscles with local anaesthetic spread

DISCUSSION

In the current era, the practice of fast-tracking anesthesia for cardiac surgical procedures necessitates the search for techniques to reduce opioid requirement and facilitate early extubation. Fascial plane blocks have come a long way in this regard owing to their ease of administration and ability to provide analgesia over large areas. Pediatric cardiac surgical patients are often good candidates for early extubation if adequate analgesia is achieved. Ultrasound-guided SAP block, a fascial plane block, in expert hands and with adequate precautions, may help to achieve adequate analgesia and facilitate early extubation in pediatric cardiac surgical patients.

The spread of the SAP block involves levels between T2 and T9 including anterior, lateral, and posterior chest wall which is primarily influenced by the volume of local anesthesia (LA) injected as well as injection site deep or superficial to the SAM. Deposition of LA deep to SAM provides analgesia by primarily blocking lateral cutaneous branches of the intercostal nerves. While superficial deposition of LA (between latissimus dorsi and SAM) blocks the long thoracic nerve and thoracodorsal nerve in addition to a lateral cutaneous branch of the intercostal nerve.^[2,3]

In our case, we gave the superficial SAP block infiltrating LA between the two, latissimus dorsi and SAMs in relation to the fifth intercostal space bilaterally. Ropivacaine, having a safer cardiac profile, was used and the amount was well below the maximum daily dose, and volume was kept to minimum. In our patient, the total duration of pain relief was almost 20 hours. The reason may be the spread of the LA better in the posterior compartment with this technique as also reported by Blanco *et al.*^[2]

Due to the large area covered by SAP block, bilateral SAP block has been found to be effective for post sternotomy analgesia in pediatric age group. In a case series reported by Kupeli *et al.*^[4] in 2021 showed the effectiveness of deep SAP block given bilaterally. This series differed from ours as the block was given before sternotomy and cardiac surgery, the plane between ribs and SA muscle was chosen and the SAP block was given at two rib levels bilaterally. The major concern with this approach we think is the very near proximity to pleura in contrast to the plane between latissimus dorsi and serratus anterior muscles. Second, a single injection rather than two on each side, if properly directed in the plane can make the large and wide local anaesthetic spread.

Deep SAP block being very near to the ribs, the muscles between the ribs and pleurae can cause more vascular injuries and potential pneumothorax that may have serious implications in the postoperative period. The younger the child and smaller the weight, these complications may increase in number and severity. Desai *et al.*^[5] in 2020 reported pneumothorax in a 63-year-old female undergoing breast lump excision. Such complications may cause prolong ICU stay defeating the purpose of fast-tracking in cardiac surgery. Other complications of SAP block may include infection, hematoma formation, local anesthetic toxicity, and hemodynamic fluctuations. However, related complications of SAP block are not very clear and further studies are needed in this direction.^[6]

CONCLUSION

The SAP block via superficial approach provided effective analgesia and reduced postoperative opioids requirement in our case. Although meticulous precautions should be exercised owing to the high systemic toxicity of LA and increased vascularity of chest wall in the pediatric age group. In this regard, observation of real-time spread of LA and expected lower systemic absorption in superficial SAP block provides additional safety. This technique also reduces the risk of complications like pneumothorax. Hence, we recommend the use of bilateral superficial SAP block for pediatric cardiac surgeries done via median sternotomy where other criteria for fast-tracking are met.

Declaration of patient consent

The authors certify that they have obtained all appropriate patient consent forms. In the form, the patient(s) has/have given his/her/their consent for his/her/their images and other clinical information to be reported in the journal. The patients understand that their names and initials will not be published and due efforts will be made to conceal their identity, but anonymity cannot be guaranteed.

Financial support and sponsorship

Nil.

Conflicts of interest

There are no conflicts of interest.

REFERENCES

1. Dontukurthy S, Mofidi R. The role of interfascial plane blocks in paediatric regional anaesthesia: A narrative review of current perspectives and updates. *Anesthesiol Res Pract* 2020;2020; Article ID 8892537, 10 pages. <https://doi.org/10.1155/2020/8892537>.
2. Blanco R, Perras T, McDonnell JG, Prats-Galino A. Serratus plane block: A novel ultrasound guided thoracic wall nerve block. *Anaesthesia* 2013;68:1107-13.
3. Kelava M, Alfirevic A, Bustamante S, Hargrave J, Marciniak D. Regional anaesthesia in cardiac surgery: An overview of fascial plane chest wall blocks. *Anesth Analg* 2020;131:127-35.
4. Kupeli I, Adilovic AS. The “Feasibility” and “Safety” of Ultrasound guided bilateral two level serratus anterior plane block in children with median sternotomy pain: A case series. *J Cardiothorac Vasc Anesth* 2021;35:270-3.
5. Desai M, Narayanan MK, Venkataraju A. Pneumothorax following serratus anterior plane block. *Anaesth Rep* 2020;8:14-6.
6. Xie C, Ran G, Chen D, Lu Y. A narrative review of ultrasound guided serratus anterior plane block. *Ann Palliat Med* 2021;10:700-6.