

# Electrophysiological examination in uveitis: a review of the literature

Marilita M Moschos<sup>1</sup>  
Nikolaos S Gouliopoulos<sup>1</sup>  
Christos Kalogeropoulos<sup>2</sup>

<sup>1</sup>Laboratory of Electrophysiology,  
First Department of Ophthalmology,  
University of Athens, Athens, Greece;

<sup>2</sup>Department of Ophthalmology,  
University of Ioannina, Ioannina,  
Greece

**Purpose:** Uveitis is the inflammation of the uveal tract, which usually also affects the retina and vitreous humor. The electrophysiological examination is an objective ocular examination that includes the electroretinogram, visual evoked potentials, the electrooculogram, the multifocal electroretinogram, and multifocal visual evoked potentials. Our aim is to review the literature of the use of the electrophysiological examination in cases of uveitis.

**Methods:** We performed a systematic search of the literature of published papers until October 2012 using the PubMed search engine. The key terms that were used were “uveitis”, “electrophysiological examination”, “electroretinogram”, “visual evoked potentials”, “electro-oculogram”, “multifocal electroretinogram”, and “multifocal visual evoked potentials” in multiple combinations. To the best of our knowledge, this is the first review concerning the assessment of electrophysiology in uveitis.

**Results:** Our search of the literature demonstrated that the electrophysiological examination, mainly by means of electroretinogram, multifocal electroretinogram, and visual evoked potentials, is performed in several cases of uveitis for many purposes, including diagnosis and monitoring of disease progression and treatment efficacy. The electrophysiological examination is more useful in patients with multiple evanescent white dot syndrome, acute posterior multifocal placoid pigment epitheliopathy, birdshot chorioretinopathy, Vogt–Koyanagi–Harada disease, Adamantiades–Behçet disease, ocular syphilis, and Fuchs heterochromic cyclitis.

**Conclusion:** This review summarizes the use of the electrophysiological examination in uveitic patients and underlines its value as a useful tool in the objective assessment and the monitoring of the disease.

**Keywords:** uveitis, ERG, mfERG, VEP

## Introduction

### Uveitis

Uveitis is the inflammation of the uveal tract, which is composed of the iris, the ciliary body, and the choroid. The inflammation in uveitis is located not only in the uveal tract but also usually affects the adjacent structures, mainly the retina and the vitreous humor.<sup>1</sup> Uveitis can be acute sudden onset, chronic long lasting, or recurrent relapsing. The disease is classified according to the principal anatomic location of the inflammation in four categories, which are anterior uveitis – iris and/or ciliary body; intermediate uveitis – peripheral retina, pars plana of the ciliary body; posterior uveitis – choroid and retina; and panuveitis – whole uvea.<sup>2</sup> The prevalence of uveitis is approximately 38 cases per 100,000 people.<sup>3</sup> Uveitis is more frequent in young adults, with the mean age of disease onset being between 35 and 45 years. Uveitis affects both sexes,

Correspondence: Marilita M Moschos  
Laboratory of Electrophysiology,  
First Department of Ophthalmology,  
University of Athens, 6 Ikaras,  
Ekali, Athens 14578, Greece  
Tel +30 694 488 7319  
Fax +30 210 776 8321  
Email moschosmarilita@yahoo.fr

with the disease being a little more prevalent in women in the developed world. Multiple studies have reported that anterior uveitis is the most common form of uveitis – over 50% – while the other forms are less frequent.<sup>4</sup>

Uveitis is a major cause of severe visual impairment, being the fourth most frequent reason of blindness in the working-age population in the developed world,<sup>4–6</sup> while in the US it is the cause of 10%–15% of cases of blindness.<sup>7</sup> Panuveitis is associated with the worst prognosis. This visual dysfunction is a result of uveitic complications, of which the most important are cataract formation, cystoid macular edema, band keratopathy, secondary glaucoma, vitreous opacities, retinal detachment, retinoschisis, “retinitis pigmentosa-like” changes, and dragged disk vessels.<sup>8</sup> Typical symptoms and signs of uveitis include eye redness, eye pain, light sensitivity, blurred vision, floaters, and decreased vision.

The etiology of uveitis includes many different causes, both systemic disorders with ocular involvement and disorders that are primarily located in the eye, such as local infection due to herpes simplex virus or *Cytomegalovirus* (CMV) retinitis. However, in many cases, there is not a specific cause recognized, and then uveitis is characterized as idiopathic. Uveitis has been associated with sarcoidosis, Behçet’s syndrome, rheumatoid arthritis, juvenile chronic arthritis, ankylosing spondylitis, Reiter’s syndrome, psoriatic arthritis, inflammatory bowel disease, (ulcerative colitis, Crohn’s disease), syphilis, tuberculosis, and toxoplasmosis. Moreover, an ocular injury can result in uveitis. In addition, uveitis-masquerade syndromes due to malignant (mainly lymphomas and leukemia) and nonmalignant diseases should be taken into consideration in the differential diagnosis.

The assessment of uveitis is based on a complete ophthalmologic examination, which includes visual acuity (VA) examination, slit-lamp examination, indirect ophthalmoscopy and evaluation of the posterior pole after pupil dilatation, and evaluation of the intraocular pressure. Furthermore, a complete medical history should be acquired, and laboratory tests may be performed in order that possible coexisting systemic diseases are recognized.

## Electrophysiology

The electrophysiological examination is widely used in clinical practice for the assessment of multiple ocular diseases. It is an objective tool, because the evaluation of ocular lesions is achieved regardless of the patient’s cooperation, and subclinical and previously undetected dysfunctions may be revealed. Apart from the diagnosis of an ocular disease, the electrophysiological examination is also used for the

monitoring of disease progression and the efficacy of the applied treatment. Furthermore, the findings of the electrophysiological examination are significant in identifying the location of the ocular lesion. The examination allows the assessment of visual system integrity in the presence of opaque media as well.

The electrophysiological examination includes the electroretinogram (ERG), visual evoked potentials (VEPs), electrooculogram (EOG), multifocal ERG (mfERG), and multifocal VEPs (mVEPs).

## Electroretinogram

The ERG is an electrophysiological examination that reflects retinal electrical potential in response to a light stimulus.<sup>9</sup> It is a useful test that objectively evaluates retinal function, allowing the detection of retinal dysfunction even in the absence of an abnormality in the fundus examination.<sup>10</sup> All the retinal cells contribute in the ERG recording, and different stimuli, flashes, or patterns allow a stronger response from more specific retinal cells.<sup>11</sup>

Flash ERG represents the retinal electrical response to photic stimulation, and the generated waveform consists of four major waves: a, b, c, and d. The first two are seen consistently in clinical practice, whereas d-waves appear only if the stimulus is applied for sufficient time.<sup>12</sup> The a-wave is the first negative wave, and is followed by the positive b-wave, which is followed by a second negative wave – the c-wave. The amplitudes and implicit times of the waves are measured in ERG evaluation.<sup>12</sup> a-Waves are generated by the photoreceptors in the outer retina, b-waves reflect the responses of bipolar and Müller cells in inner retinal layers, c-waves are generated in the retinal pigment epithelium (RPE), and d-waves reflect the activity of “off” bipolar cells.<sup>13,14</sup> The evaluation of b:a wave ratio is used as an index of inner to outer retinal function,<sup>15</sup> and the analysis of the waves gives information about the location of a retinal lesion.<sup>16</sup> It is a useful clinical adjunct in the assessment of various retinal and choroidal disorders, such as retinitis pigmentosa, Leber’s congenital amaurosis,<sup>17</sup> congenital stationary night blindness, congenital achromatopsia, cone–rod dystrophies, retinal aplasia, total retinal detachment, ophthalmic artery occlusion,<sup>18,19</sup> cancer-associated retinopathy, melanoma-associated retinopathy, intraocular lymphoma,<sup>20</sup> toxic retinopathies,<sup>21</sup> hepatic retinopathy,<sup>22</sup> diffuse retinal and choroidal inflammations,<sup>22</sup> and traumatic retinal lesions.<sup>12</sup> It is also useful in preoperative evaluation in the presence of opaque media.<sup>12</sup>

The oscillatory potentials (OPs), initially described by Cobb and Morton as a component of ERG,<sup>23</sup> are four to six

wavelets normally seen on the rising limb of the b-wave.<sup>11,24</sup> All retinal components have been proposed as generators of OPs, except for the photoreceptors and the Müller cells.<sup>14</sup> Multiple studies have identified OPs as sensitive indicators of diabetic retinopathy,<sup>25–29</sup> since they monitor the progression of the disease and detect early neuronal alterations.<sup>22</sup> They have also been identified as a useful tool in such diseases as glaucoma,<sup>30</sup> vascular occlusions,<sup>31,32</sup> and congenital eye diseases.<sup>33</sup>

Pattern ERG (PERG) is generated by a stimulus structure in the form of a black-and-white alternating checkboard or bars on a pattern monitor.<sup>34</sup> The PERG wave consists of three components. The first, a small negative component, is N35, which is followed by a prominent positive component, P50, and finally a large negative component – N95.<sup>35</sup> PERG is used primarily for the evaluation of the function of inner retinal layers and especially the ganglion cells layers of the retina.<sup>20,35</sup> It is useful in detecting macular and inner retinal lesions that do not affect the flash ERG. Furthermore, in the presence of an abnormal VEP recording, PERG can be used in order to determine if the abnormality is caused by macular or optic nerve dysfunction. In optic nerve dysfunctions, it is useful for quantification of neural loss.<sup>35</sup> PERG is a significant testing method in glaucoma, and it can be also used as a predictor of the progression of ocular hypertension to glaucoma.<sup>22</sup> Moreover, PERG is used for the diagnosis and management of several diseases, especially demyelinating optic neuropathies,<sup>22</sup> toxic lesions of the anterior visual pathway, Leber's hereditary optic neuropathy, dominant optic atrophy, multiple sclerosis, nonarteritic anterior ischemic optic neuropathy, and compressive diseases of the optic chiasm.<sup>35</sup>

### Visual evoked potentials

VEPs are an electrophysiological examination whose findings objectively reflect the functional integrity of the whole visual pathway, from the photoreceptors to the visual cortex in the occipital cortex. VEPs are generated by the electrical activity in the entire visual cortex because of stimulation of the eye. Since the central retina is represented in the visual cortex in a much larger area than the peripheral retina, the VEPs reflect primarily central visual function. The International Society for Clinical Electrophysiology of Vision recognizes three types of stimuli: the flash, the pattern reversal, and the pattern on/off, while beyond these, variations of VEPs, such as sweep and dichoptic, can be performed in special clinical conditions. Pattern-reversal VEPs are the most suitable for the assessment of both pre- and postchiasmal lesions, while flash VEPs are preferred in the presence of opaque media

and the on/off VEPs for the evaluation of VA. The most important markers in VEP examination are the amplitude and the latency of P100, which is the largest positive component of the VEP.

VEP examination is useful in the assessment of the visual function in uncooperative patients. Moreover, a normal VEP examination can exclude several disorders associated with the visual pathway. A disadvantage of the examination is that since it reflects the entire visual pathway, an abnormal test does not provide the exact location of the dysfunction.<sup>36</sup> Another disadvantage is the fact that due to the overrepresentation of the macula in the visual cortex, any macular lesions are overexpressed in the VEP findings.<sup>37</sup>

The VEP examination is valuable in assessing optic neuropathies due to several causes, such as toxins, vascular abnormalities in diabetes, and nutritional deficiencies. It is also useful in the evaluation of optic nerve integrity in the presence of tumors that compress the optic nerve, and in the presence of glaucoma and any other cases accompanied by intraocular hypertension. In cases of optic neuritis, especially due to multiple sclerosis, the VEP examination is valuable for both the diagnosis and the monitoring of the disease. In multiple sclerosis, it can also diagnose subclinical optic nerve involvement, even if optic neuritis is not obvious.<sup>38</sup> Furthermore, VEPs are recorded as abnormal in maculopathy, in ocular media opacities, in amblyopia, and in uncorrected refractive errors.<sup>12,36</sup> VEP examination, in combination with mfERG and PERG, can establish the area of dysfunction in cases of unexplained visual loss.<sup>36</sup>

### Electrooculography

EOG is an electrophysiological test that examines the function of the outer retina and RPE, reflecting metabolic changes in the RPE and giving extra information about retinal function and supporting tissues.<sup>39</sup> EOG evaluates changes in resting potential between the cornea and the back of the eye during successive periods of dark and light adaptation, while the most significant structure of its formation is the RPE. It is expressed as a ratio of the peak amplitude in the light to the minimum amplitude in the dark (light/dark or Arden ratio).

EOG is mainly used in conjunction with ERG, and together these give an objective evaluation of visual function. However, when evaluating its results, it should be taken into account that age severely affects the findings of the EOG examination.<sup>22</sup>

EOG is a useful examination in detecting early retinal intoxication due to treatment with antimalarial drugs, especially quinine and chloroquine.<sup>12</sup> It is also a very important examination

in detecting retinal detachment in eyes with opaque media, since it is more accurate than ERG.<sup>12</sup> Abnormal EOG values are also recorded in acute zonal occult outer retinopathy.

EOG findings are almost always correlated with the ERG findings, a fact that results in the limited use of EOG in clinical practice. However, there are cases in which a normal ERG is accompanied by a highly abnormal EOG examination. Those are vitelliform dystrophy (Best's disease), autosomal recessive bestrophinopathy, and autosomal-dominant vitreoretinopathy.

### Multifocal ERG

mfERG is an electrophysiological examination that was developed by Sutter and Tran.<sup>40</sup> mfERG objectively evaluates the macula, allowing functional mapping of the central retina by selecting electrical responses from multiple retinal locations of the macular area, which are tested simultaneously.<sup>41</sup> mfERG reflects the electrophysiological responses from both the photoreceptors and the inner retinal layers, including the bipolar and Müller cells.<sup>42</sup> Its findings are useful in detecting the location and the extent of central lesions or excluding the dysfunction of outer retinal layers of the macula.<sup>36,40</sup> The typical mfERG waveform is a biphasic wave, and consists of an initial negative deflection followed by a positive peak, after which there is usually a second negative deflection. These are named N1, P1, and N2, respectively.<sup>43</sup> mfERG is also displayed as 3-D response-density plots, which should be accompanied by the corresponding trace array.

The integrity of the foveal photoreceptors, which are responsible for normal VA, is demonstrated by retinal responses in the fovea, also called area 1, which also reflect the electrical activity of the photoreceptors and the inner layers of the perifoveal area.<sup>44</sup> Consequently, retinal lesions in this area may be mapped by mfERG, even if they are not visible in the ophthalmoscopic examination or if VA of the eyes is normal. In diseases of the outer retina, the pattern of distribution of mfERG activity is similar to the pattern of visual field defect, whereas in disorders of the ganglion cell layer, no correlation between the mfERG waveform and defects in visual fields could be found.<sup>45</sup>

mfERG is a useful tool in clinical practice. It may be used for the assessment of cases of unexplained visual loss, and together with VEP recordings and PERG, is the most suitable examination in such cases.<sup>36</sup> It is also useful in the differential diagnosis of retinal and optic nerve diseases. In retinitis pigmentosa, mfERG is an objective method for the evaluation and monitoring of residual retinal function in the macular region.<sup>46</sup> In maculopathies, such as age-related macular

degeneration, macular holes, vitelliform maculopathies, juvenile retinoschisis, and central serous retinopathy, the central responses in mfERG are either absent or very decreased, and they are surrounded by normal or almost normal responses (volcano-like appearance in the 3-D plot appearance), allowing not only the recognition of central lesions but also the evaluation of their extent.<sup>45</sup> Abnormal implicit times in mfERG have been found in regions associated with retinal edema because of central retinal vein occlusion and in regions associated with exudation because of diabetic retinopathy.<sup>45</sup> Moreover, mfERG responses are highly abnormal in patients with cone dystrophies, and in the affected areas of CMV retinitis.<sup>45</sup> Furthermore, mfERG may be used as a measure of the success of a treatment in macular holes, since it has been demonstrated that the initially decreased central responses increase after surgical treatment.<sup>47</sup>

### Multifocal VEP

mVEP is an objective electrophysiological examination that evaluates the functional integrity of the visual pathway from the retina to the visual cortex.<sup>48</sup> The mVEP examination allows the recognition and isolation of local lesions of the visual pathway, which are small or undetected with the conventional VEP examination. mVEPs demonstrate the function of the optic nerve in a more detailed way compared to conventional VEPs, since the recordings include information from optic nerve fibers that are reflected in the periphery of the visual field.<sup>49</sup>

mVEP examination is an objective tool for the evaluation of the visual fields and defects in various disorders.<sup>50</sup> It may be useful in the assessment of optic neuropathies with an unreliable visual field examination, while its findings may demonstrate lesions of the visual pathway that have not yet been shown in the automatic perimetry.<sup>51</sup> In optic neuropathies, such as glaucoma, mVEP examination is useful, since its findings correlate with the visual field defects in automatic perimetry,<sup>52</sup> while in glaucomatous patients mVEP examination also provides parameters that are good predictors of psychophysical losses.<sup>52</sup> mVEP recordings are also used for identifying local lesions in ischemic optic neuropathy<sup>53,54</sup> and optic neuritis.<sup>55</sup> Furthermore, in retinitis pigmentosa, it has been suggested that the findings of the mVEP and mfERG examination are useful for the evaluation and the monitoring of residual central retinal function.<sup>46</sup>

## Electrophysiological examination in uveitis

Electrophysiological tests do not constitute common examination methods for the study of uveitis; however, in certain

uveitic entities, they can contribute to the evaluation of the severity and expansion of the impairment due to the uveitis, the evolution of the uveitis, and the response to the treatment. On the other hand, electrophysiology is helpful in some clinical cases for either the differential diagnosis or confirmation of diagnosis in uveitis. During recent years, there has been ongoing interest in electrophysiology in the study of uveitis and the pathophysiology of uveitis complications. In the following paragraphs, the findings of the electrophysiological examination will be discussed in different forms of uveitis. Since white-dot syndromes (WDSs) are discussed in detail with regard to the electrophysiological examination, it is worth mentioning that WDS is a term classically restricted to certain well-defined entities, ie, multiple evanescent WDS (MEWDS), acute posterior multifocal placoid pigment epitheliopathy, and acute zonal occult outer retinopathy. However, white dots occur in almost all inflammatory conditions of the posterior segment, ie, multifocal choroiditis, birdshot retinochoroidopathy, ocular histoplasmosis, sympathetic ophthalmia, Vogt–Koyanagi–Harada (VKH) disease, serpiginous choroiditis, sarcoidosis, and tuberculosis, including infectious and noninfectious posterior-segment intraocular inflammations. There is a considerable overlap of clinical presentation of WDS with other conditions. Electrophysiological examination provides in those cases interesting information.

### Multiple evanescent white-dot syndromes

MEWDS is a self-limiting inflammatory disease of unknown etiology, which is characterized by multiple discrete dots located at the level of the outer retina or the RPE (dysfunction of the RPE is revealed by EOG abnormalities). Several cases have been reported regarding the findings of mfERG examination in MEWDS patients, and significantly decreased amplitudes were found in the areas corresponding to visual field scotomas.<sup>56,57</sup>

The electrophysiological examination is useful in the investigation of outer and inner retinal function in MEWDS patients, and its findings are used in determining where functional abnormalities initially occur. Horiguchi et al<sup>58</sup> performed a study in MEWDS patients, and they demonstrated abnormal a- and b-wave amplitudes as well as abnormal oscillatory potentials. Their findings suggested that both the outer and the inner retina are affected in MEWDS. As far as which area is affected first, the findings are questionable. There have been reports suggesting that the outer retina is affected first,<sup>59,60</sup> while others suggest the opposite. Cheng et al<sup>61</sup> performed full-field ERG, mfERG, and multifocal

oscillatory potentials, which reflect inner retinal function, in three MEWDS patients. They found that multifocal oscillatory potentials are reduced throughout the retina, even in areas where mfERG is recorded as normal, suggesting that the dysfunction initially takes place in the inner retina and the outer retina is affected afterwards.

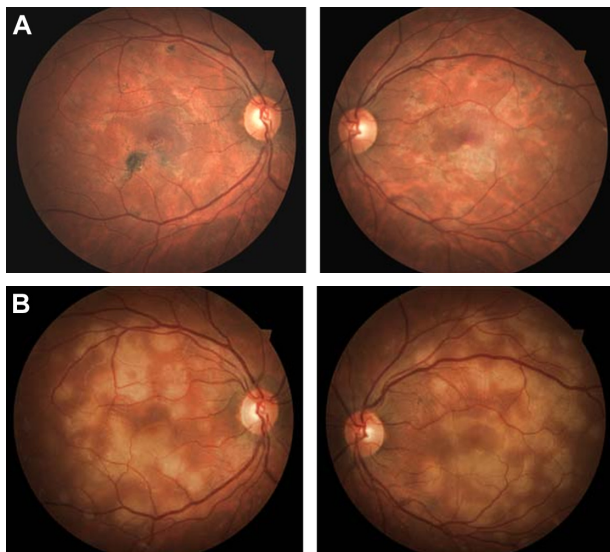
It has been suggested that electrophysiological examination may be useful in detecting the first manifestations of MEWDS. Sieving et al<sup>62</sup> demonstrated that the acute phase of the disease is accompanied by a significant decrease of the a- and b-waves of the Ganzfeld ERG and of the early receptor-potential amplitudes. Feigl et al<sup>63</sup> examined MEWDS patients for whom mfERG was recorded at different times after the onset of the disease. According to them, the early stages of the disease (1 day to 1 week after onset) are characterized by supernormal N1- and P1-wave amplitudes of the first-order kernel in mfERG, which get reduced to subnormal values in 2 weeks' time. In the later stages of the disease, the N1- and P1-wave amplitudes are recorded as decreased or within the normal range. As for the P1 latencies, their values remain normal in all stages.

mfERG has also been used in monitoring the recovery of retinal dysfunction due to MEWDS. Chen et al<sup>57</sup> reported that mfERG abnormalities were resolved together with the resolution of clinical symptoms, while Huang et al<sup>56</sup> reported a case in which mfERG abnormalities were still present after clinical resolution, a finding that indicates a delayed recovery of the retinal function. Although rarely, VEPs reveal in some cases transient dysfunction of the optic nerve.<sup>64</sup>

Therefore, electrophysiological examination results in MEWDS (especially mfERG) are sensitive indicators of recovery compared to VA, visual field, and imaging techniques.

### Acute posterior multifocal placoid pigment epitheliopathy

Acute posterior multifocal placoid pigment epitheliopathy (APMPPE) is a self-limited inflammatory chorioretinal disease of unknown etiology, which is characterized by multiple yellow-white placoid subretinal lesions of the posterior pole (Figure 1). Deutman et al<sup>65</sup> studied EOG and ERG recordings in APMPPE patients. EOG responses were recorded as highly abnormal in the acute phase of the disease, indicating presumably a severe dysfunction of the RPE, whereas in the scar stage the EOG recordings were significantly improved (Figure 2). The ERG findings in the acute phase consisted of slightly abnormal values of the a- and b-wave amplitudes. ERG recordings after recovery demonstrated similar results,



**Figure 1** (A and B) Fundus of a 30-year-old man diagnosed with acute multifocal placoid pigment epitheliopathy. (A) Acute phase of disease; (B) scar phase of the disease.

reflecting a lag recovery of retinal function. Concerning ERG findings, there are some discrete differences between APMPE and MEWDS (Table 1). VEPs have been found either to be normal or abnormal, suggesting in the latter a more extended involvement including the optic nerve.

### Birdshot chorioretinopathy

Birdshot chorioretinopathy (BCR) is a rare chronic bilateral intraocular inflammatory disease (Figure 3), which accounts for approximately 6% of posterior uveitis cases, and is highly associated with the human leukocyte antigen A29 haplotype.<sup>66,67</sup> ERG has been tested in BCR patients. ERG results are associated with the severity and the stage of the disease.<sup>68</sup> In mild cases, ERGs may be recorded as supernormal, while the disease progression is accompanied by diminished ERGs until they become unrecordable in the late stages of the disease, a finding that corresponds with the poor night vision that BCR patients face at those stages.<sup>69</sup>

BCR is the first uveitic entity in which ERG found application. The most predominant finding in ERG examination is an electronegative pattern with selective b-wave amplitude reduction (Figure 4) compared to the a-wave amplitude, which results in a low b:a ratio. This ERG pattern is unique in BCR, and does not appear in any other type of uveitis.<sup>68</sup> Taking into account the fact that the b wave is generated in the neural retinal layers, it has been suggested that the initial dysfunction in BCR is located in the inner neural retinal layers. Sobrin et al<sup>69</sup> performed ERG examinations in 23 BCR patients, and reported that severe abnormalities in a-wave amplitudes and timing were also observed at the patients' examination before treatment,

suggesting that the outer retinal layers and the photoreceptors are affected early in the progression of the disease, probably by the coexisting choroidal inflammation. In EOG, pathological findings have also been recorded.

ERG data, and particularly the 30 Hz flicker implicit time and bright scotopic amplitudes, have been used as the most sensitive indicators of disease activity.<sup>70</sup> A normal 30 Hz implicit time before treatment is associated with a favorable prognosis.<sup>37</sup> Furthermore, these two ERG parameters can predict if tapering of immunomodulatory therapy will result in recurrence of inflammation.<sup>70</sup> It is suggested that immunosuppressive therapy should not be tapered before the normalization of these parameters is achieved in both of the patient's eyes. They are also useful in monitoring patients during the course of taper, and if they get abnormal then immunosuppressive therapy should be increased.

### Vogt–Koyanagi–Harada disease

VKH disease is an autoimmune condition in which ocular manifestations include anterior-segment inflammation, choroiditis, and exudative retinal detachment. In VKH disease, electrophysiological examination by means of mfERG is a useful and sensitive tool for the detection of early retinal damage, since mfERG responses may be significantly reduced in VKH patients – after the resolution of inflammation – who have normal VA and no obvious retinal atrophy.<sup>71</sup>

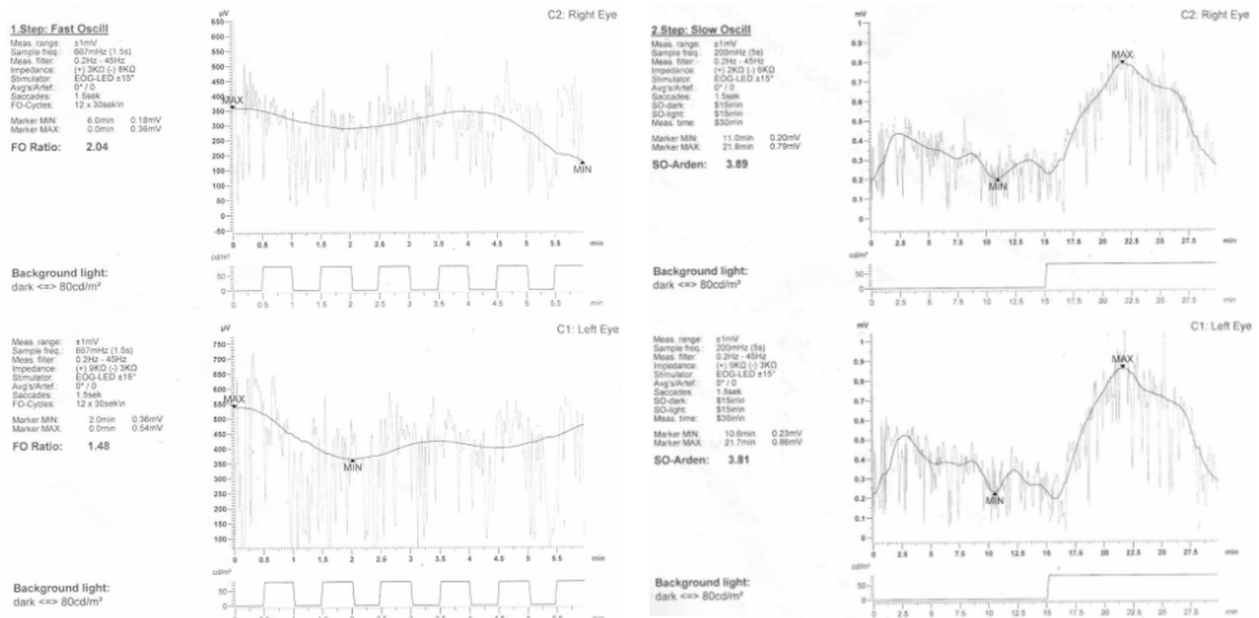
mfERG is also a useful test in guiding the therapy of VKH patients. Yang et al<sup>72</sup> performed a study in which mfERG was evaluated, along with best-corrected VA, in VKH patients before and during treatment with immunosuppressive agents. Before treatment, VA was decreased and mfERG highly abnormal. During treatment, VA rapidly improved in the first month, while N1 and P1 amplitude and latency improved significantly in 3 months. However, P1 and N1 amplitude remained significantly decreased after 12 months. These results indicate that immunosuppressive agents in VKH lead to an early improvement in VA, but with delayed and limited recovery of macular function.

Previous electrophysiological studies in VKH have proved that retinal dysfunction of inner layers is mild and reversible. On the contrary, the retinal dysfunction of outer layers is severe, and the hyperosmolarity response in the EOG has been reported to be suppressed at the convalescent stage of the disease.<sup>73,74</sup>

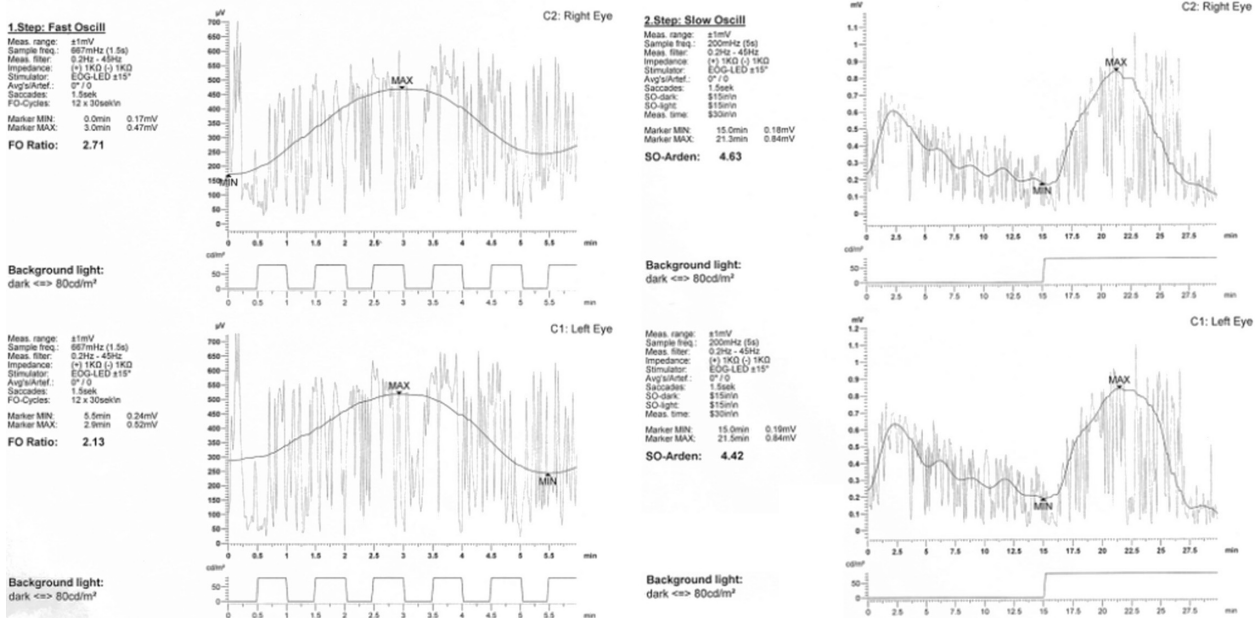
### Adamantiades–Behçet disease

Adamantiades–Behçet disease (ABD) is a chronic, recurrent multisystemic vasculitis of unknown etiology, and classic

**A**



**B**



**Figure 2 (A)** Electrooculogram recording of the same patient as in Figure 1, showing decrease in the acute phase in both eyes. **(B)** Electrooculogram showing improvement after treatment.

symptoms include oral aphthous ulcers, genital ulcers, and uveitis.<sup>75</sup> Electrophysiological examination by means of VEPs may be helpful in disclosing subclinical involvement of the central nervous system in ABD patients without symptoms, or even findings in neurological examination. A study<sup>76</sup> that was performed in such a population revealed abnormal VEPs, since the mean latency value of P100 was significantly delayed compared to healthy subjects (Figures 5 and 6).

As for initial retinal lesions in ABD patients, it has been hypothesized that they take place in the inner retinal layer. To confirm this, Asai et al<sup>77</sup> examined the hyperosmolarity response (which originates in the RPE layer) on EOG, the oscillatory potentials (which originate in the inner retinal layer), and the rapid-off response in ERG in six ABD patients. The findings included highly abnormal oscillatory potentials, especially in the earlier stages of the disease, while the rapid-off response and the hyperosmolarity response were in

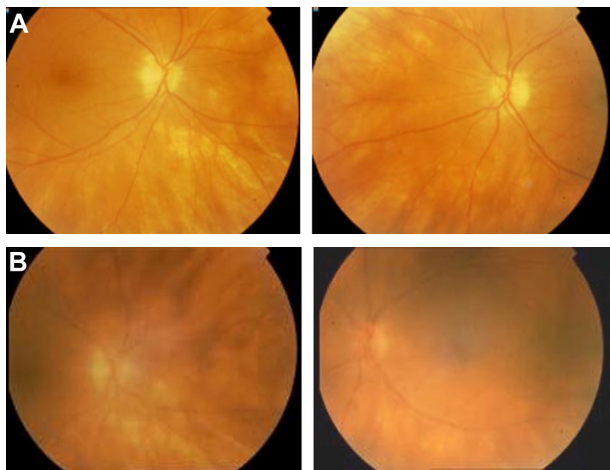
**Table 1** Findings and clinical usefulness of electrophysiological examination in uveitis

Diseases	VEP	ERG	EOG	Usefulness of electrophysiological examination	Differential diagnosis
MEWDS	In some cases: decrease of P100 amplitude P100 delayed	Acute phase: a- and b-wave amplitude reduced oscillatory potentials abnormal Resolved in recovery	Abnormal	Findings suggested that both outer and inner retina are affected Sensitive indicator of recovery (especially mfERG)	APMPPE AMN MCP Birdshot DUSN PIOL Sarcoidosis Metastases Viral retinitis <i>Toxoplasma</i> RC Pneumocystis C VKH Other WDS Pars planitis Papilledema PIOL VKH MEWDS OHS SO Sarcoidosis Posterior scleritis CSCR multifocal type Multifocal choroiditis WDS Sympathetic ophthalmia
APMPPE	Either normal or abnormal	Acute phase: slightly abnormal values of a- and b-wave Recovery: similar results, contrary to MEWDS	Acute phase: highly abnormal Scar stage: significantly improved	Findings suggested a severe dysfunction of RPE in acute phase and a possible involvement of optic nerve, indicating an implication of CNS	
Birdshot chorioretinopathy		Selective b-wave amplitude reduction most prominent finding, prolonged implicit times Late stages: ERGs extinguished	Abnormal	ERG results: 1) are unique for BCR 2) are associated with the severity and stage of the disease and 3) are useful guide for treatment monitoring	
Vogt-Koyanagi-Harada		Before treatment: highly abnormal During treatment, NI and PI amplitude and latency initially improve significantly, but NI and PI amplitude remains significantly decreased compared to normal for at least 1 year Improvement of amplitudes in patients without chronic disease	Suppressed at the convalescent time of the disease	MfERG: useful test in guiding the therapy and detecting early retinal damage ERG + EOG combined results: the dysfunction is more severe and permanent concerning the outer layers	
Behçet's disease	P100 significantly delayed (in neuro-Behçet even without clinical signs) Significantly reduced in a significant proportion of patients Values recovered much more slowly after VA restoration	In chronic or recurrent, remains abnormal Before treatment: almost extinguished or highly abnormal After treatment: initiation: values recovered much more slowly after VA restoration PERG and flash-ERG abnormalities, along with reduced amplitude of oscillatory potentials Photopic and scotopic ERG decreased in <i>Toxoplasma</i> retinochoroiditis	Normal	ERG is mostly useful in testing the efficacy of therapy VEP: diagnosis of subclinical involvement of CNS VEP: evidence that optic nerve is commonly affected in syphilitic uveitis MfERG and VEP: monitoring of the recovery of outer retina and optic nerve ERG findings suggest subclinical retinal damage associated with FHC Localization of lesions, cloudy vitreous, or cases in doubt concerning active disease, the latter of crucial importance in immunocompromised patients Detection of possible optic nerve affection	Sarcoidosis Syphilis (as other causes of retinal vasculitis) Syphilis may mimic any form of PSI
Ocular syphilis					
Fuchs heterochromic cyclitis <i>Toxoplasma</i> retinochoroiditis	Rarely abnormal				Especially in immunocompromised individuals Herpes simplex, syphilis, and CMV retinitis



Crohn's disease	Before treatment: a/b amplitudes reduced After treatment: mildly reduced Delayed b-wave implicit time Abnormal response to 30 Hz flicker Reduced b-wave oscillatory potentials Amplitudes abnormally reduced Photopic and scotopic b-waves abnormal Abnormal in cases with retinal affection	More precise assessment of the disease impact and better treatment monitoring Indication of retinal involvement and eventual retinal vasculitis	
Intermediate uveitis			
Sympathetic ophthalmia		Early detection of disease progression potentially helping treatment strategies	VKH
Sarcoidosis	Abnormal in some cases with retinal affection	Assessment of intraocular inflammation expansion	Sarcoidosis Any form of PSII, especially those without a characteristic clinical pattern
Acute retinal pigment epithelitis	Normal	Early detection of possible subclinical neurosarcoidosis EOG abnormalities imply a more widespread RPE dysfunction than revealed by angiography	APMPPE AMNR
Acute macular neuroretinopathy	Either normal or abnormal, especially pattern ERG	Assessment of macular function impairment	Acute retinal pigment epithelitis MEWDS APMPPE CSCR Optic neuritis Old inner retinal infarcts Tuberculosis Syphilis POHS Viral retinitis MEWDS, PIC, APMPPE BCR Sarcoidosis, SO, VKH
Multifocal choroiditis panuveitis	Abnormal extinguished ERG responses Poor oscillatory potentials	Severe chorioretinal involvement	
Punctate inner choroidopathy	Normal	Absence of retinal affection	Masquerade syndrome IOL Multifocal choroiditis and panuveitis, MCP, and other types of WDS
Serpiginous choroiditis	Usually normal, with the exception of extensive disease with reduced ERGs, especially in posterior pole involvement	Assessment of disease severity and progression	APMPPE, MCP, ARPE, TB choroiditis Outer-layer retinal toxoplasmosis Sarcoidosis choroiditis Harada's disease
Masquerade syndromes simulating uveitis	IOL: all amplitudes reduced b-wave amplitude: the most significantly affected CAR: all amplitudes extinguished	To suspect malignancy, especially in cases of vitritis of unclear origin	

**Abbreviations:** MEWDS, multiple evanescent white-dot syndromes; APMPPE, acute posterior multifocal placoid pigment epitheliopathy; ERG, electroretinogram; PERG, pattern-electroretinogram; VA, visual acuity; RPE, retinal pigment epithelium; CNS, central nervous system; BCR, birdshot chorioretinopathy; EOG, electrooculography; VEP, visual evoked potentials; FHC, Fuchs heterochromic cyclitis; AMN, acute macular neuroretinopathy; WDS, white dot syndromes; SO, sympathetic ophthalmia; TB, tuberculosis; MCP, multifocal choroiditis and panuveitis; DUSN, diffuse unilateral subacute neuroretinitis; PLOL, primary intraocular lymphoma; OHS, ocular histoplasmosis syndrome; CSCR, central serous chorioretinopathy; PSII, posterior segment intraocular inflammation; IOL, intraocular lymphoma; CAR, cancer associated retinopathy; AMNR, acute macular neuroretinopathy; PIC, punctate inner chorioidopathy.



**Figure 3** Fundus photograph in a 56-year-old woman with birdshot chorioretinopathy (A) before and (B) after treatment.  
**Note:** Left images correspond to the left eye and right images correspond to the right eye.

almost all cases within normal ranges, and these findings are in accordance with the aforementioned hypothesis.

The efficacy of interferon (IFN)- $\alpha$ 2a in ABD patients with posterior uveitis/panuveitis with macular edema was tested by Stübiger et al<sup>78</sup> by means of mfERG. The results demonstrated that improvement of amplitudes and normalization of implicit time occurred only in patients without chronic disease with secondary retinal changes. Furthermore, in chronic or recurrent uveitis with secondary retinal changes, mfERG remained abnormal, although treatment with IFN- $\alpha$ 2a resulted in good VA and in disappearance of significant retinal changes on ophthalmoscopic examination.<sup>79</sup> These results suggest that mfERG reflects the extent of damage to the central retina due to ABD in patients with good VA and ophthalmoscopic examination, and that it can be used as an objective follow-up of macular dysfunction in recurrent uveitis.

## Ocular syphilis

Ocular manifestations in syphilis are numerous and polymorphous, can affect both the anterior and the posterior segment of the eye, and may occur during the secondary or tertiary stages of the disease.<sup>80–82</sup> Posterior-segment involvement (especially chorioretinitis) and panuveitis are the most common presentations of syphilitic uveitis.<sup>83</sup> Syphilis remains the first great imitator with regard to inflammatory ocular diseases considered as a differential diagnosis in any uveitis of unclear origin.

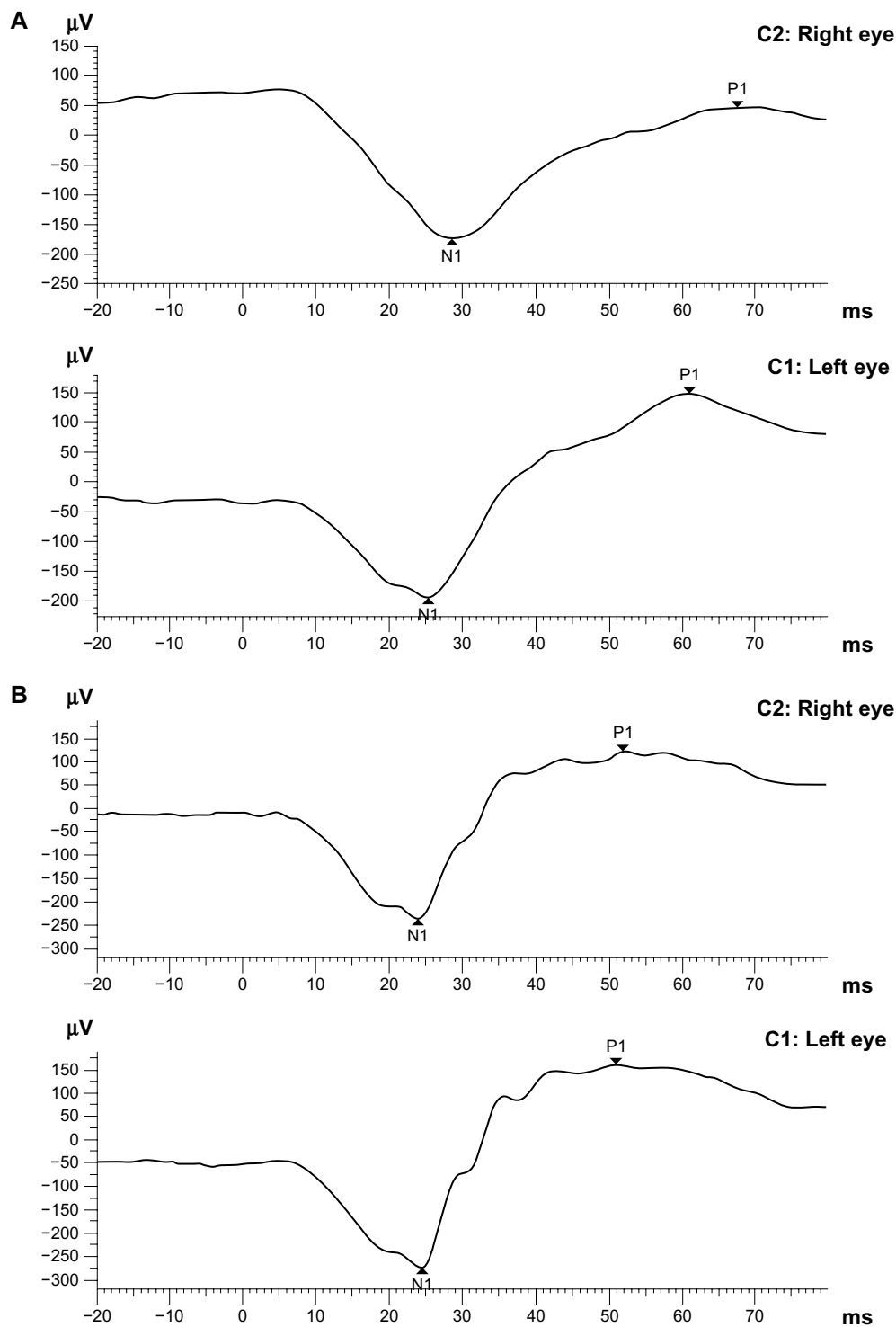
Early diagnosis and initiation of treatment are fundamental for the best restoration of VA and ocular function, and electrophysiological findings help in the diagnosis and monitoring of syphilitic uveitis. Several studies and reports have examined

the findings of electrophysiological examination in patients with syphilitic uveitis.<sup>84–86</sup> All of them demonstrated marked dysfunction of the outer retinal layers at diagnosis and before initiation of treatment, since mfERGs were either almost extinguished<sup>84–86</sup> or highly abnormal (reduced and delayed).<sup>86</sup> Moreover, electrophysiological examination by means of mfERG was also performed on patients during and after treatment.<sup>84–86</sup> In all these studies, initiation of treatment was accompanied by a rapid improvement of VA, but mfERG values recovered much more slowly, taking up to 6–9 months after VA restoration<sup>86</sup> in order to return in normal limits. Alexander et al<sup>86</sup> also described VEP changes along with mfERG, and found that they were significantly reduced and their changes showed evidence of optic nerve involvement in six of the eight examined eyes. The same study described the correlation of electrophysiological examination not only with VA but also with clinical findings in syphilitic posterior uveitis. It was demonstrated that recovery of the outer retina (mfERG) and the optic nerve (VEPs) also lagged behind the resolution of the clinical findings. These findings suggest that mfERG and VEPs allow objective monitoring of the recovery of the outer retina and optic nerve during therapy for syphilitic posterior uveitis. Complete recovery of Ganzfeld ERGs (ERG and mERG) after intravenous penicillin therapy also emphasizes the need for prompt diagnosis and treatment in cases of acute syphilitic posterior placoid chorioretinitis,<sup>84</sup> a particular type of syphilitic uveitis with acute and severe visual impairment.

## Fuchs heterochromic cyclitis

Fuchs heterochromic cyclitis (FHC) represents 3% of all cases of uveitis, mainly in anterior uveitis, while the involvement of the posterior segment is unusual, although there are cases reported with retinal involvement and chorioretinal scars. Electrophysiological examination is needed in patients with FHC in order to assess retinal involvement. Martenet and Niemeier<sup>87</sup> tested Ganzfeld ERG in patients with FHC, and the findings of the examination were normal or slightly altered, suggesting little or no retinal involvement in FHC.

Electrophysiological examination by means of flash ERG and PERG was undertaken by Murray et al<sup>88</sup> in patients with FHC, in order to test the extent of retinal involvement. They found significant reduction in amplitude and significant delay in the latency of PERG, and as for flash ERG, they found a significant selective reduction in the scotopic b-wave amplitude, significantly reduced amplitude of oscillatory potentials, and abnormal 30 Hz ERG amplitudes. On the other hand, flash ERG results showed no significant differences in a-wave amplitude, in latency of scotopic b-wave, or in mean



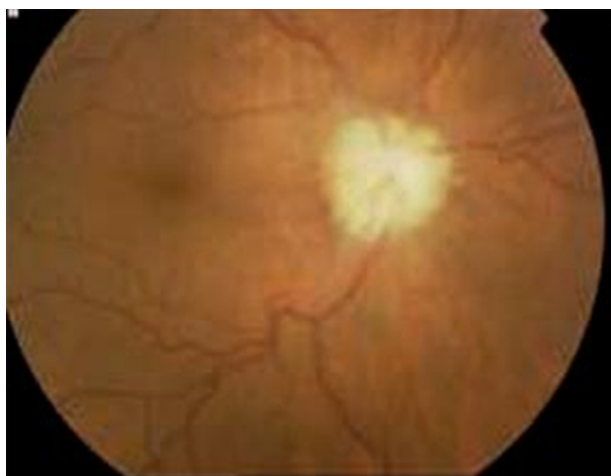**Figure 4 (A)** Electroretinogram recordings before treatment. **(B)** Electroretinogram recordings after treatment. b-Wave amplitude is increased. **Abbreviation:** ms, millisecond.

latency of 30 Hz ERG. These findings suggest that FHC is associated with subclinical retinal damage, especially in the macular area, as it is indicated by PERG abnormalities. Moreover the selective reduction of scotopic b waves and the reduced oscillatory potentials suggest that the inner retinal layers are affected, involving the bipolar and Müller cell

layers. Finally, the photoreceptors seem not to be affected, since the a wave of scotopic ERG was normal.

### *Toxoplasma* retinochoroiditis

*Toxoplasma gondii* may cause retinochoroiditis, and treatment strategy depends on the position of active lesions in the



**Figure 5** Fundus photograph of the right eye of a patient with Adamantiades–Behçet disease, showing optic nerve involvement.

retina and the presence of vitreous activity. ERG is a useful tool in order to locate the lesions (either active or inactive) in eyes with dense vitreous clouding. Riemsdag et al<sup>89</sup> proved this hypothesis by performing standard flash ERG in patients with inactive *Toxoplasma* retinochoroiditis lesions, and photopic ERG or scotopic ERG were found to decrease with regard to location (macular region or extramacular region involved, respectively). In active *Toxoplasma* retinochoroiditis in experimental animals, ERG is abnormal and there is a close relationship between the degree of inflammation

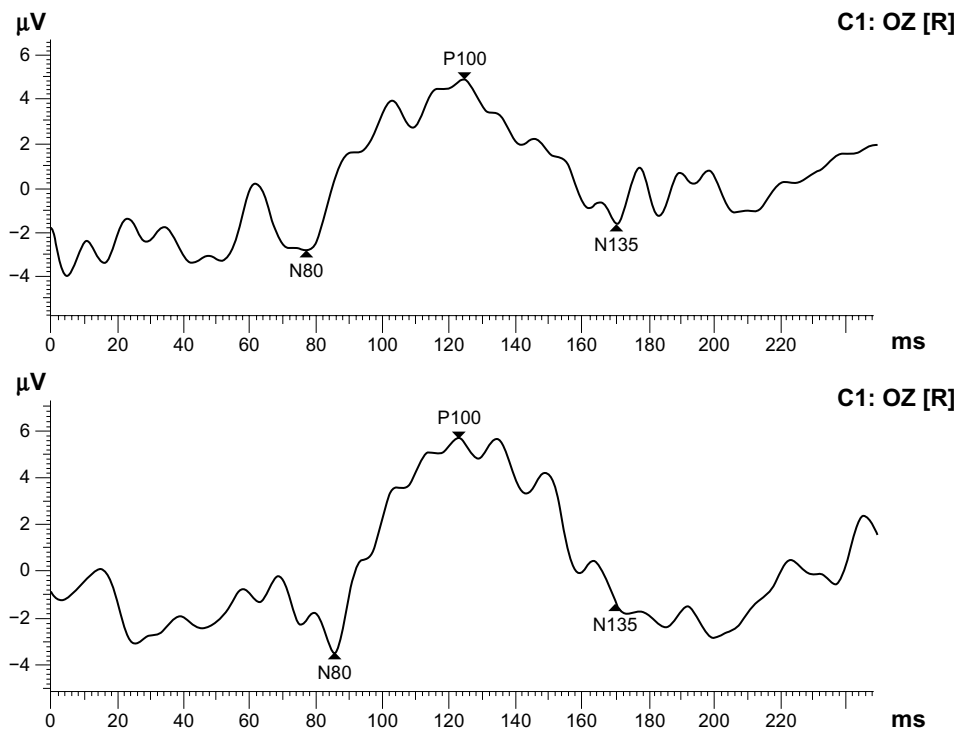
and the depression of ERGs.<sup>90</sup> In addition, Riemsdag et al<sup>89</sup> observed some cases with remarkable visual field defects more severe than those expected with regard to lesion size and location; VEP abnormalities (P100 latency delayed) reflected optic nerve affection.

### Crohn’s disease

It is well known that Crohn’s disease is associated with ocular affliction, mainly anterior uveitis, while posterior uveitis is unusual. Tappeiner et al<sup>91</sup> reported such a case with a 37-year-old patient with Crohn’s disease and chorioretinal manifestations, in whom mfERG was performed before and after 3 months’ use of oral prednisolone. Initially, a/b amplitudes were reduced, and 3 months later, although the initial visual field defects disappeared and the inflammatory lesions had resolved, they still remained mildly reduced.

### Intermediate uveitis

ERG examination is required to be performed in cases of intermediate uveitis in order to determine the involvement of the retina. Cantrill et al<sup>92</sup> studied the changes of ERG in patients with chronic pars planitis and good vision. The results consisted of delayed b-wave implicit time, abnormal response to 30 Hz flicker, and reduced b-wave oscillatory potentials. These results indicated that retinal manifestations were present and that retinal vasculitis may coexist.



**Figure 6** Visual evoked potential recording shows increased latency of P100 to 124.9 milliseconds.  
**Abbreviations:** ms, millisecond; R, right eye; OZ, mid-occipital electrode is placed on the midline.

## Sympathetic ophthalmia

There is a paucity of literature on electrophysiology in sympathetic ophthalmia. ERG amplitudes have been reported abnormally reduced in the sympathizing eye, beginning early in the course of the disease. Photopic and scotopic b waves were classified as abnormal, with peak latency of scotopic b waves reported delayed.<sup>93</sup>

## Sarcoidosis

Sarcoidosis is the second “great mimicker” after syphilis with regard to intraocular inflammation. There is evidence that in uveitis associated with sarcoidosis, a significant proportion of patients have signs of retinal dysfunction, since flash and pattern ERG abnormalities have been documented. In addition, a fair proportion of those patients revealed VEP abnormalities, suggesting that an optic neuropathy in this group of patients is more common than that identified clinically,<sup>94</sup> a sign probably consistent with subclinical central nervous system involvement.

## Acute retinal pigment epithelitis

Acute retinal pigment epithelitis is a distinct clinical entity characterized by acute inflammation of the RPE, first described by Krill and Deutman.<sup>95</sup> Ophthalmoscopically discrete clusters of small, dark-gray spots are seen at the macular area, and each of these spots is surrounded by a yellow, halo-like zone, spontaneously resolved within weeks to months. EOG is subnormal, reflecting the dysfunction of RPE, while ERG and VEP are normal.<sup>96</sup> The main entities one should include in differential diagnosis are APMPE and acute macular neuroretinopathy (Table 1).

## Acute macular neuroretinopathy

Acute macular neuroretinopathy is a rare disease, considered as a specific type of posterior uveitis, and is seen in young adults (mostly women), and may be either unilateral or bilateral, with characteristic dark red or brownish lesions in the perifoveal area, first described by Bos and Deutman.<sup>97</sup> There is an association of acute macular neuroretinopathy with MEWDS, since both entities are observed in some patients at different times in their clinical course. ERG is usually but not always normal.<sup>98,99</sup>

## Masquerade syndromes simulating uveitis

In patients with intraocular lymphoma, reduced amplitudes of all ERG components can be recorded, with b-wave amplitude being most significantly affected. Of course, differential diagnosis is not based on electrophysiological examination,

oriented mainly by other methods, ie, intraocular fluids flow cytometry, but ERG abnormalities could be useful as early indicators of ocular disease.<sup>98</sup>

Some additional entities of uveitis and uveitis-masquerade syndromes are associated with abnormalities of visual electrophysiological examination, while in others abnormal findings concerning electrophysiology are unusual (Table 1).

## Ocular complications of human immunodeficiency virus

Ocular involvement is common in patients infected with human immunodeficiency virus (HIV), and includes retinal microangiopathy, opportunistic ocular infections (primarily CMV retinitis), conjunctival, lid, and orbital involvement by Kaposi's sarcoma, and lymphoma and neuro-ophthalmic lesions.<sup>100</sup> Studies in HIV-positive adults without CMV retinitis have demonstrated that there is up to 50% loss in nerve-fiber population, notwithstanding the fact that the optic nerve appears clinically normal.<sup>101</sup> It was hypothesized that the loss of optic nerve fibers is secondary, due to inner retinal damage caused by HIV. Another recent study by Moschos et al<sup>44</sup> suggested that there is some subclinical dysfunction of the photoreceptors and the inner retinal layers of the fovea in HIV-positive children with normal vision and without ocular disease.

## Conclusion

In conclusion, although the electrophysiological examination is not a routine examination in uveitic patients, various electrophysiological tests are helpful in the assessment of many forms of uveitis, mainly in posterior uveitis (Table 1). Electrophysiological tests serve usually as an extension of the ophthalmologic examination rather than as a diagnostic examination. ERG is the test that is performed most often in uveitic patients, and is primarily used in the detection of early retinal lesions and their location, in the monitoring of disease activity and expansion, and in the efficacy of treatment, especially in the era of intravitreal therapies. mfERG is also used for the early recognition of macular lesions due to uveitis, and for the effectiveness of treatment. VEPs are less frequently used, mainly for the recognition of subclinical involvement of the optic nerve. EOG is not frequently used in cases of uveitis, and its main use is for the detection of RPE dysfunction.

However, when involvement of the retina is present in severe uveitis, electrophysiological examinations and especially the ERG (including mfERG) have particular importance even for differential diagnosis, though rarely, (ie, in cases of

difficult discrimination with regard to differential diagnosis between sarcoidosis and BCR and VKH and APMPE). On the other hand, in the near future, interpretation of electrophysiological examination results along with findings of imaging methods (fundus autofluorescence, fluorescein angiography, indocyanine green angiography, and spectral domain optical coherence tomography) will contribute to a better understanding of pathophysiology of various types of uveitis and the ongoing use of electrophysiology in ophthalmic research.<sup>102</sup>

## Disclosure

The authors report no conflicts of interest in this work.

## References

- Rothova A, Buitnhuis HJ, Meenken C, et al. Uveitis and systemic disease. *Br J Ophthalmol*. 1992;76:137–141.
- Bloch-Michel Ea, Nussenblatt RB. International uveitis study group recommendations for the evaluation of intraocular inflammatory disease. *Am J Ophthalmol*. 1987;103:234–235.
- Wakefield D, Chang JH. Epidemiology of uveitis. *Int Ophthalmol Clin*. 2005;45:1–13.
- Barisani-Asenbauer T, Maca SM, Mejoubi L, Machold K, Auer H. Uveitis – a rare disease often associated with systemic diseases and infections – a systematic review of 2619 patients. *Orphanet J Rare Dis*. 2012;7:57.
- Bodaghi B, Cassoux N, Wechsler B, et al. Chronic severe uveitis: etiology and visual outcome in 927 patients from a single center. *Medicine Baltimore*. 2001;80:262–270.
- De Smet MD, Taylor SR, Bodaghi B, et al. Understanding uveitis: the impact of research on visual outcomes. *Prog Retin Eye Res*. 2011;30:452–470.
- Nussenblatt RB. The natural history of uveitis. *Int Ophthalmol*. 1990;14:303–308.
- Smith RE, Godfrey WA, Kimura SJ. Complications of chronic cyclitis. *Am J Ophthalmol*. 1976;82:277–282.
- Brown KT. The electroretinogram: its components and their origins. *Vision Res*. 1968;8:633–677.
- Hidajat R, Goode D. The clinical value of ophthalmic electrodiagnosis. *Australas Phys Eng Sci Med*. 2001;24:172–176.
- Rosolen SG, Kolomiets B, Varela O, Picaud S. Retinal electrophysiology for toxicology studies: applications and limits of ERG in animals and ex vivo recordings. *Exp Toxicol Pathol*. 2008;60:17–32.
- Favilla I, Barry WR. Ocular electrophysiology: principles and clinical applications. *Aust J Ophthalmol*. 1981;9:163–167.
- Armington J, Johnson E, Riggs L. The scotopic A-wave in the electrical response of the human retina. *J Physiol*. 1952;118:289–298.
- Wachtmeister L. Oscillatory potentials in the retina: what do they reveal? *Prog Retin Eye Res*. 1998;17:485–521.
- Perlman I. Relationship between the amplitudes of the b-wave and the a-wave as a useful index for evaluating the electroretinogram. *Br J Ophthalmol*. 1983;67:443–448.
- Tomita T, Yanagida T. Origins of the ERG waves. *Vision Res*. 1981;21:1703–1707.
- Camuglia JE, Gree RM, Welch L, Gole GA. Use of the electroretinogram in a paediatric hospital. *Clin Experiment Ophthalmol*. 2011;39:506–512.
- Karpe G, Rendahl I. Clinical electroretinography in detachment of the retina. *Acta Ophthalmol Scand*. 1969;47:633–641.
- Matsumoto C, Shinoda K, Yamada K, Nakatsuka K. Photopic negative response reflects severity of ocular circularity damage after central retinal artery occlusion. *Ophthalmologica*. 2009;223:362–369.
- Young B, Eggenberger E, Kaufman D. Current electrophysiology in ophthalmology: a review. *Curr Opin Ophthalmol*. 2012;23:497–505.
- Weinstein JM, Kelman SE, Bresnick GH, Kornuth SE. Paraneoplastic retinopathy associated with antiretinal bipolar cell antibodies in cutaneous malignant melanoma. *Ophthalmology*. 1994;101:1236–1243.
- Scholl HP, Zrenner E. Electrophysiology in the investigation of acquired retinal disorders. *Surv Ophthalmol*. 2000;45:29–47.
- Cobb WA, Morton HB. A new component of the human electroretinogram. *J Physiol*. 1953;123:36–37.
- Hancock HA, Kraft TW. Oscillatory potential analysis and ERGs of normal and diabetic rats. *Invest Ophthalmol Vis Sci*. 2004;45:1002–1008.
- Juen S, Kieselbach GF. Electrophysiological changes in juvenile diabetics without retinopathy. *Arch Ophthalmol*. 1990;108:372–375.
- Yoshida A, Kojima N, Ogasawara H, Ishiko S. Oscillatory potentials and permeability of the blood-retinal barrier in noninsulin-dependent diabetic patients without retinopathy. *Ophthalmology*. 1991;98:1266–1271.
- Vadala M, Anastasi M, Lodato G, Cillino S. Electroretinographic oscillatory potentials in insulin-dependent diabetes patients: a long-term follow-up. *Acta Ophthalmol Scand*. 2002;80:305–309.
- Bresnick GH, Palta M. Oscillatory potential amplitudes. *Arch Ophthalmol*. 1987;105:929–933.
- Bresnick GH, Palta M. Predicting progression to severe proliferative diabetic retinopathy. *Arch Ophthalmol*. 1987;105:810–814.
- Holopigian K, Greenstein VC, Seiple W, Hood DC, Ritch R. Electrophysiologic assessment of photoreceptor function in patients with primary open-angle glaucoma. *J Glaucoma*. 2000;9:163–168.
- Hara A, Miura M. Decreased inner retinal activity in branch retinal vein occlusion. *Doc Ophthalmol*. 1994;88:39–47.
- Derr PH, Meyer AU, Haupt EJ, Brigell MG. Extraction and modeling of the oscillatory potential: signal conditioning to obtain minimally corrupted oscillatory potentials. *Doc Ophthalmol*. 2002;104:37–55.
- Tremblay F, Laroche RG, De Becker I. The electroretinographic diagnosis of the incomplete form of congenital stationary night blindness. *Vision Res*. 1995;35:2383–2393.
- Holder GE. Pattern electroretinography PERG and an integrated approach to visual pathway diagnosis. *Prog Retin Eye Res*. 2001;20:531–561.
- Hokazono K, Oyamada MK, Monteiro ML. Pattern-reversal electroretinograms for the diagnosis and management of disorders of the anterior visual pathway. *Arq Bras Oftalmol*. 2011;74:222–226.
- Renner AB, Kellner U, Tillack H, Kraus H, Foerster MH. Recording of both VEP and multifocal ERG for evaluation of unexplained visual loss. *Doc Ophthalmol*. 2005;111:149–157.
- Daniel P, Whittridge D. The representation of the visual field on the cerebral cortex in monkeys. *J Physiol*. 1961;159:203–221.
- Gundogan FC, Demirkaya S, Sobaci G. Is optical coherence tomography really a new biomarker candidate in multiple sclerosis? A structural and functional evaluation. *Invest Ophthalmol Vis Sci*. 2007;48:5773–5781.
- Marmor MF, Brigell MG, McCulloch DL, Westall CA, Bach M. ISCEV standard for clinical electro-oculography 2010 update. *Doc Ophthalmol*. 2011;122:1–7.
- Sutter EE, Tran D. The field topography of ERG components on man – I. The photopic luminance response. *Vision Res*. 1992;32:433–446.
- Georgiadou E, Moschos MM, Margetis J, Chalkiadakis J, Markomichelakis NN. Structural and functional outcomes after treatment of uveitic macular oedema: an optical coherence tomography and multifocal electroretinogram study. *Clin Exp Optom*. 2012;95:89–93.
- Kondo M, Miyake Y, Horiguchi M, Suzuki S, Tanikawa A. Clinical evaluation of multifocal electroretinogram. *Invest Ophthalmol Vis Sci*. 1995;36:2146–2150.
- Hood DC, Bach M, Brigell M, et al. ISCEV standard for clinical multifocal electroretinography mfERG 2011 edition. *Doc Ophthalmol*. 2012;124:1–13.
- Moschos MM, Margetis I, Markopoulos I, Moschos MN. Optical coherence tomography and multifocal electroretinogram study in human immunodeficiency virus-positive children without infectious retinitis. *Clin Exp Optom*. 2011;94:291–295.

45. Kretschmann U, Bock M, Gockeln R, Zrenner E. Clinical applications of multifocal electroretinography. *Doc Ophthalmol.* 2000;100:99–113.
46. Gränse L, Ponjavic V, Andreason S. Full-field ERG, multifocal ERG and multifocal VEP in patients with retinitis pigmentosa and residual central visual fields. *Acta Ophthalmol Scand.* 2004;82:701–706.
47. Si YJ, Kishi S, Aoyagi K. Assessment of macular function by multifocal electroretinogram before and after macular hole surgery. *Br J Ophthalmol.* 1999;83:420–424.
48. Klistorner A, Arvind H, Garrick R, Graham SL, Paine M, Yiannikas C. Interrelationship of optical coherence tomography and multifocal visual-evoked potentials after optic neuritis. *Invest Ophthalmol Vis Sci.* 2010;51:2770–2777.
49. Klistorner A, Fraser C, Garrick R, Graham S, Arvind H. Correlation between full-field and multifocal VEPs in optic neuritis. *Doc Ophthalmol.* 2008;116:19–27.
50. Betsuin Y, Mashima Y, Ohde H, Inoue R, Oguchi Y. Clinical application of the multifocal VEPs. *Curr Eye Res.* 2001;22:54–63.
51. Jayaraman M, Ambika S, Gandhi R, Bassi SR, Ravi P, Sen P. Multifocal visual evoked potential recordings in compressive optic neuropathy secondary to pituitary adenoma. *Doc Ophthalmol.* 2010;121:197–204.
52. Hood D, Greenstein V. Multifocal VEP and ganglion cell damage: applications and limitations for the study of glaucoma. *Prog Retin Eye Res.* 2003;22:201–251.
53. Hood DC, Zhang X, Greenstein VC, et al. An interocular comparison of the multifocal VEP: a possible technique for detecting local damage to the optic nerve. *Invest Ophthalmol Vis Sci.* 2000;41:1580–1587.
54. Klistorner AI, Graham SL. Objective perimetry in glaucoma. *Ophthalmology.* 2000;107:2283–2299.
55. Hood DC, Odel JG, Zhang X. Tracking the recovery of local optic nerve function after optic neuritis: a multifocal VEP study. *Invest Ophthalmol Vis Sci.* 2000;41:4032–4038.
56. Huang HJ, Yamazaki H, Kabawata H, Ninomiya T, Adachi-Usami E. Multifocal electroretinogram in multiple evanescent white dot syndrome. *Doc Ophthalmol.* 1997;92:301–309.
57. Chen D, Martidis A, Baurnal CR. Transient multifocal electroretinogram dysfunction in multiple evanescent white dot syndrome. *Ophthalmic Surg Lasers.* 2002;33:246–249.
58. Horiguchi M, Miyake Y, Nakamura M, Fujii Y. Focal electroretinogram and visual field defect in multiple evanescent white dot syndrome. *Br J Ophthalmol.* 1993;77:452–455.
59. Li D, Kishi S. Restored photoreceptor outer segment damage in multiple evanescent white dot syndrome. *Ophthalmology.* 2009;116:762–770.
60. Nguyen MH, Witkin AJ, Reichel E, et al. Microstructural abnormalities in MEWDS demonstrated by ultrahigh resolution optical coherence tomography. *Retina.* 2007;27:414–418.
61. Cheng JY, Luu CD, Yeo IY, Chee SP. The outer and inner retinal function in patients with multiple evanescent white dot syndrome. *Clin Experiment Ophthalmol.* 2009;37:478–484.
62. Sieving P, Fishman G, Jampol LM, Pugh D. Multiple evanescent white-dot syndrome. II. Electrophysiology of the photoreceptors during retinal pigment epithelial disease. *Arch Ophthalmol.* 1984;102:675–679.
63. Feigl B, Haas A, El-Shabrawi Y. Multifocal ERG in multiple evanescent white dot syndrome. *Graefes Arch Clin Exp Ophthalmol.* 2002;240:615–621.
64. Takeda N, Numata K, Yamamoto S, Katayama T, Kubota Y. Electrophysiologic findings in optic nerve dysfunction associated with multiple evanescent white dot syndrome. *Doc Ophthalmol.* 1992;79:295–302.
65. Deutman AF, Oosterhuis JA, Boen-Tan TN, Aan de Kerk AL. Acute posterior multifocal placoid pigment epitheliopathy. Pigment epitheliopathy of choriocapillaritis? *Br J Ophthalmol.* 1972;56:863–874.
66. Gasch AT, Smoth JA, Whitcup SM. Birdshot retinochoroidopathy. *Br J Ophthalmol.* 1999;83:241–249.
67. LeHoang P, Ozdemir N, Benhamou A, et al. HLA-A29.2 subtype associated with birdshot retinochoroidopathy. *Am J Ophthalmol.* 1992;113:33–35.
68. Hirose T, Katsumi O, Pruett RC, Sakaue H, Mehta M. Retinal function in birdshot retinochoroidopathy. *Acta Ophthalmol Copenh.* 1991;69:327–337.
69. Sobrin L, Lam BL, Liu M, Feuer WJ, Davis JL. Electroretinographic monitoring in birdshot chorioretinopathy. *Am J Ophthalmol.* 2005;140:52–64.
70. Zacks DN, Samson CM, Loewenstein J, Foster CS. Electroretinograms as an indicator of disease activity in birdshot retinochoroidopathy. *Graefes Arch Clin Exp Ophthalmol.* 2002;240:601–607.
71. Chee SP, Luu CD, Cheng CL, Lim WK, Jap A. Visual function in Vogt-Koyanagi-Harada patients. *Graefes Arch Clin Exp Ophthalmol.* 2005;243:785–790.
72. Yang P, Fang W, Wang L, Wen F, Wu W, Kijlstra A. Study of macular function by multifocal electroretinography in patients with Vogt-Koyanagi-Harada syndrome. *Am J Ophthalmol.* 2008;146:767–771.
73. Jacobson JH, Popkin A, Hirose T. The electroretinogram in Harada's disease. *Am J Ophthalmol.* 1967;64:1152–1154.
74. Nagaya T. Use of the electro-oculogram for diagnosing and following the development of Harada's disease. *Am J Ophthalmol.* 1972;74:99–109.
75. Ozdal PC, Ortac S, Taskintuna I, Firat E. Posterior segment involvement in ocular Behcet's disease. *Eur J Ophthalmol.* 2002;12:424–431.
76. Anlar O, Akdeniz N, Tombul T, Calka O, Bilgili SG. Visual evoked potential findings in Behcet's disease without neurological manifestations. *Int J Neurosci.* 2006;116:281–287.
77. Asai H, Wakabayashi K, Segawa Y, Kawasaki K. Electro-ophthalmological analysis of Behcet's disease. *Nihon Ganka Gakkai Zasshi.* 1989;93:1038–1043.
78. Stübiger N, Besch D, Deuter CM, Zierhut M, Kötter I. Multifocal ERG changes in patients with ocular Behcet's disease during therapy with interferon alpha 2a. *Adv Exp Med Biol.* 2003;528:529–532.
79. Kötter I, Zierhut M, Eckstein AK, et al. Human recombinant interferon alfa-2a for the treatment of Behcet's disease with sight threatening posterior or panuveitis. *Br J Ophthalmol.* 2003;87:423–431.
80. Aldave AJ, King JA, Cunningham ET Jr. Ocular syphilis. *Curr Opin Ophthalmol.* 2001;12:433–441.
81. Kiss S, Damico FM, Young LH. Ocular manifestations and treatment of syphilis. *Semin Ophthalmol.* 2005;20:161–167.
82. Gaudio PA. Update on ocular syphilis. *Curr Opin Ophthalmol.* 2006;17:562–566.
83. Villanueva AV, Sahouri MJ, Ormerod LD, Puklin JE, Reyes MP. Posterior uveitis in patients with positive serology for syphilis. *Clin Infect Dis.* 2000;30:479–485.
84. Menon SR, Fleischhauer J, Jost K, Helbig H. Clinical and electrophysiological course of acute syphilitic posterior placoid chorioretinitis. *Klin Monbl Augenheilkd.* 2005;222:261–263.
85. Joseph A, Rogers S, Browning A, et al. Syphilitic acute posterior placoid chorioretinitis in nonimmuno-compromised patients. *EyeLond.* 2007;21:1114–1119.
86. Alexander P, Wen Y, Baxter JM, Tint NL, Browning AC, Amoaku WM. Visual evoked potential VEP and multifocal electroretinogram mfERG in ocular syphilitic posterior segment inflammation. *Doc Ophthalmol.* 2012;125:169–178.
87. Martenet AC, Niemyer G. [The value of electroretinography in uveitis]. *Ophthalmologie.* 1990;4:169–172. French.
88. Murray DC, Stavrou P, Good PA, Murray PI. Electroretinographic findings in Fuchs' heterochromic cyclitis. *EyeLond.* 1997;11:102–108.
89. Riemsdag FC, Brinkman CJ, Verduyn Lunel HF, Spekrijse H, Kijlstra A. Analysis of the electroretinogram in *Toxoplasma* retinochoroiditis. *Doc Ophthalmol.* 1992;82:57–63.
90. Norose K, Aosai F, Mizota A, Yamamoto S, Mun HS, Yano A. Deterioration of visual function as examined by electroretinograms in *Toxoplasma gondii*-infected IFN- $\gamma$ -knockout mice. *Invest Ophthalmol Vis Sci.* 2005;46:317–321.
91. Tappeiner C, Dohrmann J, Spital G, Heiligenhaus A. Multifocal posterior uveitis in Crohn's disease. *Graefes Arch Clin Exp Ophthalmol.* 2007;245:457–459.

92. Cantrill HL, Ramsay RC, Knobloch WH, Purple RL. Electrophysiologic changes in chronic pars planitis. *Am J Ophthalmol.* 1981;91: 505–512.
93. Georgiades G, Argalias A, Batsolas B, Stangos N, Zissiadis C, Papoulis A. Remarks on sympathetic ophthalmia. *Ophthalmologica.* 1969;158: 543–560.
94. Stavrou P, Sivaraj R, Allie M, Good PA. Electrophysiological, Heidelberg's retinal tomographyHRT2 and echographic assessment of patients with uveitis associated with sarcoidosis. *Invest Ophthalmol Vis Sci.* 2004;45:2704.
95. Krill AE, Deutman AF. Acute retinal pigment epithelitis. *Am J Ophthalmol.* 1972;74:193–205.
96. Deutman AF. Acute retinal pigment epithelitis. *Am J Ophthalmol.* 1974;78:571–578.
97. Bos PJ, Deutman AF. Acute macular neuroretinopathy. *Am J Ophthalmol.* 1975;80:573–584.
98. Turbeville SD, Cowan LD, Goss JD. Acute macular neuroretinopathy. *Surv Ophthalmol.* 2003;48:1–11.
99. Corver HD, Ruys J, Kestelyn-Stevens AM, De Laey JJ, Leroy BP. Two cases of acute macular neuroretinopathy. *EyeLond.* 2007;21: 1226–1229.
100. Holland GN. AIDS and ophthalmology: the first quarter century. *Am J Ophthalmol.* 2008;146:397–408.
101. Falkenstein I, Kozak I, Kayikcioglu O, et al. Assessment of retinal function in patients without infectious retinitis by multifocal electroretinogram and automated perimetry. *Retina.* 2006;26: 928–934.
102. Ng JS. The time is now for visual electrophysiology [editorial]. *Int J Ophthalmic Pathol.* 2012;1:1.

## Clinical Ophthalmology

### Publish your work in this journal

Clinical Ophthalmology is an international, peer-reviewed journal covering all subspecialties within ophthalmology. Key topics include: Optometry; Visual science; Pharmacology and drug therapy in eye diseases; Basic Sciences; Primary and Secondary eye care; Patient Safety and Quality of Care Improvements. This journal is indexed on

Submit your manuscript here: <http://www.dovepress.com/clinical-ophthalmology-journal>

Dovepress

PubMed Central and CAS, and is the official journal of The Society of Clinical Ophthalmology (SCO). The manuscript management system is completely online and includes a very quick and fair peer-review system, which is all easy to use. Visit <http://www.dovepress.com/testimonials.php> to read real quotes from published authors.