

Traumatic pseudo-lipoma in 3-year-old child

NILESH V. RATHI, PRASANNA T. DAHAK¹, KAUSTUBH THAKRE², SACHIN S. PAWADE³

Abstract

The buccal fat pad is relatively large and prominent in neonates, infants and young children. The main function of this fat pad is considered as a cushioning tissue and sucking pad. A minor tear of buccal mucosa and buccinator muscle can result in herniation of large volume of fat into oral cavity that is termed as “pseudolipoma.” The young children tend to be very playful while brushing their teeth. Improper brushing technique resulted in severe trauma to the buccal fat, including soft-tissue between buccinator and retromolar area. This article presents a case-report of a female child who developed traumatic pseudolipoma after faulty tooth brushing for long duration and its management along with its detail review of literature.

Keywords: Buccal fat pad, trauma, traumatic pseudolipoma

Introduction

The buccal fat pad also called as Buccal fat pad of Bichat or suctorial pad is relatively large and prominent in neonates, infants and young children. It has great relevance to this area^[1] giving fullness to face, aids in cushioning and sucking in neonates and children.^[2]

It serves to line the masticatory space, separating the muscles of mastication from the zygomatic arch, ramus of the mandible and other muscles.^[3] The buccal fat pad consists of a central body and four extensions: Buccal, pterygoid, superficial and deep temporal. The buccal extension is encapsulated by a parotidomasseteric fascia and enters the cheek below the parotid duct. A minor tear of the buccinators muscle can allow herniation into the oral cavity. The term “traumatic pseudolipoma” was proposed by Brooke and

MacGregor in their case report involving adipose tissue in a swelling of the buccal mucosa distinguishing it from other benign fatty tumors of the oral cavity.^[4]

Two etiologic factors and pathogenetic links between soft-tissue trauma and adipose tissues growth had been discussed in the literature. The first possibility is the herniation of the buccal fat pad with subsequent epithelialization, termed “traumatic pseudolipoma.” This usually results from direct impact, has a relatively short natural history of presentation and commonly occurs in young children.^[5] The second possibility suggests lipoma formation is due to deposition and differentiation of adipocytes, mediated by cytokine release, secondary to trauma and hematoma formation. These lesions are termed “post-traumatic lipomas.” The average time between soft-tissue trauma and lipoma formation is almost 3 years and occurs more commonly in the fourth to sixth decade.^[6] All the reported cases of traumatic pseudolipoma except one 12-year-old boy, were in infants or young children, with an age range from 5 months to 5 years.^[2] In every case, two contributory factors were proposed: The buccal fat pad is relatively prominent in infants and young children, who frequently investigate foreign objects by placing them in their mouths. Further sucking action results in fat pad being pulled out.^[7]

Case Report

A 3 year old female patient was referred from a pediatrician to the Department of Pedodontic and Preventive Dentistry with a chief complaint of extra- and intra-oral swelling and pain on the right side of face. Child's father gave history of appearance of extra-oral swelling 5 days back with pain, discomfort, drooling of saliva from mouth and inability to eat. Overlying cheek skin was normal and swelling was non-tender. The intra-oral swelling was first noticed approximately 1 month ago as a small reddish pink growth which increased gradually [Figure 1]

Departments of Pedodontics and Preventive Dentistry and

²*Periodontics, Sharad Pawar Dental College and Hospital, Sawangi (M), Wardha, 'Pedodontics and Preventive dentistry, CSMSS Dental College and Hospital, Kanchanwadi, Aurangabad,*

³*Pediatrics, Jawaharlal Nehru Medical College, Sawangi (M), Wardha, Maharashtra, India*

Correspondence: Dr. Prasanna T. Dahake, Department of Pedodontics and Preventive Dentistry, CSMSS Dental College and Hospital, Kanchanwadi, Paithan Road, Aurangabad - 431 002, Maharashtra, India.

E-mail: prasannadahake@gmail.com

Access this article online	
Quick Response Code:	Website: www.contempclindent.org
	DOI: 10.4103/0976-237X.107451

The patient reported to the department after 3 days with complain of intense pain and increased extra-oral swelling and compressed intra-oral swelling [Figure 2]. Gross clinical intra-oral examination of the lesion revealed the presence of a reddish pink, ovoid, smooth, pedunculated, non-ulcerated, freely mobile, tender swelling of approximately $3.0 \times 2.0 \times 1.5$ cm size, located between the maxillary and mandibular primary second molar regions. The lesion was found to be soft, fluctuant in consistency and freely mobile on palpation. The child was having the habit of placing toothbrush for more than 1h daily while brushing teeth. She used to bite on it while keeping it in the right buccal vestibule from last 6 months.

Differential diagnosis of the mass was given as a pyogenic granuloma, traumatic fibroma, haemangioma, infected lipoma, inflammatory pseudotumour, infected benign minor salivary gland tumor, foreign body granuloma and traumatic neuroma. The child was prescribed antibiotics, analgesic and antiseptic mouthwash for 3 days to reduce infection, inflammation, pain as well as post-operative complications while healing. The intra-oral growth was seen pale yellow in color and shrunken after 3 days. As the patient was highly uncooperative (Frankl rating I), after complete hematological investigations, Surgical excision of the mass was done under local anesthesia with soft-tissue diode laser (Doctor Smile Wiser Laser) at 2W continuous pulse. Tissue mass was excised in-toto from the base of buccal mucosa and sent for histopathological examination to the Department of Oral Pathology [Figure 3]. An attempt was made to express saliva from the parotid duct to identify the location of the parotid papilla and confirm that it is not severed or damaged [Figure 4]. Patient was recalled after 1 week and 3 months for follow-up of wound healing. Manoeuvre to express saliva from Stensen's duct was repeated to make sure that it was not damaged.

Macroscopic examination revealed one soft-tissue of a reddish pink, ovoid, firm in consistency, smooth surfaced, pedunculated, non-ulcerated mass of approximately $3.0 \times 2.0 \times 1.5$ cm size [Figure 3]. Histological examination of the tissue revealed the presence of adipose tissues with non-ulcerated overlying epithelium. The overlying epithelium is atrophic stretched parakeratinised stratified squamous epithelium. Presence of marked edema and diffuse proliferation of capillaries along with formation of granulation tissue, composed of moderately dense polymorphonuclear neutrophilic and lymphoplasmocytic infiltrate [Figure 5]. The connective tissue stroma consists of dense collagen bundles and lobules of mature adipocytes with no cellular atypia. Compressed blood vessels engorged with Red Blood Cells were also evident in the connective tissue stroma. The overall histo-pathological features were confirmatory of traumatic pseudolipoma (Traumatic herniation of buccal fat pad) [Figures 5].

Discussion

The buccal fat pad is located between buccinator and masseter muscle. Anteriorly it extends medial to the masseter muscle. It is closely associated with the muscles of mastication, the parotid duct and the facial nerve. Its importance in masticatory function is best illustrated in infants where it acts as sucking pad. It contributes to the bulging of the infant's cheeks and usually persists in adults, the body and the buccal extensions of which are largely responsible for cheek contour in adults.^[8]

Literature suggests that traumatic intra-oral herniation of the buccal fat pad is a rare phenomenon. Most of the reported cases were observed in infants and young children ranging from age of 5 months to 5 years.^[3,4] Relatively increased incidence of traumatic herniation of buccal fat pad in infants and young children is attributed to habit of investigating or frequently placing foreign objects like pencil, toothbrush, chopstick in their mouths.^[7] The most characteristic aspect of such a lesion is that the mucosal injury or perforation is very small compared to the size of the extruded mass.^[9] As to the anatomic location of this lesion, Matarasso suggested that a defect or weakness in the parotidomasseteric fascia of the region contribute to the occurrence.^[10] Sucking action of an infant might encourage the herniation of fat pad through the wound into the mouth, and may also pose the risk of respiratory embarrassment.^[7] Majority of cases documented involved a foreign object in the mouth, which subsequently caused the penetrating injury through buccal mucosa and buccinator muscle. In this case, traumatic herniation of buccal fat pad can be thought to be caused by primarily because of improper brushing technique. Gradual increase in the size of the mass can be because of prolonged placement and sucking of brush for more than 1 h daily.

The treatment of traumatic herniation of the buccal fat pad includes two surgical procedures.^[5,7] Cases in which there is early evaluation and the protruded mass is small, the tissues are able to be repositioned immediately back to its place, followed by suturing of the mucosal laceration. The approximate period between the injury and the first visit should be less than 4 h as tissues start necrotizing after this duration.^[7] If the mass is too large to be replaced in the limited laceration or infected because of prolonged exposure to oral cavity, it is recommended to excise the mass at the base with no recurrence. In this case, it was decided to excise the mass from its base under local anesthesia using diode laser in a continuous wave in a contact mode. Diode laser cuts soft-tissues and reduces bacterial counts in at the wound surface.^[11] There is evidence that this wavelength may cause a reduction in tissue inflammation and a reduced need for local anesthetic during surgical procedures. Thermal necrosis zones of less than 1 mm can be achieved, which provides adequate surgical precision and hemostasis for many soft-tissue procedures. The laser when used in a non-contact mode; coagulates soft tissues or provides hemostasis over the surgical area.^[12]

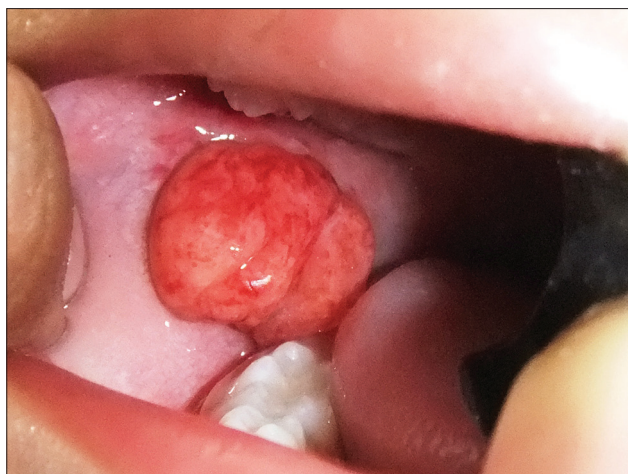

Figure 1: Intra-oral swelling noticed 1 month ago

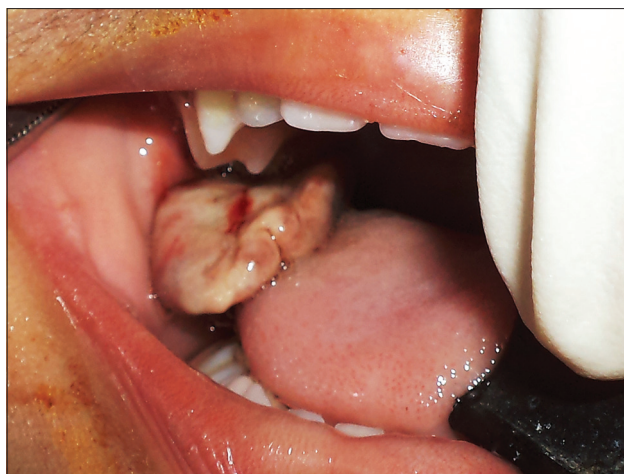

Figure 2: Compressed intra-oral swelling seen after 3 days

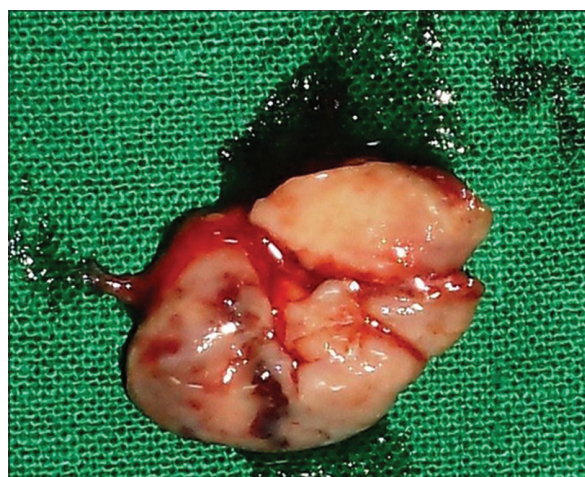


Figure 3: Excised tissue mass from buccal mucosa

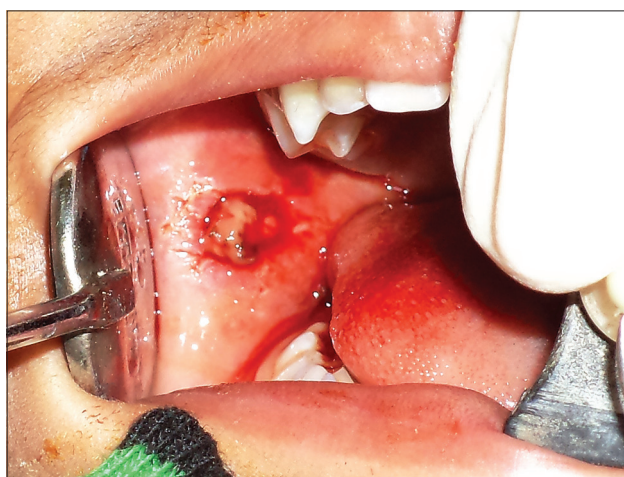

Figure 4: Buccal mucosa after excision of lesion and identification of parotid papilla

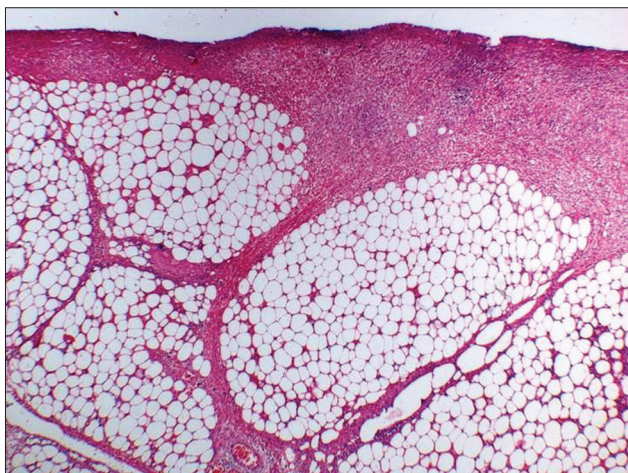


Figure 5: Histo-pathological photomicrograph of traumatic pseudolipoma (x10 view)

Conclusion

It can be concluded from above discussion that the penetrating injuries of soft tissues of oral cavity or lesions

occurring from it should be considered potentially serious. Proper evaluation of such lesions or injuries is important before coming to final diagnosis and treatment modality. While excising such a traumatic pseudolipoma and closing the wound care should be taken to avoid injury to Stensen's duct and parotid papilla.

References

1. Dubin B, Jackson IT, Halim A, Triplett WW, Ferreira M. Anatomy of the buccal fat pad and its clinical significance. *Plast Reconstr Surg* 1989;83:257-64.
2. Messenger KL, Cloyd W. Traumatic herniation of the buccal fat pad. Report of a case. *Oral Surg Oral Med Oral Pathol* 1977;43:41-3.
3. Patil R, Singh S, Subba Reddy VV. Herniation of the buccal fat pad into the oral cavity: A case report. *J Indian Soc Pedod Prev Dent* 2003;21:152-4.
4. Brooke RI, MacGregor AJ. Traumatic pseudolipoma of the buccal mucosa. *Oral Surg Oral Med Oral Pathol* 1969;28:223-5.
5. Horie N, Shimoyama T, Kaneko T, Ide F. Traumatic herniation of the buccal fat pad. *Pediatr Dent* 2001;23:249-52.
6. Aust MC, Spies M, Kall S, Jokuszies A, Gohritz A, Vogt P.

- Posttraumatic lipoma: Fact or fiction? *Skinmed* 2007;6:266-70.
7. Fleming P. Traumatic herniation of buccal fat pad: A report of two cases. *Br J Oral Maxillofac Surg* 1986;24:265-8.
 8. Takenoshita Y, Shimada M, Kubo S. Traumatic herniation of the buccal fat pad: Report of case. *ASDC J Dent Child* 1995;62:201-4.
 9. Marano PD, Smart EA, Kolodny SC. Traumatic herniation of buccal fat pad into maxillary sinus: Report of case. *J Oral Surg* 1970;28:531-2.
 10. Matarasso A. Pseudoherniation of the buccal fat pad: A new clinical syndrome. *Plast Reconstr Surg* 1997;100:723-30.
 11. Moritz A, Gutknecht N, Doertbudak O, Goharkhay K, Schoop U, Schauer P, *et al.* Bacterial reduction in periodontal pockets through irradiation with a diode laser: A pilot study. *J Clin Laser Med Surg* 1997;15:33-7.
 12. Tam G. Low power laser therapy and analgesic action. *J Clin Laser Med Surg* 1999;17:29-33.

How to cite this article: Rathi NV, Dahake PT, Thakre K, Pawade SS. Traumatic pseudo-lipoma in 3-year-old child. *Contemp Clin Dent* 2012;3:487-90.

Source of Support: Nil. **Conflict of Interest:** None declared.

Announcement



Download
**Android
application**

FREE

A free application to browse and search the journal's content is now available for Android based mobiles and devices. The application provides "Table of Contents" of the latest issues, which are stored on the device for future offline browsing. Internet connection is required to access the back issues and search facility. The application is compatible with all the versions of Android. The application can be downloaded from <https://market.android.com/details?id=comm.app.medknow>. For suggestions and comments do write back to us.