



## Multiple giant retinal tears due to inflicted injury in a neonate

Sadik Taju Sherief<sup>a</sup>, Arjan S. Dhoot<sup>b</sup>, Sarah Schwartz<sup>b,c</sup>, Cynthia VandenHoven<sup>a</sup>,  
Wai-Ching Lam<sup>a</sup>, Kamiar Mireskandari<sup>a,\*</sup>

<sup>a</sup> Department of Ophthalmology and Vision Sciences, The Hospital for Sick Children, Toronto, Canada

<sup>b</sup> Faculty of Medicine, University of Toronto, Toronto, Ontario, Canada

<sup>c</sup> Department of Paediatrics, The Hospital for Sick Children, Toronto, Ontario, Canada

### ARTICLE INFO

#### Keywords:

Giant retinal tear  
Child abuse  
Retinal detachment  
Inflicted injury  
Physical abuse  
Child mistreatment

### ABSTRACT

**Purpose:** This case represents the longest follow-up period and youngest patient treated for multiple GRTs in the same eye associated with physical abuse.

**Observations:** A 4-week-old otherwise healthy male presented with a constellation of unexplained injuries. Examination of the left eye revealed a mild lens opacity and a shallow retinal detachment with two giant retinal tears (GRTs) and no retinal hemorrhages. Examination of the right eye was unremarkable. Extensive investigations were negative for any underlying medical conditions. The constellation of injuries was felt to be due to physical abuse. The giant retinal tears were treated successfully with lens sparing pars plana vitrectomy. After long-term follow-up of 5 years, there was no cataract progression or development of glaucoma.

**Conclusions and importance:** Clinicians should suspect child abuse in any pediatric patient with GRTs, with or without retinal hemorrhages, to ensure they are connected with the appropriate children's safeguarding society as soon as possible.

### 1. Introduction

A giant retinal tear (GRT) is a full-thickness neurosensory retinal break extending circumferentially for  $\geq 90^\circ$  ( $\geq 3$  clock hours) of the retina.<sup>1</sup> The majority of GRTs are idiopathic in nature (60–80%), but traumatic injury is an important etiology accounting for 16.1% of all cases.<sup>1,2</sup> GRTs associated with traumatic retinal detachments have very poor visual outcomes, leading to permanent morbidity and reduced quality of life.<sup>3</sup> Furthermore, traumatic injuries disproportionately account for 32% of all GRTs in pediatric patients.<sup>4</sup>

We report a rare case of multiple GRTs with retinal detachment occurring in a 4-week-old male with suspected physical abuse.

### 2. Case description

A 4-week-old male with unremarkable birth history presented to the emergency department for assessment of a laceration on his right 3rd digit and left-hand swelling. He also had multiple skin abrasions over his body, swelling and bruises on his forehead and scalp, and a torn superior labial frenulum. This unusual presentation prompted further investigations including a skeletal survey which identified multiple

bilateral rib fractures, biparietal skull fractures, multiple bilateral metaphyseal fractures of the upper and lower extremities, and a pharynx fracture. Magnetic resonance imaging (MRI) of the head showed bilateral intraparenchymal frontal, parieto-occipital and right cerebellar tonsil hemorrhages and no subdural hemorrhages.

Ophthalmic examination revealed normal ocular adnexa, conjunctiva, cornea, round and reactive pupils, deep anterior chambers and mild left anterior capsular lens opacity. Dilated fundus examination of the left eye revealed shallow retinal detachment associated with two GRTs; one from 1 to 5 o'clock and the other from 7 to 11 o'clock. (Fig. 1A and B). A B-scan ultrasound confirmed an inferior retinal detachment (Fig. 2). There were also multiple smaller retinal breaks, however, no retinal hemorrhages. Examination of the right eye was unremarkable. Detailed medical evaluation did not identify any underlying medical conditions. The underlying cause of the skin and soft tissue injuries, fractures, head injuries, and ocular findings was trauma. No accidental injury event was provided to account for these injuries.

The patient underwent a lens sparing pars plana vitrectomy (PPV) with cryopexy and 15% C3F8 gas tamponade of the left eye. There were no intraoperative and post-operative complications. His retina remained attached, his cataract did not progress to require surgery, and he did not

\* Corresponding author. Department of Ophthalmology & Vision Sciences, Hospital for Sick Children, 555 University Avenue, Toronto, Ontario, M5G 1X8, Canada.  
E-mail address: [kamiar.mireskandari@sickkids.ca](mailto:kamiar.mireskandari@sickkids.ca) (K. Mireskandari).

<https://doi.org/10.1016/j.ajoc.2022.101453>

Received 5 January 2022; Received in revised form 18 February 2022; Accepted 22 February 2022

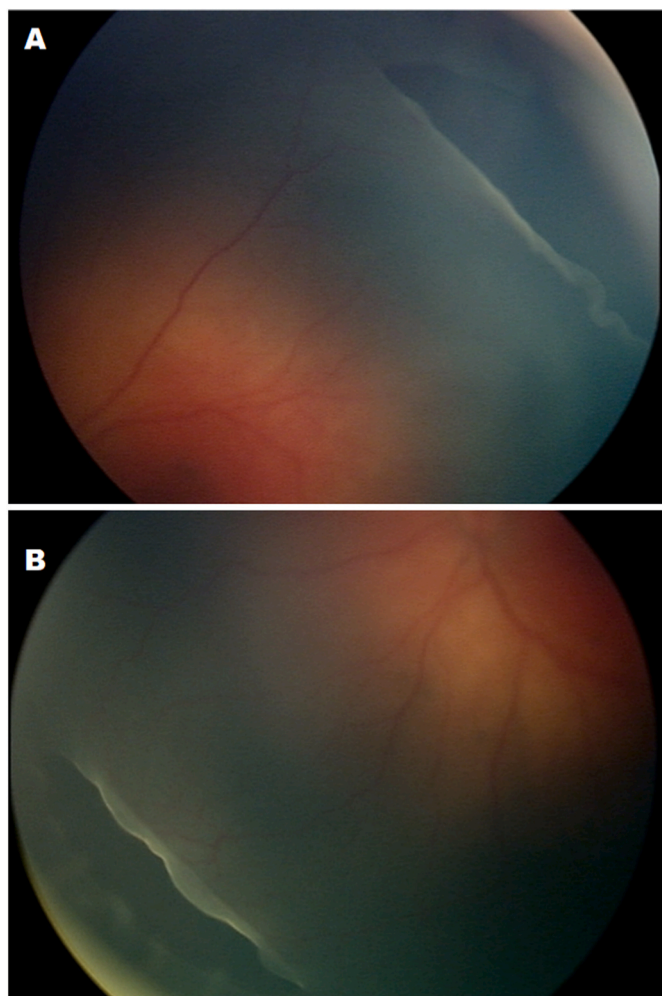
Available online 25 February 2022

2451-9936/© 2022 The Authors.

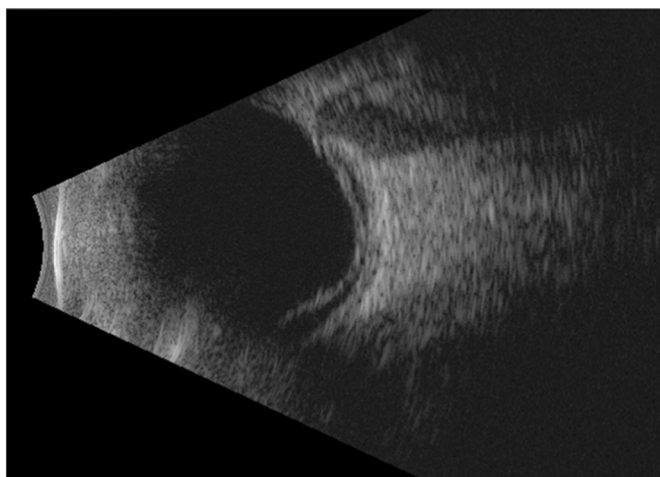
Published by Elsevier Inc.

This is an open access article under the CC BY-NC-ND license

(<http://creativecommons.org/licenses/by-nc-nd/4.0/>).



**Fig. 1.** A) Peripheral fundus image demonstrating the anterior and posterior retinal flaps at the edge of the patient's giant retinal tear from 1 to 5 o'clock supero-temporally. B) Peripheral fundus image demonstrating the patient's shallow retinal detachment and giant retinal tear from 7 to 11 o'clock.



**Fig. 2.** B-scan ultrasound demonstrating inferior retinal detachment.

develop glaucoma after the 5 years of follow up. He demonstrated manifest horizontal nystagmus with right head turn to achieve null zone.

He developed anisometropic amblyopia with refraction of  $-2.00$  in the right and  $-12.50$  in the left eye. The anisometropia was due to a

mixed etiology of axial myopia (26.04 vs 27.25mm), lenticular myopia (lens thickness 3.59 vs 4.79mm) and steeper average keratometry (41.75 vs 43.25) between the right and left eye respectively. He achieved a final visual acuity of 20/100 in the right eye and 20/200 (at 1 m only) in the left eye using HOTV eye chart. His vision was likely reduced in both eyes due to nystagmus and cortical visual impairment. Vision in the left eye also had amblyopia compounded by moderate compliance with glasses and contact lens wear and little success with patching therapy. His optical coherent tomography showed no foveal abnormality in either eye.

### 3. Discussion

Ocular injury is a common feature of abusive injury. Retinal hemorrhages are the most common finding and are present in approximately 75% of pediatric patients with abusive head injury.<sup>5</sup> There are numerous other manifestations of ocular trauma inflicted to children including signs of periorbital trauma (ecchymosis, lid edema, orbital fractures), anterior segment trauma (hyphema, iris prolapse, corneal laceration, cataract), or posterior segment trauma (retinoschisis, retinal folds, epiretinal membrane, macular hole, choroidal rupture, vitreous hemorrhage, retinal detachment, optic nerve avulsion).

The injuries documented in this case, including multiple rib, skull and long bone metaphyseal fractures, a phalanx fracture, forehead bruising, scalp swelling, multiple facial abrasions, a finger laceration, a frenular tear, and multiple areas of parenchymal hemorrhage were the result of child abuse. The present case is unique in that traumatic retinal hemorrhages were not present, however, a minor cataract and retinal detachment secondary to GRTs were present.

GRTs are defined as a retinal break greater than or equal to 3 clock-hours in circumferential extent.<sup>1</sup> Most of GRTs are idiopathic in nature and occur as a result of separation of the vitreous as far anterior as the ora serrata with persistent attachment to the anterior flap of the GRT.<sup>1</sup> Our case reports physical abuse as the cause of multiple GRTs in a pediatric patient. The mechanism of GRT development following blunt trauma is not entirely understood and most cases are idiopathic in nature.<sup>6</sup> It is possible that trauma can result in a shearing force on the retina along the posterior border of the vitreous base, leading to GRTs.

To our knowledge, there are only three cases of GRTs secondary to physical abuse in infants reported in the literature to date. One case presents a single, large 360° GRT in a 4 months old girl from presumed inflicted injury without retinal hemorrhages.<sup>7</sup> Similar to our case, they reported an anterior lens opacity, but long term follow up was not provided.<sup>7</sup> After 5 years of follow up, our patient did not have further cataract progression following PPV. Although the vitrectomized eye developed a myopic shift and high anisometropia at last follow up, this was mostly due to axial and lenticular myopia, based upon biometry. An abnormal childhood visual experience and visual deprivation is a known mechanism for developing axial myopia. A second case demonstrated a single GRT due to inflicted injury in an 11 week old infant, who also did not have associated retinal hemorrhages.<sup>8</sup> A third case reports bilateral rhegmatogenous retinal detachments associated with GRT in a 2-month-old following inflicted injury with an underlying Stickler Syndrome, a hereditary vitreoretinopathy.<sup>9</sup> There were no retinal hemorrhages and bilateral, single GRTs reported in this case. One eye was inoperable whereas the other demonstrated an attached retina 2 years following PPV. Interestingly, in all published cases of GRT in physical abuse as well as the current case, retinal hemorrhages were absent.

We report a rare and unique presentation of non-accidental injury with multiple GRTs in the same eye. To our knowledge, this is the first such case reported in the literature. Furthermore, our case represents the youngest patient (4 weeks old) and the longest follow-up period (5 years) with a successful reattached retina and no progression of cataract or glaucoma. In the absence of significant witnessed trauma, clinicians should be highly suspicious for abuse in any pediatric patient with single or multiple GRTs, even in the absence of retinal hemorrhages, and

ensure an urgent consultation to the appropriate pediatric team and children's safeguarding society is made.

### Consent

Written informed consent was attained from the patient's legal guardian to publish this case report. This report does not contain any personal identifying information.

### Funding

No funding or grant support.

### Meeting presentation

None.

### Online supplemental materials

None.

### Authorship

All authors attest that they meet the current ICMJE criteria for Authorship.

### Declaration of competing interest

The following authors have financial disclosures: KM: Research Funding - Bayer; Advisory Board - Santen Canada Inc and Novartis. WCL:

Research Funding - Alcon, Bayer; Consulting - Bayer, Novartis; Lecture Fees - Bayer, Novartis. The following authors have no financial disclosures: STS, ASD, SS, CV.

### Acknowledgements

None.

### References

1. Shunmugam M, Ang GS, Lois N. Giant retinal tears. *Surv Ophthalmol.* 2014;59(2): 192–216. <https://doi.org/10.1016/j.survophthal.2013.03.006>.
2. Ang GS, Townend J, Lois N. Interventions for prevention of giant retinal tear in the fellow eye. *Cochrane Database Syst Rev.* 2012;2(CD006909). <https://doi.org/10.1002/14651858.cd006909.pub3>.
3. Soheilian M, Peyman GA, Wafapoor H, Navarro GC, Thompson H. Surgical management of traumatic retinal detachment with perfluorocarbon liquid. *Int Ophthalmol.* 1996;20(5):241–249. <https://doi.org/10.1007/bf00131918>.
4. Karel I, Michaličková M. Pars plana vitrectomy in the pediatric population: indications and long-term results. *Eur J Ophthalmol.* 1999;9(3):291–297. <https://doi.org/10.1177/112067219900900311>.
5. Bhardwaj G, Chowdhury V, Jacobs MB, Moran KT, Martin FJ, Coroneo MT. A systematic review of the diagnostic accuracy of ocular signs in pediatric abusive head trauma. *Ophthalmology.* 2010;117(5):983–992. <https://doi.org/10.1016/j.ophtha.2009.09.040>.
6. Mehdizadeh M, Afarid M, Haqiqi MS. Risk factors for giant retinal tears. *J Ophthalmic Vis Res.* 2010;5(4):246–249.
7. Lash SC, Williams CPR, Luff AJ, Hodgkins PR. 360 Degree giant retinal tear as a result of presumed non-accidental injury. *Br J Ophthalmol.* 2004;88(1):155. <https://doi.org/10.1136/bjo.88.1.155>.
8. Sornalingam K, Borman AD, Ashworth J. Nonaccidental injury presenting as unilateral retinal detachment in two infants. *J AAPOS.* 2018;22(3):231–233. <https://doi.org/10.1016/j.jaapos.2017.10.018>.
9. Ebert JJ, Utz VM, Sisk RA. Bilateral rhegmatogenous retinal detachments from giant retinal tears in an infant with abusive head trauma and Stickler syndrome. *Am J Ophthalmol Case Rep.* 2020;17. <https://doi.org/10.1016/j.ajoc.2019.100581>.