

An Example of Breast Cancer Regression on Imaging

Elizabeth S. Burnside, Amy Trentham-Dietz, Frederick Kelcz, Jannette Collins

Controversy exists as to whether some breast cancers spontaneously regress without treatment. Regression of malignant breast neoplasms contradicts the long-accepted natural history of the disease and may have implications on the efficacy of breast cancer screening programs. We present a case in which a breast cancer regressed following cessation of hormone replacement therapy and consider the biologic basis and implications of breast neoplasms that depart from the accepted model of progressive tumor growth.

Introduction

Conventional teaching asserts that breast neoplasms generally grow at a given rate and very few if any regress without treatment. The fact that large randomized controlled trials have demonstrated a significant survival benefit in screened groups versus non-screened groups suggests that a large number of invasive breast cancers follow the model of progressive tumor growth. These growing cancers, when diagnosed at an earlier stage with mammographic screening, are amenable to early intervention which reduces mortality.

On the other hand, several sources of evidence suggest that the natural history of some breast cancers may not be as straightforward as generally assumed.(1, 2) Mathematical

models have shown that the number of cancers detected by screening mammography is larger than would be expected based on statistics prior to the adoption of population based screening. Simulations based on these models suggest that some of these cancers would not have become clinically significant.(Fryback DG et al., The case for limited malignant potential breast cancer, presented at the 26th Annual Meeting of the Society for Medical Decision Making, 2004) Studies of European breast cancer screening programs (offering mammography to women aged 50-65) demonstrate an approximately 50% higher cancer detection rate than background (non-screened) rates in the same age groups.(3, 4) In Norway's breast cancer screening program, the cumulative incidence of breast cancer is statistically significantly greater than the prevalence round. Some investigators theorize that a proportion of these incident cases might never have become clinically manifest without screening. (Zahl PH et al, Frontiers in Cancer Prevention Research, presented at Third Annual American Association for Cancer Research (AACR) International Conference, 2004)

Furthermore, if all of these cancers were not detected but were left to progress, the rate of breast cancers in older women (>65) in non-screened populations would be triple what is actually seen.(3,4) Therefore, to account for these discrepancies, scientists have asserted the likelihood that some subclinical breast cancers may not progress or may regress spontaneously.(5) The purpose of this report is to describe a case of apparent breast cancer regression and recrudescence associated with hormone replacement therapy (HRT).

Citation: Burnside ES, Trentham-Dietz A, Kelcz F, Collins, J. An example of breast cancer regression on imaging. *Radiology Case Reports*. [Online] 2006;1:4.

Copyright: © Elizabeth S. Burnside. This is an open-access article distributed under the terms of the Creative Commons Attribution-NonCommercial-NoDerivs 2.5 License, which permits reproduction and distribution, provided the original work is properly cited. Commercial use and derivative works are not permitted.

Abbreviations: MRI, magnetic resonance imaging, HRT, hormone replacement therapy, MLO, mediolateral oblique, CC, craniocaudal, ER/PR, estrogen/progesterone receptors, WHI, Women's Health Initiative, AACR, American Association for Cancer Research, Gd-DTPA, gadopentate dimeglumine-diethylenetriaminepentaacetate, DCIS, ductal carcinoma in situ

Elizabeth S. Burnside (E-mail: es.burnside@hosp.wisc.edu), Frederick Kelcz, and Jannette Collins are with the Department of Radiology, University of Wisconsin School of Medicine and Public Health, Wisconsin, United States of America

Amy Trentham-Dietz is with the Department of Population Health Sciences, and Comprehensive Cancer Center, University of Wisconsin, Wisconsin, United States of America

DOI: 10.2484/rcr.v1i2.4

An Example of Breast Cancer Regression on Imaging

Case Report

Our institutional review board granted us an exemption from their review for this report. A 64-year-old postmenopausal female with a four year history of hormone replacement therapy (Estradiol, 1 mg po, q.d. and Methylprogesterone, 2.5 mg po q.d.) underwent screening mammography in December of 2001. This examination revealed a mass in the inner left breast (Figure 1a and b).

Diagnostic views confirmed this finding (Figure 1c) and an MRI was recommended for further evaluation. A dynamic contrast-enhanced MRI examination in February 2002 revealed a suspicious 9 mm mass in the upper inner left breast (Figure 2 a-d) corresponding to the mammographic finding and demonstrating rapid uptake of gadolinium with washout in the delayed phase. Ultrasound was not performed at this time. Needle localization by MRI was recommended because the interpreting radiologist thought the abnormality could be more confidently identified on this modality. The patient discontinued HRT at this time.

Eight weeks later the patient returned for MRI-guided needle localization. Repeat MRI examination with light breast compression but an otherwise identical imaging protocol showed that the MRI abnormality had decreased in size to 4 mm (Figure 3 a-d) and the enhancement was less

marked. At this time, the MRI localization procedure was canceled. The case was presented at our monthly breast imaging conference. The mammographic abnormality was thought to be suspicious enough to warrant biopsy despite the decreasing conspicuity of the MRI finding. The patient was offered a stereotactic core biopsy but declined in favor of follow-up mammography.

The patient, still off HRT, returned for mammography of the left breast in July of 2002. This mammogram demonstrated the mass had continued to decrease in size, measuring 3 mm (Figure 4 a-c). The patient was advised to resume a screening schedule of mammography and in December of 2002 the mass had resolved completely (Figure 5 a-c).

In January of 2003, the patient began using vaginal cream containing Estradiol. A 10 mm mass was observed on screening mammography in December of 2003, and confirmed on diagnostic mammography in January of 2004 in the exact location of the previously identified finding, in the upper inner left breast (Figure 6 a-c). Ultrasound revealed a corresponding 10 mm hypoechoic mass with a thick hyperechoic rim in the left upper inner left breast (Figure 7a). An ultrasound-guided core biopsy (Figure 7b) and clip placement (Figure 7c) were performed. Post-procedure mammography showed the clip to be lo

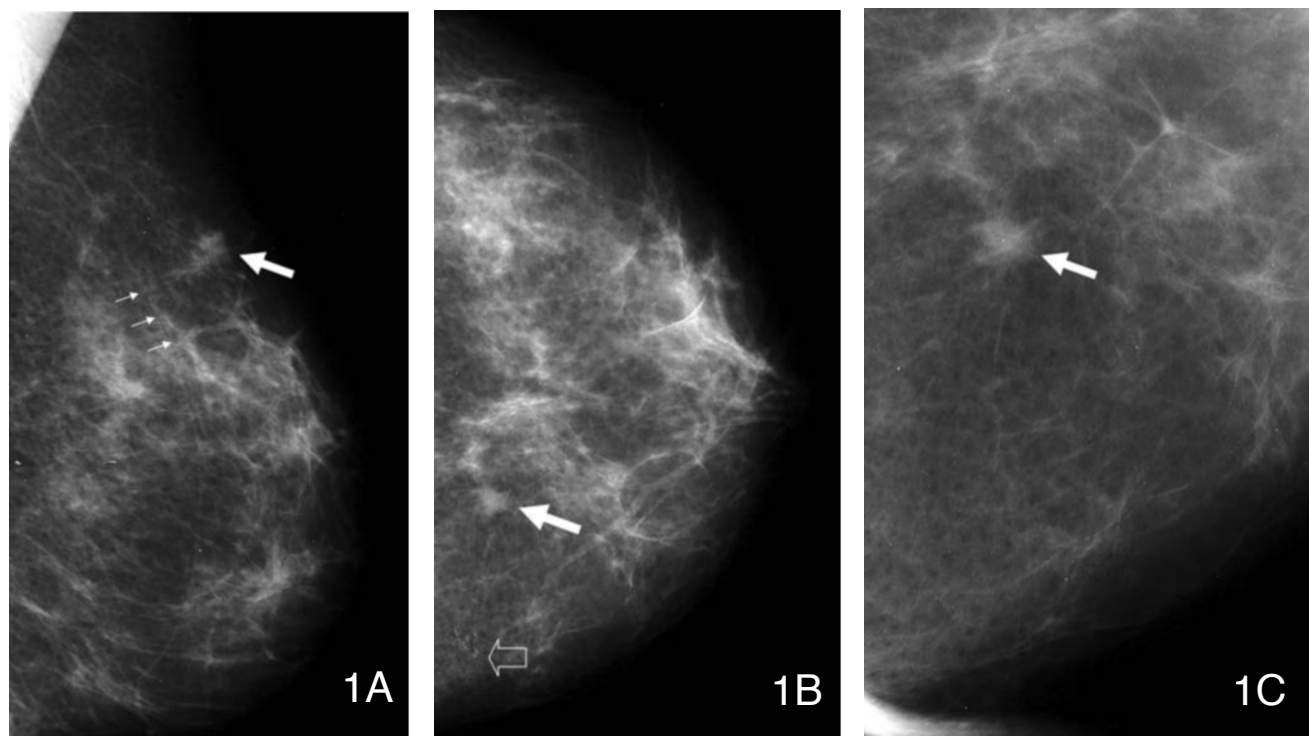


Figure 1. A 64-year-old asymptomatic female presents for screening and subsequent diagnostic mammography: 1A) Left mediolateral oblique (MLO) demonstrates a mass in the upper breast (large arrow) while the smaller arrows denote an artery for anatomic reference, 1B) Craniocaudal (CC) view shows that the mass is in the inner left breast (solid arrow)— dust artifact is noted medial to this finding (open arrow), 1C) spot compression magnification view in the CC projection confirms a mass in the left inner breast (large arrow).

An Example of Breast Cancer Regression on Imaging

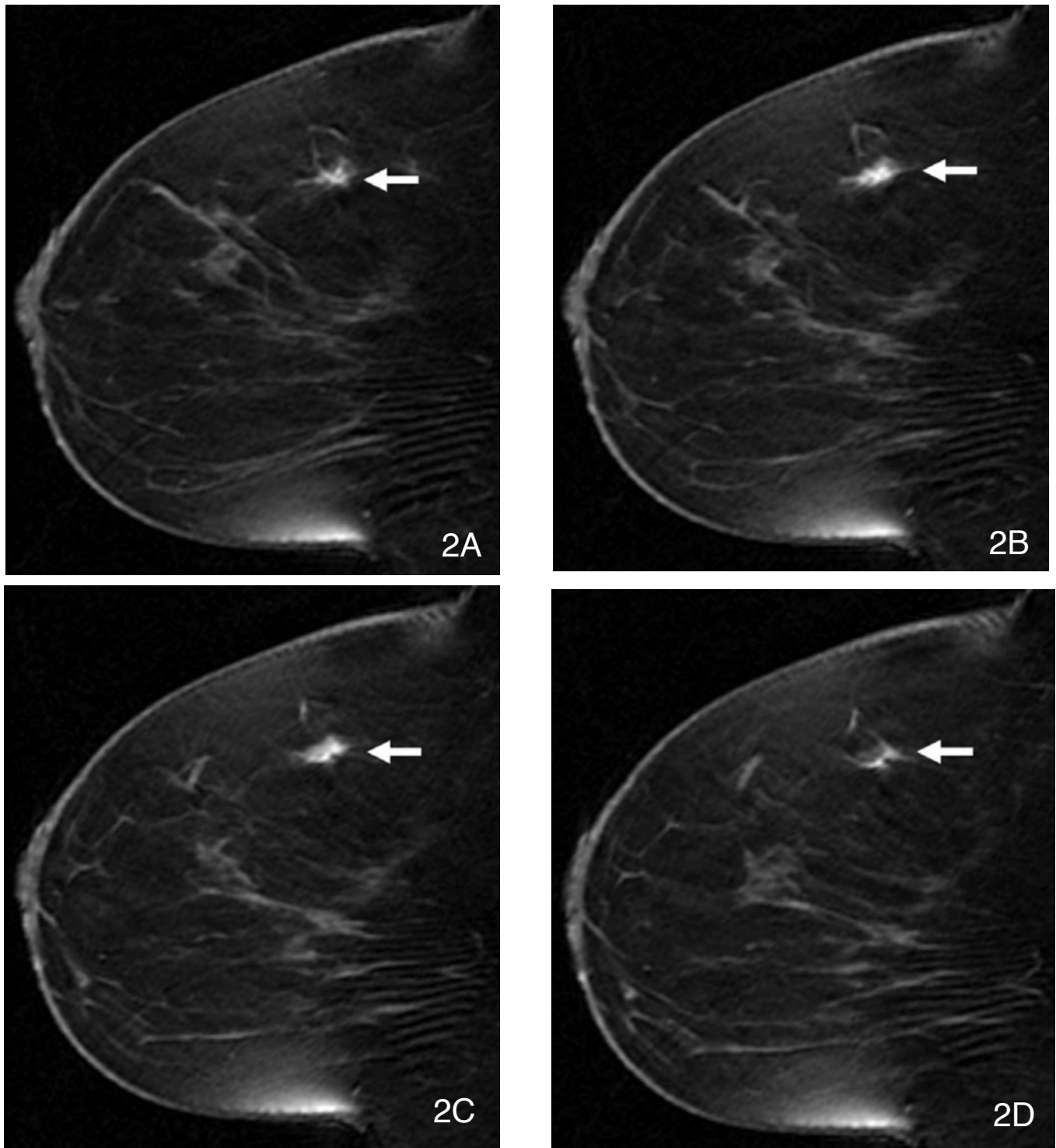


Figure 2 (A-D). Four sequential frames with 2 mm slice thickness from three dimensional fat suppressed T1-weighted gradient recalled echo sequence (from just medial to the nipple proceeding medially) obtained approximately 9 minutes after Gd-DTPA contrast injection demonstrate a spiculated mass in the left upper slightly inner breast (arrow).

An Example of Breast Cancer Regression on Imaging

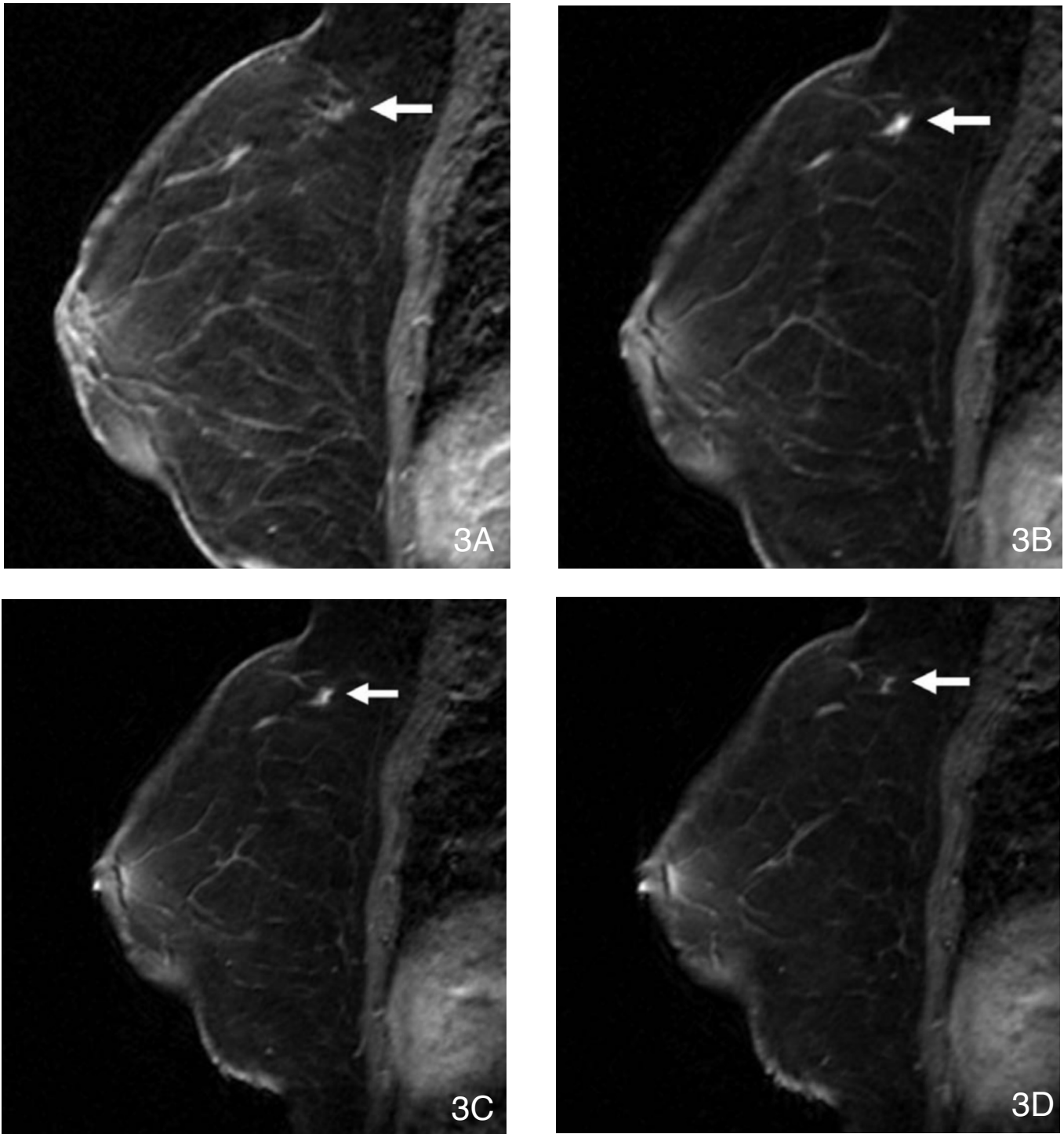


Figure 3 (A-D). Six weeks after the initial breast MRI, a repeat study for the purpose of needle localization was performed. Four sequential frames using the same slice thickness in the same location from a T1-fat-suppressed imaging obtained two minutes after contrast injection demonstrate significantly diminished size and enhancement of the mass (arrow). The breast anatomy appears slightly different due to light compression placed during the needle localization procedure.

An Example of Breast Cancer Regression on Imaging

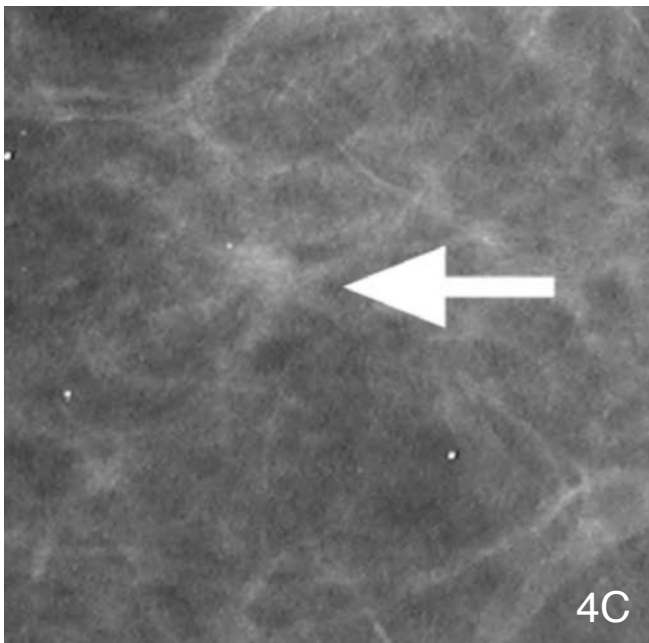
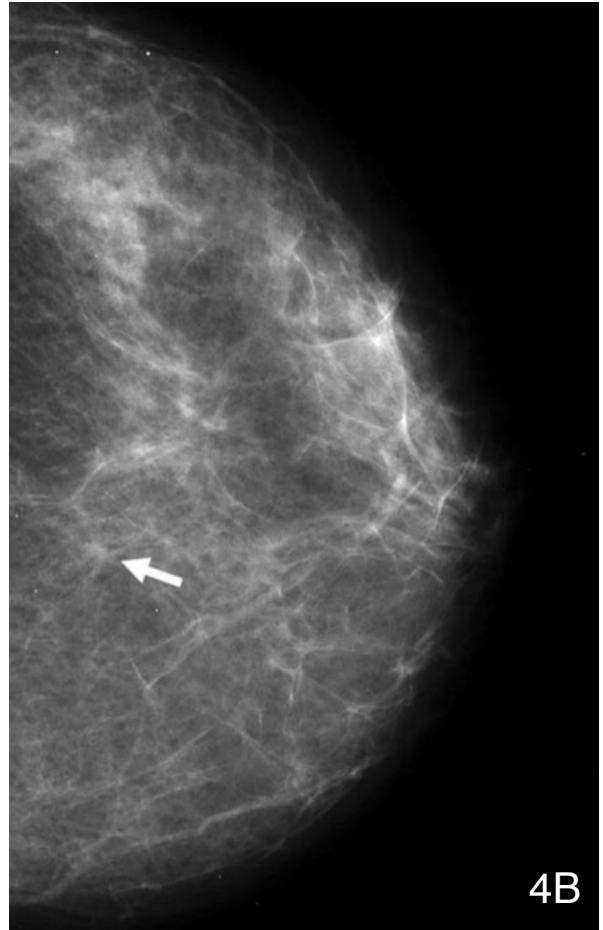
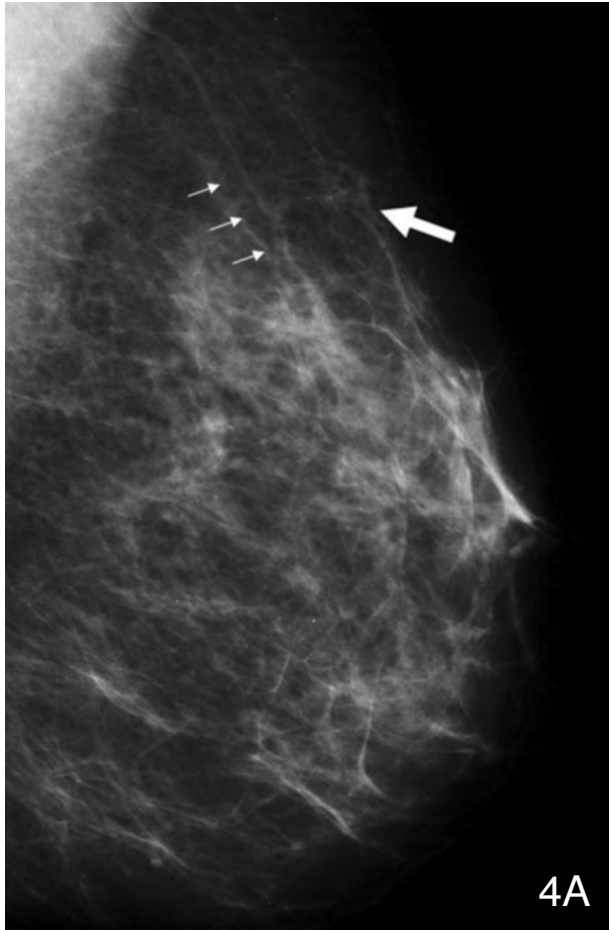


Figure 4. Six months after the initial mammogram: 4A) left MLO (smaller arrows denote an artery for anatomic reference), 4B) CC, and 4C) photographic magnification in the CC projection demonstrate that the mass has decreased in size (large arrow).

An Example of Breast Cancer Regression on Imaging

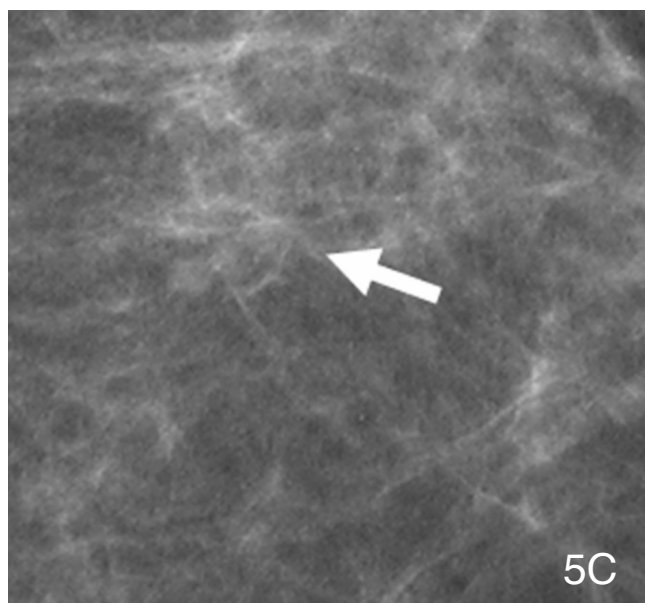
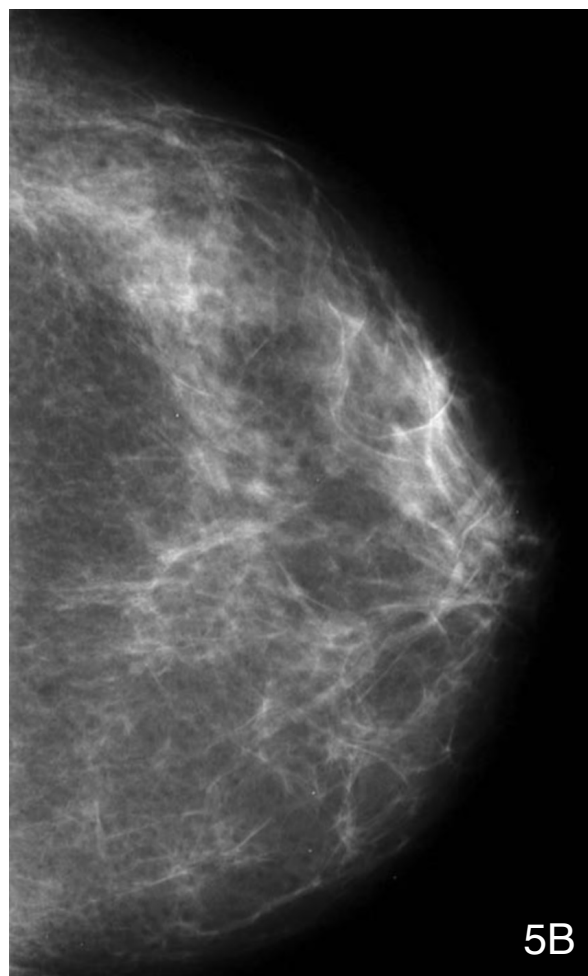
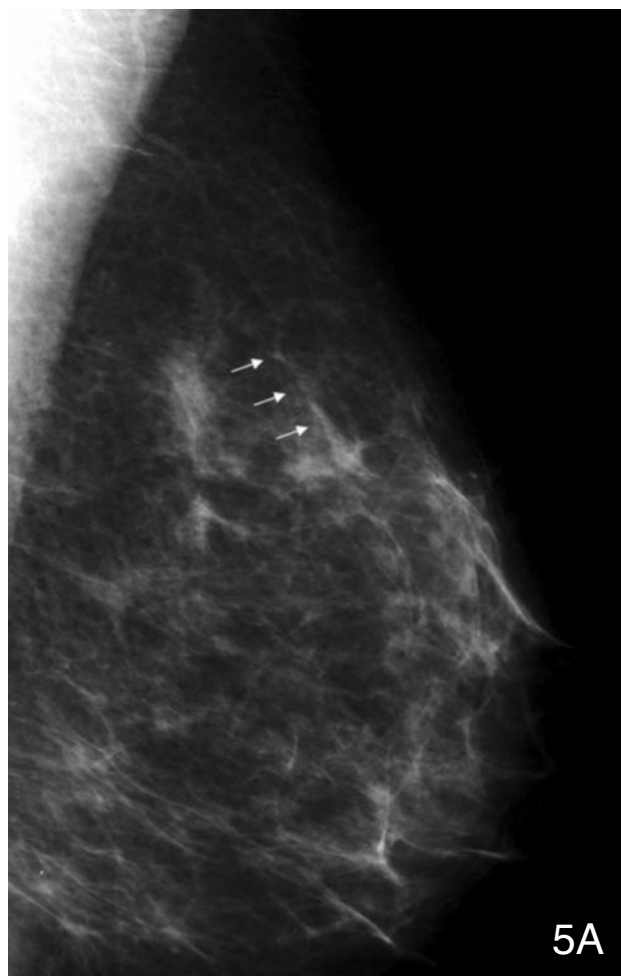


Figure 5. One year after the initial mammogram: 5A) left MLO (smaller arrows denote an artery for anatomic reference), 5B) CC, and 5C) photographic magnification in the CC projection (arrow denotes the area of interest) demonstrate that the mass has disappeared.

An Example of Breast Cancer Regression on Imaging

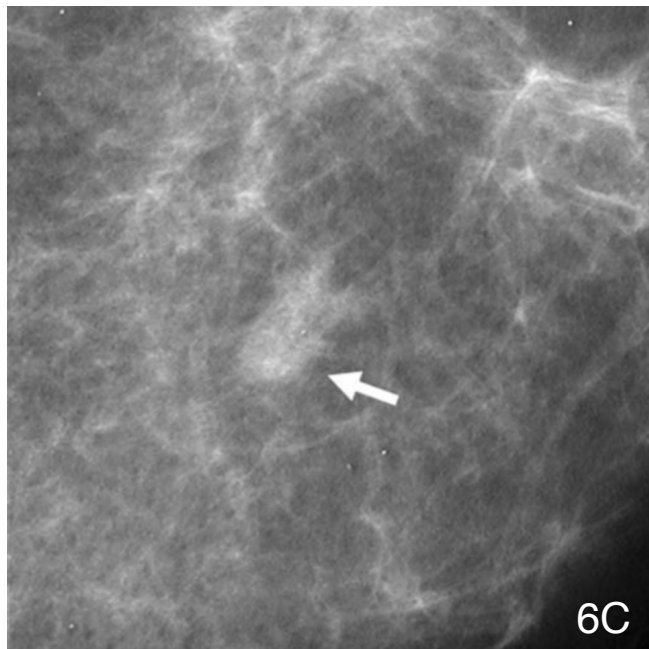
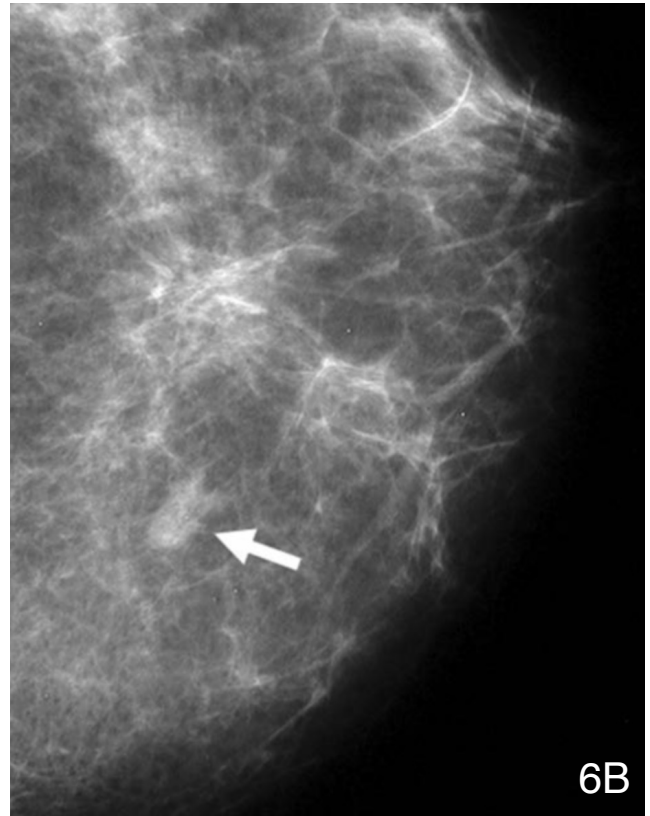
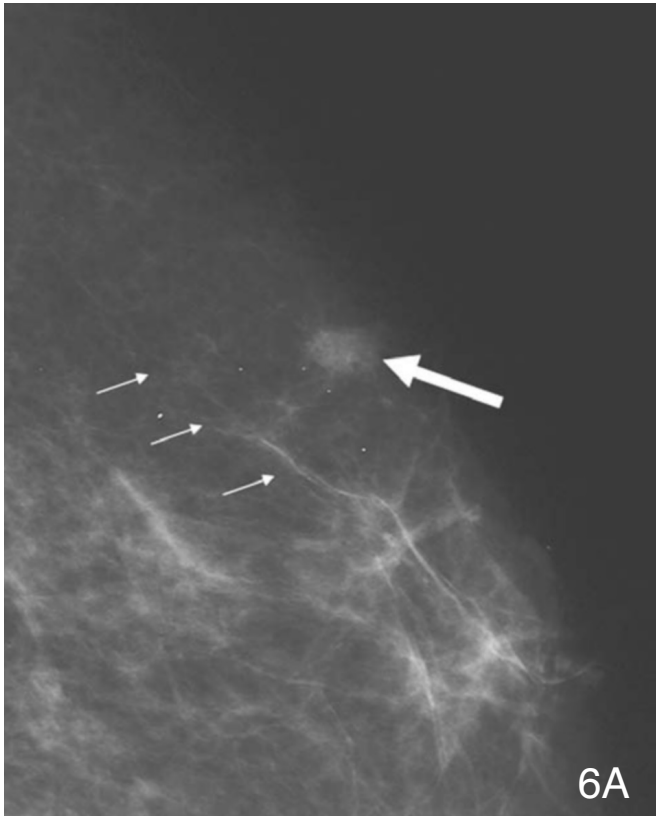


Figure 6. Two years after the initial mammogram, 6A) left MLO (smaller arrows denote an artery for anatomic reference), 6B) CC, and 6C) photographic magnification in the CC projection demonstrate that the mass has recurred (large arrow).

An Example of Breast Cancer Regression on Imaging

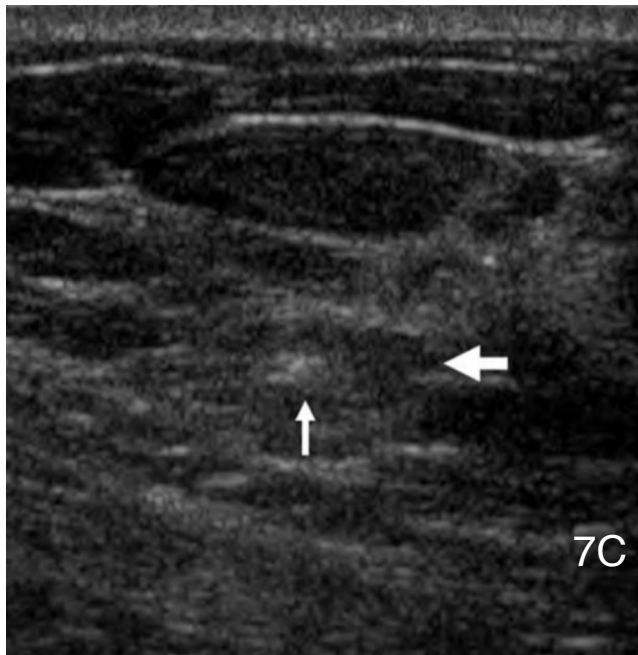
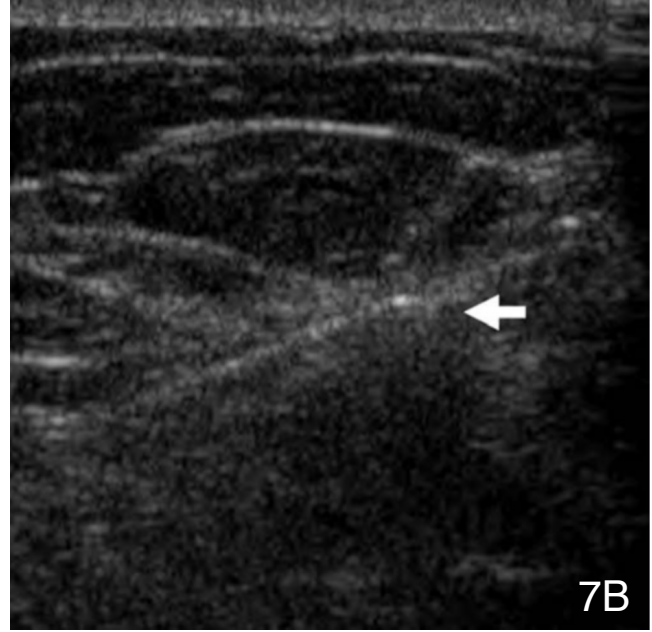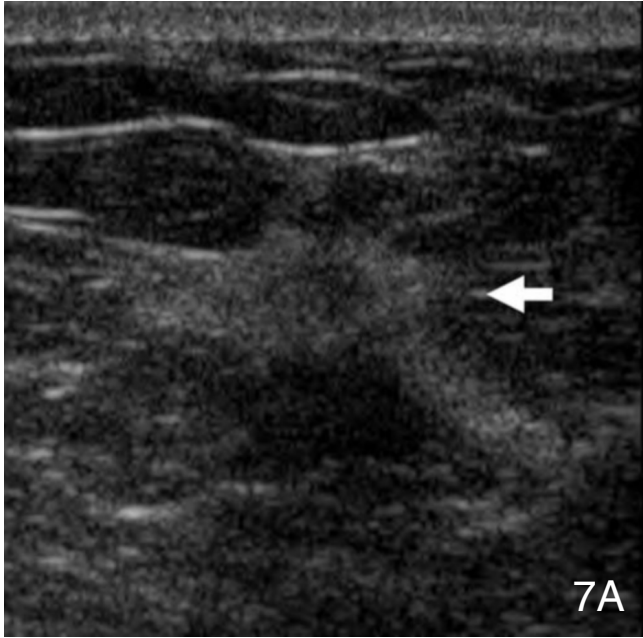


Figure 7. Ultrasound images of the left upper inner breast (all in the transverse plane) demonstrate: 7A) a 10 cm hypoechoic mass with a thick hyperechoic rim (arrow), 7B) ultrasound guided biopsy of the mass (arrow), and 7C) the mass (large arrow) following placement of a clip (small arrow) just adjacent to the mass

cated in the anterior aspect of the mass (Figure 8 a-c). Biopsy showed invasive lobular carcinoma. Needle localization and subsequent lumpectomy revealed a 12 mm, grade 1, invasive lobular carcinoma with ductal features. Estrogen/progesterone receptors (ER/PR) were strongly positive. Sentinel lymph node biopsy was negative with four lymph nodes removed. The patient was treated with radiation therapy and tamoxifen. The patient remains disease free one year after her diagnosis.

Discussion

Understanding the natural history of breast cancer is critically important in the effective and appropriate diagnosis and treatment of the disease. The medical community has generally operated under the assumption that invasive breast cancers typically progress and only rarely regress spontaneously. Several epidemiologic concepts have been cited as evidence that small breast cancers may cease growing or regress spontaneously including: 1) cancer incidence is significantly higher in screened versus non-screened populations, 2) the cumulative breast cancer incidence is higher than what would be expected based on a prevalence screening round, and 3) no subsequent decrease in cancer incidence is seen with cessation of mammographic screening. (5)

One review of the literature found 32 reported cases of spontaneous remission of breast cancer and the histologic diagnosis was only sufficiently documented in six of these cases.(1) Several malignant neoplasms, other than primary breast tumors, have shown the ability to regress spontaneously. These include lymphoma, hepatocellular carcinoma, and pediatric neuroblastoma among others. In general, the number of such cases is extremely small. The notable exception is neuroblastoma in infants which frequently regresses or matures spontaneously.(6-8)

The biologic mechanism behind regression of malignant neoplasm is unknown. In cancers such as hepatocellular

An Example of Breast Cancer Regression on Imaging

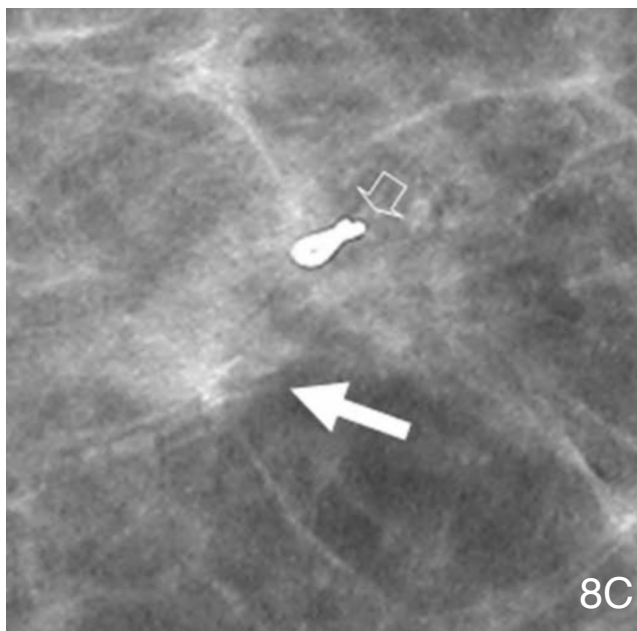
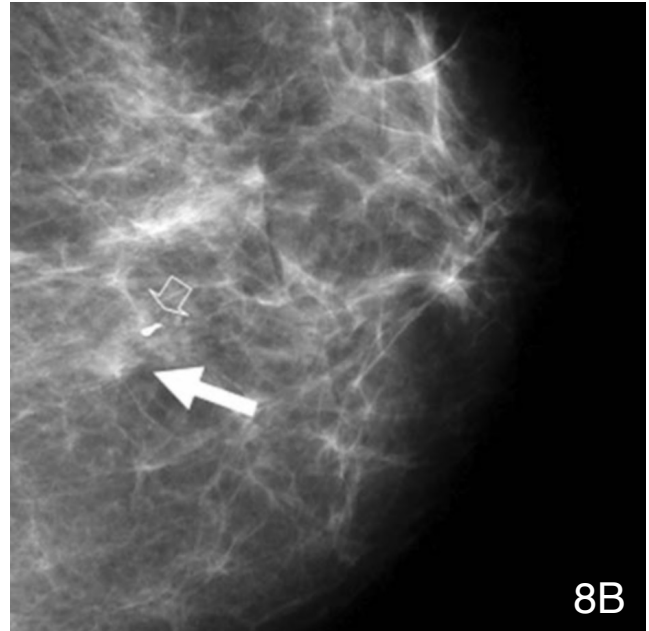
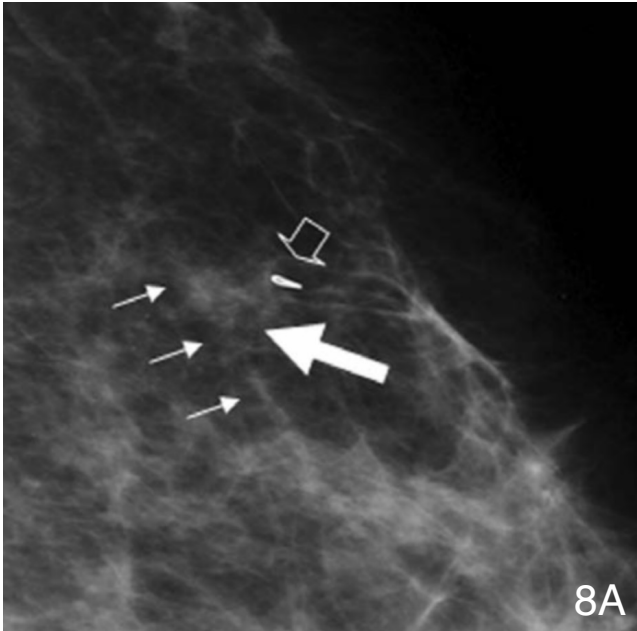


Figure 8. Following ultrasound guided core biopsy; 8A) left MLO (smaller arrows denote an artery for anatomic reference), 8B) CC, and 8C) photographic magnification in the CC projection demonstrate the mass (large solid arrow) and a radioopaque marking clip (large open arrow) placed in the anterior lateral aspect of the tumor.

carcinoma, an immune response to the tumor is cited as the causative agent.(9) An immune influence is also associated with transplant-related malignancies. Post-transplant lymphoproliferative disorder is a direct consequence of chronic immunosuppression and resulting infection by Epstein-Barr virus. If detected early, most cases resolve with reduction of immunosuppressive therapy.(10) In breast cancer, a decrease in either intrinsic or extrinsic female hormones may be a mechanism for tumor regression.

While an in depth discussion of the relationship of breast cancer and hormones is beyond the scope of this manuscript, a brief consideration of available evidence that estrogen may have played a role in this patient's care is im-

portant. Observational studies have repeatedly shown a correlation between estrogen-based hormone replacement regimens and the development of breast cancer.(11, 12) The Women's Health Initiative (WHI) study, the largest randomized controlled trial to investigate the effects of HRT, was stopped because the correlation between estrogen and progesterone therapy and the development of breast cancer appeared to outweigh any significant benefit of HRT.(13) Interestingly, the number of ER/PR positive cancers did not differ significantly between the HRT and the placebo groups in the WHI study.(14) Finally, it has been well established that selective estrogen receptor modulator drugs like tamoxifen are effective in the treatment of breast cancer.(15) In fact, such drugs have been shown to play a role in breast cancer prevention.(16) While the link between tumor receptor status and breast cancer development, growth, and possible regression is undoubtedly important, the precise mechanisms remain uncertain.

Most of the prior case reports suggest but none definitively establish a link between hormone use, and tumor evolution.(1, 17) Most of the previously reported cases are so old that tumor hormone receptor status was unlikely evaluated. Though our case report documents a possible association between ER/PR positivity, estrogen/progesterone therapy discontinuation, and tumor regression, a cause-and-effect relationship cannot be inferred without further study. Recent research has proposed to look at tumor biomarkers to determine which breast cancers

An Example of Breast Cancer Regression on Imaging

may regress under certain conditions.⁽²⁾ Although basing therapeutic decisions on specific tumor characteristics appears promising, such research is in its infancy.

The unnecessary treatment of breast neoplasms not destined to impact survival is not a new concept. The increasing number of DCIS diagnoses and subsequent therapies, which parallel rates of mammographic screening, have raised concerns of over-treatment.⁽¹⁸⁾ Similarly, if a proportion of invasive breast cancers will ultimately regress, over-treatment may be occurring. Unfortunately, current technology does not allow accurate distinction of which cases of breast cancer will lead to morbidity and mortality if left untreated. Therefore, we treat virtually all cases.

Regression of malignant neoplasms in a screening setting is extremely difficult to document with certainty because the candidate neoplasms will most likely be very small. Two scenarios exist in which tumor regression can be documented. A patient can undergo percutaneous biopsy proving malignancy and then refuse treatment. If the tumor disappears, this may qualify as tumor regression. Unfortunately, the biopsy itself may be cited as the causative factor of regression either by completely removing the tumor or disrupting its blood supply. The second scenario demonstrating regression is shown in our case report—a suspicious mass regresses before biopsy is performed. With recrudescence of this tumor, we have indirect evidence that it has regressed only to recur subsequent to the reinstatement of estrogen therapy. In this case, we simply do not have histologic proof of the initial diagnosis. Considering the difficulty of definitively proving regression beyond a shadow of a doubt, the case presented here, with its convincing imaging features, is strong evidence of this phenomenon. The difficulty in documenting breast cancer regression makes directly measuring the frequency of this phenomenon as a percentage of all invasive breast cancers impossible. Alternative strategies, such as simulation modeling, may provide some answers. Until reliable predictors of future tumor regression become available, all invasive breast cancers must be assumed to be life threatening.

In conclusion, we believe this case is a compelling example of breast cancer that transiently regressed after cessation of estrogen and progesterone replacement therapy. It is impossible to surmise how common such an occurrence might be without further study. Future investigation into this phenomenon will be critically important not only for individual treatment decisions but also in determining the optimal deployment of population based detection and treatment resources.

References

1. Larsen SU, Rose C. [Spontaneous remission of breast cancer. A literature review]. *Ugeskr Laeger*. 1999 Jun 28;161(26):4001-4. Review. Danish. [[PubMed](#)]
2. Love RR, Niederhuber JE. Models of breast cancer growth and investigations of adjuvant surgical oophorectomy. *Ann Surg Oncol*. 2004 Sep;11(9):818-28. Review. [[PubMed](#)]
3. Sarkeala T, Anttila A, Forsman H, Luostarinen T, Saarenmaa I, Hakama M. Process indicators from ten centres in the Finnish breast cancer screening programme from 1991 to 2000 *Eur J Cancer*. 2004 Sep;40(14):2116-25. [[PubMed](#)]
4. Smith-Bindman R, Chu PW, Miglioretti DL, et al. Comparison of screening mammography in the United States and the United Kingdom. *JAMA*. 2003 Oct 22;290(16):2129-37. Erratum in: *JAMA*. 2004 Feb 18;291(7):824. [[PubMed](#)]
5. Zahl PH, Andersen JM, Maehlen J. Spontaneous regression of cancerous tumors detected by mammography screening. *JAMA*. 2004 Dec 1;292(21):2579-80; author reply 2580. [[PubMed](#)]
6. Yamamoto K, Hanada R, Kikuchi A, et al. Spontaneous regression of localized neuroblastoma detected by mass screening. *J Clin Oncol*. 1998 Apr;16(4):1265-9. [[PubMed](#)]
7. Okazaki T, Kohno S, Mimaya J, et al. Neuroblastoma detected by mass screening: the Tumor Board's role in its treatment. *Pediatr Surg Int*. 2004 Jan;20(1):27-32. Epub 2003 Dec 19. [[PubMed](#)]
8. Nickerson HJ, Matthay KK, Seeger RC, et al. Favorable biology and outcome of stage IV-S neuroblastoma with supportive care or minimal therapy: a Children's Cancer Group study. *J Clin Oncol*. 2000 Feb;18(3):477-86. [[PubMed](#)]
9. Blondon H, Fritsch L, Cherqui D. Two cases of spontaneous regression of multicentric hepatocellular carcinoma after intraperitoneal rupture: possible role of immune mechanisms. *Eur J Gastroenterol Hepatol*. 2004 Nov;16(12):1355-9. [[PubMed](#)]
10. Collins J, Muller NL, Leung AN, et al. Epstein-Barr virus-associated lymphoproliferative disease of the lung: CT and histologic findings. 1998 Sep;208(3):749-59. [[PubMed](#)]
11. Steinberg KK, Thacker SB, Smith SJ, et al. A meta-analysis of the effect of estrogen replacement therapy on the risk of breast cancer. 1991 Apr 17;265(15):1985-90. Erratum in: *JAMA* 1991 Sep 11;266(10):1362. [[PubMed](#)]
12. Key T, Appleby P, Barnes I, Reeves G. Endogenous sex hormones and breast cancer in postmenopausal women: reanalysis of nine prospective studies. *J Natl Cancer Inst*. 2002 Apr 17;94(8):606-16. [[PubMed](#)]

An Example of Breast Cancer Regression on Imaging

13. Rossouw JE, Anderson GL, Prentice RL, et al. Risks and benefits of estrogen plus progestin in healthy postmenopausal women: principal results From the Women's Health Initiative randomized controlled trial. *JAMA*. 2002 Jul 17;288(3):321-33. [[PubMed](#)]
14. Chlebowski RT, Hendrix SL, Langer RD, et al. Influence of estrogen plus progestin on breast cancer and mammography in healthy postmenopausal women: the Women's Health Initiative Randomized Trial. *JAMA*. 2003 Jun 25;289(24):3243-53. [[PubMed](#)]
15. Kaklamani VG, Gradishar WJ. Adjuvant therapy of breast cancer. *Minerva Ginecol*. 2005 Oct;57(5):521-36. [[PubMed](#)]
16. Fisher B, Costantino JP, Wickerham DL, et al. Tamoxifen for the prevention of breast cancer: current status of the National Surgical Adjuvant Breast and Bowel Project P-1 study. *J Natl Cancer Inst*. 2005 Nov 16;97(22):1652-62. [[PubMed](#)]
17. Lewison EF. Spontaneous regression of breast cancer. *Natl Cancer Inst Monogr*. 1976 Nov;44:23-6. [[PubMed](#)]
18. Ernster VL, Barclay J, Kerlikowske K, Grady D, Henderson C. Incidence of and treatment for ductal carcinoma in situ of the breast. *JAMA*. 1996 Mar 27;275(12):913-8. [[PubMed](#)]