

# Organizing pneumonia in a carrier of human T-cell lymphotropic virus type-1

Masahiro Yamasaki, Masaya Taniwaki, Kunihiko Funaishi<sup>1</sup>, Noboru Hattori<sup>2</sup>

Department of Respiratory Medicine, Hiroshima Red Cross Hospital and Atomic-Bomb Survivors Hospital, Naka-ku, <sup>1</sup>Department of Internal Medicine, Mihara Medical Associations Hospital, Mihara, <sup>2</sup>Department of Molecular and Internal Medicine, Institute of Biomedical and Health Sciences, Hiroshima University, Minami-ku, Hiroshima, Japan

## Address for correspondence:

Dr. Masahiro Yamasaki,  
1-9-6 Senda-Machi,  
Naka-ku, Hiroshima  
730-8619, Japan.  
E-mail: myamasanj@  
yahoo.co.jp

Submission: 09-07-2019  
Accepted: 12-09-2019  
Published: 02-01-2020

## Abstract:

Human T-cell lymphotropic virus type-1 (HTLV-1)-associated bronchioloalveolar disorders (HABAs) are pulmonary disorders with various interstitial lung disease patterns that often occur in HTLV-1 carriers. Among HABAs, organizing pneumonia (OP) is extremely rare. We present a case of an 82-year-old woman with OP as a HABA. This patient responded to corticosteroid therapy; however, the patient required the continuation of oral corticosteroid therapy to avoid OP relapse. In cases of OP as a HABA that are not stabilized by treatment with corticosteroids, continuation of oral corticosteroid therapy might be considered.

## Keywords:

Human T-cell lymphotropic virus type-1, human T-cell lymphotropic virus type-1-associated bronchioloalveolar disorder, human T-cell lymphotropic virus type-1 carrier, organizing pneumonia

**H**uman T-cell lymphotropic virus type-1 (HTLV-1) is a retrovirus that causes adult T-cell leukemia/lymphoma (ATL). In HTLV-1 carriers, pulmonary disorders with various interstitial lung disease patterns often occur<sup>[1]</sup> and are known as HTLV-1-associated bronchioloalveolar disorders (HABAs).<sup>[2]</sup> Among HABAs, organizing pneumonia (OP) is extremely rare.<sup>[3]</sup> Therefore, the efficacy of corticosteroid therapy for OP as a HABA has not been established. Herein, we present a case of OP that was relatively refractory to corticosteroid therapy.

## Case Report

An 82-year-old woman, who was a nonsmoker and had no remarkable personal or family medical history, presented with exertional breathlessness. She had no fever or sore throat. A physical examination revealed no remarkable abnormalities; breath sounds and skin appearance were

normal. However, chest radiography showed airspace consolidations in the bilateral lung fields [Figure 1a], and chest computed tomography showed airspace consolidations along the bronchovascular bundles and bronchiectasis [Figure 1b]. Serum levels of *Chlamydomyces pneumoniae* and *Mycoplasma pneumoniae* IgM antibodies were not increased. Antibiotic administration did not improve the chest radiography findings. The patient tested positive for serum anti-HTLV-1 antibodies and was therefore diagnosed with HTLV-1 carrier. The levels of other viral serum IgM antibodies, such as cytomegalovirus, herpes simplex virus, herpes zoster virus, and Epstein-Barr virus VCA-IgM, were not increased. Pulmonary function tests were performed; vital capacity (VC) was 1.71 L (81.4%); forced expiratory volume in 1 s (FEV1) was 1.30 L; FEV1/forced vital capacity (FVC) was 72.63%; and carbon monoxide diffusing capacity (DLCO) was 5.16 mL/min/mmHg (27.1%). She subsequently underwent a bronchoscopy. On histopathological examination of the transbronchial biopsy specimen of the

This is an open access journal, and articles are distributed under the terms of the Creative Commons Attribution-NonCommercial-ShareAlike 4.0 License, which allows others to remix, tweak, and build upon the work non-commercially, as long as appropriate credit is given and the new creations are licensed under the identical terms.

For reprints contact: reprints@medknow.com

**How to cite this article:** Yamasaki M, Taniwaki M, Funaishi K, Hattori N. Organizing pneumonia in a carrier of human T-cell lymphotropic virus type-1. *Ann Thorac Med* 2020;15:41-3.

## Access this article online

Quick Response Code:

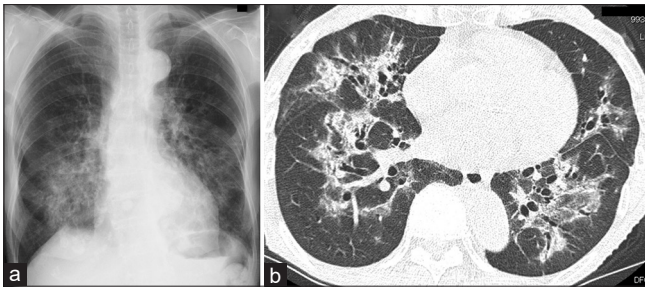


Website:

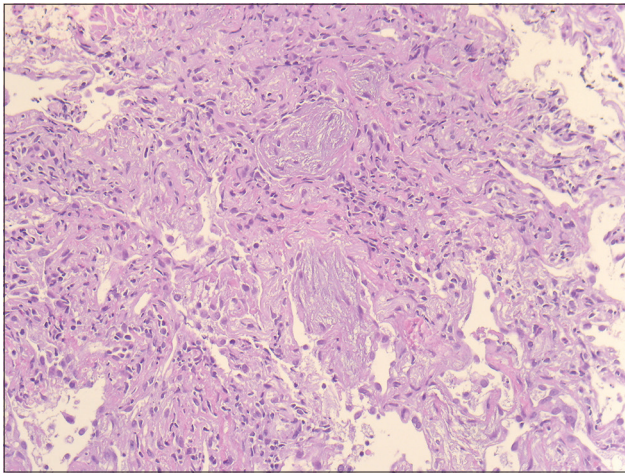
www.thoracicmedicine.org

DOI:

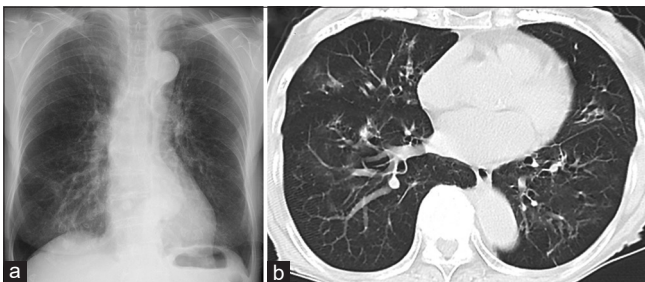
10.4103/atm.ATM\_204\_19



**Figure 1:** (a) Chest radiography showing airspace consolidations in the bilateral middle and lower lung fields. (b) Chest computed tomography showing airspace consolidations along the bronchovascular bundles and bronchiectasis. The computed tomography findings closely resemble one of several patterns of typical cryptogenic organizing pneumonia



**Figure 2:** The transbronchial biopsy specimen of the pulmonary lesion indicating organizing pneumonia (H and E)



**Figure 3:** (a) Chest radiography and (b) chest computed tomography scan after 7 months of corticosteroid therapy showing improved findings were observed

pulmonary lesion, the patient was diagnosed with OP [Figure 2]. The bronchoalveolar lavage fluid (BALF) showed a slightly elevated cell concentration (484 cells/ $\mu$ L), and 50% of these cells were lymphocytes. The lymphocyte subsets of BALF were as follows: CD3 (87.4%), CD4 (54.0%), CD8 (37.5%), and the CD4/CD8 ratio was 1.44. A culture of the BALF detected no pathogenic microorganisms. She had no prior use of medical drugs. In addition, we detected no autoantibodies or malignancies. Hence, the final diagnosis was OP as a HABA.

She was administered a 30-mg dose of oral prednisolone daily. Even after 10 days of treatment, chest radiography findings and breathlessness did not improve significantly. Therefore, she was administered 250 mg/day of intravenous methylprednisolone for 3 days followed by 20 mg/day of oral prednisolone. An improvement was observed in chest radiography findings [Figure 3] and breathlessness. Pulmonary function improved as follows: VC was 2.03 L (96.7%), FEV1 was 1.49 L, FEV1/FVC was 77.60%, and DLCO was 6.41 mL/min/mmHg (33.7%). Therefore, the prednisolone dose was tapered to 2 mg/day. This dose was maintained to avoid the possibility of an OP relapse. The OP has been stable for 17 months, with no ATL cells detected in the peripheral blood.

## Discussion

In this case report, we have presented two important clinical observations. First, OP can occur in an HTLV-1 carrier. To the best of our knowledge, only two cases of OP in HTLV-1 carriers have been reported previously.<sup>[4,5]</sup> Known causes and associations of secondary OP include medical-related drugs, infections, inflammation, malignancy, transplantation, interstitial lung disease, and miscellaneous lung injury.<sup>[6]</sup> In the present case, none of the known causes or associations of OP were found. However, as the patient was an HTLV-1 carrier, diagnosing the OP as a HABA in the present case is justified.

Second, OP as a HABA may be effectively treated with corticosteroids as previously reported.<sup>[4,5]</sup> In general, OP responds rapidly to oral corticosteroid therapy. The present case also showed the efficacy of corticosteroid therapy. However, the present case required continuation of oral corticosteroid therapy to avoid OP relapse. In cases of OP as a HABA that are not stabilized by treatment with corticosteroids, continuation of oral corticosteroid therapy might be considered.

The increment of CD4/CD8 ratio in BALF might be a feature of OP as a HABA. Considering cryptogenic OP, it has been reported that the CD4/CD8 ratio decreases.<sup>[7]</sup> Moreover, it has been reported that CD4+ and CD25+ lymphocytes increase in the BALF of HABA.<sup>[1]</sup> To evaluate the usefulness of the examination of CD4/CD8 ratio in BALF for the diagnosis of OP as a HABA, accumulation of BALF data of OP as a HABA is required.

HTLV-1 infection is endemic in Japan, Africa, the Caribbean islands, and Central and South America.<sup>[8]</sup> However, because of immigration, HTLV-1 carriers can be found in many other regions of the world. Based on the findings of this report, if a patient presents with OP

of unknown causes, the anti-HTLV-1 antibody test might be advisable.

## Conclusion

We report a rare case of OP as a HABA. OP as a HABA may be effectively managed with acute corticosteroid therapy; however, if stabilization of the patient's condition is not achieved, continuation of oral corticosteroid therapy might be considered.

## Declaration of patient consent

The authors certify that they have obtained all appropriate patient consent forms. In the form the patient(s) has/have given his/her/their consent for his/her/their images and other clinical information to be reported in the journal. The patients understand that their names and initials will not be published and due efforts will be made to conceal their identity, but anonymity cannot be guaranteed.

## Financial support and sponsorship

Nil.

## Conflicts of interest

There are no conflicts of interest.

## References

1. Dias AR, Falcão LF, Falcão AS, Normando VM, Quaresma JA. Human T lymphotropic virus and pulmonary diseases. *Front Microbiol* 2018;9:1879.
2. Yokohori N, Sato A, Hasegawa M, Katsura H, Hiroshima K, Takemura T. Effectiveness of combined therapy with pirfenidone and erythromycin for unclassifiable interstitial pneumonia induced by HTLV-1-associated bronchioloalveolar disorder (HABA). *Intern Med* 2017;56:73-8.
3. Yamashiro T, Kamiya H, Miyara T, Gibo S, Ogawa K, Akamine T, *et al.* CT scans of the chest in carriers of human T-cell lymphotropic virus type 1: Presence of interstitial pneumonia. *Acad Radiol* 2012;19:952-7.
4. Matsuo K, Tada S, Kataoka M, Kanehiro A, Kaneko S, Miyake T, *et al.* Bronchiolitis obliterans organizing pneumonia (BOOP) in a case of smouldering adult T-cell leukaemia. *Respirology* 2000;5:81-5.
5. Taniwaki M, Yamasaki M, Matsumoto Y, Matsumoto N, Ohashi N, Hattori N. Corticosteroid therapy for organizing pneumonia in a human T-cell lymphotropic virus type-1 carrier. *Pulmonology* 2019;25:193-5.
6. Robertson BJ, Hansell DM. Organizing pneumonia: A kaleidoscope of concepts and morphologies. *Eur Radiol* 2011;21:2244-54.
7. Jara-Palomares L, Gomez-Izquierdo L, Gonzalez-Vergara D, Rodriguez-Becerra E, Marquez-Martin E, Barrot-Cortés E, *et al.* Utility of high-resolution computed tomography and BAL in cryptogenic organizing pneumonia. *Respir Med* 2010;104:1706-11.
8. Watanabe T. Current status of HTLV-1 infection. *Int J Hematol* 2011;94:430-4.