

The adverse effects of the methoxsalen and ultraviolet A radiation on spermatogenesis in mice

Mona Farhadi¹ Ph.D., Homa Mohseni Kouchesfahani³ Ph.D., Abass Shockravi² Ph.D.,
Mosaeeforoozanfar³ Ph.D., Kazem Parivar³ Ph.D.

1. Department of Microbiology,
Karaj Branch, Islamic Azad
University, Karaj, Iran.

2. Faculty of Chemistry, Kharazmi
University, Tehran, Iran.

3. Department of Biology,
Kharazmi University, Tehran,
Iran.

Corresponding Author:

Mona Farhadi, Department of
Microbiology, Karaj Branch,
Islamic Azad University, Karaj,
Iran. P.O.Box: 31485-313

Email: monafarhadi@yahoo.com

Tel: (+98) 9122467389

Received: 24 November 2013

Revised: 16 February 2015

Accepted: 11 May 2015

Abstract

Background: Different investigation showed that 5-methoxypsoralen and 8-methoxypsoralen reduce birth rates in the rats.

Objective: In this study we worked out the effect of methoxsalen together with ultraviolet A (UVA) radiation on mature Balb/C mice spermatogenesis.

Materials and Methods: The LD50 standard was determined 160 mg/kg and the UVA dose which causes erythema was calculated 0.046 J/cm². A sub-lethal dose of 80 mg/kg of methoxsalen solution was injected intraperitoneally to mature mice and after one hour they were exposed to UVA radiation for 20 minutes. Experiments applied included methoxsalen alone, methoxsalen with UVA, UVA alone, sham group (a group received Tween 80), and control group (N=6). In all experimental groups except UVA alone group, injections were carried out, during two consecutive weeks. Serial cross sections (5 µm thickness) were prepared for morphological and histological studies. Tunica albuginea diameter, and number of type A and type B spermatogonia and histological investigation of the testes were measured.

Results: Microscopical and statistical analyses showed significant anomalies among the experimental groups compared to control and sham group. These anomalies included decrease the body weight; increase the relative testis weight; and decrease the number of spermatogonia (type A and B), primary spermatocytes, spermatids and sperms in experimental groups I and II compared to control group. Our results showed the number of spermatozoa in experimental group I was 22.6±2.12, in experimental group II was 33.6±2.05 and in control group was 44.3±2.77 (p<0.05). Moreover in some experimental groups (I and II) shrinkage of seminiferous tubules and release of primary spermatocyte and spermatids were observed to the lumen of them.

Conclusion: It is concluded from the results of this work that treatment with methoxsalen with UVA can damage and disorganize seminiferous tubules and decrease spermatogenic cells.

Key words: Methoxsalen, UVA, Abnormality, Spermatogenesis.

Introduction

Psoralens are a class of three rings, heterocyclic and planar compounds that occur naturally as secondary metabolites in various plant species (1, 2, 3, 4) Methoxsalen (8-methoxypsoralen) together with ultraviolet A (UVA) long-wave therapy (PUVA) is known to be a human carcinogen based on sufficient evidence of carcinogenicity from studies in humans. In photo chemotherapy methoxsalen and UVA (320-400 nm) are used for treatment of some epidermal proliferative disorders such as psoriasis and vitiligo (5, 6). Psoralens are

known to be toxic to a wide range of organisms (7). In the last three decades researchers were able to show that psoralens inhibit epidermal cell proliferation after UV light irradiation (6).

It has been shown that methoxsalene has toxic effects on reproductive and developmental processes (8). Studies by Diawara *et al.* (1997) showed that, oral administration of methoxsalen to male and female rats reduces birth rate significantly. Also, 200 to 400 mg/Kg dosage of methoxsalen could reduce animal weight and could change the histology of the liver, testes and adrenal (9). In 2013 it was shown that

methoxsalen decreased mean level of estrogen and progesterone significantly and it significantly reduced the number and diameter of corpus luteum and number of growing follicles (10). *Ruta graveolens* (RG) is one of the species of herbal medicinal families that use for male contraception (11, 12). Long term administration of RG can decrease the weight of genital organs, sperm motility and sexual behavior in rat (13). RG plus 8-methoxy psoralen (sodab) caused weight gain in testicle and epididym (14). These findings showed that psoralen could affect the male and female reproductive systems. Despite of the long term application of furocoumarines (methoxsalen, xanthotoxin, bergapten, isopimpinellin) in traditional medicine, the teratogenicity of methoxsalen alone or together with UV radiation is not clear yet. This study was applied to investigate the probable teratogenicity of methoxsalen on unmated male mature Balb/C mice.

Materials and methods

In an experimental study in Kharazmi University we used Methoxsalen with formula of 9-methoxy-7H-furo [3, 2-g] [1]-benzopyran-7-one that was purchased from Sigma Aldrich (Germany) and Tween 80 was used as solvent. The UVA source consisted of a L40/79k (Osram) lamp emitting 7.632×10 (w/cm) at 50 cm distance. The UVA dose which causes erythema is 0.046 J/cm^2 . Male Balb/C mice were obtained from Pasture Institute (Experimental Animal Keeping Center, Tehran, Iran) and were grown in the animal room at temperature of $22\text{-}23^\circ\text{C}$, 50-55% humidity and lighting cycle of 12-h light/12-h dark. The animals were randomly divided in three experimental, sham and control groups which all were unmated mature Balb/C mice (65 days old), 6 in each group. The LD50 standard was determined 160 mg/kg body weight and the UVA dose which causes erythema was applied (0.046 g/cm). A sub-lethal dose of 80 mg/kg methoxsalen solution was injected intraperitoneally to mature mice and after one hour the mice were exposed to UVA radiation for 20 minutes. Experimental group I received methoxsalen only; experimental group II received

methoxsalen with UVA and PUVA, while experimental group III were under UVA only. Injections were applied for two consecutive weeks. The animals of experimental groups (I, II, III) were sacrificed 48 hours after the last injection, and their testes were removed and fixed in Bouin's fixative and embedding with paraffin. Then serial cross sections ($5 \mu\text{m}$ thickness) were prepared and slides were stained with H & E solutions for morphological and histological studies (15). The following observations were recorded: initial and final male body weights, testes weights, Tunica albuginea diameter, and number of spermatogonia and histological investigation of the testes. Morphometric measurements were applied by light microscopy. Tubule diameters of 100 nearly round seminiferous tubules were measured for each testis using an ocular micrometer at 250X. Diameter averaged for each rat for statistical analysis (16). All animal-related protocols were approved by Ethical Committee at Kharazmi University, Tehran, Iran.

Statistical analysis

In all experiments, data were analyzed using SPSS (Statistical Package for the Social Sciences, SPSS Inc., Chicago, IL, USA) software, and one way ANOVA statistical method. For each variable, means were calculated at the 5% level using LSD test.

Results

The results showed that body weight reduced significantly in all experimental groups compared to the control group. Relative testes weight and the thickness of tunica albuginea, was significantly increased (Figure 1) in experimental groups I and II, while the testis volume and its length and diameter did not show significant changes (Table I). The number of type A and B spermatogonia, primary spermatocytes, spermatids and sperms were significantly reduced in all experimental groups, compared to control group (Table II). In addition, PUVA experience (experimental group I) and methoxsalen alone experience (experimental group II) showed shrinkage of seminiferous tubules, release of primary spermatocytes and sperms into the lumen, and disorganized seminiferous tubules (Figure 2).

Table I. Results of the effects of methoxsalen on the testes (mean±SE)

Groups	Body weight *	Relative testis weight**	Thickness of Tunica albuginea μm
Controls	2.35±0.57	0.774±0.03	13.7±0.63
Sham	2.17±0.71	0.779±0.03	14.74±0.66
Methoxalen (experimental group I)	-12.51±0.71	0.885±0.03	21.5±0.82
Methoxalen with UVA (experimental group II)	-11.9±1.18	0.883±0.03	31.62±0.84
UVA (experimental group III)	-1.28±0.57	0.771±0.02	19.7±0.77

* Body weight gain= (w2-w1)/w1×100: w1=animal weight before experiment, w2=animal weight after experiment and SE=standard error

** Relative testis weight =(testis weight/body weight)×100

b: Statistical difference to control group (p<0.05)

UVA: Ultraviolet A

Table II. Results of the effects of methoxsalen on the number of spermatogenic cells (mean±SE)

Groups	No. of spermatogonia	No. of spermatogonia	No. of primary	No. of	No. of
	Type A	Type B	spermatocyte	spermatid	spermatozoid
Controls	2.4±0.12	13.52±0.67	18.2±0.82	66.5±2.81	44.3±2.77
Sham	2.2±0.11	13.22±0.65	17.4±0.79	64.9±2.63	44.6±2.76
Methoxalen (experimental group I)	1.44±0.13	9.6±0.715	15.14±0.73	39.9±2.67	22.6±2.12
Methoxalen with UVA(experimental group II)	1.28±0.11	7.64±0.497	12.04±0.71	46.8±2.84	33.6±2.05
UVA (experimental group III)	1.52±0.12	10.96±0.67	16.7±0.71	49.1±1.54	38.5±2.56

b: Statistical difference to control group (p<0.05).

UVA: Ultraviolet A

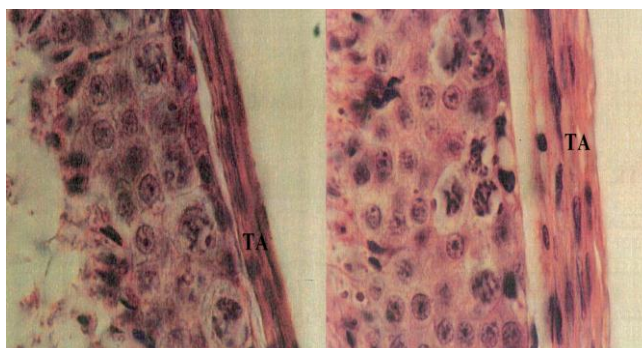


Figure 1. Photomicrograph of tunica albuginea of testis. Control (left), experimental: methoxsalen with UVA (right). The increase of tunica albuginea diameter (2500X)

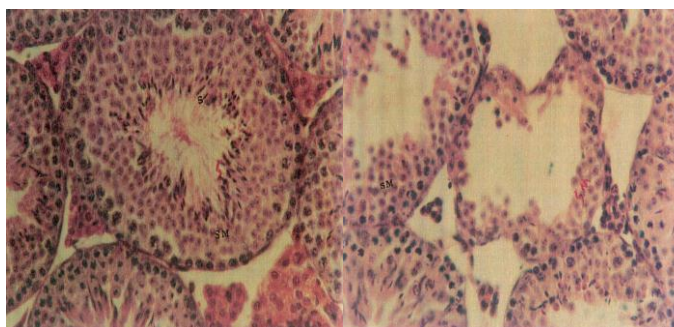


Figure 2. Photomicrograph of seminiferous tubules of testis. Control (left) experimental: methoxsalen with UVA (right). The shrank seminiferous tubule with empty lumen of sperm (1000X)

Discussion

8-methoxypsoralen (methoxsalen) with UVA (PUVA) has recovery effect on several autoimmune diseases including psoriatic arthritis, skin disorders and also reproductive system (8, 16). Despite the treatment effects of PUVA, it has photo toxicity, mutagenic and carcinogenic effects on various physiological pathways and cell components (15, 17, 18). Different studies indicated, various byproducts of methoxsalen could have toxicity effects on cell membrane or nucleic acids (19). Our findings showed, methoxsalen can affect male reproductive organs; toxicity of methoxsalen lead to decrease in the number of spermatocytes, spermatids and sperms in all experimental groups compared to control group.

In addition, PUVA induces chromosomal aberrations, sister chromatid exchanges, mutations, damage and cross-links in DNA of human cells in vitro (20). In our study, methoxsalen alone and with PUVA showed significant decrease in the mice body weight. This decrease in the body weight showed that methoxsalen can act as an important repressor for cell division. Thus, the interaction of PUVA with different parts of the cell such as DNA results in decreasing normal development. Investigation of the in vitro interaction between DNA-methoxsalen in darkness resulted in two mechanisms for DNA-methoxsalen binding: in low dosage methoxsalen intercalates with DNA whereas in high dosage methoxsalen remains out of the DNA molecule (21). Our result showed that intraperitoneal administration of 80mg/kg of methoxsalen for two weeks results in significant decrease in body weight and the number of spermatogenic cells specifically spermatids and spermatozooids. This finding could be due to interaction between methoxsalen-DNA which leads to chromosomal aberrations in low dosage and short period of time.

Sufficient evidences for carcinogenicity of methoxsalen and UVA on experimental animals exist. Methoxsalen applied by oral, intraperitoneal administration and skin application in combination with ultraviolet radiation induced epidermal and dermal tumors in the mice (19). Increase in relative testis weight and diameter of tunica albuginea only in experimental groups I and II could be

as a results of anti-apoptotic and tumor induction effects of methoxsalen. Whereas, this increase in experimental group III compared to control group was not significant; one reason for this result could be because of accumulative side effects of UVA together with methoxsalen that needs further investigation.

Methoxsalen induces liver enzyme mRNA, cytochrome P4501A1 and UDP-glucuronosyltransferase1A6, suggesting enhancement of metabolism of estrogen. Thus, methoxsalen treatment may explain the reproductive toxicity including reduction of ovarian follicular function and ovulation, effect on pituitary-gonad axis, and ovarian function (9, 10) Mated females treated by methoxsalen require more time to become pregnant and mated males treated by methoxsalen need more breeding attempts (12). This finding showed that the methoxsalen has effects on both males and females. Our results for experimental group I and II showed shrinkage and disorganize in seminiferous tubules and release of primary spermatid cells, while there was not any change in group III. This result indicated the effect of methoxsalen on pituitary axis. *Ruta graveolens* L. (RG) contains various types of secondary metabolites including coumarins, furanocoumarins (methoxsalen, xanthotoxin, bergapten and isopimpinellin). The studies of RG showed a significant decrease in the number of spermatogonia type A and B, primary spermatocyte, spermatid, and sperm in the experimental groups as a result of methoxsalen (14). Although these results are compatible with our results, our data were obtained in lower dose and shorter time (80mg/kg and 2 weeks) compared to RG result (300 mg/kg and 100 days). It showed that adverse effects of methoxsalen even start with low dose and in the short time.

Another study showed that treated males Wistar rats had significantly smaller pituitary glands, fewer sperm per ejaculation, and fewer sperm in the vasa deferentia and epididymis than control (9); methoxsalen has specific effect on sperm concentration and reproductive ability by inducing CREM gene expression (13). Our results showed only methoxsalen and PUVA decrease spermatogenic cells and body weight. Thus, effect of methoxsalen on pituitary-gonad axis could result in decrease of spermatogenic

cells and seminiferous disorganization. In addition, adverse effects of methoxsalen on nucleic acids, cell division or cell death in all spermatogenic cells could be another reason for decreasing spermatogenic cells. We conclude that both methoxsalen and PUVA have toxic effects on the spermatogenesis and all spermatogenic cells. Significant difference between the numbers of spermatozoa was not observed in groups I and II.

Moreover, our results showed that releases of primary spermatocytes and spermatids into the lumen of seminiferous tubules lead to the adverse effects of methoxsalen on spermatogenesis. Our previous research on effects of methoxsalen on oogenesis showed significant difference in long term treatment compared to short term treatment. For instance, increase in diameter of graafian follicle was observe only in short term treatment (22). Thus, investigating short term and long term effects of methoxsalen on spermatogenesis is another important fact to be considered in future researches. For a better understanding of side effects of methoxsalen on reproductive system, it is important to investigate whether the toxic effects of methoxsalen on spermatogenesis is temporary or permanent. This is essential to understand if methoxsalen side effects will reverse when the treatment has stopped. More studies about exact mechanism (s) of this compound on Sertoli cells are needed.

Conclusion

We conclude, that administration of methoxsalen together with UVA radiation can damage the spermatogenic germ cells in mice, disorganize seminiferous tubules, decrease spermatogenic cells, decrease body weight and increase diameter of tunica albuginea.

Acknowledgments

We express our best attitude to the vice chancellor of Kharazmi University for providing us research facilities and grant.

Conflict of interest

There is no conflict to of interest in this article.

References

1. Stern RS, Nichols KT, Väkevä LH. Malignant melanoma in patients treated for psoriasis with methoxsalen (psoralen) and ultraviolet A radiation (PUVA). *J Engl Med* 1997; 336: 1041-1045.
2. McDermott DC, Hoyer PB, Diawara MM. Morphological evidence of 8-MOP-induced apoptosis in rat ovary. *J Toxin Reviews* 2003; 22: 701-708.
3. Kaur P, Arora R, Gill N. Review on oxygen heterocycles. *Indo American J of Pharmaceutical Research* 2013; 3: 9067-9084.
4. Shockravi A, Valizadeh H, Heravi MM. A one-pot and convenient synthesis of coumarins in solventless system. *Phosphorus Sulfur and Silicon* 2003; 178: 501-504.
5. Brickl R, Schmid J, Koss F. Clinical pharmacology of oral psoralen drugs. *Photo-dermatol* 1984; 1: 174-186.
6. Zarebska Z, Waszkowska E, Caffieri S, Dall'Acqua F. PUVA (psoralen+ UVA) photochemotherapy: processes triggered in the cells. *Il Farmaco* 2000; 55: 515-520.
7. Roelandts R. Mutagenicity and carcinogenicity of methoxsalen plus UV-A. *Arch dermatol* 1984; 120: 662-669.
8. Laufersweiler MC, Gadagbui B, Baskerville-Abraham IM, Maier A, Willis A, Scialli AR, et al. Correlation of chemical structure with reproductive and developmental toxicity as it relates to the use of the threshold of toxicological concern. *Regul Toxicol Pharmacol* 2012; 62: 160-182.
9. Diawara MM, Chavez KJ, Simpleman D, Williams DE, Franklin MR, Hoyer PB. The psoralens adversely affect reproductive function in male wistar rats. *Reprod Toxicol* 2001; 15: 137-144.
10. Fattahi E, Jorsaraei SGA, Gardaneh M, Marzony ET. The Effect of 8-Methoxypsoralen on Pituitary-Gonad Axis and Ovarian Function in Mice. *Cell J* 2013; 15: 206.
11. Bazrafkan M, Sobhani A. Study of Spermatogenesis in Wistar Adult Rats Administrated to Long Term of Ruta Graveolens. *Jentashapir J Health Research* 2014; 5: e21870.
12. Sailani M, Moeini H. Effect of Ruta graveolens and Cannabis sativa alcoholic extract on spermatogenesis in the adult wistar male rats. *Indian J Urol* 2007; 23: 257.
13. Yang WM, Chang MS, Park SK. Effects of Psoralea corylifolia on the cAMP-responsive element modulator (CREM) expression and spermatogenesis in rats. *J Ethnopharmacol* 2008; 117: 503-506.
14. Khouri NA, El-Akawi Z. Antiandrogenic activity of Ruta graveolens L in male Albino rats with emphasis on sexual and aggressive behavior. *Neuro Endocrinol Lett* 2005; 26: 823-829.
15. Liu D, Fernandez BO, Hamilton A, Lang NN, Gallagher JM, Newby DE, et al. UVA irradiation of human skin vasodilates arterial vasculature and lowers blood pressure independently of nitric oxide synthase. *J Invest Dermatol* 2014; 134: 1839-1846.
16. Menter A, Korman NJ, Elmets CA, Feldman SR, Gelfand JM, Gordon KB, et al. Guidelines of care for the management of psoriasis and psoriatic arthritis: section 6. Guidelines of care for the treatment of psoriasis and psoriatic arthritis: case-based

- presentations and evidence-based conclusions. *J Am Acad Dermatol* 2011; 65: 137-174.
17. Neuner P, Charvat B, Knobler R, Kirnbauer R, Schwarz A, Luger TA, et al. Cytokine release by peripheral blood mononuclear cells is affected by 8-methoxypsoralen plus UV-A. *Photochem Photobiol* 1994; 59: 182-188.
 18. Stern RS, Bagheri S, Nichols K, Study PFU. The persistent risk of genital tumors among men treated with psoralen plus ultraviolet A (PUVA) for psoriasis. *J Am Acad Dermatol* 2002; 47: 33-39.
 19. Allanson M, Domanski D, Reeve VE. Photoimmunoprotection by UVA (320–400 nm) radiation is determined by UVA dose and is associated with cutaneous cyclic guanosine monophosphate. *J Invest Dermatol* 2006; 126: 191-197.
 20. Schoonderwoerd S, van Henegouwen GB, Persons C, Caffieri S, Dall'Acqua F. Photobinding of 8-methoxypsoralen, 4, 6, 4'-trimethylangelicin and chlorpromazine to Wistar rat epidermal biomacromolecules in vivo. *J Photochem Photobiol B: Biology* 1991; 10: 257-268.
 21. Arabzadeh A, Bathaie S, Farsam H, Amanlou M, Saboury A, Shockravi A, et al. Studies on mechanism of 8-methoxypsoralen–DNA interaction in the dark. *Inte J pharm* 2002; 237: 47-55.
 22. Farhadi M, Fattahi E, Kouchesfahani HM, Shockravi A, Parivar K. The Adverse Effects of Methoxsalen on the oogenesis of Balb/C Mice. *Cell J* 2014; 15: 348.