

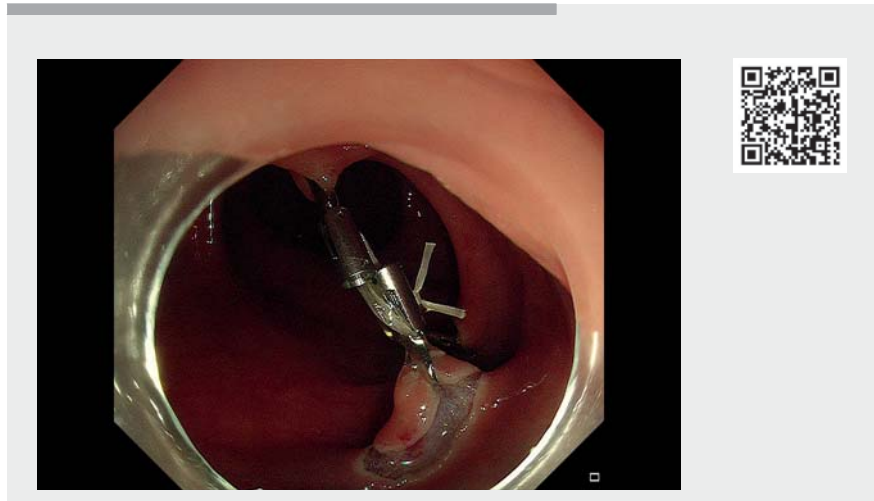
Traction by dental floss loop for adequate submucosal dissection depth in a rectal neuroendocrine tumor



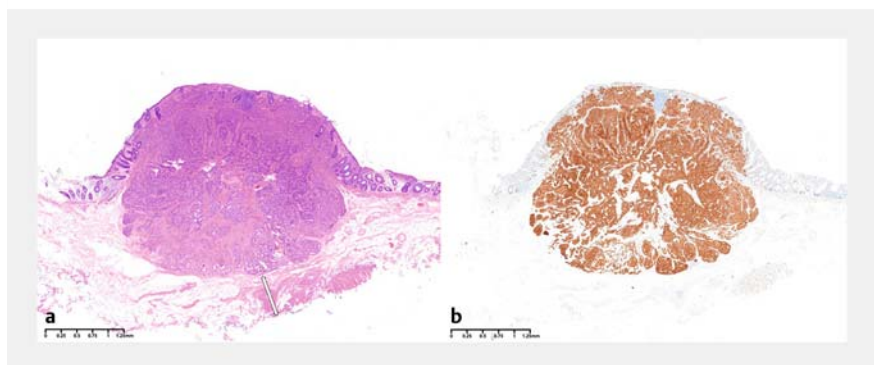
The European Society of Gastrointestinal Endoscopy (ESGE) recommends modified EMR (mEMR) as the first option for removing rectal neuroendocrine tumors (rNETs), since mEMR was shown to be superior to endoscopic submucosal dissection (ESD) for histological complete resection [1,2]. In rNETs, deep mucosa and submucosa are involved, and therefore adequate submucosal dissection depth is essential to achieve complete resection. A loop of dental floss has been previously reported to enable proper access to the submucosal layer and could potentially be useful for achieving deeper resection in ESD [3]. We present a case of a small rNET successfully treated by loop-traction-assisted ESD (▶ **Video 1**).

A subepithelial lesion 4 mm in size was detected in the lower rectum of a 38-year-old woman. ESD was decided on based on the suspected diagnosis of neuroendocrine tumor. After circumferential mucosal incision, a loop made from dental floss was fixed to the anal edge of the resected lesion and to the opposite rectal wall using clips to provide traction. Dissection close to the muscularis propria was achieved without complications. Histological analysis showed a neuroendocrine tumor (grade 1) with tumor-free lateral and vertical margins (▶ **Fig. 1**). Adequate submucosal dissection depth was achieved with a 710- μ m distance from the lesion edge to the vertical resection margin.

To achieve adequate submucosal resection depth, EMR with ligation utilizes suction, which has poor control on horizontal and vertical margins; where submucosal fibrosis is substantial, it may fail. Hybrid ESD is like conventional ESD: circumferential incision and trimming are still needed, and the resection depth would not be improved over traditional EMR unless proper traction is used [4]. We have described how loop traction could be useful in improving the dissec-



▶ **Video 1** Traction-assisted endoscopic submucosal dissection using a dental floss loop for the removal of a small rectal neuroendocrine tumor.



▶ **Fig. 1** Small rectal neuroendocrine tumor in a 38-year-old woman: histological assessment of specimen resected by loop-traction-assisted endoscopic submucosal dissection. **a** The resected specimen showed a tumor-free horizontal and vertical margin with a distance of 710 μ m from the lesion edge to the vertical resection margin. **b** Tumor tissue was outlined by immunohistochemical staining using synaptophysin.

tion depth of ESD, which could in turn improve the outcome of patients with rNETs.

In conclusion, traction-assisted ESD which enables deeper dissection could be effective in the management of rNETs. Further comparative studies are warranted.

Endoscopy_UCTN_Code_TTT_1AQ_2AD

Competing interests

The authors declare that they have no conflict of interest.

The authors

Jianning Liu¹, Nian Fang^{2,3}

- 1 School of Queen Mary, Nanchang University, Nanchang, P. R. China
- 2 Third Clinical Medical College, Nanchang University, Nanchang, P. R. China
- 3 Department of Gastroenterology, The First Hospital of Nanchang (The Third Affiliated Hospital of Nanchang University), Nanchang, P. R. China

Corresponding author

Nian Fang, MD

Third Clinical Medical College, Nanchang University, Xiangshan North Road 128, 330009, Nanchang, P. R. China
fangnian_ncu@163.com

References

- [1] Zhang HP, Wu W, Yang S et al. Endoscopic treatments for rectal neuroendocrine tumors smaller than 16 mm: a meta-analysis. *Scand J Gastroenterol* 2016; 51: 1345–1353. doi:10.1080/00365521.2016.1200140
- [2] Zheng JC, Zheng K, Zhao S et al. Efficacy and safety of modified endoscopic mucosal re-

section for rectal neuroendocrine tumors: a meta-analysis. *Z Gastroenterol* 2020; 58: 137–145. doi:10.1055/a-1062-8897

- [3] Chen PJ, Chu HC, Chang WK et al. Endoscopic submucosal dissection with internal traction for early gastric cancer (with video). *Gastrointest Endosc* 2008; 67: 128–132. doi:10.1016/j.gie.2007.07.021
- [4] Nasu T, Esaki M, Shoguchi Y et al. Traction-assisted hybrid endoscopic submucosal dissection for small rectal neuroendocrine tumors. *Endoscopy* 2022; 54: E550–E551. doi:10.1055/a-1662-4965

Bibliography

Endoscopy 2023; 55: E326–E327
DOI 10.1055/a-1974-9297
ISSN 0013-726X
published online 13.12.2022
© 2022. The Author(s).

This is an open access article published by Thieme under the terms of the Creative Commons Attribution-NonDerivative-NonCommercial License, permitting copying and reproduction so long as the original work is given appropriate credit. Contents may not be used for commercial purposes, or adapted, remixed, transformed or built upon. (<https://creativecommons.org/licenses/by-nc-nd/4.0/>)
Georg Thieme Verlag KG, Rüdigerstraße 14, 70469 Stuttgart, Germany



ENDOSCOPY E-VIDEOS

<https://eref.thieme.de/e-videos>



Endoscopy E-Videos is an open access online section, reporting on interesting cases and new techniques in gastroenterological endoscopy. All papers include a high quality video and all contributions are freely accessible online. Processing charges apply (currently EUR 375), discounts and waivers acc. to HINARI are available.

This section has its own submission website at <https://mc.manuscriptcentral.com/e-videos>