



# Implant-supported overdentures with different bar designs: A retrospective evaluation after 5-19 years of clinical function

Sven Rinke<sup>1,2</sup>, Hajo Rasing<sup>1</sup>, Nikolaus Gersdorff<sup>1</sup>, Ralf Buegers<sup>1</sup>, Matthias Roediger<sup>1\*</sup>

<sup>1</sup>Department of Prosthodontics, Georg-August-University, Goettingen, Germany

<sup>2</sup>Private Practice, Hanau, Germany

**PURPOSE.** This retrospective study evaluated the outcome of implant-retained overdentures (IODs) after 5-19 years of clinical function. **MATERIALS AND METHODS.** A retrospective analysis of patient files was performed referring to 27 patients who received 36 IODs with 3 different bar designs (group A=prefabricated round bars, n=7; group B=one-piece anterior milled bars, n=20; and group C=two bilaterally placed milled bars, n=9) in the mandible (n=24) and/or in the maxilla (n=12). The analysis focused on the survival and success rates (according to Kaplan-Meier) of the implants and prostheses. Technical complication rates for each type of restoration were analyzed and compared via one-way ANOVA and the Chi-squared test. The prevalence of peri-implantitis (radiographic bone loss  $\geq 3.5$  mm) was evaluated by digital analysis of panoramic radiographs taken post-operative (baseline) and after 5-19 years of clinical function (follow-up). **RESULTS.** The mean observational time was 7.3 years. The survival rates of the prostheses and implants were 100% and 97.7%, respectively. Technical complications occurred more frequently in group A (mean: 3.5 during observational time) than in the other two groups (B: 0.8; C: 1.0). However, this difference was not statistically significant ( $P=0.58$ ). Peri-implantitis was diagnosed for 12.4% of the implants in 37% of the patients. **CONCLUSION.** Bar-retained IODs are an adequate treatment option for edentulous jaws. These restorations may exhibit high implant/prosthesis survival rates (>97%), and a limited incidence of technical complications after a mean observational period of >7 years. Nevertheless, peri-implantitis was identified as a frequent and serious biological complication for this type of reconstruction. [*J Adv Prosthodont 2015;7:338-42*]

**KEY WORDS:** Bar-retained overdentures; Implants; Marginal bone level; Radiographic; Peri-implantitis

## INTRODUCTION

Bar-retained implant overdentures (IODs) are a common treatment option in implant prosthodontics, and the implants that support the prosthetic restorations exhibit

high survival rates.<sup>1-3</sup> It has been discussed controversially if the number of implants or a placing of extensions on bars influence the clinical outcome of IODs.<sup>4-8</sup> However, the data on the prevalence of biological complications remains limited.<sup>9,10</sup> It has been proven that the bone resorption for IODs on prefabricated bars is lower in comparison with IODs on cast bars.<sup>11</sup> In contrast, a systematic review demonstrated similar bone loss around implants supporting IODs with different attachment designs.<sup>12</sup> This retrospective study examined the survival and success rates as well as the prevalence of peri-implantitis of IODs retained by 3 different bar designs.

## MATERIALS AND METHODS

This study is based on patient files from the departments of Maxillofacial Surgery and Prosthodontics of the University

Corresponding author:  
Matthias Roediger  
Department of Prosthodontics, Georg-August-University, Goettingen,  
Robert-Koch-Str. 40, 37075 Goettingen, Germany  
Tel. 49 551 39 14034; e-mail, matthias.roediger@med.uni-goettingen.de  
Received March 25, 2015 / Last Revision July 29, 2015 / Accepted August 5, 2015

© 2015 The Korean Academy of Prosthodontics  
This is an Open Access article distributed under the terms of the Creative Commons Attribution Non-Commercial License (<http://creativecommons.org/licenses/by-nc/3.0>) which permits unrestricted non-commercial use, distribution, and reproduction in any medium, provided the original work is properly cited.

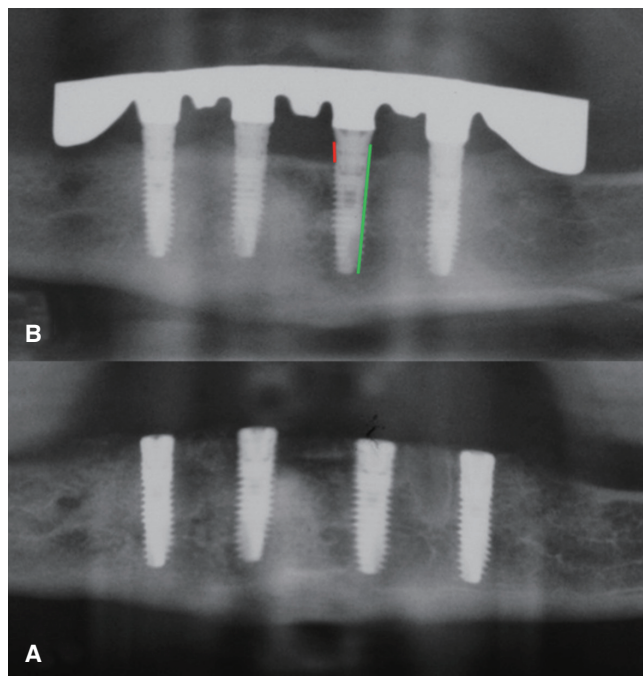
Medical Center Goettingen. It was approved by the local ethics committee (approval no. 1/9/09). Twenty-seven patients (16 female, 11 male) were treated between 1991 and 2006 with IODs (n=36) that were retained by 3 different bar designs (group A=prefabricated round bars without extensions, resilient anchorage, n=7; group B=one-piece anterior milled bars with distal extensions, rigid anchorage, n=20; and group C=two bilaterally placed milled bars, with distal extensions, rigid anchorage, n=9) on 4 to 6 implants (2 - 3 per side) (n=161, mean: 4.5 per jaw) in the mandible (n=24) and/or in the maxilla (n=12).

Inclusion criteria for the study were in compliance with annual recall intervals, a post-operative (baseline) panoramic radiograph, and at least one follow-up panoramic radiograph after a minimum observational period of 5 years (mean:  $7.3 \pm 3.6$  years; range: 5-19 years). Furthermore, the complete documentation of all implant- and prosthesis-related technical complications was mandatory for inclusion in the study. All radiographs were digitally analyzed (Adobe Photoshop CS4, San Jose, CA, USA). Calibration was performed by referencing the documented implant length. The marginal bone levels were calculated on the basis of the radiographic linear distance from the implant shoulder to the first bone-to-implant contact (Fig. 1). Radiographic bone loss during the functional period was calculated by subtracting the linear distance from the implant shoulder to the marginal bone level at baseline from the distance from the implant shoulder to the marginal bone level at the last available radiograph.

Bone loss  $\geq 3.5$  mm was defined as “peri-implantitis”.<sup>9,10,13</sup> Furthermore, all prosthodontic maintenance was recorded for the survival and success analysis according to Kaplan-Meier. Technical complication rates for each type of restoration were analyzed and compared via one-way ANOVA and the Chi-squared test (Software R version 2.8, www.r-project.org). A type one error of  $<0.05$  was accepted as statistical significance.

## RESULTS

Two implants (one in the maxilla after 7 years and one in the mandible after 6 years) had to be removed (7-year survival rate: 97.7%). All IODs remained in function (7-year survival rate: 100%). In total, 70 of the technical complica-

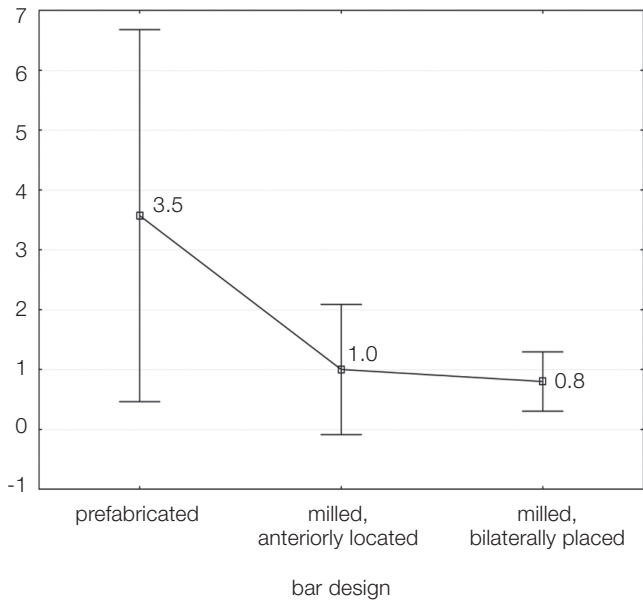


**Fig. 1.** Measurement of radiographic bone loss. (A) Baseline after implant insertion, (B) After 5 years of clinical function. The implant length is marked for calibration (green line), and the highest bone loss at implant 032 (mesial site, red line) is also marked.

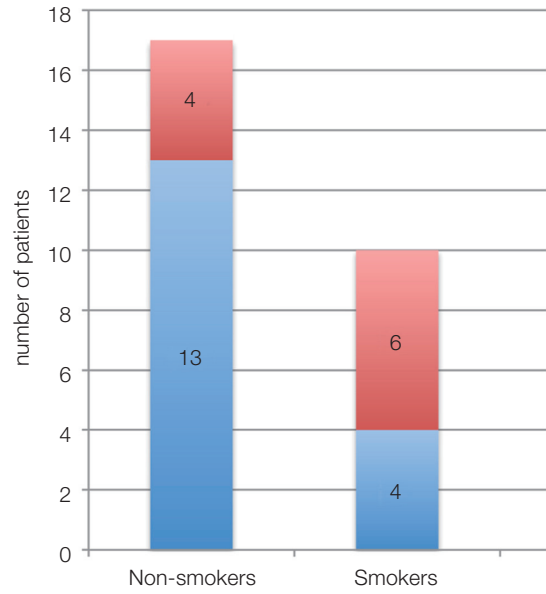
tions (attachment-related: 49%, denture-related: 51%) required clinical intervention to maintain the function of the IODs (overall technical complication rate: 0.37 treatments per patient per year (T/P/Y)), (Table 1). Technical complications occurred more frequently in group A (mean: 3.5 during observational time) than in the other two groups (B: 0.8: C: 1.0). However, this difference was not statistically significant ( $P=0.58$ , Fig. 2). The success rates (Kaplan-Meier) which represent the share of IODs that were functional without any clinical intervention are presented in Fig. 3. Peri-implantitis was diagnosed in 20 implants (12.4%), in 12 IODs (3 in the maxilla, 9 in the mandible) (A: 2; B: 9; C: 1) in 10 of 27 patients (37%). Six of the 10 smokers (60%) that participated in the study, and 4 of the 17 non-smokers (23.5%) were diagnosed with peri-implantitis (Fig. 4).

**Table 1.** Technical complications of implant-retained overdentures with 3 different bar designs

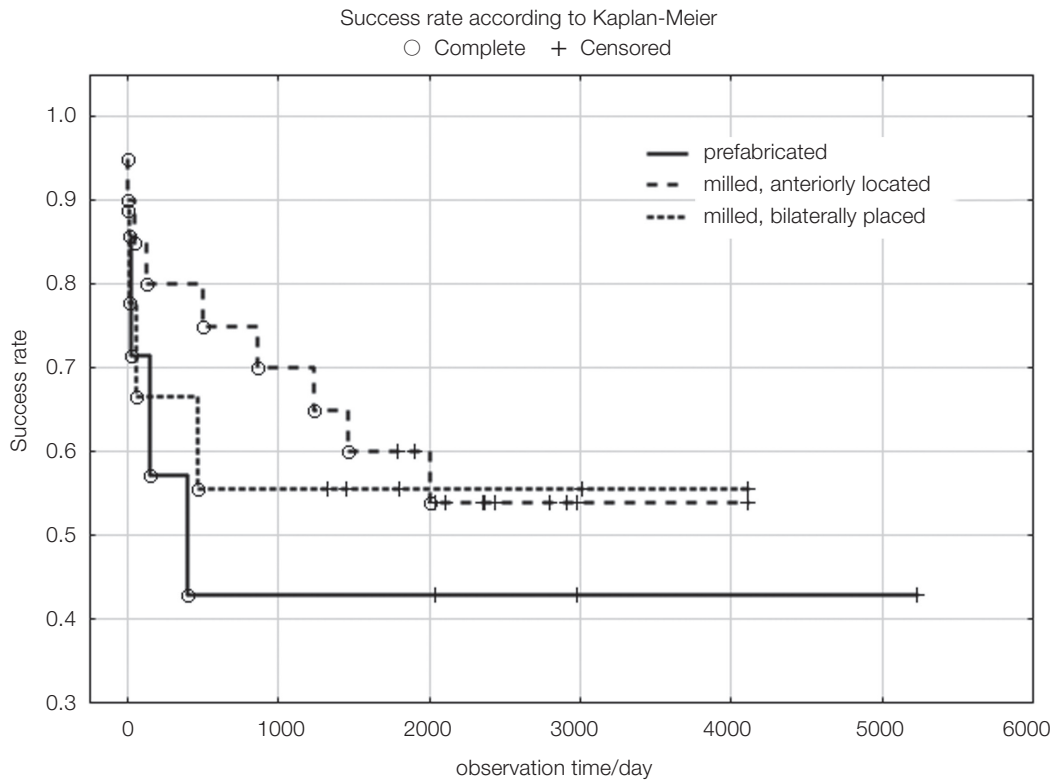
Complication	Bar design		
	Prefabricated round (n=7)	Milled, anteriorly located (n=20)	Milled, bilaterally placed (n=9)
Screw (loosening, fracture)	3	1	0
Bar (fracture, retention/friction loss, TK Snap renewal)	22	5	3
Denture (crack/fracture repair, relining, tooth renewal)	18	11	7



**Fig. 2.** Number of technical complications according to the bar design (means with 95% confidence intervals) after a 7.3-year mean observation time.



**Fig. 4.** Distribution of peri-implantitis (red fraction) in non-smokers (4/17=23.5%) and smokers (6/10=60%).



**Fig. 3.** Success rates (Kaplan Meier analysis) of implant-retained overdentures with 3 different bar designs after a 7.3-year mean observation time.

## DISCUSSION

The implant (97.7%) and prosthetic (100%) survival rates are similar to the findings reported by other studies.<sup>1-3</sup> In literature, the requirements for prosthetic maintenance of IODs vary between 0.25 and 4.03 (T/P/Y).<sup>1-3,10</sup> The overall technical complication rate of 0.37 (T/P/Y) that was calculated in the present study is at the lower end of this range, it is similar to other studies that reported technical complications of bar-retained IODs.<sup>1,2</sup> In the present study, IODs that were retained by milled bars exhibited rather lower but statistically insignificant rates of mechanical complications in comparison with IODs retained by prefabricated round bars. Nevertheless, this is similar to previous studies that reported lower technical complication rates for milled bars than that of prefabricated round bars.<sup>1,2</sup> Krennmair *et al.*<sup>6</sup> (2012) demonstrated high implant success rates and limited prosthodontic maintenance for rigid anchoring with milled bars or telescopic attachments. In this study, bar-related complications predominantly appeared for prefabricated round bars, whereas IODs retained by milled bars showed more denture-related complications. Bressan *et al.*<sup>14</sup> (2012) also demonstrated mainly bar-related complications for IODs retained by round bars supported by two implants. Alternatively, Heschl *et al.*<sup>15</sup> (2013) documented only limited complication rates for round bars supported by 4 implants with distal extensions. Other authors controversially discussed whether the number of implants and/or the use of extensions have an impact on the complication rates of IODs. Ueda *et al.*<sup>8</sup> (2011) and Meijer *et al.*<sup>7</sup> (2009) found no differences between IODs supported by 2 or 4 implants. However, Krennmair *et al.* (2007 & 2012) demonstrated prevention of non-axial overloading, posterior bone resorption or denture rotation for bar-structures rigidly retained by 4 implants.<sup>5,7</sup> Moreover, up to now, the relevance of extensions regarding the complication rates of IODs seems indistinct. Placing cantilevers on bars was rated useful to offer adequate occlusal posterior support.<sup>4</sup> However, Krennmair *et al.*<sup>5</sup> (2007) showed that distal extensions included in their bars affected neither the degree of distal bone loss nor the implant survival rate. Nevertheless, in the present study round bars on 2 implants without extensions offered higher complication rates than milled bars on 4 implants including distal extensions.

In the present study, 12.4% of the implants in 37% of the patients exhibited radiographic symptoms of peri-implantitis. Studies using the same diagnostic criteria have reported implant-based peri-implantitis rates between 10.1-11.7%, and patient-based peri-implantitis rates of 9.2-10.0% for mean observational periods of 5.6-7 years.<sup>9,10</sup> The bar design might explain the comparatively high peri-implantitis rates in the present study. It may lead to a reduced accessibility for oral hygiene procedures at home.<sup>10</sup> IODs retained by milled bars exhibited significantly higher plaque index values than IODs retained by telescopic crowns.<sup>6</sup> In the present study, especially massive one-piece milled bars in the mandible showed radiological symptoms

of peri-implantitis (9 out of 20, however, the rates were not statistically significant). Abd El-Dayem *et al.*<sup>11</sup> (2009) demonstrated less bone resorption for IODs supported by round bars compared to custom-made bars. In the present study, smoking patients exhibited a higher prevalence of peri-implantitis than non-smoking patients (60% vs. 23.5%), thus supporting data from previous studies suggesting that a smoking habit is a significant risk factor for the development of peri-implant diseases.<sup>9</sup>

## CONCLUSION

Within the limitations of this study, we concluded that bar-retained IODs are an adequate treatment option for edentulous jaws. These restorations may exhibit high implant and prosthesis survival rates (>97%) and a limited incidence of technical complications after a mean observational period of >7 years. Nevertheless, peri-implantitis was identified as a frequent and serious biological complication for this type of reconstruction.

## ORCID

Sven Rinke <http://orcid.org/0000-0003-3804-6410>

Ralf Buegers <http://orcid.org/0000-0002-6320-4348>

Matthias Roediger <http://orcid.org/0000-0002-8615-5147>

## REFERENCES

1. Krennmair G, Krainhöfner M, Piehslinger E. The influence of bar design (round versus milled bar) on prosthodontic maintenance of mandibular overdentures supported by 4 implants: a 5-year prospective study. *Int J Prosthodont* 2008;21: 514-20.
2. Krennmair G, Piehslinger E. Removable implant-supported maxillary prostheses anchored on milled bars: a retrospective evaluation of two concepts. *Int J Prosthodont* 2009;22:576-8.
3. Andreiotelli M, Att W, Strub JR. Prosthodontic complications with implant overdentures: a systematic literature review. *Int J Prosthodont* 2010;23:195-203.
4. Brosky ME, Koriath TW, Hodges J. The anterior cantilever in the implant-supported screw-retained mandibular prosthesis. *J Prosthet Dent* 2003;89:244-9.
5. Krennmair G, Krainhöfner M, Piehslinger E. Implant-supported mandibular overdentures retained with a milled bar: a retrospective study. *Int J Oral Maxillofac Implants* 2007;22:987-94.
6. Krennmair G, Sütö D, Seemann R, Piehslinger E. Removable four implant-supported mandibular overdentures rigidly retained with telescopic crowns or milled bars: a 3-year prospective study. *Clin Oral Implants Res* 2012;23:481-8.
7. Meijer HJ, Raghoobar GM, Batenburg RH, Visser A, Vissink A. Mandibular overdentures supported by two or four endosseous implants: a 10-year clinical trial. *Clin Oral Implants Res* 2009;20:722-8.
8. Ueda T, Kremer U, Katsoulis J, Mericske-Stern R. Long-term results of mandibular implants supporting an overdenture:

- implant survival, failures, and crestal bone level changes. *Int J Oral Maxillofac Implants* 2011;26:365-72.
9. Rinke S, Roediger M, Eickholz P, Lange K, Ziebolz D. Technical and biological complications of single-molar implant restorations. *Clin Oral Implants Res* 2015;26:1024-30.
  10. Frisch E, Ziebolz D, Ratka-Krüger P, Rinke S. Double crown-retained maxillary overdentures: 5-year follow-up. *Clin Implant Dent Relat Res* 2015;17:22-31.
  11. Abd El-Dayem MA, Assad AS, Eldin Sanad ME, Mahmoud Mogahed SA. Comparison of prefabricated and custom-made bars used for implant-retained mandibular complete overdentures. *Implant Dent* 2009;18:501-11.
  12. Cehreli MC, Karasoy D, Kökat AM, Akça K, Eckert S. A systematic review of marginal bone loss around implants retaining or supporting overdentures. *Int J Oral Maxillofac Implants* 2010;25:266-77.
  13. Rinke S, Ohl S, Ziebolz D, Lange K, Eickholz P. Prevalence of periimplant disease in partially edentulous patients: a practice-based cross-sectional study. *Clin Oral Implants Res* 2011;22:826-33.
  14. Bressan E, Tomasi C, Stellini E, Sivoilella S, Favero G, Berglundh T. Implant-supported mandibular overdentures: a cross-sectional study. *Clin Oral Implants Res* 2012;23:814-9.
  15. Heschl A, Payer M, Clar V, Stopper M, Wegscheider W, Lorenzoni M. Overdentures in the edentulous mandible supported by implants and retained by a Dolder bar: a 5-year prospective study. *Clin Implant Dent Relat Res* 2013;15:589-99.