

# Adrenal incidentalomas: A collection of six interesting cases and brief review of literature

Roopal Panchani, Ashutosh Goyal, Tarun Varma, Nitinranjan Gupta, Sudhir Tripathi, Surender Kumar

Department of Endocrinology, Sir Ganga Ram Hospital, Old Rajinder Nagar, New Delhi, India

### ABSTRACT

**Introduction:** Adrenal incidentalomas (AI) are detected in approximately 4-7% of patients in imaging studies. Majority are benign, but careful evaluation is warranted to rule out carcinoma and functional adenomas. **Aim:** The purpose of presenting these cases is to highlight the approach to management of AI in terms of diagnosis, follow-up, and treatment. **Materials and Methods:** Seven patients presenting in the endocrine clinic with AI were evaluated for their presenting clinical features and investigated. **Results:** Case 1 was a 49-year-old female, with adrenal androgen secreting adrenocortical carcinoma with amenorrhoea which was mistaken as menopause. She had minimal hirsutism, which was mistaken as postmenopausal hirsutism. Case 2 was a 39-year-old male, presenting with hyperglycemia found to have Conns' syndrome with aldosterone producing adenoma on routine ultrasound. Case 3 was a 32-year-old male, presenting with gastritis and bloating, where ultrasound showed bilateral large adrenal masses revealed as diffuse large B cell lymphoma on biopsy. Case 4 was a 21-year-old boy, who had pheochromocytoma misdiagnosed as benign intracranial hypertension (HTN). Case 5 was a 59-year-old hypertensive male, presenting with fever had pheochromocytoma with catecholamine excess, producing fever. Case 6 was isolated adrenal tuberculosis who presented with chronic diarrhea. **Conclusion:** AI are common, though prevalence varies depending on the reason for scanning, the characteristics of the population studied, and the radiological techniques used. Most are non-secreting cortical adenomas. AI should be evaluated both biochemically and radiologically. When a hormonal disorder is suspected clinically, targeted, diagnostic testing for autonomous cortisol secretion, pheochromocytoma, and hyperaldosteronism is indicated.

**Key words:** Adrenal incidentalomas, Conn's syndrome, pheochromocytoma

## INTRODUCTION

We present six interesting cases of adrenal incidentalomas (AI).

Case 1 was a 49-year-old female, incidentally found to have large adrenal mass on routine ultrasound as a part of annual checkup. She had secondary amenorrhea mistaken as menopause and hirsutism mistaken as postmenopausal hirsutism. Upon surgical excision, she was found to have androgen secreting adrenocortical carcinoma (ACC).

Case 2 was a 39-year male, presenting with impaired fasting glucose found to have Conns' syndrome with aldosterone producing adenoma on routine ultrasound. Case 3 was a 32-year-old male, presenting with recurrent gastritis and bloating where ultrasound showed bilateral large adrenal masses. Biopsy revealed primary diffuse large B cell lymphoma. Case 4 was a 21-year-old boy, who was under treatment for benign intracranial HTN presented with AI and found to have had pheochromocytoma. Case 5 was a 59-year-old hypertensive male, presenting with fever found to have an AI on ultrasound done for workup of pyrexia. AI turned out to be pheochromocytoma with catecholamine excess producing fever. Case 6 was a 32-year-old female, with isolated adrenal tuberculosis who presented with chronic diarrhea.

AI is an adrenal mass of >1 cm discovered incidentally on imaging performed for unrelated reasons.<sup>[1]</sup> Prevalence ranges from 4-7%.<sup>[1]</sup> Upto 25% are functional with subclinical Cushings syndrome (SCCS) being most

#### Access this article online

##### Quick Response Code:



Website:  
www.ijem.in

DOI:  
10.4103/2230-8210.104100

**Corresponding Author:** Dr. Roopal Panchani, A/7, Rashmi Park, Near Saurabh Park, Subhanpura, Baroda, Gujarat - 390 021, India.  
E-mail: droopalpanchani@yahoo.in

common followed by pheochromocytoma, aldosterone secreting adenoma and others.

The distribution of etiology of AI depends upon the size of mass, age, and presence of malignancy.<sup>[2]</sup> In bilateral AI metastasis is common with congenital adrenal hyperplasia (CAH), lymphomas, infections, hemorrhage, Adrenocorticotrophic Hormone (ACTH) dependent cortical adenomas, infiltrative disorders, amyloidosis, and pheochromocytomas being rare.

Patients should be clinically evaluated from two perspectives: Function (hormone secretion) and possibility of malignancy. History and physical examination should focus on presence of symptoms and signs of cortisol, catecholamine, mineralocorticoid, and androgen excess and to rule out possibility of malignancy as AI can be a metastasis from primary or very rarely primary adrenal malignancy.

AI should be evaluated both biochemically and radiologically. Size of AI is of limited use because, although lesions larger than 4 cm are likely to be malignant, certain adenomas, myelolipomas, and hemorrhage into the adrenal gland rarely cause enlargement >6 cm. Lipid rich property of adenomas in comparison with malignancy is exploited in lipid sensitive imaging techniques such as attenuation value, computed tomography (CT) histogram analysis, chemical shift, dual energy CT. Perfusion techniques like contrast wash out are used.<sup>[1]</sup> MRI is as effective as CT. Functional imaging using Meta-Iodo-Benzyl-Guanidine (MIBG), fluorodeoxy glucose (FDG), F-DA or F-DOPA and NP59 are used when needed.<sup>[1]</sup>

All patients should undergo hormonal evaluation for Cushing syndrome and pheochromocytoma and hyperaldosteronism in those with HTN.<sup>[2]</sup>

SCCS is among the most controversial issue in AI. Several problems in diagnosis render the management extremely difficult.<sup>[2]</sup> Screening tests for SCCS aim at diagnosis of three pathophysiologic derangements typical of Cushing syndrome viz nonsuppressible ACTH independent the production of cortisol, (serum cortisol >5.0 mg/dl (or 1.8 mg/dl) after 1 mg dexamethasone suppression test); loss of a normal diurnal pattern, (with late night salivary cortisol >100 ng/dl); excess production of cortisol (24-h urinary free cortisol more than 100 µg/day). Surgery of SCCS leads to beneficial effect of on blood pressure, and less consistently on obesity and abnormalities in glucose metabolism.<sup>[2]</sup>

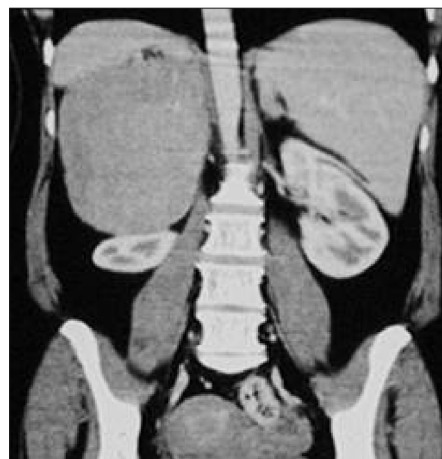
Pheochromocytoma although comparatively rare<sup>[2]</sup> needs

attention because of serious consequences associated with missed diagnosis. Patients thought to have a pheochromocytoma should undergo measurement of plasma fractionated metanephrines and normetanephrines or 24-h urinary fractionated metanephrines and catecholamines.<sup>[3]</sup> Genetic studies should be performed in an appropriate clinical background. Surgical resection should be performed in all with meticulous perioperative care.<sup>[3]</sup>

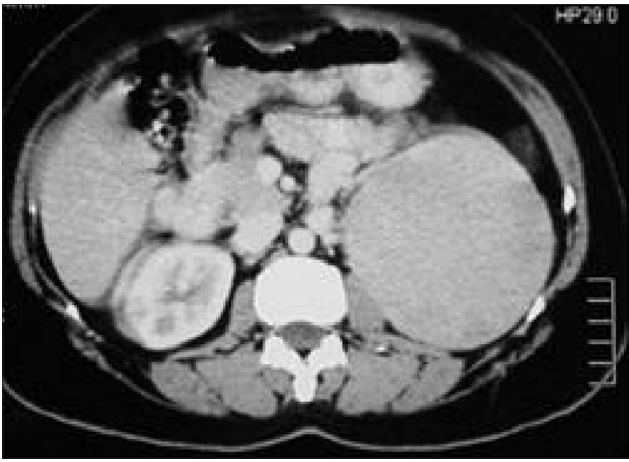
Isolated adrenal tuberculosis is extremely rare and presents with acute or chronic adrenal insufficiency.<sup>[4]</sup> CT cannot easily distinguish between isolated adrenal tuberculosis and other benign and malignant adrenal pathology. Biopsy is diagnostic. Treatment is anti-tuberculous regimen and steroid replacement.<sup>[4]</sup>

Mineralocorticoid hypersecretion comprise 1.6-3.8% of all AI.<sup>[2]</sup> In patients with HTN, serum potassium and a plasma aldosterone concentration-plasma renin activity ratio (PAC-PRA) should be measured. A PAC-PRA greater than 30 with a PAC >0.5 nmol/L is highly suggestive of autonomous aldosterone production. Primary aldosteronism is confirmed by demonstrating the lack of aldosterone suppression. Sub-type evaluation should be done.<sup>[3]</sup>

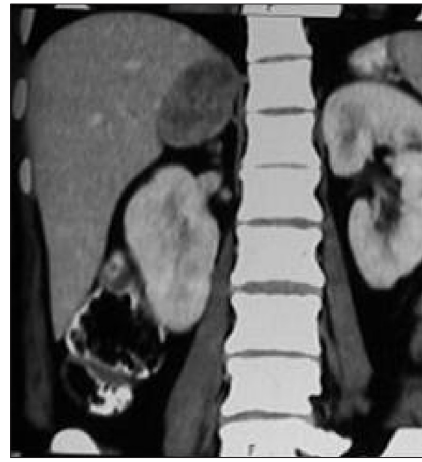
Androgen secreting ACC are rare and present with hirsutism and virilization, male pattern baldness and oligo/amenorrhea. Measurement of dehydroepiandrosterone-sulfate (DHEA-S) has been recommended. Low serum DHEA-S is used as evidence of an adrenocortical origin of the tumor. High DHEA-S is found in ACC. The value of DHEA-S in the assessment of adrenal tumors is low, because DHEA-S shows a steep age-related decrease in normal subjects with wide inter-subject variation, and some cases



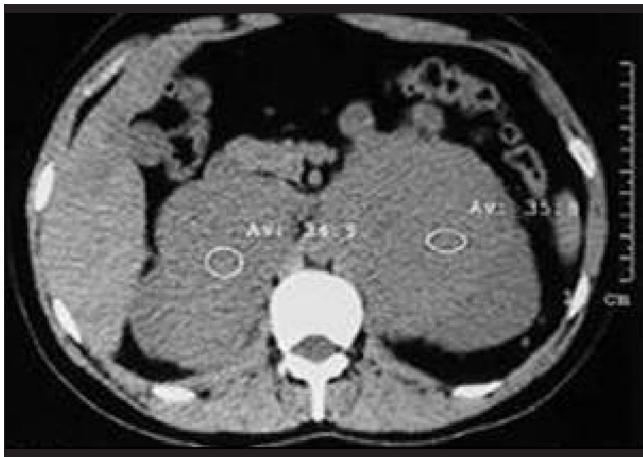**Figure 1:** Computed tomography scan showing left adrenal mass diagnosed as androgen secreting adrenocortical carcinoma



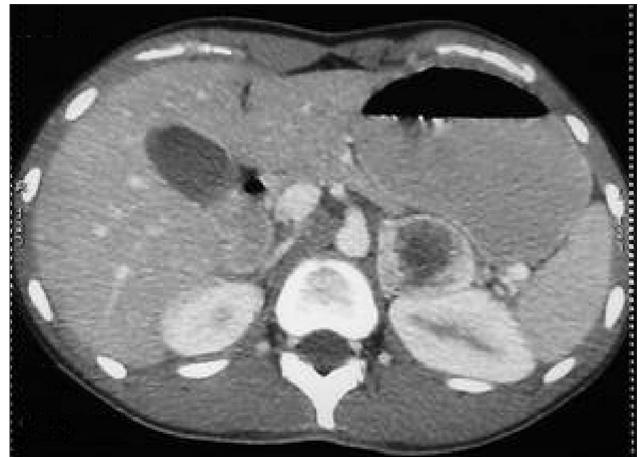**Figure 2:** Computed tomography scan with axial view of left adrenocortical carcinoma



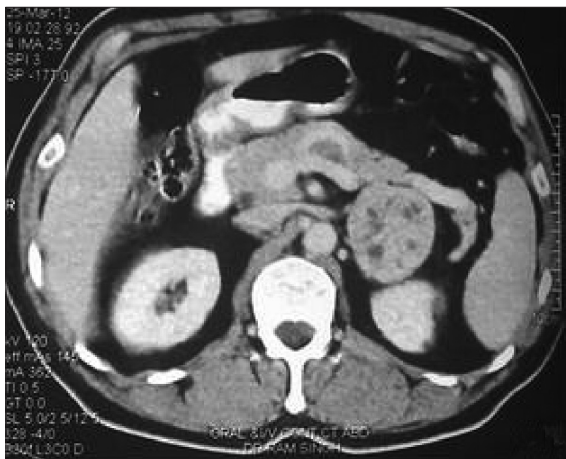**Figure 3:** Computed tomography scan showing Conn's adenoma in right adrenal



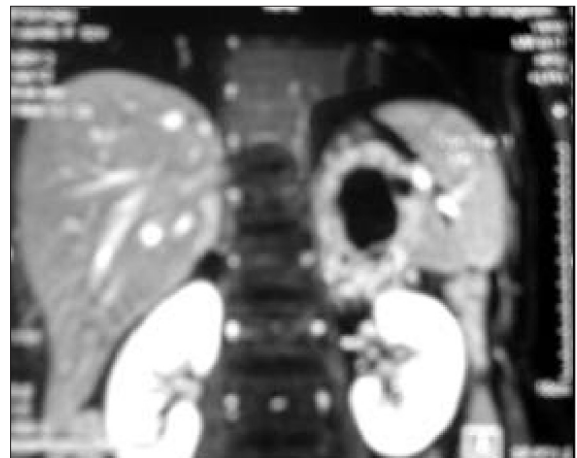
**Figure 4:** Computed tomography showing large bilateral adrenal masses



**Figure 5:** Computed tomography showing pheochromocytoma on left side



**Figure 6:** Computed tomography showing pheochromocytoma on left side with multiple renal cysts in left kidney



**Figure 7:** Computed tomography showing isolated left adrenal tuberculosis

**Table 1: Clinical data of six patients**

No.	Age	Sex	Presentation	Imaging	Hormonal evaluation*,£,€	Treatment
1.	49	F	Routine annual check up	Ultrasound followed by CT showing left adrenal homogenous mass of size 9.4×10.2×8.5 cm	DHEA-S-1799 md/dl 17-OHP-105 T-42.8 Cortisol-16.9	Surgical excision with left adrenalectomy DHEA-S, T six monthly and imaging annually
2.	39	M	IFG, HTN	CT-well defined heterogeneously enhancing hypodense mass lesion measuring 5 cm×3.8 cm×4.1 cm replacing the right adrenal gland	PAC-58.8 PRA-0.18 PAC/PRA>100 K=3.7 mg/dl Post saline loading test PAC=14.8 Cortisol 8 am-19.9	Surgical excision
3.	32	M	Vague abdominal pain, bloating	CT-homogeneously enhancing well defined bilateral adrenal masses (Rt-9.5×8.7×10.1 cm and Lt-8.5×7.9×8.6 cm)	Cortisol-19.5 Pl. MN-18.6 Pl. NMN-79.8 Ur. MN-116	Biopsy followed by chemotherapy <sup>§</sup>
4.	21	M	Headache, blurring of vision	CT-well defined mass 3.8×4.3×4.2 cm showing heterogenous internal enhancement in left adrenal	Cortisol-18.3 Pl. MN-284 Pl. NMN-496 Ur. MN-996	Surgical excision with follow-up Pl. met annually
5.	59	M	Known hypertensive with low grade fever	CT-hypodense lesion 6.5×4.2×3.9 cm in left adrenal with multiple renal cysts	Cortisol-17.6 Ur. MN-6411 Ur. NMN-4693.	Surgical excision with follow-up Pl. met annually
6.	32	F	Chronic diarrhea	CT-showing heterogenous necrotic left adrenal mass of 5.7×5.3 cm predominantly cystic	Cortisol-13.3 ACTH-48 pg/ml Pl. MN-36.7 Ur. MN-146 DHEA-S-112 PAC-26 PRA-1.8 EUS guided FNAC showing tubercular granulomas	Anti-tuberculous drugs

\*Only relevant laboratory results are displayed. Cortisol is collected at 8 am. PRA and PAC in supine position in morning. †DHEA-S: Dehydroepiandrosterone-sulfate, PAC: Plasma aldosterone concentration, PRA: Plasma renin activity, Pl. MN: Plasma metanephrines, Pl. NMN: Plasma normetanephrines, Ur. MN: 24 h urinary metanephrines, EUS: Endoscopic ultrasound, IFG: Impaired fasting glucose, HTN: Hypertension, 17-OHP: 17 hydroxy progesterone. ‡Plasma metanephrines and normetanephrines are expressed in pg/ml metanephrines (12-61) normetanephrines (18-112), Urinary metanephrines and normetanephrines are expressed in µg/24 h, metanephrines (53-341) normetanephrines (88-444), PAC expressed in ng/dl (4.5-35.4), PRA expressed in ng/ml/hr (0.6-5.0), cortisol is expressed in µg/dl (5-23), DHEA-S expressed in ng/dl (130-950), 17-OHP in ng/dl (20-70) and total testosterone in ng/dl (15-70). §Patient referred to higher center and there he expired after 3 cycles of chemotherapy. Exact details not available

of ACC have low DHEA-S. When ACC is suspected, DHEA-S, 17-hydroxyprogesterone, testosterone (in female), androstendione and estradiol (in male) is recommended.

Primary adrenal lymphoma is rare and characterized with old age, male-predominance, bilateral adrenal involvement, adrenal insufficiency, histological type of diffuse large B-cell lymphoma and grave prognosis compared to secondary adrenal involvement.<sup>[5]</sup>

To conclude, incidentally discovered adrenal masses have increased due to widespread use of imaging procedures. In patients without a known extra-adrenal primary malignancy, most of these lesions are benign non hyperfunctioning adenomas. The Plethora of various studies on imaging of AI should be interpreted cautiously as sensitivity and specificity are reported as aggregate and may not be correct in individual case. Follow-up should be structured according to size, hormonal secretion and imaging characteristics. Due consideration should be given to the cost-effectiveness of investigations and treatment.

## REFERENCES

- McDermott S, O'Connor OJ, Cronin CG, Blake MA. Radiological evaluation of adrenal incidentalomas: Current methods and future prospects. *Best Pract Res Clin Endocrinol Metab* 2012;26:21-33.
- Aron D, Terzolo M, Cawood TJ. Adrenal incidentalomas. *Best Pract Res Clin Endocrinol Metab* 2012;26:69-82.
- Zeiger MA, Thompson GB, Duh QY, Hamrahian AH, Angelos P, Elaraj D, *et al.* American Association of Clinical Endocrinologists and American Association of Endocrine Surgeons Medical Guidelines for the management of adrenal incidentalomas: Executive summary of recommendations. *Endocr Pract* 2009;15:450-3.
- Almahrezi A, Balkhair A, Al-Yaarubi S, Al Lawati H, Al Lawati F, Al-Futaisi A. Chronic adreno-cortical insufficiency associated with a unilateral adrenal mass. *Oman Med J* 2008;23:46-7.
- Ho CH, Chueh SC, Yeong-Shiau P, Chen SC, Yu HJ, Huang KH. Primary adrenal lymphoma: A rare entity with grave prognosis. *JTUA* 2009;20:168-72.

**Cite this article as:** Panchani R, Goyal A, Varma T, Gupta N, Tripathi S, Kumar S. Adrenal incidentalomas: A collection of six interesting cases and brief review of literature. *Indian J Endocr Metab* 2012;16:S378-81.

**Source of Support:** Nil, **Conflict of Interest:** None declared