

# Detection of vulnerable atherosclerotic plaque during thoracic endovascular aortic repair using nonobstructive angiography

Journal of International Medical Research

2018, Vol. 46(3) 1086–1090

© The Author(s) 2017

Reprints and permissions:

[sagepub.co.uk/journalsPermissions.nav](http://sagepub.co.uk/journalsPermissions.nav)

DOI: 10.1177/0300060517731681

[journals.sagepub.com/home/imr](http://journals.sagepub.com/home/imr)



Takashi Murakami<sup>1</sup>, Sei Komatsu<sup>2</sup>,  
Kazuhisa Kodama<sup>2</sup> and Toshihiko Shibata<sup>1</sup>

## Abstract

An angioscope was used to observe the intima of the aorta in an 82-year-old patient who had undergone thoracic endovascular aortic repair. The aortic angioscopic findings showed vulnerable plaques from the ascending aorta to the aortic arch that had not been visualized using preoperative computed tomography. After deploying a stent graft from zone 1 to zone 4, the proximal edge of the stent graft was adjacent to the ruptured plaque with mixed thrombi. In spite of these findings, the patient had an uneventful recovery. Angioscopy may have the potential to stratify the risk of thoracic endovascular aortic repair-related complications.

## Keywords

Angioscopy, thoracic endovascular aortic repair, vulnerable plaque, plaque rupture, stent graft, aortic aneurysm

Date received: 19 January 2017; accepted: 24 August 2017

## Introduction

Stroke remains an important complication of thoracic endovascular aortic repair (TEVAR) despite recent technological advances in devices.<sup>1–5</sup> Aortic angiography is reportedly a powerful modality for detecting vulnerable plaques in the aorta,<sup>6</sup> which are difficult to visualize using conventional diagnostic tools. We herein report a case of a vulnerable plaque of the

<sup>1</sup>Department of Cardiovascular Surgery, Osaka City University Graduate School of Medicine, Osaka, Japan

<sup>2</sup>Cardiovascular Center, Osaka Gyomeikan Hospital, Osaka, Japan

### Corresponding author:

Takashi Murakami, Department of Cardiovascular Surgery, Osaka City University Graduate School of Medicine, 1-4-3 Asahimachi, Abeno-ku, Osaka 545-8585, Japan.

Email: [takashimurakami24@hotmail.com](mailto:takashimurakami24@hotmail.com)



Creative Commons Non Commercial CC-BY-NC: This article is distributed under the terms of the Creative Commons Attribution-NonCommercial 4.0 License (<http://www.creativecommons.org/licenses/by-nc/4.0/>)

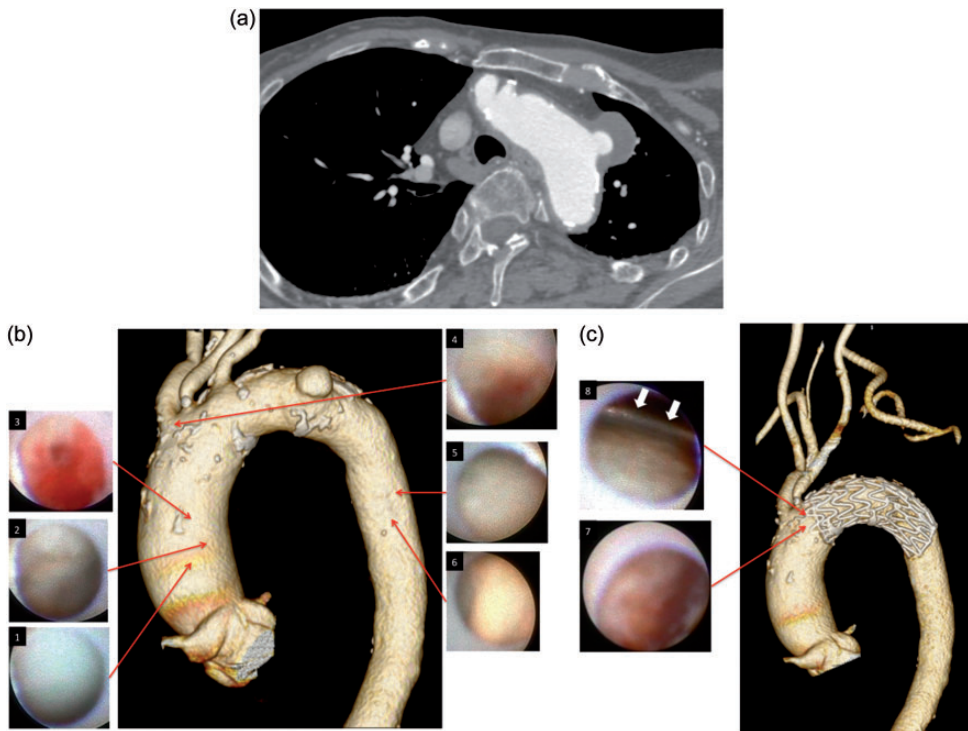
which permits non-commercial use, reproduction and distribution of the work without further permission provided the original work is attributed as specified on the SAGE and Open Access pages (<https://us.sagepub.com/en-us/nam/open-access-at-sage>).

aortic arch visualized using nonobstructive angioscopy during TEVAR. This case report highlights the potential of angioscopy and demonstrates that this approach can reveal the etiology of TEVAR-related complications or even predict the risk of adverse events.

## Case report

An 82-year-old Japanese woman presented to our institution with a distal arch saccular

aneurysm (Figure 1a). She had a history of minor stroke that had resulted in mild cognitive impairment and a nonambulatory status. She was not taking a statin, although her low-density lipoprotein cholesterol level was 141 mg/dl. Computed tomography (CT) angiography showed moderate atherosclerosis around the origin of the aneurysm but only mild atherosclerosis at the scheduled proximal landing zone and ascending aorta (Figure 1b), which was deemed acceptable for endovascular



**Figure 1.** (a) Multiplanar reconstruction computed tomography angiogram showing a saccular aneurysm at the distal aortic arch. (b) Images of nonobstructive angioscopy before stent graft deployment; corresponding locations of the images are projected onto a volume-rendered, contrast-enhanced computed tomography (CECT) image. Panel 1: Normal white surface of the aorta. Panel 2: Yellow, irregular surface. Panel 3: Ruptured plaque with mixed thrombi. Panel 4: Erosion with red thrombi. Panel 5: Yellow, irregular surface. Panel 6: Thick, protruding, yet stable yellow plaque. (c) Images of nonobstructive angioscopy after stent graft deployment; corresponding locations of the images are projected onto a postoperative volume-rendered CECT images. The left subclavian artery was coil embolized and reconstructed by carotid-axillary bypass. Panel 7: Ruptured plaque with mixed thrombi. Panel 8: Bare stent (arrows) of the Conformable Gore TAG Endoprosthesis (W.L. Gore & Associates, Flagstaff, AZ, USA) on the irregular, yellow, yet stable plaque.

repair. Therefore, zone 2 TEVAR was planned. We obtained permission from the institutional review board of Osaka City University Graduate School of Medicine to use the nonobstructive angioscopy system for observation of the aortic intima during TEVAR. This angioscopy system consisted of a VISIBLE Fiber (FiberTech Co., Ltd., Tokyo, Japan), Fiber Imaging System FT-203F (FiberTech Co., Ltd.), and Console (Intertec Medicals Co., Ltd., Osaka, Japan). Written informed consent was obtained from the patient. The patient underwent zone 2 TEVAR with concomitant left carotid–left axillary artery bypass and left subclavian artery coil embolization (Figure 1c). Before and after stent graft deployment, the aorta was observed using nonobstructive angioscopy. Details of the procedure have been reported previously.<sup>6</sup> In brief, angioscopy provides a full-color vessel surface morphology and was originally used for observation of coronary arteries. Nonobstructive angioscopy provides a visual field with the injection of low-molecular-weight dextran into the space between the 4-French probing catheter and the fiber. Low-molecular-weight dextran is also infused from a 6-French guiding catheter (dual infusion), leading to a clearer visual field even in vessels larger than coronary arteries, including the aorta. An appropriately curved guiding catheter is selected, and steering the guiding catheter enables orientation of the tip of the angioscope toward the target region on the inner surface of the aorta.

Before stent graft deployment, a white, smooth surface was observed in most parts of the ascending aorta (Figure 1b). Yellow plaques with either a smooth or an irregular surface were also found. Furthermore, plaque rupture was observed with mixed thrombi. Erosion with a red thrombus was seen proximal to the brachiocephalic artery. The area around the aneurysm was avoided with careful observation.

At the proximal descending aorta, the intima was relatively healthy; however, a yellow, irregular surface, sometimes with thick plaque formation, was a common finding. After deploying a Conformable Gore TAG Endoprosthesis (W.L. Gore & Associates, Flagstaff, AZ, USA), we focused on the site at the proximal edge of the stent graft. Immediately proximal to the graft at zone 1, the bare stent of the stent graft on an irregular yet stable yellow plaque was seen (Figure 1c). Most parts of the aortic wall at zone 1 did not have severe atherosclerosis. However, a ruptured plaque with mixed thrombi was found at the anterior aortic wall, adjacent to the bare stent. Because the impact of these findings on the patient's clinical outcomes (e.g., stroke and clinically evident embolism) was unknown, no further treatment was performed during the operation. Following the operation, the patient was extubated in the operating room. She had an uneventful recovery. Postoperative CT showed complete exclusion of the aneurysm and no evident embolism. Brain magnetic resonance imaging (MRI) showed no newly developed stroke or embolism. Strong statin therapy was initiated postoperatively because of the possibility of a pleiotropic effect at the aortic plaque.

## **Discussion**

To the best of our knowledge, this is the first report of angioscopic findings of the aortic wall during TEVAR. The findings included subtle, albeit important, alterations of the intimal surface of the aorta that were unable to be visualized by other modalities such as CT, MRI, or even intravascular ultrasound.

Previous reports have suggested that subclinical embolisms are frequently present during TEVAR. Transcranial Doppler studies have demonstrated the presence of multiple high-intensity signals

during TEVAR.<sup>7,8</sup> Furthermore, subclinical brain embolisms are a frequent finding on MRI.<sup>9</sup> However, their impact on the prognosis is unknown. Previous studies have demonstrated several risk factors for stroke, such as an aortic pathology, proximal landing zone, and atheromatous burden.<sup>1–5</sup>

Despite these facts, embolic protection is not yet fully justified given the relative scarcity of reports describing clinically evident stroke. Risk evaluation using conventional imaging modalities such as CT, MRI, and intravascular ultrasound is limited. Angioscopy may have the potential to stratify the risk of TEVAR-related complications by improving the understanding of the pathophysiology behind them, which may lead to effective preventive measures or appropriate indications for TEVAR.

The usefulness of angioscopy during open antegrade stent grafting is well recognized, as reported by Tsagakis et al.<sup>10,11</sup> It has been used for various purposes, including intraoperative evaluation of aortic diseases, such as plaques, entry/re-entry of aortic dissection, and control of stent-graft deployment. A flexible bronchovideoscope was utilized under hypothermic circulatory arrest.<sup>10,11</sup> In contrast, when performing endovascular aortic repair, the endoscopic view is obtained only when the tip of the catheter is located close to the aortic wall and blood is flushed away for a substantial period. With the currently available device, the view is limited to about 2 mm in diameter, and reproducibility to visualize the target region is not always possible. Therefore, real-time decision-making during certain procedures, such as open stent grafting, is technically challenging. However, preprocedure evaluation might help to prevent complications related to TEVAR, such as embolization and aortic dissection, through careful avoidance of lesions if possible or adoption of embolic protection measures.

## Conclusion

Angioscopy during TEVAR can be used to visualize vulnerable plaques in the aorta. This approach may have the potential to elucidate the cause of TEVAR-related complications.

## Declaration of conflicting interest

The authors declare that there is no conflict of interest.

## Funding

This research received no specific grant from any funding agency in the public, commercial, or not-for-profit sectors.

## References

1. Gutsche JT, Cheung AT, McGarvey ML, et al. Risk factors for perioperative stroke after thoracic endovascular aortic repair. *Ann Thorac Surg* 2007; 84: 1195–1200.
2. Melissano G, Tshomba Y, Bertoglio L, et al. Analysis of stroke after TEVAR involving the aortic arch. *Eur J Vasc Endovasc Surg* 2012; 43: 269–275.
3. Feezor RJ, Martin TD, Hess PJ, et al. Risk factors for perioperative stroke during thoracic endovascular aortic repairs (TEVAR). *J Endovasc Ther* 2007; 14: 568–573.
4. Chung J, Kasirajan K, Veeraswamy R, et al. Left subclavian artery coverage during thoracic endovascular aortic repair and risk of perioperative stroke or death. *J Vasc Surg* 2011; 54: 979–984.
5. Ullery BW, McGarvey M, Cheung AT, et al. Vascular distribution of stroke and its relationship to perioperative mortality and neurologic outcome after thoracic endovascular aortic repair. *J Vasc Surg* 2012; 56: 1510–1517.
6. Komatsu S, Ohara T, Takahashi S, et al. Early detection of vulnerable atherosclerotic plaque for risk reduction of acute aortic rupture and thromboemboli and atheroemboli using non-obstructive angioscopy. *Circ J* 2015; 79: 742–750.

7. Kim K, Reynolds T, Donayre C, et al. Predictability of cerebral embolization from aortic arch manipulations during thoracic endovascular repair. *Am Surg* 2011; 77: 1399–1409.
8. Bismuth J, Garami Z, Anaya-Ayala JE, et al. Transcranial Doppler findings during thoracic endovascular aortic repair. *J Vasc Surg* 2011; 54: 364–369.
9. Kahlert P, Eggebrecht H, Janosi RA, et al. Silent cerebral ischemia after thoracic endovascular aortic repair: a neuroimaging study. *Ann Thorac Surg* 2014; 98: 53–58.
10. Tsagakis K, Kamler M, Benedik J, et al. Angioscopy—a valuable tool in guiding hybrid stent grafting and decision making during type A aortic dissection surgery. *Eur J Cardiothorac Surg* 2010; 38: 507–509.
11. Tsagakis K. Angioscopy as a supplement to frozen elephant trunk treatment. *Ann Cardiothorac Surg* 2013; 2: 653–655.