

Received: 2016.02.02
Accepted: 2016.04.18
Published: 2016.07.04

ISSN 1941-5923
© Am J Case Rep, 2016; 17: 448-453
DOI: 10.12659/AJCR.897876

Anal Canal Adenocarcinoma in a Patient with Longstanding Crohn's Disease Arising From Rectal Mucosa that Migrated From a Previously Treated Rectovaginal Fistula

Authors' Contribution:
Study Design A
Data Collection B
Statistical Analysis C
Data Interpretation D
Manuscript Preparation E
Literature Search F
Funds Collection G

ABCDEF 1 **Taku Maejima**
ABCDEF 2 **Toru Kono**
ABCDEF 3 **Fumika Orii**
ABCDEF 3 **Atsuo Maemoto**
ABCDEF 3 **Shigeru Furukawa**
ABCDEF 1 **Wang Liming**
ABCDEF 1 **Shoji Kasai**
ABCEF 1 **Susumu Fukahori**
ABCDEF 1 **Nobutaka Mukai**
ABCDEF 1 **Daitaro Yoshikawa**
ABCDEF 1 **Hidenori Karasaki**
ABCDEF 4 **Hiroya Saito**
ABCDEF 5 **Kazuo Nagashima**

1 Department of Surgery, Sapporo Higashi Tokushukai Hospital, Sapporo, Japan
2 Advanced Surgery Center, Sapporo Higashi Tokushukai Hospital, Sapporo, Japan
3 Inflammatory Bowel Disease Center, Sapporo Higashi Tokushukai Hospital, Sapporo, Japan
4 Department of Radiology, Sapporo Higashi Tokushukai Hospital, Sapporo, Japan
5 Department of Pathology, Sapporo Higashi Tokushukai Hospital, Sapporo, Japan

Corresponding Author: Taku Maejima, e-mail: pop45else@hotmail.com
Conflict of interest: None declared

Patient: Female, 50
Final Diagnosis: Anal canal adenocarcinoma
Symptoms: —
Medication: —
Clinical Procedure: CT • MRI • biopsy
Specialty: Surgery





Objective: Unknown etiology
Background: This study reports the pathogenesis of anal canal adenocarcinoma in a patient with longstanding Crohn's disease (CD).

Case Report: A 50-year-old woman with a 33-year history of CD presented with perianal pain of several months' duration. She had been treated surgically for a rectovaginal fistula 26 years earlier and had been treated with infliximab (IFX) for the previous 4 years. A biopsy under anesthesia revealed an anal canal adenocarcinoma, which was removed by abdominoperineal resection. Pathological examination showed that a large part of the tumor consisted of mucinous adenocarcinoma at the same location as the rectovaginal fistula had been removed 26 years earlier. There was no evidence of recurrent rectovaginal fistula, but thick fibers surrounded the tumor, likely representing part of the previous rectovaginal fistula. Immunohistochemical analysis using antibodies against cytokeratins (CK20 and CK7) revealed that the adenocarcinoma arose from the rectal mucosa, not the anal glands.

Conclusions: Mucinous adenocarcinoma can arise in patients with CD, even in the absence of longstanding perianal disease, and may be associated with adenomatous transformation of the epithelial lining in a former fistula tract.

MeSH Keywords: Adenocarcinoma, Mucinous • Anal Canal • Crohn Disease • Rectovaginal Fistula

Full-text PDF: <http://www.amjcaserep.com/abstract/index/idArt/897876>

 1348   8  24



Background

Crohn's disease (CD) has been associated with perianal fistulas and abscesses, as well as an increased risk of malignancy [1–4]. The frequency of malignancy associated with CD has been reported to be 0.6–3.1% [5–7]. Although tumor location varies and is not always predictable, cancer arising from a fistula is rare [8–11]. Several hypotheses have been proposed to explain carcinoma development in fistulas, but the pathogenic mechanisms by which carcinomas arise in patients with CD remain unclear [12–14]. Indeed, the risk of carcinoma as a complication of CD may be cumulative. Most of these tumors are diagnosed at an advanced stage, with late diagnosis and delayed treatment associated with poor patient prognosis [15]. This report describes an early symptomatic anal canal adenocarcinoma in a patient with a 33-year history of CD and a history of rectovaginal fistula, which had been cured by surgical treatment 26 years earlier. The pathological and immunohistological findings in this patient suggest the origin and progression of CD-associated cancer.

Case Report

A 50-year-old woman with a 33-year history of CD, mostly concentrated in the ileum and colon, presented with perianal pain of several months' duration. She had undergone surgical correction of a rectovaginal fistula 26 years earlier. Postoperatively, she did not report any symptoms related to this fistula, which remained quiescent for 26 years until a few months before presentation to us. She developed significant perianal pain in the 12 o'clock position. Infliximab therapy was initiated at age 46 years, and uncontrolled bleeding from multiple ileocecal ulcers required surgical resection at the age of 49 years.

She was admitted to our department for severe perianal pain. Computed tomography (CT) at presentation showed an 18-mm isodense collection of perianal fluid on the anterior rectal wall with unclear margins (Figure 1A). CT performed 10 months earlier during routine surveillance showed perianal fluid collection around the same area, but it was 7 mm in diameter at that time and asymptomatic. Endoscopic examination showed no lesions in the rectum or anus. Magnetic resonance imaging (MRI) of the pelvis showed a multiple conglomerated cystic mass at the same location, with no invasion of the vaginal wall (Figure 1B). Colonoscopy revealed an ulcerative lesion in the anal canal 10 mm in diameter and located from the 12 o'clock to the 2 o'clock position, corresponding to the collection of perianal fluid identified by CT and MRI (Figure 2).

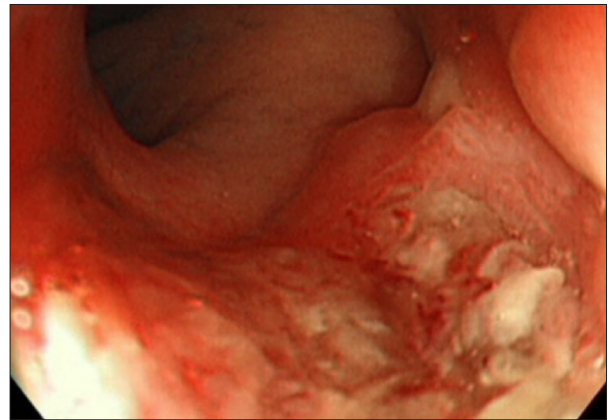


Figure 2. Colonoscopy findings. Colonoscopy revealed an ulcerative lesion that was 10 mm in diameter in the anal canal from the 12 o'clock to the 2 o'clock position. This corresponded to the perianal fluid collection identified by CT and MRI

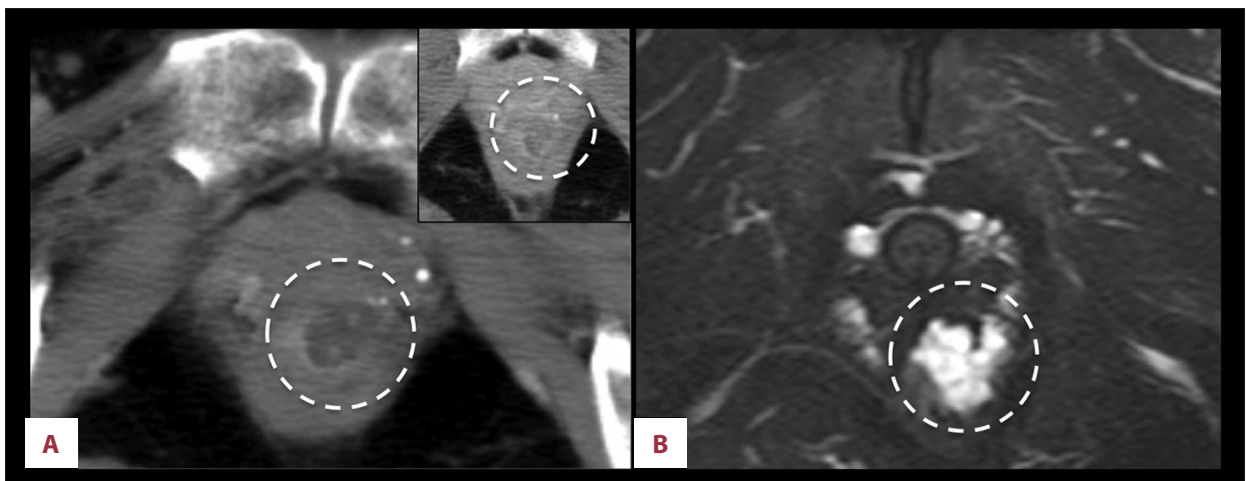


Figure 1. Radiology findings. (A) CT showed an 18-mm isodense perianal fluid collection on the anterior rectal wall (circle). The inset in the top right corner shows the results of CT performed at 10 months. A perianal fluid collection around the same lesion remained, but it was 7 mm at that time. (B) MRI showed a multiple conglomerated cystic mass at the same location with no invasion of the vaginal wall (arrow).

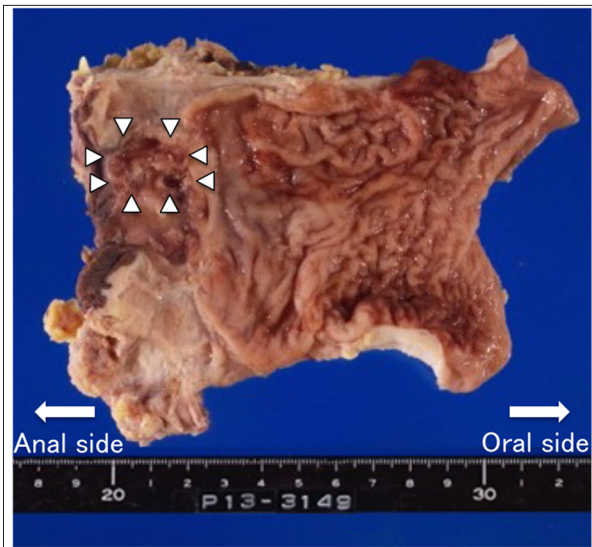


Figure 3. Resected rectum and anus. White arrowheads indicate a tumor on the anal canal.

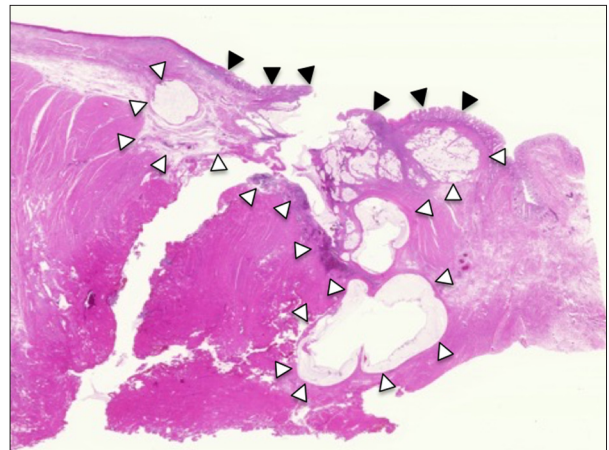


Figure 4. Pathological findings of the resected specimen (H.E. stain $\times 40$). Black arrowheads indicate tubular adenocarcinoma in the rectal mucosa. White arrowheads show mucinous adenocarcinoma in the submucosa.

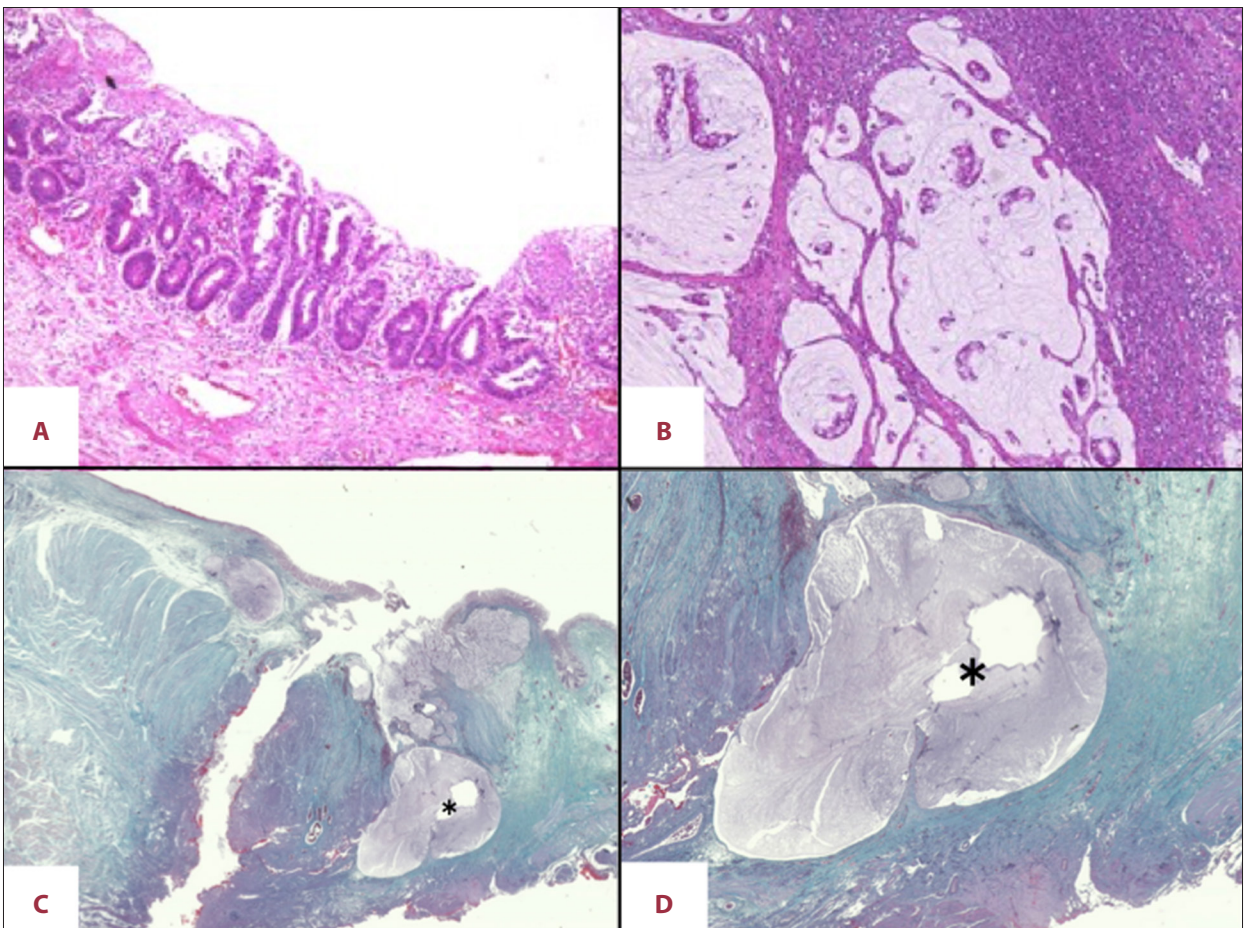


Figure 5. Pathological findings of the resected specimen. (A) Tubular adenocarcinoma in the rectal mucosa and submucosa (H.E. stain $\times 100$). (B) Mucinous adenocarcinoma in the submucosa and the muscularis propria (H.E. stain $\times 100$). (C) The mucin lake (asterisk) was surrounded by thick fibrous tissue with no evidence of infiltration by inflammatory cells (E.M. stain $\times 40$). (D) Magnification of Figure 5C (E.M. stain $\times 100$).

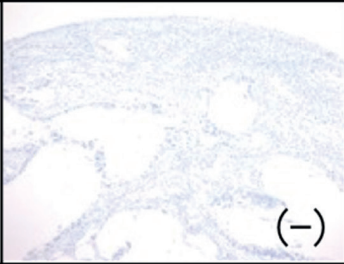
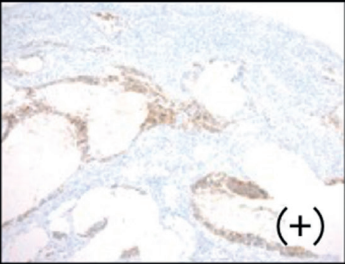
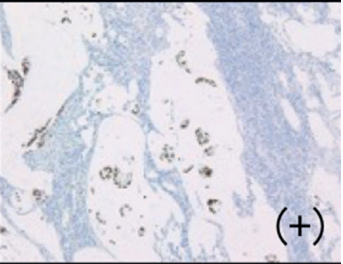
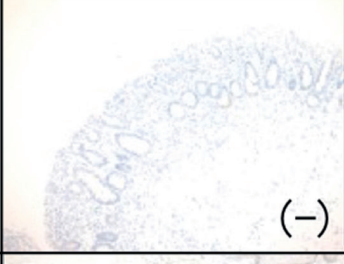
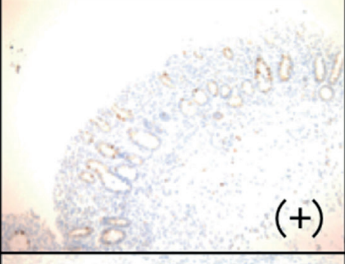
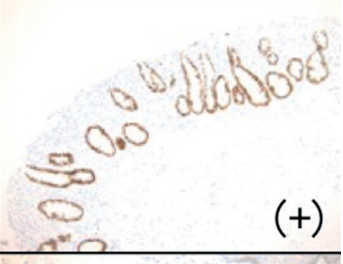
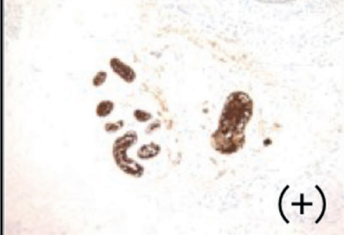

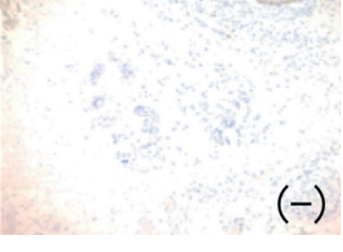
	CK7	CK20	CDX2
Tumor	 (-)	 (+)	 (+)
Rectal mucosa	 (-)	 (+)	 (+)
Anal gland	 (+)	 (-)	 (-)

Figure 6. Immunohistochemical findings. The tumor cells and rectal mucosa cells were positive for CDX2 and CK20, but negative for CK7. However, the anal gland cells were negative for CDX2 and CK20, but positive for CK7

A digital rectal examination, performed under local anesthesia of the anorectum, showed a small amount of jelly-like fluid at the site of ulcerative lesion, which was located on the level from 2 cm from the anus as CT and colonoscopy showed, along with compression of the posterior vaginal wall, but no fistula connected with the distal posterior vagina. The lesion was biopsied because mucinous adenocarcinoma was suspected. Pathologic examination showed disappearance of the crypts and a lack of mucous membranes. The pathological diagnosis was mucinous adenocarcinoma. Based on radiological findings, the stage was T1N0M0. Abdominoperineal resection was performed, with negative resection margins (Figure 3). Stenosis of the small bowel was observed during surgery, necessitating small bowel resection with a Kono-S anastomosis.

The final pathological diagnosis consisted of two types of adenocarcinoma: well differentiated tubular adenocarcinoma in the rectal mucosa and mucinous adenocarcinoma in the submucosa, measuring 1.5 cm and 2.0 cm in size, respectively (Figure 4). The tubular adenocarcinoma had invaded to the level of the submucosa (Figure 5A) and the mucinous adenocarcinoma had invaded to the level of the muscularis propria (Figure 5B).

There was no evidence of lymph node metastasis, but invasion of the lymph channels was observed. In addition, the tumor was surrounded by thick fibrous tissue with no evidence of infiltration by inflammatory cells (Figure 5C, 5D). The tumor cells expressed CDX2 and cytokeratin20 but were negative for cytokeratin (CK) 7 (Figure 6). Immunostaining showed the tumor cells were positive for MUC2 and MUC5AC but negative for MUC1 and MUC6 (Figure 7). These findings indicate that the tumor originated from the rectal mucosa, not from the anal glands. The final diagnosis was anal canal adenocarcinoma arising from the rectal mucosa.

Postoperatively, the patient developed catheter-related sepsis, which resolved after a course of treatment with antibiotics. One month after surgery, she started IFX therapy, which was scheduled once every 8 weeks. Based on the Japanese Society for Cancer of the Colon and Rectum's Guidelines 2014 for the Treatment of Colorectal Cancer, adjuvant chemotherapy was not administered. She continues to be followed with no signs or symptoms of recurrent carcinoma 18 months after surgery.

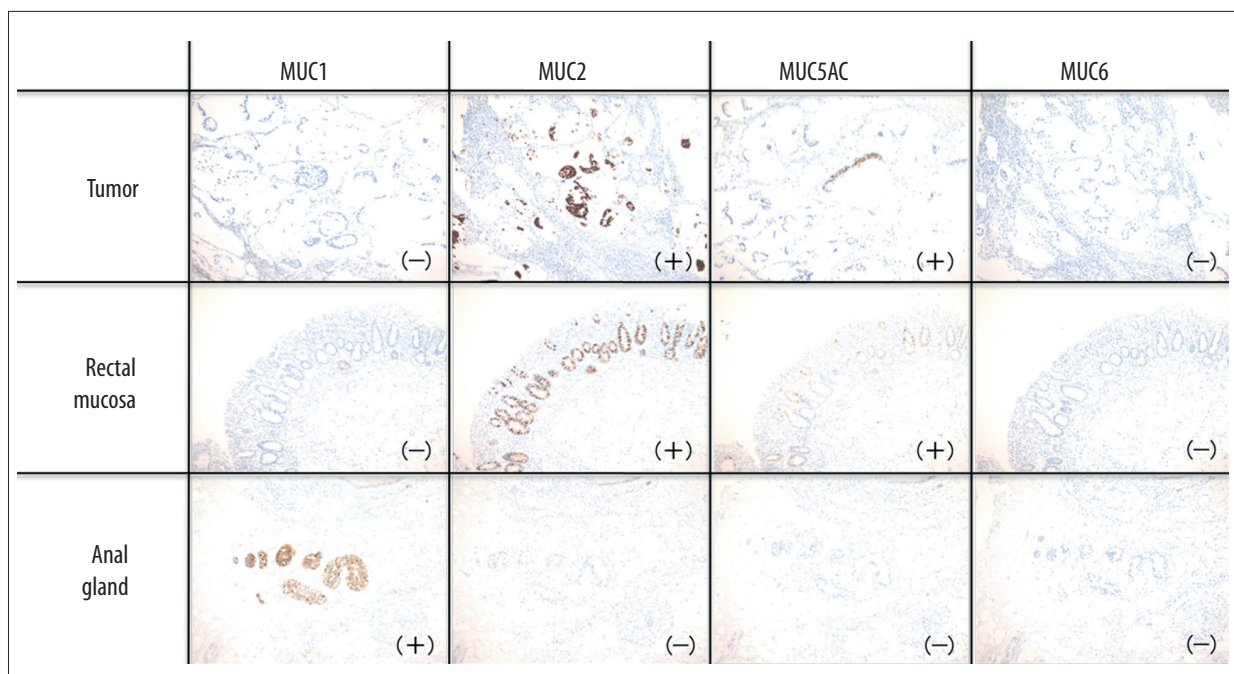


Figure 7. Immunostaining findings. The tumor cells and rectal mucosa cells were positive for MUC2 and MUC5AC, but negative for MUC1 and MUC6. However, the anal gland cells were negative for MUC2, MUC5AC and MUC6 but positive for MUC1.

Discussion

CD increases the risk of cancer. The incidence of malignant transformation has been reported to be 0.6–3.1% [5,6] in Europe and the United States.

A diagnosis of anorectal cancer arising from a former fistula requires not only pathological findings, but knowledge of the clinical course of the patient. Five clinical features have been reported necessary for a diagnosis of anorectal cancer arising from a fistula: 1) an anal fistula with continuous inflammation for more than 10 years, 2) pain or induration of the anal fistula, 3) mucinous secretions, 4) no evidence of any other primary cancer, and 5) the primary opening being an anal crypt or the anal canal [16–19]. However, this patient did not meet the first diagnostic criterion.

Her rectovaginal fistula had been successfully repaired 26 years earlier, with no evidence of exacerbation until she experienced severe pain several months prior to presentation. Pathological and clinical findings did not demonstrate the presence of a rectovaginal fistula or chronic inflammation. However, the tumor was located at the site of the former rectovaginal fistula. Pathological examination also showed that the thick fibers surrounding the tumor were likely part of the former rectovaginal fistula. Immunohistological methods are useful in determining the origin of anorectal adenocarcinomas [20,21]. For instance, adenocarcinomas arising from anal glands are positive for CK7 but negative for CK20, whereas adenocarcinomas

arising from the rectal mucosa are negative for CK7 but positive for CK20. This patient's tumor was positive for CK7 but negative for CK20, suggesting that its origin was the rectal mucosa, not the anal gland.

Pathological examination also showed that the mucinous adenocarcinoma component of the tumor was larger than the tubular adenocarcinoma component. In addition, the former showed deeper invasion. Radiological examination 10 months earlier showed that a small asymptomatic mass was present in the same location, but this lesion was not apparent on endoscopic examination (i.e., an aphthous ulcer).

These findings suggested that rectal epithelial cells had migrated from the primary opening of the rectovaginal fistula, and that the rectal epithelium lining the former rectovaginal fistula was the origin of the anorectal adenocarcinoma in the absence of chronic inflammation (Figure 8). However, we cannot completely exclude the possibility that the rectal mucosa in the anal canal became malignant and that tumor cells in the mucosal epithelium invaded the submucosa along the fistula and ultimately became mucinous adenocarcinoma.

Although several studies have suggested that carcinogenesis may be due to long-term treatment with IFX, an anti-tumor necrosis factor α (TNF α) antibody that has been shown effective for inducing and maintaining CD remission, the role of IFX in cancer progression remains unclear [22–24]. The current patient had been treated with IFX for 4 years. IFX therapy may

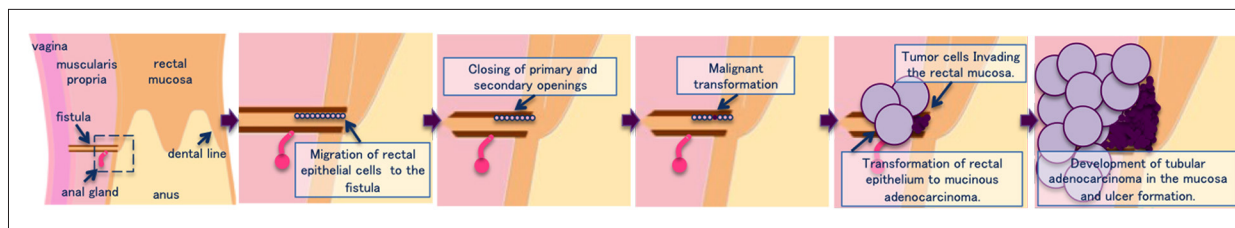


Figure 8. Clinical hypothesis. The rectal epithelial cells migrated to the fistula and became mucinous and tubular adenocarcinoma. Mucinous adenocarcinoma grew mainly in the submucosa and muscularis propria and formed a mucin lake. Tubular adenocarcinoma invaded to the mucosa and formed small ulcer.

suppress TNF α and thus enhance tumor growth. IFX therapy may also delay cancer diagnosis by controlling inflammation and ameliorating anal symptoms such as pain. Therefore, particular attention should be paid to malignant transformation in patients with CD on long-term IFX therapy, especially when they complain of increased symptoms (i.e. increased pain or fluid discharge) from a perianal lesion.

Conclusions

This report describes an anal canal adenocarcinoma diagnosed early in a patient with longstanding CD and long-term

IFX treatment. Pathological and clinical findings suggest that adenocarcinoma might arise in patients with CD, even in the absence of longstanding perianal disease, and that it might be associated with adenomatous transformation of the migrated epithelial lining of a former fistula tract.

Acknowledgements

The authors thank Mr. Fukuda for his skillful assistance.

Conflict of interest

There is no conflict of interest in this study.

References:

1. Kalla R, Ventham NT, Satsangi J, Arnott ID: Crohn's disease. *BMJ*, 2014; 349: g6670
2. Bressenot A, Cahn V, Danese S, Peyrin-Biroulet L: Microscopic features of colorectal neoplasia in inflammatory bowel diseases. *World J Gastroenterol*, 2014; 20: 3164–72
3. Andersen NN, Jess T: Has the risk of colorectal cancer in inflammatory bowel disease decreased? *World J Gastroenterol*, 2013; 19: 7561–68
4. Freeman HJ: Colorectal cancer risk in Crohn's disease. *World J Gastroenterol*, 2008; 14: 1810–11
5. Korelitz BI: Carcinoma arising in Crohn's disease fistulae: Another concern warranting another type of surveillance. *Am J Gastroenterol*, 1999; 94: 2337–39
6. Connell WR, Sheffield JP, Kamm MA et al: Lower gastrointestinal malignancy in Crohn's disease. *Gut*, 1994; 35: 347–52
7. Dyson JK, Rutter MD: Colorectal cancer in inflammatory bowel disease: What is the real magnitude of the risk? *World J Gastroenterol*, 2012; 18: 3839–48
8. Papaconstantinou I, Mantzos DS, Kondi-Pafiti A, Koutroubakis IE: Anal adenocarcinoma complicating chronic Crohn's disease. *Int J Surg Case Rep*, 2015; 10: 201–3
9. Sobala A, Herbst F, Novacek G, Vogelsang H: Colorectal carcinoma and preceding fistula in Crohn's disease. *J Crohns Colitis*, 2010; 4: 189–93
10. Iesalnieks I, Gaertner WB, Glass H et al: Fistula-associated anal adenocarcinoma in Crohn's disease. *Inflamm Bowel Dis*, 2010; 16: 1643–48
11. Marzo M, Felice C, Pugliese D et al: Management of perianal fistulas in Crohn's disease: an up-to-date review. *World J Gastroenterol*, 2015; 21: 1394–403
12. Thomas M, Bienkowski R, Vandermeer TJ et al: Malignant transformation in perianal fistulas of Crohn's disease: A systematic review of literature. *J Gastrointest Surg*, 2010; 14: 66–73
13. Scharl M, Frei P, Frei SM et al: Epithelial-to-mesenchymal transition in a fistula-associated anal adenocarcinoma in a patient with long-standing Crohn's disease. *Eur J Gastroenterol Hepatol*, 2014; 26: 114–18
14. Pellino G: Immunosuppression may exert a hypoxia-mediated carcinogenic effect in long-standing fistulizing Crohn's disease. *Eur J Gastroenterol Hepatol*, 2014; 26: 575–76
15. Higashi D, Futami K, Kawahara K et al: Study of colorectal cancer with Crohn's disease. *Anticancer Res*, 2007; 27: 3771–74
16. Skir I: Mucinous carcinoma associated with fistulas of long-standing. *Am J Surg*, 1948; 75: 285–89
17. McIntyre JM: Carcinoma associated with fistula-in-ano. *Am J Surg*, 1952; 84: 610–13
18. Rundle FF, Hales IB: Mucoïd carcinoma supervening on fistula-in-ano, its surgical pathology and treatment. *Ann Surg*, 1953; 137: 215–19
19. Rosser C: The relation of fistula-in-ano to cancer of the anal canal. *Trans Am Proc Soc*, 1934; 35: 65–71
20. Nishigami T, Kataoka TR, Ikeuchi H et al: Adenocarcinomas associated with perianal fistulae in Crohn's disease have a rectal, not an anal, immunophenotype. *Pathology*, 2011; 43: 36–39
21. Smith R, Hicks D, Tomljanovich PI et al: Adenocarcinoma arising from chronic perianal Crohn's disease: Case report and review of the literature. *Am Surg*, 2008; 74: 59–61
22. Williams CJ, Peyrin-Biroulet L, Ford AC: Systematic review with meta-analysis: malignancies with anti-tumour necrosis factor- α therapy in inflammatory bowel disease. *Aliment Pharmacol Ther*, 2014; 39: 447–58
23. Lichtenstein GR, Feagan BG, Cohen RD et al: Drug therapies and the risk of malignancy in Crohn's disease: results from the TREAT Registry. *Am J Gastroenterol*, 2014; 109: 212–23
24. Ogawa H, Haneda S, Shibata C et al: Adenocarcinoma associated with perianal fistulas in Crohn's disease. *Anticancer Res*, 2013; 33: 685–89