

# Case report and literature review of Huntington disease with intermediate CAG expansion

Stefan D Jevtic ,<sup>1</sup> John P Provias<sup>1,2</sup>

**To cite:** Jevtic SD, Provias JP. Case report and literature review of Huntington disease with intermediate CAG expansion. *BMJ Neurology Open* 2020;**2**:e000027. doi:10.1136/bmjno-2019-000027

Accepted 23 January 2020

## ABSTRACT

**Background** Huntington disease (HD) is a genetically inherited neurodegenerative disorder that classically involves a trinucleotide CAG repeat expansion on chromosome 4, with 36 repeats or greater being disease identifying. It generally presents between the age of 30 and 40 years old and is characterised by severe caudate/striatum degeneration with huntingtin protein aggregation. We present here the case of a patient in her early 80s who presented with 5-year history of worsening chorea and family history of HD but an intermediate length CAG expansion.

**Methods** Genetic testing of CAG repeats on chromosome 4. Postmortem brain tissue was obtained and stained using immunohistochemistry for amyloid-beta, tau and glial fibrillary acidic protein (GFAP). Sections from the caudate/putamen were also analysed by p62 immunofluorescence. All sections were reviewed by trained neuropathologists.

**Results** On genetic testing the patient was found to have a 28 CAG repeat on the longest expansion. Microscopic analysis revealed significant neuronal atrophy in the caudate and putamen with gliosis. Immunofluorescent staining demonstrated minimal intranuclear p62 inclusions suggesting little huntingtin aggregation present. Furthermore, there was significant amyloid-beta pathology (Thal-IV stage) and tau involvement in the medial temporal lobe (Braak stage II).

**Conclusion** This case provides clinical and pathological evidence to support an emerging clinical entity involving HD presentation in late age with an intermediate CAG repeat.

have been reported of HD patients with repeats in this intermediate range.<sup>4-11</sup> Unfortunately, the majority lack autopsy diagnosis of disease and thus cannot be confirmed.

We present here a case involving an octogenarian woman clinically diagnosed with HD who was found to have 28 CAG repeats on genetic testing. The diagnosis was confirmed on autopsy with classic histological findings in the brain consisting of severe neuronal loss in the caudate. Interestingly, there was significant diffuse amyloid-beta pathology with minimal tau aggregation. This case represents the lowest pathological repeat reported to date in the literature with autopsy-confirmed diagnosis. It emphasises an interesting ethical dilemma regarding genetic counselling for intermediate range repeats and the complex pathophysiology of this disease.

## CASE REPORT

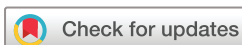A woman in her 80s with a 5-year history of worsening motor symptoms presented to the Movement Disorders Clinic. Her initial symptoms included difficulty walking that progressively worsened alongside presence of choreic movements, involving head bobbing and extremity tremors. There were no symptoms of numbness, urinary incontinence or memory impairment (mild forgetfulness was noted and attributed to age). No significant alcohol intake history was elicited.

Family history was significant for a sister with HD that developed in her 40s, with no relevant history in parents or grandparents. Her children were not known to have developed any signs of Huntington chorea and have not received genetic testing to date.

On general physical examination there was no distress or abnormality identified. Her neurological assessment revealed mild abnormal movements in her mouth/face, upper and lower extremities. Asymmetric bradykinesia was present on the left greater than right side as well as mild symmetrical

## INTRODUCTION

Huntington disease (HD) is a neurodegenerative disorder that is clinically characterised by chorea, psychiatric involvement and dementia. Typical inheritance is autosomal dominant and defined by a trinucleotide repeat expansion (CAG) in the huntingtin gene on chromosome 4.<sup>1,2</sup> Greater than 36 repeats is disease-identifying whereas less than 26 implies wild-type.<sup>3</sup> However, there remains an 'intermediate' range, from 27 to 35 repeats, that is typically not pathological but subject to genetic anticipation (a worsening phenotype with subsequent generations). Recently, several controversial cases



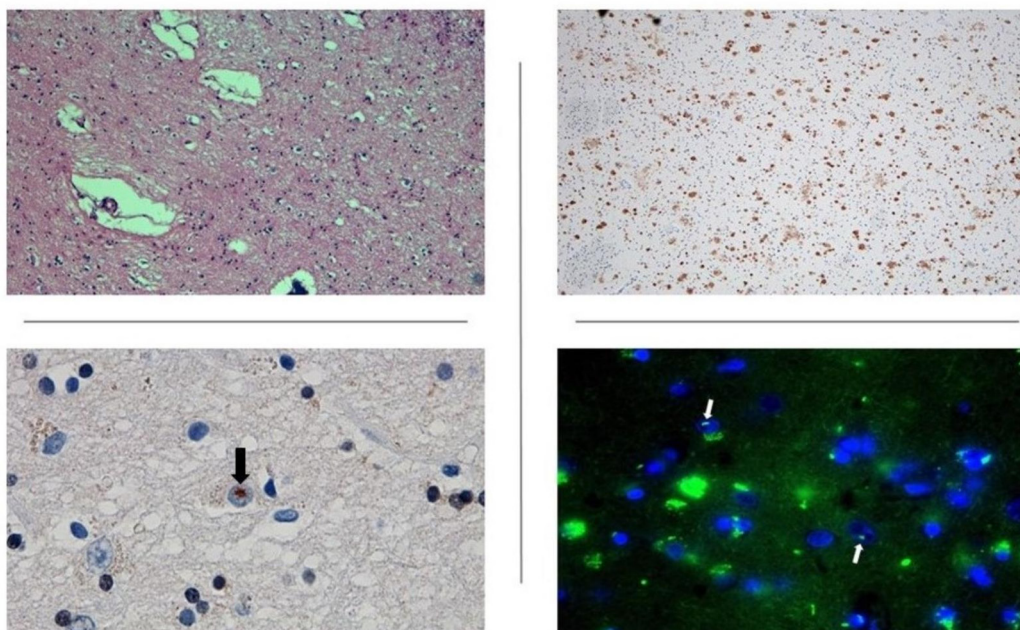
© Author(s) (or their employer(s)) 2020. Re-use permitted under CC BY-NC. No commercial re-use. See rights and permissions. Published by BMJ.

<sup>1</sup>Michael G. DeGroot School of Medicine, McMaster University, Hamilton, Ontario, Canada

<sup>2</sup>Laboratory Medicine and Pathology - Neuropathology, Hamilton Health Sciences, Hamilton, Ontario, Canada

### Correspondence to

Stefan D Jevtic;  
stefan.jevtic@medportal.ca



**Figure 1** Brain tissue histology. Evidence of significant neuronal loss was present throughout the caudate and putamen (top left, H&E, 40 $\times$ ). There was also presence of diffuse and neuritic plaques (top right, amyloid-beta 42 antibody, 20 $\times$ ) and rare ubiquitin inclusions (bottom left, black arrow, ubiquitin, 63 $\times$ ). Finally, staining with p62 demonstrated minimal nuclear inclusions (bottom right, white arrows, p62, 40 $\times$ ).

rigidity. Her stance was normal with slow gait and mild shuffling. Long tract signs were absent, along with negative Romberg sign, no cerebellar dysmetria or truncal ataxia.

Genetic testing revealed a 28-repeat CAG expansion in the huntingtin allele on chromosome 4.

Following a clinical diagnosis of HD, she was started on tetrabenazine therapy 12.5 mg two times per day that was gradually increased to three times per day. A remarkable improvement was noted on follow-up and near complete resolution of her abnormal movements. Unfortunately, the patient was unable to continue therapy due to cost and suffered a return of choreic movement with dysphagia to solids. She was thus started on reserpine 0.1 mg daily with plans to increase the dose.

Due to unrelated circumstances, the patient passed away at the age of 81 and a neuropathological assessment was completed. This revealed classic HD findings including caudate atrophy, severe neuronal loss in the basal ganglia (particularly caudate and putamen), with concomitant gliosis in these areas (figure 1). p62 showed rare intraneuronal inclusions thus suggesting minimal huntingtin aggregation (figure 1). Interestingly, Alzheimer type pathology was also identified consisting of amyloid-beta plaques (Thal-phase IV staging) and tau neuronal degeneration of the medial temporal lobe (Braak stage II) (figure 1).

## DISCUSSION

HD is an autosomal dominant neurodegenerative disorder that is classically associated with a repeat CAG

expansion in the huntingtin gene. Genetic testing is often relied on in clinical practice for diagnostic confirmation. Furthermore, it can be used to determine the risk for family members to develop disease, given the autosomal dominant nature and association of repeat length with disease penetrance/severity.<sup>12</sup> There is an intermediate CAG repeat length (27–35) that is prevalent in the general population and often does not manifest as disease. However, several cases have been reported of individuals developing HD symptoms with this intermediate range.<sup>4–11</sup> Unfortunately, most do not have pathological confirmation of disease and controversy remains as to whether they represent true HD or misdiagnoses.

Our case represents the lowest repeat length (28) in the literature with both clinical and pathological confirmation and thus supports the notion that intermediate CAG expansions contribute to disease. This highlights an important ethical question regarding patient counselling for disease risk and need for testing of relatives. If an intermediate length repeat is interpreted as non-pathological it may discourage testing of family members who harbour a classic pathological expansion (particularly given the phenomenon of genetic anticipation). Furthermore, there has been debate in the literature regarding whether these ‘intermediate repeat’ HD cases represent true disease or rather misdiagnosis. Unfortunately, only one previous case has confirmed diagnosis by autopsy, to our knowledge.<sup>4</sup> Thus, our case supports the notion that minimal CAG repeats can lead to HD, likely in conjunction with environmental and other genetic factors such as MSH3.<sup>13</sup>

The classic CAG expansion was previously thought to cause disease through mutant huntingtin expression that is predisposed to aggregation. However, recent literature has challenged this assumption and there is currently no consensus on the role of soluble versus insoluble huntingtin in HD. In our case, there is marked atrophy in classic HD associated areas as well as rare evidence of p62 neuronal inclusions. p62 is a protein that is linked to huntingtin through its role in redirecting cytosolic proteins to the autophagosome for clearance.<sup>14 15</sup> It has also been shown to associate with huntingtin to regulate autophagy and appears to correlate with huntingtin aggregation but not diffuse huntingtin.<sup>14 16</sup> Therefore, with p62 serving as a surrogate marker for huntingtin, the paucity of staining suggests minimal huntingtin aggregation. This further highlights the controversial role of insoluble huntingtin in disease, as previous studies have shown both protective and toxic functions.<sup>17-19</sup>

Lastly, our case contains a co-occurrence of classic Alzheimer disease pathology in a patient with no diagnosis of mild cognitive impairment or dementia. In particular there was significant amyloid-beta staining in classic HD areas such as the caudate and putamen. This may represent a subclinical stage of Alzheimer disease since amyloid-beta staining has been identified in healthy individuals without cognitive symptoms.<sup>20</sup>

We thus present a unique case of HD that highlights important ethical considerations for genetic testing and the predictive value of intermediate length repeats. It is likely that a variety of factors contribute or trigger the onset of disease. Ideally, this information will contribute to the appreciation of neurodegenerative disease pathology and how to approach genetic testing in the clinical environment.

**Acknowledgements** We would like to thank Dr John Woulfe for his assistance in providing necessary reagents and labour for p62 tissue staining.

**Contributors** SDJ and JPP were involved in the initial case procurement, analysis and writing. JW performed p62 immunofluorescent staining and interpretation.

**Funding** The authors have not declared a specific grant for this research from any funding agency in the public, commercial or not-for-profit sectors.

**Competing interests** None declared.

**Patient consent for publication** Not required.

**Provenance and peer review** Not commissioned; externally peer reviewed.

**Data availability statement** Data sharing not applicable as no datasets generated and/or analysed for this study. No additional data was collected other than what is presented in this report.

**Open access** This is an open access article distributed in accordance with the Creative Commons Attribution Non Commercial (CC BY-NC 4.0) license, which permits others to distribute, remix, adapt, build upon this work non-commercially,

and license their derivative works on different terms, provided the original work is properly cited, appropriate credit is given, any changes made indicated, and the use is non-commercial. See: <http://creativecommons.org/licenses/by-nc/4.0/>.

#### ORCID iD

Stefan D Jevtic <http://orcid.org/0000-0002-0806-9833>

#### REFERENCES

- Bates GP, Dorsey R, Gusella JF, *et al.* Huntington disease. *Nat Rev Dis Primers* 2015;1:15005.
- MacDonald ME, Ambrose CM, Duyao MP, *et al.* A novel gene containing a trinucleotide repeat that is expanded and unstable on Huntington's disease chromosomes. The Huntington's disease Collaborative Research Group. *Cell* 1993;72:971-83.
- Kremer B, Goldberg P, Andrew SE, *et al.* A worldwide study of the Huntington's disease mutation. The sensitivity and specificity of measuring CAG repeats. *N Engl J Med* 1994;330:1401-6.
- Kenney C, Powell S, Jankovic J. Autopsy-Proven Huntington's disease with 29 trinucleotide repeats. *Mov Disord* 2007;22:127-30.
- Ha AD, Jankovic J. Exploring the correlates of intermediate CAG repeats in Huntington disease. *Postgrad Med* 2011;123:116-21.
- AD H, Beck CA, Jankovic J. Intermediate CAG Repeats in Huntington's Disease: Analysis of COHORT. *Tremor Other Hyperkinet Mov* 2012;2.
- Squitieri F, Jankovic J. Huntington's disease: how intermediate are intermediate repeat lengths? *Mov Disord* 2012;27:1714-7.
- Andrich J, Arning L, Wiczorek S, *et al.* Huntington's disease as caused by 34 CAG repeats. *Mov Disord* 2008;23:879-81.
- Herishanu YO, Parvari R, Pollack Y, *et al.* Huntington disease in subjects from an Israeli Karaites community carrying alleles of intermediate and expanded CAG repeats in the HTT gene: Huntington disease or phenocopy? *J Neurol Sci* 2009;277:143-6.
- Groen JL, de Bie RMA, Foncke EMJ, *et al.* Late-onset Huntington disease with intermediate CAG repeats: true or false? *J Neurol Neurosurg Psychiatry* 2010;81:228-30.
- Garcia-Ruiz PJ, Garcia-Caldentey J, Feliz C, *et al.* Late onset Huntington's disease with 29 CAG repeat expansion. *J Neurol Sci* 2016;363:114-5.
- Andrew SE, Goldberg YP, Kremer B, *et al.* The relationship between trinucleotide (CAG) repeat length and clinical features of Huntington's disease. *Nat Genet* 1993;4:398.
- Moss DJH, Pardiñas AF, Langbehn D, *et al.* Identification of genetic variants associated with Huntington's disease progression: a genome-wide association study 2017:701-11.
- Bjørkøy G, Lamark T, Brech A, *et al.* p62/SQSTM1 forms protein aggregates degraded by autophagy and has a protective effect on huntingtin-induced cell death. *J Cell Biol* 2005;171:603-14.
- Huang N, Erie C, Lu ML, *et al.* Aberrant subcellular localization of SQSTM1/p62 contributes to increased vulnerability to proteotoxic stress recovery in Huntington's disease. *Mol Cell Neurosci* 2018;88:43-52.
- Rui Y-N, Xu Z, Patel B, *et al.* Huntingtin functions as a scaffold for selective macroautophagy. *Nat Cell Biol* 2015;17:262-75.
- Davies SW, Turmaine M, Cozens BA, *et al.* Formation of neuronal intranuclear inclusions underlies the neurological dysfunction in mice transgenic for the HD mutation. *Cell* 1997;90:537-48.
- Miller J, Arrasate M, Shaby BA, *et al.* Quantitative relationships between huntingtin levels, polyglutamine length, inclusion body formation, and neuronal death provide novel insight into huntingtin's disease molecular pathogenesis. *J Neurosci* 2010;30:10541-50.
- Saudou F, Finkbeiner S, Devys D, *et al.* Huntingtin acts in the nucleus to induce apoptosis but death does not correlate with the formation of intranuclear inclusions. *Cell* 1998;95:55-66.
- Zolochovska O, Tagliatalata G. Non-Demented individuals with Alzheimer's disease neuropathology: resistance to cognitive decline may reveal new treatment strategies. *Curr Pharm Des* 2016;22:4063-8.