

Research Article

Comparing Different Anesthesia Methods on Anesthetic Effect and Postoperative Pain in Patients with Early Gastric Cancer during Endoscopic Submucosal Dissection

Jie Zhang,¹ Yanlei Chen,² Zhiwu Liu,³ and Zhihao Pan ³

¹Department of Anesthesia, Yantai Mountain Hospital, Yantai 264001, Shangdong, China

²Chinese Peoples Liberat Army, Dept of Gastroenterology, Hosp970, Joint Logist Support Unit, Yantai 264001, Shangdong, China

³Chinese Peoples Liberat Army, Dept Anesthesiol, Hosp 970, Joint Logist Support Unit, Yantai 264001, Shangdong, China

Correspondence should be addressed to Zhihao Pan; 2725651686@qq.com

Received 21 June 2022; Revised 18 July 2022; Accepted 6 August 2022; Published 29 August 2022

Academic Editor: Jinghua Pan

Copyright © 2022 Jie Zhang et al. This is an open access article distributed under the Creative Commons Attribution License, which permits unrestricted use, distribution, and reproduction in any medium, provided the original work is properly cited.

Endoscopic submucosal dissection (ESD) is a minimally invasive technique to completely peel the pathological mucosa from the submucosa under endoscopy, which has been often utilized to treat early gastric cancer. During the operation, anesthesia is required to reduce the discomfort due to the complexity, high risk, and longtime operation of ESD. In this study, we compared different anesthesia methods on anesthetic effect and postoperative pain in patients (≥ 65 years old) with early gastric cancer during ESD. For this purpose, 60 patients with early gastric cancer who were more than 65 years old were selected from January 2019 to December 2021, where 30 patients treated with simple intravenous general anesthesia were divided into the simple group and 30 patients treated with intravenous combined inhalation general anesthesia were regarded as the composite group. The hemodynamic index, wake-up time, postoperative pain intensity, operation time, and the incidence of adverse reactions were compared between the two groups. For the hemodynamic index before incision, after incision, and at the end of the operation, the mean arterial pressure (MAP) in the composite group was higher than that in the simple group ($P < 0.05$) and the heart rate (HR) was lower than that in the simple group ($P < 0.05$). After the ESD operation, the wake-up time and visual analogue scale (VAS) in the composite group were lower than those in the simple group ($P < 0.05$). In addition, the ESD operation time and incidence of adverse reactions in the composite group was significantly lower than that in the simple group ($P < 0.05$). These results showed that intravenous combined inhalation general anesthesia had a good anesthetic effect, stable hemodynamics during ESD operation, and slight postoperative pain.

1. Introduction

Early gastric cancer refers to the early stage of gastric cancer, where the lesion only involves the mucosa or submucosa and does not consider the size of the lesion and lymph node metastasis [1]. It is difficult to detect since it has no obvious symptoms or sometimes has nonspecific symptoms such as epigastric discomfort, satiety after eating, nausea, and so on [2]. More than 75% of patients have entered the advanced stage when they are first diagnosed with gastric cancer and the mortality of late gastric cancer is high [3]. With the development of medical technology, endoscopic submucosal dissection (ESD) have been used to diagnose and treat early

gastric cancer, which increased the survival rate and survival time. ESD indicated the minimally invasive technique to completely peel the pathological mucosa from the submucosa under endoscopy [4–6]. Many studies have shown that ESD is not inferior to surgery in terms of complete resection rate, and it has the advantages of minimally invasive, short hospital stay, and low total treatment cost [7, 8].

The ESD operation is carried out under anesthesia, since the patients are very likely to have bleeding, perforation, and other phenomena, and even circulatory and respiratory dysfunction during a long time of the ESD operation [9, 10]. Common anesthesia methods include simple intravenous general anesthesia (propofol plus small dose fentanyl) and

intravenous combined inhalation general anesthesia [11, 12]. Propofol plus low-dose fentanyl sedation is often used in short-term outpatient surgery, such as gastrointestinal endoscopy and induced abortion, which has the characteristics of rapid onset, high quality of recovery, and low post-operative adverse reactions [13]. Intravenous combined inhalation general anesthesia refers to the method of combining intravenous anesthetics with inhalation anesthetics to produce and maintain general anesthesia. Intravenous anesthetics are often used to induce anesthesia because of their fast onset and no irritation to respiratory tract, and inhaled anesthetics are usually used to maintain general anesthesia since it is easy to control the anesthesia and recover after operation [14, 15]. For the patients more than 65 years old, surgical anesthesia is a big problem. Specifically, elderly patients often suffer from one or several chronic diseases due to functional decline of various organs and low immunity, resulting in poor tolerance to surgery and anesthesia, strong stress response, unstable intra-operative hemodynamics, and increased anesthesia risk [16, 17]. Therefore, it is very important and necessary to explore an effective anesthesia method.

Here, we chose 60 elderly patients with early gastric cancer and compared the effects of two different anesthesia methods to clarify the application advantages of intravenous combined inhalation general anesthesia and its impact on the anesthetic effect and postoperative pain of patients.

2. Materials and Methods

2.1. Clinical Data. 69 patients hospitalized in our hospital from January 2019 to December 2021 with early gastric cancer who were more than 65 years old were selected retrospectively. After filtering by the inclusion and exclusion criteria, 60 patients were kept to be further analyzed, where 30 patients treated with simple intravenous general anesthesia (propofol plus small dose fentanyl) were divided into the simple group and other 30 patients treated with intravenous combined inhalation general anesthesia were divided to the composite group (Figure 1). The study protocol has been approved by the ethics committee of our hospital.

2.1.1. Inclusion Criteria. The inclusion criteria were as follows:

- (1) All the patients fit the diagnostic criteria for early gastric cancer: the tumor tissue was limited to the gastric mucosa or submucosa, the diameter of small gastric cancer lesions was ≤ 5 mm, the diameter of small gastric cancer lesions was 5~10 mm, and the diagnosis was made by endoscopy and pathological biopsy.
- (2) Age ≥ 65 years old.
- (3) Patients complying with ESD treatment indications.
- (4) Patients carried on the ESD treatment successfully.
- (5) Patients with complete clinical medical records.

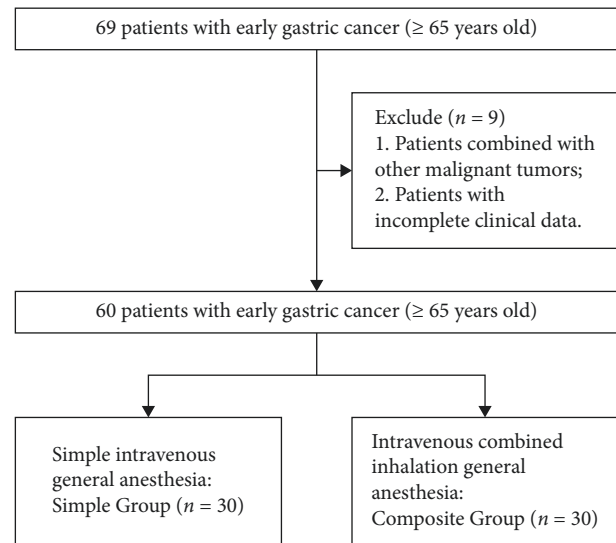


FIGURE 1: The flowchart of patients' selection and classification.

2.1.2. Exclusion Criteria. The exclusion criteria were as follows:

- (1) Patients combined with other malignant tumors
- (2) Patients with incomplete clinical medical records

2.2. ESD Treatment. All patients were treated with ESD. Food and water were forbidden for 6 h and 2 h at least, respectively, before operation. After general anesthesia, the lesions were located under routine endoscopy. In combination with iodine staining and magnifying endoscopy, the lesion boundary was confirmed. Spot electrocoagulation marks were made at the place 3~5 mm away from the lesion edge. The submucosal injection was made at the outside of the mark point with 10% glycerol fructose concrete solution, and the lesion boundary was fully raised. We cut the lesion mucosa to the submucosa circularly at about 5 mm outside the marked point and gradually peel off along the submucosa below the lesion until the lesion mucosa completely falls off. After the lesion mucosa is completely stripped, argon ion coagulation should be performed to treat the visible small blood vessels on the wound surface. For those with deep local stripping, intrinsic muscular injury, and visible holes, metal clips should be used to clamp them.

2.3. Anesthesia

2.3.1. The Anesthesia in the Simple Group. 30 patients in the simple group were treated with simple intravenous general anesthesia (propofol plus small dose fentanyl). Specifically, continuous oxygen inhalation through nasal catheter, oxygen flow rate of 8l/min, intravenous injection of fentanyl 1 μ g/kg, and propofol 2~2.5 mg/kg for induction. The operation was started after the patient fell asleep and the eyelash reflex disappeared. During the operation, propofol 4~6 mg/(kg h) was continuously pumped to maintain anesthesia until the end of the operation.

2.3.2. The Anesthesia in the Composite Group. 30 patients in the composite group were treated with intravenous combined inhalation general anesthesia. Anesthesia induction: intravenous injection of 1~2 mg/kg propofol, 1~1.5 mg/kg vecuronium, and 4~6 μ g/kg fentanyl. Anesthesia maintenance: after endotracheal intubation, propofol (10 g/L) was injected intravenously at the rate of 15~20 ml/h with a micropump, sevoflurane (volume fraction: 0.015~0.020) was inhaled, and fentanyl was intermittently injected intravenously.

2.4. Observation Index. The observation indexes were as follows:

- (1) The general data including age and gender
- (2) Hemodynamic index including the mean arterial pressure (MAP), heart rate (HR) at 30 min and 60 min, and the end of the operation
- (3) The wake-up time
- (4) Postoperative pain: visual analogue scale (VAS) [18] was utilized to measure the pain at 1, 6, 12, and 24 hours after the operation. The full score was 10, and the lower the score, the less the pain

2.5. Statistical Processing. SPSS 26.0 and GraphPad Prism 8.0 were utilized to analyze and visualize the data, respectively. The measurement data were expressed in (mean \pm sd) and analyzed by *T* test, which was consistent with the normal distribution. The counting data were expressed in the number of cases and compared by χ^2 test. $P < 0.05$ reveals that there is an obvious difference between the groups.

3. Results

3.1. Clinical Data in the Simple and Composite Groups. As shown in Table 1, for the age, gender, BMI, and ASA, there was no obvious distinction between the simple and composite groups ($P > 0.05$), while the ESD operation time in the composite group was shorter than that in the simple group ($P < 0.05$).

3.2. Comparison of MAP. Before anesthesia, the MAP in the simple and composite groups was no difference ($P > 0.05$). Before incision, after incision, and at the end of anesthesia operation, the MAP in the composite group was higher than that in the simple group ($P < 0.05$) (Figure 2). Besides, the fluctuation amplitude of MAP in the composite group was smaller than that in the simple group, indicating that the MAP in the group with intravenous combined inhalation general anesthesia was more stable.

3.3. Comparison of HR. There was no difference in the HR between the two cohorts before anesthesia ($P > 0.05$). Before incision, after incision, and at the end of anesthesia the HR in the composite group was obviously lower than that in the simple group ($P < 0.05$) (Figure 3). Additionally, the

fluctuation amplitude of HR in the composite group was smaller than that in the simple group, indicating that the HR in the group with intravenous combined inhalation general anesthesia was more steady.

3.4. Comparison of the Wake-Up Time. Figure 4 reveals that the wake-up time in the simple and composite groups was 23.23 ± 2.648 (min) and 19.27 ± 1.760 (min), respectively, indicating that the wake-up time in the composite group was shorter than that in the simple group ($P < 0.05$).

3.5. Comparison of the VAS Score. As shown in Figure 5, at 1, 6, 12, and 24 hours after the ESD, the VAS scores in the composite group were lower than those in the simple group ($P < 0.05$), indicating that the analgesic effect of intravenous combined inhalation general anesthesia was better than simple intravenous general anesthesia.

3.6. Comparison of the Adverse Reactions. We further collected the data of patients' adverse reactions. Specifically, there were 4 cases of body movement, 3 cases of hypoxemia, and 2 cases of cough in the simple group. A total of 2 patients had adverse reactions in the composite group, one was cough, and the other was hypoxemia. The comparison result shows that the incidence of adverse reactions in the composite group was significantly lower than that in the simple group ($P < 0.05$) as shown in Table 2.

4. Discussion

At present, gastric cancer is still endangering human health, with a high degree of malignancy and poor prognosis [19]. Among malignant tumors, its incidence rate and mortality ranked second and third in China [20, 21]. With the change of population aging, elderly patients have become the main population of gastric cancer, accounting for about two-thirds of the total number of patients [22, 23]. In recent years, with the popularization of gastroscopic examination and the increase of people's attention to their own health, more and more gastric cancer lesions can be diagnosed by endoscopy in the early stage [24, 25]. Compared with traditional radical surgical resection, early gastric cancer located in the mucosa or submucosa can be treated with minimally invasive endoscopic submucosal dissection [26]. During the operation, scientific and effective anesthesia is the key to ensuring the smooth implementation of radical gastrectomy for gastric cancer and achieving ideal results [27]. Therefore, the choice of safe and efficient anesthesia has an important clinical significance and value.

The commonly used anesthesia methods are propofol plus low-dose fentanyl intravenous analgesia and intravenous combined inhalation anesthesia [28]. Propofol plus low-dose fentanyl sedation is commonly used in short-term outpatient surgery, such as gastrointestinal endoscopy and induced abortion. It has the characteristics of rapid onset, high quality of recovery, and small postoperative adverse reactions [29–31]. Our results showed that the MAP

TABLE 1: Clinical data in the simple and composite groups.

Index	Simple group ($n = 30$)	Composite group ($n = 30$)	t/χ^2	P
Age (years)	75.07 ± 4.127	75.17 ± 4.194	-0.093	0.926
Sex (male, %)	16 (53.33%)	15 (50%)	0.067	0.796
BMI (kg) (m^2)	20.47 ± 0.603	20.45 ± 0.625	0.137	0.892
ASA (I, %)	15 (50.00%)	16 (53.33%)	0.067	0.796
ESD time (h)	2.31 ± 0.180	1.78 ± 0.158	12.200	$P < 0.001$

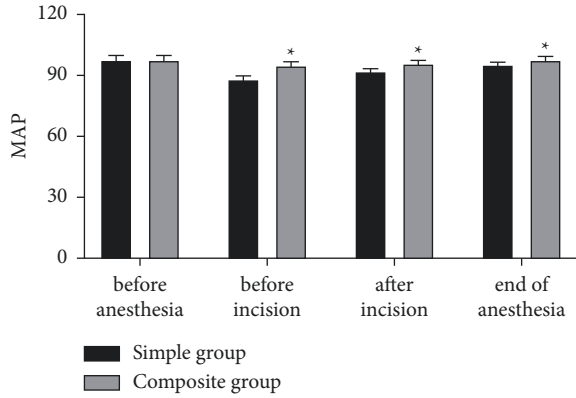
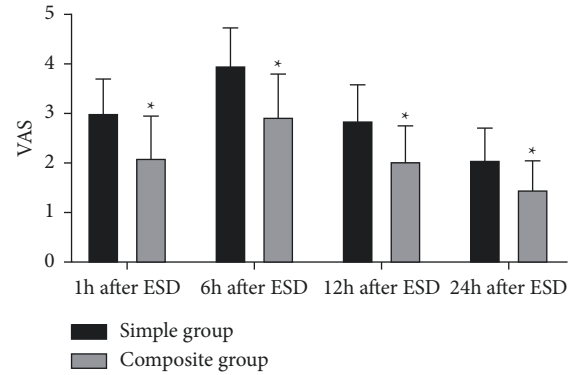
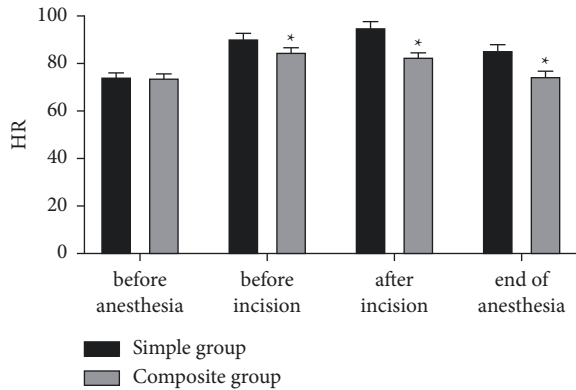
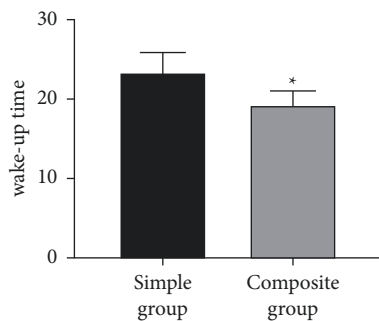
FIGURE 2: Comparison of MAP (mmHg). *represents $P < 0.05$ compared with the simple group.FIGURE 5: Comparison of VAS. *represents $P < 0.05$ compared with the simple group.FIGURE 3: Comparison of HR (mmHg). *represents $P < 0.05$ compared with the simple group.FIGURE 4: Comparison of the wake-up time (min). *represents $P < 0.05$ compared with the simple group.

TABLE 2: Comparison of the adverse reactions.

Group	Body movement	Hypoxemia	Cough	Total
Simple group	4	3	2	9
Composite group	1	1		2
χ^2				5.455
P				0.020

decreased and HR increased during operation compared with those before ESD, which may be related to the decreased sympathetic tension and vasodilation of propofol after the patient falls asleep [32].

In addition, the results of this study revealed that the fluctuation amplitude of MAP and HR in the composite group was less than that in the simple group, suggesting that intravenous combined inhalation can maintain the stability of hemodynamics during operation compared with simple intravenous general anesthesia. Intravenous combined inhalation general anesthesia can effectively protect the airway and carry out mechanical ventilation, so it can maintain the appropriate depth of anesthesia, so as to avoid adverse reactions in simple intravenous general anesthesia, improve oxygenation, and maintain hemodynamic stability [33]. Propofol, sevoflurane, and fentanyl were used in this study, which have the characteristics of fast onset, short action time, and no accumulation and meet the requirements of "fast channel anesthesia". [34]. This study also showed that the wake-up time of the composite group is shorter than that of the simple group, and the postoperative pain intensity is significantly lower than that in the simple group. Our result showed that the incidence of adverse reactions in the

composite group was significantly lower than that in the simple group, indicating that intravenous combined inhalation general anesthesia can decrease the wake-up time of patients and create good conditions for postoperative recovery.

In conclusion, compared with simple intravenous general anesthesia, intravenous combined inhalation general anesthesia can better maintain the intraoperative hemodynamic stability of patients with early gastric cancer, shorten the postoperative recovery time, and reduce the postoperative pain. On the other hand, this study is a retrospective study, which may have some limitations. The analysis of the indicators is less and there are many variables between the comparison of two groups, leading to the comparison of the two anesthesia methods is not comprehensive enough. In addition, the number of objects in our study is small, and there may be a sample deviation. In the next study, prospective research is needed to obtain more comprehensive evaluations and more credible conclusions.

Data Availability

The raw data used to support the findings of this study could be obtained by getting in touch the corresponding author.

Disclosure

Jie Zhang, Yanlei Chen, and Zhiwu Liu are co-first authors.

Conflicts of Interest

The authors declare that they have no conflicts of interest.

Authors' Contributions

Jie Zhang, Yanlei Chen, and Zhiwu Liu contributed equally to this study.

References

- [1] K. Yang, L. Lu, H. Liu et al., "A comprehensive update on early gastric cancer: defining terms, etiology, and alarming risk factors," *Expert Review of Gastroenterology & Hepatology*, vol. 15, no. 3, pp. 255–273, 2021.
- [2] Y. Kono, H. Kanzaki, M. Iwamuro, S. Kawano, Y. Kawahara, and H. Okada, "Reality of gastric cancer in young patients: the importance and difficulty of the early diagnosis, prevention and treatment," *Acta Med Okayama*, vol. 74, no. 6, pp. 461–466, 2020.
- [3] M. Leja and A. Linē, "Early detection of gastric cancer beyond endoscopy—new methods," *Best Practice & Research Clinical Gastroenterology*, vol. 50–51, Article ID 101731, 2021.
- [4] H. Ono, K. Yao, M. Fujishiro et al., "Guidelines for endoscopic submucosal dissection and endoscopic mucosal resection for early gastric cancer (second edition)," *Digestive Endoscopy*, vol. 33, no. 1, pp. 4–20, 2021.
- [5] Q. Liu, L. Ding, X. Qiu, and F. Meng, "Updated evaluation of endoscopic submucosal dissection versus surgery for early gastric cancer: a systematic review and meta-analysis," *International Journal of Surgery*, vol. 73, pp. 28–41, 2020.
- [6] M. Tao, X. Zhou, M. Hu, and J. Pan, "Endoscopic submucosal dissection versus endoscopic mucosal resection for patients with early gastric cancer: a meta-analysis," *BMJ Open*, vol. 9, no. 12, Article ID e025803, 2019.
- [7] H. Li, L. Q. Feng, Y. Y. Bian et al., "Comparison of endoscopic submucosal dissection with surgical gastrectomy for early gastric cancer: an updated meta-analysis," *World Journal of Gastrointestinal Oncology*, vol. 11, no. 2, pp. 161–171, 2019.
- [8] T. Ojima, K. Takifuji, M. Nakamura et al., "Endoscopic submucosal tunnel dissection versus conventional endoscopic submucosal dissection for early gastric cancers: outcomes of 799 consecutive cases in a single institution," *Surg Endosc*, vol. 34, no. 12, pp. 5625–5631, 2020.
- [9] S. H. Kim, Y. S. Choi, S. K. Lee, H. Oh, and S. H. Choi, "Comparison of general anesthesia and conscious sedation in procedure-related complications during esophageal endoscopic submucosal dissection," *Surgical Endoscopy*, vol. 34, no. 8, pp. 3560–3566, 2020.
- [10] J. I. Chang, T. J. Kim, N. Y. Hwang et al., "Clinical outcomes and adverse events of gastric endoscopic submucosal dissection of the mid to upper stomach under general anesthesia and monitored anesthetic care," *Clinical Endoscopy*, vol. 55, no. 1, pp. 77–85, 2022.
- [11] W. W. Wu, W. H. Zhang, W. Y. Zhang et al., "The long-term survival outcomes of gastric cancer patients with total intravenous anesthesia or inhalation anesthesia: a single-center retrospective cohort study," *BMC Cancer*, vol. 21, no. 1, p. 1193, 2021.
- [12] S. Shin, C. H. Park, H. J. Kim, S. H. Park, S. K. Lee, and Y. C. Yoo, "Patient satisfaction after endoscopic submucosal dissection under propofol-based sedation: a small premedication makes all the difference," *Surgical Endoscopy*, vol. 31, no. 6, pp. 2636–2644, 2017.
- [13] M. Mandal, S. Khutia, S. Das, and S. R. Basu, "Intravenous infusion of ketamine-propofol can be an alternative to intravenous infusion of fentanyl-propofol for deep sedation and analgesia in paediatric patients undergoing emergency short surgical procedures," *Indian Journal of Anaesthesia*, vol. 56, no. 2, pp. 145–150, 2012.
- [14] Y. Wang, M. Cao, G. Cao, Y. Liu, and Y. Zhang, "Effect of combined intravenous-inhalation anesthesia on postoperative cognitive dysfunction after laparoscopic radical resection of cervical cancer: a protocol for systematic review and meta-analysis," *Medicine (Baltimore)*, vol. 99, no. 45, Article ID e23124, 2020.
- [15] Y. Liang, X. Xu, X. Sun, and C. Song, "Application of oxycodone combined with intravenous inhalation anesthesia in PFNA internal fixation of femoral intertrochanteric fracture in the elderly," *Minerva Surg*, vol. 77, no. 1, pp. 90–92, 2022.
- [16] L. Gao, L. Chen, J. He et al., "Perioperative myocardial injury/infarction after non-cardiac surgery in elderly patients," *Front Cardiovasc Med*, vol. 9, Article ID 910879, 2022.
- [17] G. Ren, C. Li, X. Wei, and J. Wang, "Effect of heptaflourane inhalation and anesthesia induction on hemodynamics of elderly patients undergoing elective gastrointestinal tumor surgery," *Journal of Oncology*, vol. 2022, pp. 1–9, 2022.
- [18] A. Chiarotto, L. J. Maxwell, R. W. Ostelo, M. Boers, P. Tugwell, and C. B. Terwee, "Measurement properties of visual analogue scale, numeric rating scale, and pain severity subscale of the brief pain inventory in patients with low back pain: a systematic review," *The Journal of Pain*, vol. 20, no. 3, pp. 245–263, 2019.
- [19] S. Lou, F. Meng, X. Yin, Y. Zhang, B. Han, and Y. Xue, "Comprehensive characterization of RNA processing factors in gastric cancer identifies a prognostic signature for

- predicting clinical outcomes and therapeutic responses,” *Front Immunol*, vol. 12, Article ID 719628, 2021.
- [20] M. C. S. Wong, J. Huang, P. S. F. Chan et al., “Global incidence and mortality of gastric cancer, 1980-2018,” *JAMA Network Open*, vol. 4, no. 7, Article ID e2118457, 2021.
- [21] R. M. Feng, Y. N. Zong, S. M. Cao, and R. H. Xu, “Current cancer situation in China: good or bad news from the 2018 Global Cancer Statistics?” *Cancer Communications*, vol. 39, no. 1, p. 22, 2019.
- [22] Q. Li, X. Xu, D. Su, T. Zhou, G. Wang, and Z. Li, “Long-term survival of an elderly patient with advanced gastric cancer after combination therapy: a case report and literature review,” *BMC Cancer*, vol. 19, no. 1, p. 459, 2019.
- [23] J. Schendel, E. Jost, M. Mah et al., “Gastric cancer management in elderly patients: a population-based study of treatment patterns and outcomes in gastric cancer patients ≥ 75 years from Alberta, Canada,” *The American Journal of Surgery*, vol. 221, no. 4, pp. 839–843, 2021.
- [24] T. Suzuki, Y. Kitagawa, R. Nankinzan, and T. Yamaguchi, “Early gastric cancer diagnostic ability of ultrathin endoscope loaded with laser light source,” *World Journal of Gastroenterology*, vol. 25, no. 11, pp. 1378–1386, 2019.
- [25] J. J. Wan, S. J. Fei, S. X. Lv et al., “Role of gastroscopic biopsy of gastric ulcer margins and healed sites in the diagnosis of early gastric cancer: a clinical controlled study of 513 cases,” *Oncology Letters*, vol. 16, no. 4, pp. 4211–4218, 2018.
- [26] Z. Zheng, J. Yin, X. Y. Liu et al., “Current indications for endoscopic submucosal dissection of early gastric cancer,” *World Journal of Gastrointestinal Oncology*, vol. 13, no. 6, pp. 560–573, 2021.
- [27] S. Nonaka, Y. Kawaguchi, I. Oda et al., “Safety and effectiveness of propofol-based monitored anesthesia care without intubation during endoscopic submucosal dissection for early gastric and esophageal cancers,” *Digestive Endoscopy*, vol. 27, no. 6, pp. 665–673, 2015.
- [28] H. S. Gurcan, A. Ulgey, O. Oz Gergin, S. Seçkin Pehlivan, and K. Yıldız, “Investigation of the effects of propofol/ketamine versus propofol/fentanyl on nausea- vomiting administered for sedation in children undergoing magnetic resonance imaging: a prospective randomized double-blinded study,” *Turk J Med Sci*, vol. 51, no. 4, pp. 2120–2126, 2021.
- [29] C. Zhang, D. Huang, W. Zeng et al., “Effect of additional equipotent fentanyl or sufentanil administration on recovery profiles during propofol-remifentanil-based anaesthesia in patients undergoing gynaecologic laparoscopic surgery: a randomized clinical trial,” *BMC Anesthesiol*, vol. 22, no. 1, p. 127, 2022.
- [30] B. Kheradmand, S. Edalatkah, E. Hazrati, M. Hashemi, A. Golaghaei, and M. Rafiei, “Evaluation of anesthesia quality with three methods: “propofol + fentanyl” vs. “propofol + fentanyl + lidocaine” vs. “propofol + fentanyl + lidocaine + ketamine” in patients referred to the scoping ward,” *Journal of Family Medicine and Primary Care*, vol. 11, no. 2, pp. 672–676, 2022.
- [31] J. E. Kim, J. B. Choi, B. N. Koo, H. W. Jeong, B. H. Lee, and S. Y. Kim, “Efficacy of intravenous lidocaine during endoscopic submucosal dissection for gastric neoplasm: a randomized, double-blind, controlled study,” *Medicine (Baltimore)*, vol. 95, no. 18, Article ID e3593, 2016.
- [32] M. F. Dogan, S. O. Arslan, O. Yildiz, M. Kurtoglu, and A. Parlar, “Propofol-induced vasodilation in human internal mammary artery: role of potassium channels,” *Journal of Cardiothoracic and Vascular Anesthesia*, vol. 33, no. 8, pp. 2183–2191, 2019.
- [33] X. Suo, Z. Wang, and Y. Zhu, “Application effect of sevoflurane combined with remifentanil intravenous inhalation anesthesia in patients undergoing laparoscopic radical resection of cervical cancer,” *American Journal of Translational Research*, vol. 14, no. 2, pp. 1034–1042, 2022.
- [34] K. Clevenger, B. Maresh, H. Graham, K. Hammonds, and M. P. Hofkamp, “The use of adjunct anesthetic medication with regional anesthesia and rates of general anesthesia for 1867 cesarean deliveries from 2014 to 2018 in a community hospital,” *Baylor University Medical Center Proceedings*, vol. 33, no. 4, pp. 536–540, 2020.