

Case Report

Acromioclavicular joint septic arthritis in an immunocompetent child: A case report

Saurabh Dutt*, Jeetendra Lodhi, Vinod Kumar, Abhishek Kashyap

Maulana Azad Medical College, India

ARTICLE INFO

Article history:

Received 11 September 2017

Received in revised form

12 November 2017

Accepted 10 December 2017

Available online 23 March 2018

Keywords:

Joint

Septic arthritis

Infection

Leukocytes count

Erythrocyte sedimentation ratio

Methicillin Resistant Staphylococcus Aureus

ABSTRACT

Septic arthritis of acromioclavicular (AC) joint is a rare entity. It is generally seen in patients who are immunocompromised. Only 15 cases have been reported till now, with only one case series of 6 patients. We report a case of septic arthritis of AC joint in an immunocompetent child. A 9 years old girl presented with history of pain in left shoulder for 4 days associated with fever. No history suggestive of any immunocompromised state was complained. On local examination, a swelling of around 3 cm in diameter was found over left AC joint region with raised local temperature, tenderness on palpation and positive response in fluctuation test. Total leukocyte count was $18.7 \times 10^9/L$ with 80% of neutrophils. Erythrocyte sedimentation rate (ESR) was 28 mm/1 h. C-reactive protein (CRP) was 12 mg/L. X-ray showed enlarged left AC joint space. Ultrasound revealed hypochoic collection in the AC joint and the surrounding area. The aspirate was thick and purulent in nature, revealing Gram positive cocci at staining. Arthrotomy and thorough lavage of AC joint was done. Culture of the aspirate showed Methicillin Resistant Staphylococcus Aureus (MRSA) after 48 hours that was sensitive to amikacin, gentamicin, erythromycin and teicoplanin. Patient was symptom-free at 2 months of follow-up with no signs of osteomyelitis on the radiographs. Thus this is the first case of AC joint septic arthritis in healthy individual. Being proximal to the shoulder joint, AC joint septic arthritis can be confused with the shoulder joint septic arthritis. Thus, high index of suspicion is required for accurate diagnosis.

© 2018 Daping Hospital and the Research Institute of Surgery of the Third Military Medical University. Production and hosting by Elsevier B.V. This is an open access article under the CC BY-NC-ND license (<http://creativecommons.org/licenses/by-nc-nd/4.0/>).

Introduction

Septic arthritis is the inflammation of the joint due to infection, usually due to bacteria commonly affecting pediatric population and elderly immunocompromised individuals in knee, hip and shoulder joints. Septic arthritis of acromioclavicular (AC) joint is a rare entity. It is generally seen in patients who are immunocompromised due to acquired immune deficiency syndrome (AIDS), chronic steroid use, intravenous drug use and lymphoma.¹ Diagnosis is made by clinical features along with the laboratory and radiological examination. X-ray may show enlarged joint space and destruction of joint. Ultrasound and magnetic resonance imaging may also be helpful to make diagnosis.² Aspiration of AC joint should be performed to identify the organism which is commonly

Staphylococcus or Streptococcus species.² Primary treatment is intravenous antibiotics and surgical debridement.

Case report

A nine years old girl presented to orthopedic emergency room with history of pain in left shoulder for four days associated with high-grade fever. There was no history of trauma, no previous or present history of any other joints pain, and no history suggestive of any immunocompromised state. On general examination, no other significant finding was found. Girl was febrile with temperature around 38.5 °C. On local examination, a swelling of around 3–4 cm in diameter was present over left AC joint region with raised local temperature, tenderness on palpation and positive response in fluctuation test. Range of movements at the shoulder joint was pain free except abduction beyond 90°.

Informed written consent for publication of this case had been taken from parents of the patient.

Complete blood count, erythrocyte sedimentation rate (ESR), C-reactive protein (CRP), seropositivity markers including human

* Corresponding author.

E-mail address: saurabhdutt22@yahoo.com (S. Dutt).

Peer review under responsibility of Daping Hospital and the Research Institute of Surgery of the Third Military Medical University.

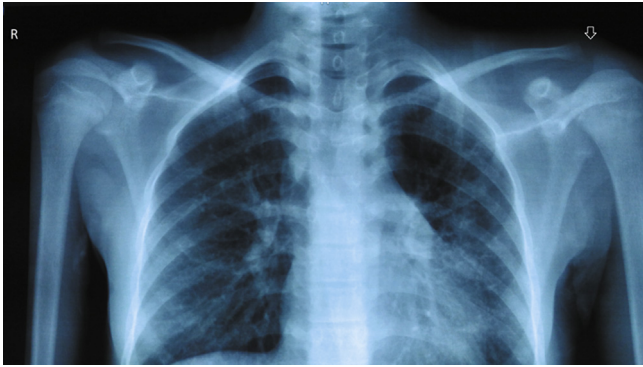

Fig. 1. Increased left AC joint space (arrow).

immunodeficiency virus (HIV), hepatitis B, C, X-ray chest with bilateral AC joint, ultrasound of AC joint with ipsilateral shoulder and non-contrast computed tomography (NCCT) of left shoulder were the initial investigations obtained. Total leukocytes count was $18.7 \times 10^9/L$ with 80% of neutrophils. ESR was 28 mm/1 h. CRP was 12 mg/L. HIV, hepatitis B, C had negative titers. X-ray showed enlarged left AC joint space (Fig. 1). Ultrasound revealed hypo-echoic collection in the AC joint and the surrounding region. Ultrasound of ipsilateral shoulder did not show any collection. NCCT showed a lytic lesion over lateral end of clavicle in axial cut (Fig. 2). The above investigations confidently ruled out the most common differential of a septic arthritis involving the gleno-humeral joint.

Aspiration was done for the affected region. The aspirate was thick and purulent in nature, revealing gram positive cocci in clusters on Gram staining (Fig. 3). Arthrotomy and thorough lavage of AC joint was done by using incision along the anterosuperior margin of acromion and lateral one fourth of clavicle. Intra-operatively purulent collection was seen with erosion of lateral end of clavicle. Periosteal elevation of lateral one fourth of clavicle and destruction of articular disc (Fig. 4) were present.

The pus was sent for culture and sensitivity study. Closure was done over negative suction drain (Fig. 5). Chest arm bandage was applied to ensure immobilization. Empirical intravenous injection of antibiotics (ceftriaxone and amikacin) was started immediately post operation. Pus culture grew Methicillin Resistant Staphylococcus Aureus (MRSA) after 48 hours that was sensitive to amikacin, gentamicin, erythromycin and teicoplanin. Following this report ceftriaxone was stopped and erythromycin was started.

After operation, patient remained in a non febrile state with healthy suture line on the 4th day (Fig. 6). The values of ESR and CRP decreased, respectively on 26 mm/1 h and 9 mg/L on the

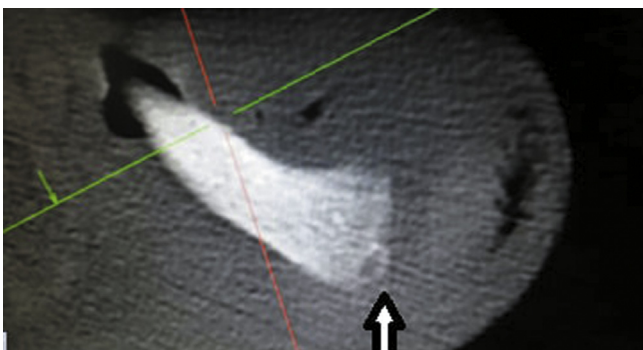


Fig. 2. Lytic lesion at articular surface of clavicle (arrow).

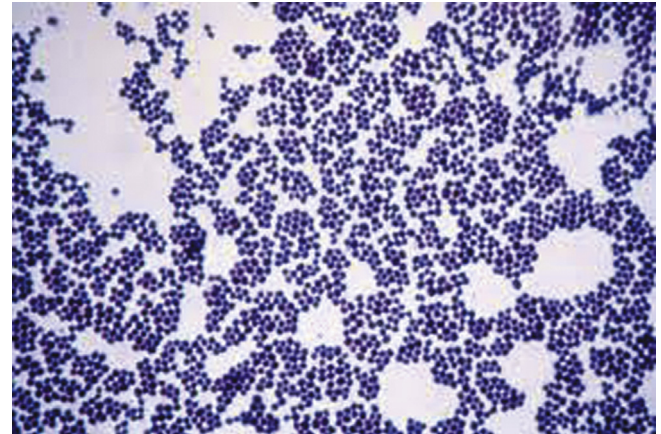


Fig. 3. Gram positive cocci in clusters.

4th day. On day 7, ESR and CRP dropped to 23 mm/1 h and 8 mg/L. Sutures were removed on the 14th day. Range of motion of shoulder was initiated till tolerance after suture removal. Full pain free movement was achieved within 3 weeks of surgery. IV antibiotics were continued for 2 weeks followed by a period of 4 weeks of oral antibiotics. Patient was symptom free at six months of follow-up with no signs of osteomyelitis on the radiographs.

Discussion

Bacterial infectious arthritis most commonly affects larger joints of the body usually spread by hematogenous route. The common differential diagnosis should include traumatic synovitis, acute

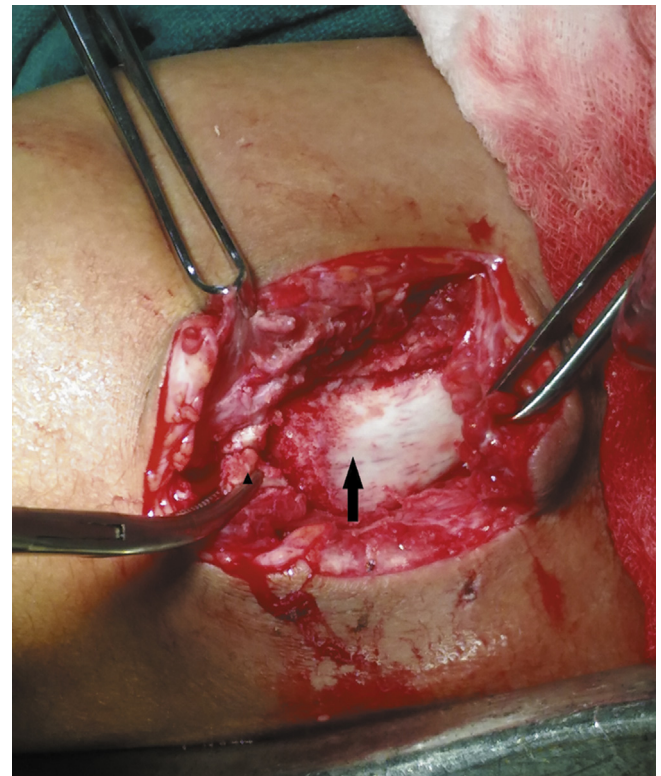


Fig. 4. Destroyed articular disc (arrow head), articular surface of clavicle and lateral end of clavicle devoid of periosteum.

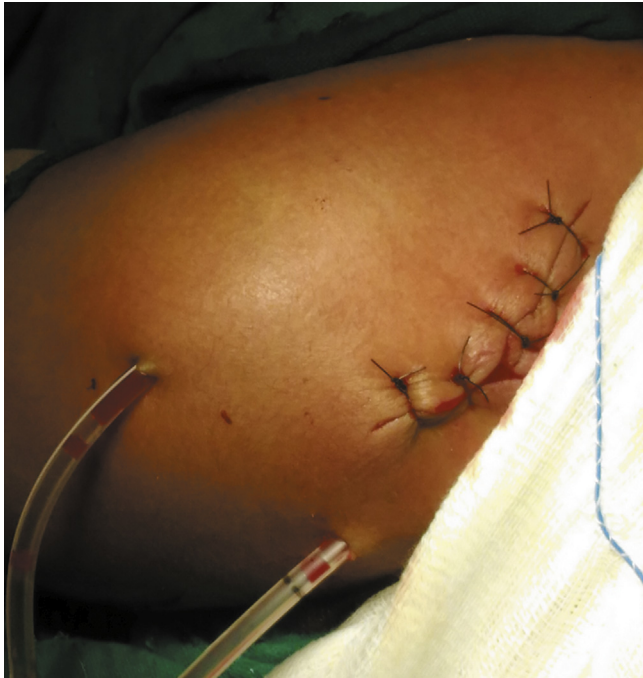

Fig. 5. Closure over negative suction drain.

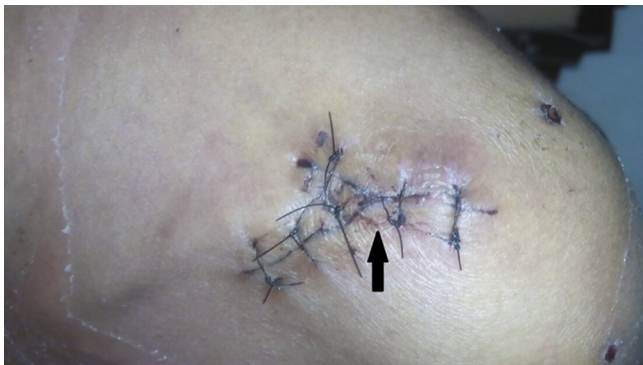

Fig. 6. Healthy suture line on 4th day post surgery (arrow head).

osteomyelitis, cellulitis, acute rheumatic fever, haemophilia, Henoch-Schoenlein purpura and Legg-Calve-Perthes disease.³

Contrary to the above facts, septic arthritis of AC joint is a rare entity and occurs in immunocompromised state. AC joint septic arthritis co-exists with shoulder septic arthritis in many cases, so incidence of AC joint septic arthritis alone is unknown.⁴ Clinical presentation includes pain over the joint, though shoulder range of motion may be fairly preserved. Ultrasound may show evidence of collection and increase in joint space. X-ray findings show enlarged joint space or erosion of the joint as was evident in our scenario hence impressing the role of clinic radiological assessment in these cases. Magnetic resonance imaging (MRI) shows soft tissue extension, but may not always be needed. Aspiration of joint followed by infiltration of saline may be used to know about extension to shoulder joint.

Mainstay of treatment includes adequate drainage of the joint and administration of antibiotics.⁵ Duration of antibiotic use should not be less than 4 weeks.⁶ Conventionally, the treatment of septic arthritis of the AC joint has been operative treatment usually by irrigation and debridement, followed by distal clavicle excision.^{1,7} However, aspiration and administration of IV antibiotics has also been documented.⁸ Adams and McDonald⁹ reported a patient with sarcoidosis and cryptococcal arthritis of the AC joint that was treated with irrigation and debridement, distal clavicle excision, and IV antibiotics. Blankenstein and colleagues¹⁰ also reported success with a similar protocol in a patient with AC joint septic arthritis due to infection of *Streptococcus viridans*. They resected the whole AC joint instead of simply resecting the distal clavicle. Zimmerman et al¹ also resected the AC joint, using oral antibiotics instead of IV antibiotics, in a patient with AIDS who had septic AC joint arthritis due to infection of *Staphylococcus aureus*.

To the best of our knowledge, the septic arthritis of the AC joint in a young immunocompetent patient has never been described in the English literature, making it a rare presentation which was successfully treated following arthroscopy and course of intravenous followed by oral antibiotics. This case emphasizes the role of meticulous clinicoradiological examination where septic arthritis of shoulder joint remains a very close differential diagnosis. Melania et al¹¹ in 2014 also published a series of 6 cases where all patients were in elderly age group with significant medical morbidities. In English literature, there are only 21 cases reported in detail (Table 1) with one case series of 6 patients recently published.¹¹

Table 1
Literature available on acromioclavicular joint septic arthritis.

No.	Study (year)	Age/sex	Organism grown	Risk factors/morbidities
1	Zimmermann et al ¹ (1989)	25/Male	Staph aureus	AIDS
2	Chiang et al ⁵ (2007)	55/Female	Strep. Pneumoniae	Chemotherapy, Multiple myeloma
3	Chiang et al ⁵ (2007)	79/Female	Group B Steptococcus	Unknown
4	Carey et al ⁶ (2010)	65/Female	Haemophilus parainfluenzae	Unknown
5	Iyenger et al ⁷ (2009)	42/Male	Staph aureus	Unknown
6	Blankstein et al ¹⁰ (1985)	48/Male	Strep. viridans	Unknown
7	Melania et al ¹¹ (2014)	52/male	Strep pneumoniae	Diabetes mellitus
8	Melania et al ¹¹ (2014)	73/male	Staphylococcus aureus	Chronic renal failure
9	Melania et al ¹¹ (2014)	46/female	Staph aureus	Disseminated breast neoplasia
10	Melania et al ¹¹ (2014)	71/female	Staph aureus	Chronic renal failure
11	Melania et al ¹¹ (2014)	53/male	Streptococcus agalactiae	Chronic renal failure
12	Melania et al ¹¹ (2014)	52/male	Streptococcus pneumoniae	Diabetes mellitus
13	Bossert et al ¹² (2010)	72/male	Staph aureus	Endocarditis
14	Bossert et al ¹² (2010)	55/Female	Staph aureus	Diabetes, Gout
15	Bossert et al ¹² (2010)	35/Male	Staph aureus	Hep B, Hep C, IV drug abuse
16	Bossert et al ¹² (2010)	62/Male	Staph aureus	Glucocorticoid infiltration
17	Hammel et al ¹³ (2005)	68/Male	Streptococcus B	Diabetes, Venous insufficiency ulcers
18	Noh et al ¹⁴ (2010)	63/Male	Staph aureus	Unknown
19	Cone et al ¹⁵ (2008)	63/Male	Staph aureus	Unknown
20	Laktasic et al ¹⁶ (2005)	44/Male	Staph aureus	Diabetes
21	Battaglia ¹⁷ (2008)	17/male	Ochrobactrum anthropi	Trauma
22	Our Study	9/female	Staph aureus	No associated risk factors

Thus, AC joint septic arthritis is an unusual case especially in an immunologically intact individual. Since it's a small joint, the destruction is at a fast rate, making early diagnosis crucial. Aspiration may be difficult due to anatomy of joint making clinic-radiological diagnosis more relevant. Adequate drainage followed by administration of antibiotics is the mainstay of treatment.

References

- Zimmerman 3rd B, Erickson AD, Mikolich DJ. Septic acromioclavicular arthritis and osteomyelitis in a patient with acquired immune deficiency syndrome. *Arthritis Rheum.* 1989;32:1175–1178.
- Widman DS, Craig JG, van Holsbeeck MT. Sonographic detection, evaluation and aspiration of infected acromioclavicular joints. *Skeletal Radiol.* 2001;30:388–392.
- Nade S. Acute septic arthritis in infancy and childhood. *J Bone Joint Surg Br.* 1983;65:234–241.
- Geirsson AJ, Statkevicius S, Víkingsson A. Septic arthritis in Iceland 1990–2002: increasing incidence due to iatrogenic infections. *Ann Rheum Dis.* 2008;67:638–643.
- Chiang AS, Ropiak CR, Bosco Iii JA, et al. Septic arthritis of the acromioclavicular joint – a report of four cases. *Bull NYU Hosp Jt Dis.* 2007;65:308–311.
- Carey TW, Jackson K, Roure R, et al. Acromioclavicular septic arthritis: a case report of a novel pathogen. *Am J Orthop (Belle Mead NJ).* 2010;39:134–136.
- Iyengar KP, Gudena R, Chitgopkar SD, et al. Primary septic arthritis of the acromio-clavicular joint: case report and review of literature. *Arch Orthop Trauma Surg.* 2009;129:83–86. <https://doi.org/10.1007/s00402-008-0747-y>.
- Sobrina J, Bosch X, Wennberg P, et al. Septic arthritis secondary to group C streptococcus typed as *Streptococcus equisimilis*. *J Rheumatol.* 1991;18:485–486.
- Adams R, McDonald M. Cryptococcal arthritis of the acromioclavicular joint. *N C Med J.* 1984;45(1):23–24.
- Blankstein A, Amsellem JL, Rubinstein E, et al. Septic arthritis of the acromioclavicular joint. *Arch Orthop Trauma Surg.* 1985;103(6):417–418.
- Melania MM, Lourdes MS, Anne RF, et al. Septic arthritis of the acromioclavicular joint: an uncommon location. *Reumatol Clin.* 2014;10:37–42. <https://doi.org/10.1016/j.reuma.2013.06.002>.
- Bossert M, Prati C, Bertolini E, Toussierot E, Wendling D. Septic Arthritis of the acromioclavicular joint. *Joint Bone Spine.* 2010;77:466–469.
- Hammel JM, Kwon N. Septic Arthritis of the acromioclavicular joint. *J Emerg Med.* 2005;29:425–427.
- Noh KC, Chung KJ, Yu HS, Koh SH, Yoo JH. Arthroscopic Treatment of septic arthritis of acromioclavicular joint. *Clin Orthop Surg.* 2010;2:186–190.
- Cone AL, Gauto A, Kazi A, et al. Staphylococcal septic arthritis of the small joints of the shoulder girdle. *J Clin Rheumatol.* 2008;14:181–182.
- Laktasic-Zerjavic N, Babic-Naglic D, Curkovic B, Potocki K, Soldo-Juresa D. Septic Acromioclavicular arthritis in a patient with diabetes mellitus. *Coll Antropol.* 2005;29:743–746.
- Battaglia TC. Ochrobactrum anthropi septic arthritis of the acromioclavicular joint in an immunocompetent 17-year-old. *Orthopedics.* 2008;31:606–608.