

## Post-fever retinitis – Newer concepts

Padmamalini Mahendradas, Ankush Kawali, Saurabh Luthra<sup>1</sup>, Sanjay Srinivasan, Andre L Curi<sup>2</sup>, Shrey Maheswari<sup>1</sup>, Imen Ksiai<sup>3</sup>, Moncef Khairallah<sup>3</sup>

Post-fever retinitis (PFR) is an infectious or para-infectious uveitic entity caused by bacterial or viral agents and seen mainly in tropical countries. Systemic symptoms such as joint pain, skin rash are common during the febrile stage. On the basis of only clinical presentation, it is difficult to pin-point the exact etiology for PFR. Serological investigations, polymerase chain reaction, and knowledge of concurrent epidemics in the community may help to identify the etiological organism. Bacterial causes of PFR such as rickettsia and typhoid are treated with systemic antibiotics, with or without systemic steroid therapy, whereas PFR of viral causes such as chikungunya, dengue, West Nile virus, and Zika virus have no specific treatment and are managed with steroids. Nevertheless, many authors have advocated mere observation and the uveitis resolved with its natural course of the disease. In this article, we have discussed the clinical features, pathogenesis, investigations, and management of PFR.

**Key words:** Chikungunya, dengue, post-fever retinitis, Rickettsia, systemic steroids, typhoid, West Nile virus, Zika virus

Post-fever retinitis (PFR) is an infectious or para-infectious uveitic entity caused by several viral, or bacterial agents commonly seen in tropical countries.<sup>[1,2]</sup> Ocular manifestations typically start developing within days to weeks after the onset of febrile illness. By the time patient seek ophthalmologist's attention their systemic signs are already fading and they are afebrile. We are presenting this review article to summarize the available literature on PFR caused by rickettsial infection, typhoid, dengue, West Nile, chikungunya and zika virus infections. This article highlights the systemic and ocular features, pathogenesis, investigations, management and visual outcome in PFR.

### Rickettsial Retinitis

Systemic rickettsial infection in India is known since the era of Second World War.<sup>[3]</sup> From Kashmir to Tamilnadu and West Bengal to Maharashtra, almost all Indian states reported several cases of systemic rickettsiosis, mainly Scrub typhus (ST).<sup>[3]</sup> Ocular manifestations of rickettsial diseases has been reported worldwide.<sup>[4-10]</sup> Systemic rickettsial diseases are now considered amongst reemerging diseases in India.<sup>[10]</sup>

Rickettsiae are obligate, intracellular, gram-negative bacilli residing in alimentary canal of arthropods such as lice, fleas, ticks and mites. Humans acquire the infection after being bitten by those insects and the bacilli then infect vascular endothelium

and reticuloendothelial cells. Three major categories of rickettsial diseases are known: the spotted fever group caused by *R. conorii*, *R. sibirica*, and *R. rickettsia*; the typhus group caused by *R. prowazekii* and *R. typhi*. and the ST group caused by *Orientia tsutsugamushi*. Later this has been re-classified as a new genera- *Orientia*.<sup>[11]</sup>

Diagnosis of rickettsial diseases are challenging due to non-specific systemic symptoms such as fever, myalgia, and headache. Maculopapular skin rash and presence of eschar (in ST) may give some clue to suspect rickettsial disease. A positive history of recent forest visits, insect bite, exposure to animals may aid the diagnosis. Although rickettsial organisms can be isolated from body fluids on different cell lines (Vero cell line culture),<sup>[12]</sup> serological tests remains the popular method: microimmunofluorescence, latex agglutination, indirect hemagglutination, immunoperoxidase assay, enzyme-linked immunosorbent assay and the "gold standard" immunofluorescence assay (IFA).<sup>[13]</sup> Unfortunately, those methods are costly and not readily available in many parts of the world. Despite less sensitivity and specificity, the cheaper, yet valuable diagnostic method, Weil Felix Test (WFT) is widely used in Indian set up. [Table 1] A study from north India recommended cut-off value as 1:80,<sup>[14]</sup> whereas studies from south have considered titers more than 1:160 for OX-K and more than 1:80 for OX-2 and OX-19 as significant.<sup>[15,16]</sup> A fourfold increase in the two sera within 1–2 week (s) (between

#### Access this article online

##### Website:

www.ijo.in

##### DOI:

10.4103/ijo.IJO\_1352\_20

#### Quick Response Code:



Department of Uveitis and Ocular Immunology, Narayana Nethralaya, Bengaluru, Karnataka, <sup>1</sup>Drishti Eye Institute, Dehradun, Uttarakhand, <sup>2</sup>National Institute of Infectious Diseases- INI-FIOCRUZ, Rio de Janeiro – Brazil, <sup>3</sup>Department of Ophthalmology, FattoumaBourguiba University Hospital, Faculty of Medicine, University of Monastir, Monastir, Tunisia

**Correspondence to:** Dr. Padmamalini Mahendradas, Narayana Nethralaya, Rajajinagar, Bangalore, India.  
E-mail: m.padmamalini@gmail.com

Received: 06-May-2020

Revision: 09-Jun-2020

Accepted: 20-Jul-2020

Published: 20-Aug-2020

This is an open access journal, and articles are distributed under the terms of the Creative Commons Attribution-NonCommercial-ShareAlike 4.0 License, which allows others to remix, tweak, and build upon the work non-commercially, as long as appropriate credit is given and the new creations are licensed under the identical terms.

**For reprints contact:** WKHLRPMedknow\_reprints@wolterskluwer.com

**Cite this article as:** Mahendradas P, Kawali A, Luthra S, Srinivasan S, Curi AL, Maheswari S, et al. Post-fever retinitis – Newer concepts. Indian J Ophthalmol 2020;68:1775-86.

**Table 1: Weil-Felix test interpretation**

OX2	OXK	OX19	Rickettsial sub-classification
+	-	+	Indian tick typhus (Spotted Fever)
-	-	+	Epidemic / Endemic typhus
-	+	-	Scrub typhus

acute and convalescent phase) is indicative of the infection.<sup>[14]</sup> Elevated white blood counts and thrombocytopenia (which is frequently confused with dengue fever) can be seen during early course of the disease.<sup>[3]</sup>

Systemic manifestations of ST have been widely reported and is considered as the most common rickettsioses followed by typhus fever.<sup>[8,14]</sup> A recent Indian study from North reported conjunctival hemorrhages and lid edema as ocular manifestations in their series, but no uveitis was noted.<sup>[17]</sup> A study from South India also did not mention any ocular involvement.<sup>[18]</sup> Very first series of 10 patients of presumed rickettsial retinitis diagnosed based on WFT reported no case of ST,<sup>[7]</sup> another series where ELISA IgM and IgG for *O. tsutsugamushi* was done in 8 patients tested negative in all.<sup>[8]</sup> A large cohort of epidemic retinitis noted only 0.03% cases positive for OX. Perhaps uveitis with retino-choroidal involvement in ST is known in literature and has been reported back in 1945–46.<sup>[19]</sup> They studied 451 patients with ST and found presence of uveitis in 1.3% of cases, although other intraocular manifestations such as engorgement of veins (67%), retinal oedema (36%), retinal haemorrhages (6.6%), exudates (4.9%), vitreous opacities (4.6%) were reported by the author. They also described histopathological findings of 9 eyes obtained at autopsy which revealed a subacute diffuse choroiditis with marked mononuclear cell infiltrates. Unfortunately, microbiological examination to rule out presence of the culprit organism in the ocular tissue was not reported by the author. Papilloedema and optic atrophy as well as inflammatory branch retinal vein occlusion post ST have been described.<sup>[20]</sup> ST is common in paediatric population, but ocular manifestations have rarely been described in small children [Fig. 1]. In most of above reports the diagnosis was based on WFT which is not a gold standard test for diagnosis of ST. Chawla *et al.* described a case where OX K was positive, but the gold standard indirect immunofluorescent antibody assay and IgM ELISA were negative for ST.<sup>[21]</sup>

Indian tick typhus (ITT) or Mediterranean spotted fever or Boutonneuse fever caused by *R. conorii* is found to be the common etiological agent for uveitis in the 2-case series from India.<sup>[7,8]</sup> A series from Tunisia, where the diagnosis was made using gold standard indirect immunofluorescence also reported ITT in 13 of 14 cases.<sup>[21]</sup> In all 3 series multifocal superficial retinitis was the common finding. Typically, ocular symptoms start 1-3 weeks after the fever. At the presentation to the ophthalmologist patients are afebrile and may have resolving skin rash or may give history of skin rash with fever. On slit-lamp examination mild to moderate circumcilliary congestion, subconjunctival haemorrhages may be evident. Vitreous inflammation also generally does not exceed grade 2 haze. Focal or multifocal cotton wool spot-like retinitis lesions of size ranged from ½ disc diameter to 3 disc diameters on the

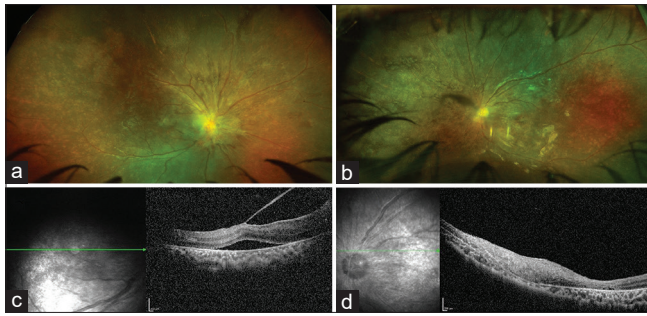
posterior pole, along the arcades and around the disc, with or without disc oedema or macular oedema with or without few hemorrhages is a typical fundus picture in the acute stage.<sup>[7,8]</sup> [Fig. 2]. Clinically evident vasculitis is rarely seen but fundus fluorescein angiography frequently shows vasculitic leakage.<sup>[7,8]</sup> Optical coherence tomography (OCT) is helpful to monitor macular edema and to differentiate other causes of retinitis by showing primary involvement of inner retina with after shadowing in contrast to full thickness involvement in CMV or toxoplasma retinitis [Fig. 2].

Whether rickettsial retinitis is as a result of direct invasion of the organism in the retinal tissue or an immune driven process is debatable. There were reports of 3 of 10 patient's case series treated with only steroids showing resolution.<sup>[7]</sup> and a single case of 14 patient's case series showing spontaneous resolution.<sup>[21]</sup> In contrast there are few reports where worsening of retinitis was noted with steroid only treatment which dramatically reversed after starting systemic doxycycline therapy.<sup>[22,23]</sup> A very recent study on epidemic retinitis with macular edema with 8 cases positive for WFT received only antibiotics (doxycycline or ciprofloxacin) without systemic or intraocular or periocular steroids and showed resolution of macular oedema and retinitis in 1-2 months' time.<sup>[24]</sup> It was arguable that the resolution of retinitis and macular oedema was a natural course of disease or the antibiotics really had a role to play. Neither the old histopathological study of 9 patients of ST commented on presence or absence of the organism in ocular tissue,<sup>[19]</sup> nor the recent molecular diagnostic study of PFR isolated any rickettsial organism from ocular fluid so far.<sup>[25]</sup> Indirect evidence of presence of rickettsial organism in ocular fluid has been reported by Mendivil *et al.* in a rare case of rickettsial endophthalmitis.<sup>[26]</sup> Taking into consideration angiotrophism of rickettsial organisms, few reported cases of worsening retinitis with steroid only treatment and the reported case of endophthalmitis, despite inadequate literature on presence of the organism in ocular tissue, current treatment recommendation remains: oral doxycycline (the drug of choice) 100 mg twice a day for 2-3 weeks along with steroids titrated to the amount of intraocular inflammation, although (steroids) can be avoided in the absence of optic neuritis or clinically evident retinal vasculitis.<sup>[24]</sup> Ciprofloxacin (except in Rocky Mountain Spotted Fever),<sup>[27]</sup> and azithromycin remains alternative to doxycycline therapy.<sup>[2,28]</sup> Intravitreal chloramphenicol has also been tried in a case of endophthalmitis.<sup>[26]</sup>

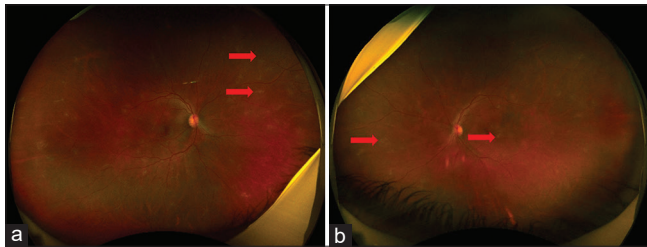
In conclusion, there is a growing evidence of rickettsial eye diseases in the literature and should be considered in a case of retinitis with a recent history of fever with skin rash. Although rickettsial retinitis with macular edema has aggressive presentation, overall visual prognosis is good without recurrences.

## Typhoid Retinitis

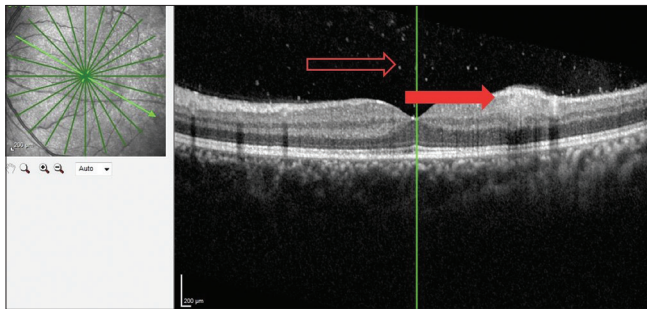
Typhoid fever affecting the eye has been reported as early as 1893.<sup>[29]</sup> Practically every layer of the eye can be affected. The role of typhoid fever in causing immune mediated retinitis has recently spiked interest in the ophthalmology community. The clinical features are similar to the other PFR sequelae described in patients who are immunocompetent and have had fever prior to the onset of ocular symptoms.



**Figure 1:** A 6-year-old girl child presented with decreased vision in both the eyes for 12 days, after an episode of fever with skin rash 25 days ago. Child had a black eschar and OX K on Weil Felix test was positive suggesting of Scrub typhus. Fundus examination revealed disc edema, hemorrhages and a thick epiretinal membrane (ERM) in OD (a), similar findings with posterior vitreous detachment in LE. (b) OCT scan confirmed vitreomacular traction with subretinal fluid (SRF) in OD (c) and showed indistinct retinal layer with thinning at the macula, minimal SRF with choroidal thinning in OS (d)



**Figure 3:** (a) Wide field fundus photography of a 35-year-old Indian Male of the right eye showing supero-nasal areas of sheathing (black red arrow) in a patient of post typhoid fever. (b) left eye showing retinitis patches (black red arrow)

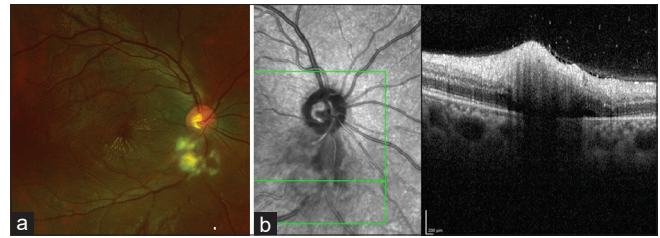


**Figure 5:** Optical coherence tomography of the left eye of the same patient showing posterior vitreous cells (red hollow arrow) and inner retinal involvement (solid red arrow)

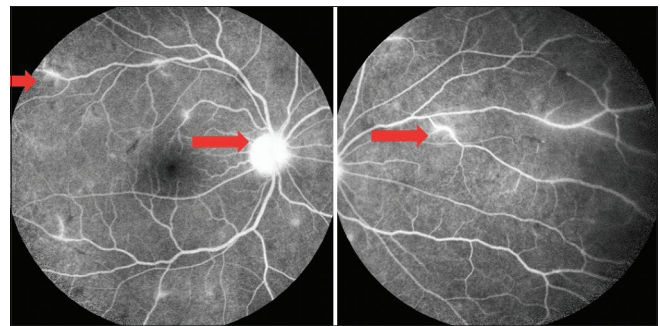
**Ocular manifestations**

Typhoid fever and its ocular manifestations can be described during acute stages of the disease or post-fever stages. During acute stages the patient can present with catarrhal conjunctivitis, ulcerative keratitis, keratomalacia, iridocyclitis, choroiditis, vitritis and optic neuritis and optic atrophy paresis of accommodation ptosis and abducens nerve palsy.<sup>[29]</sup>

Post-fever ocular signs described include focal or multifocal retinitis [Fig. 3a], with or without stellate maculopathy, vasculitis [Figs. 3b and 4], retinal venous occlusion due to vasculitis resulting in intraretinal haemorrhages, cotton wool



**Figure 2:** A 24-year-old female presented with complaints of blur vision in OD for 10 days preceding a viral fever as diagnosed by her physician. Investigations revealed positive WFT (OX2 and OX19) suggestive of ITT. Ocular examination showed normal anterior segments, but fundus exam revealed 1 + vitritis, cotton-wool spot such as retinitis lesions inferior to the disc with macular fan suggestive of resolving macular edema. (a) OCT scan passing over the retinitis lesion showed vitreous cells, thickening of inner retina with after shadowing and minimal subretinal fluid. (b)



**Figure 4:** Fundus fluorescein angiography of the same patient in the late phases showing staining of the disc with staining and leakage from the retinal veins

spots and retinal and optic nerve head edema, neuroretinitis, large neurosensory detachment, retinal detachment, frosted branch angiitis, pseudoretinitis pigmentosa, endophthalmitis, panophthalmitis, orbital cellulitis and tendonitis.<sup>[1,30-34]</sup> OCT may show hyperreflectivity in the inner retinal layers corresponding to the area of retinitis [Fig. 5].

**Diagnostic tests**

Blood culture isolation of *S typhi* is the diagnostic method of choice in typhoid fever. Incidence of positive isolates varies enormously.<sup>[35]</sup> However in a series from India 527 (9.2%) isolates were obtained from 5,735 suspected cases.<sup>[36]</sup> Blood culture identifies 45-70% of confirmed cases, even with the availability of newer continuous automated culture systems<sup>[36-38]</sup> Serological tests including the WIDAL test are widely available in endemic settings, although in the absence of paired clinical samples or background population sero surveillance data these tests perform poorly with low sensitivity and specificity.<sup>[36-39]</sup>

WIDAL test determines “O” and “H” antigens of *S. typhi* and “AH” and “BH” antigens of *S. paratyphi*. It is usually the third week after the onset of typhoid fever complications may set in and it is usually referred to as the week of complications.<sup>[1]</sup> The sensitivity of *S. typhi* detection from blood can be increased by using ox-bile as a selective culture media. Ox-bile reduces both coagulation and serum complement killing activity and causes the selective lysis of human rather than Salmonella cells.<sup>[40-43]</sup> A faster culture-Polymerase Chain Reaction (PCR) assay incorporating a brief preincubation in ox-bile along with

PCR amplification of the *S. typhi* flagellin gene, *fliC* has been described.<sup>[44,45]</sup> In a study by Darton *et al.* culture-PCR assay performed well, identifying extra typhoid cases compared with routine blood culture alone.<sup>[46]</sup>

A study done to compare PCR with blood culture, typhi-dot and Widal test for the diagnosis of typhoid in patients taking antibiotics showed positivity rate of PCR was significantly higher as compared to blood culture, Typhi-dot or Widal test for diagnosing typhoid in patients who were already taking antibiotics. This is useful in cases of post-fever immune mediated ophthalmic sequelae.<sup>[47]</sup>

In a study by Redhuan *et al.*<sup>[48]</sup> they found a higher sensitivity for IgA compared to either IgG/IgM antibodies in saliva, but for serum, IgG had a higher degree of sensitivity compared to IgA and IgM. Salivary IgA anti-50kDa antibody can be a potential biomarker for routine screening, whereas serum IgG is more suitable for confirmatory test due to its higher specificity in typhoid cases.<sup>[48]</sup>

In a study by Acharya *et al.*<sup>[49]</sup> they found high Widal titres were associated bilateral involvement, extensive lesions defined as disc involvement, retinitis, vasculitis and macular involvement and poor visual acuity which was found to be statistically significant.

### Pathogenesis

Typhoid retinitis may occur secondary to direct invasion of the *S. typhi* bacilli or immune mediated reaction attributed to post infectious immunologic effects which may lead to an immune response that reacts to self-antigens (for example, heat shock protein and myelin basic protein) or homology between retinal proteins and microbial peptides (similarity between S-antigen and microbial peptides such as yeasts, *Escherichia coli*, and hepatitis B virus) or molecular mimicry leading to autoimmunity (S antigen and interphotoreceptor retinoid binding protein-IRBP).<sup>[50]</sup> Endogenous endophthalmitis and panophthalmitis has been described post enteric fever which may be an example of direct invasion of the bacilli even though the ocular onset was reported 6 weeks to 3 months later.<sup>[40]</sup> *S typhi* tropism towards endothelial cells may cause vasculitis due to direct invasion of the vessel walls.<sup>[51]</sup>

Diagnosis of immune-mediated retinitis is often clinical, based on past history of a febrile illness (4 to 6 weeks prior). In our experience that patients had vitritis, multifocal retinitis, retinal vasculitis, choroidal neovascular membrane, neuroretinitis, retinal detachment and optic atrophy.

All the patients were treated with a combination of oral ciprofloxacin and tapering dose of steroids. Visual outcome was poor in our patients with retinal detachment and optic atrophy.

### Management

Treatment modalities described in the literature include topical non-steroidal anti-inflammatory medications, steroids in various forms including topical, subconjunctival, sub Tenon's, intravenous and oral steroids<sup>[32,33,49]</sup> Endophthalmitis secondary to typhoid was treated with intravitreal, topical and systemic antibiotic therapy. Parsplana vitrectomy was done in a patient with poor visual outcome and another patient ended up having evisceration following panophthalmitis.<sup>[50]</sup>

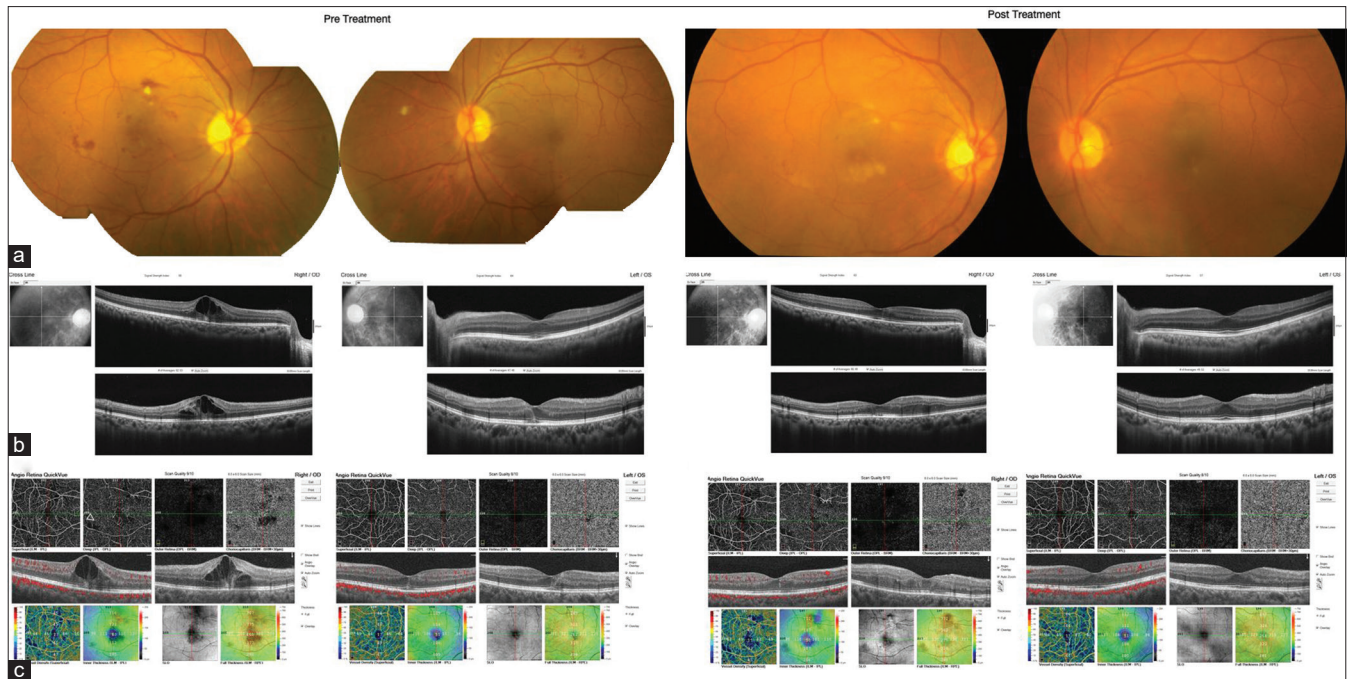
Post-treatment visual acuity in one series ranged between 6/60 to 6/12 in most of the cases and the fundus lesions almost

resolved leaving retinal pigment epithelial changes and foveal thinning in cases with severe macular involvement.<sup>[49]</sup>

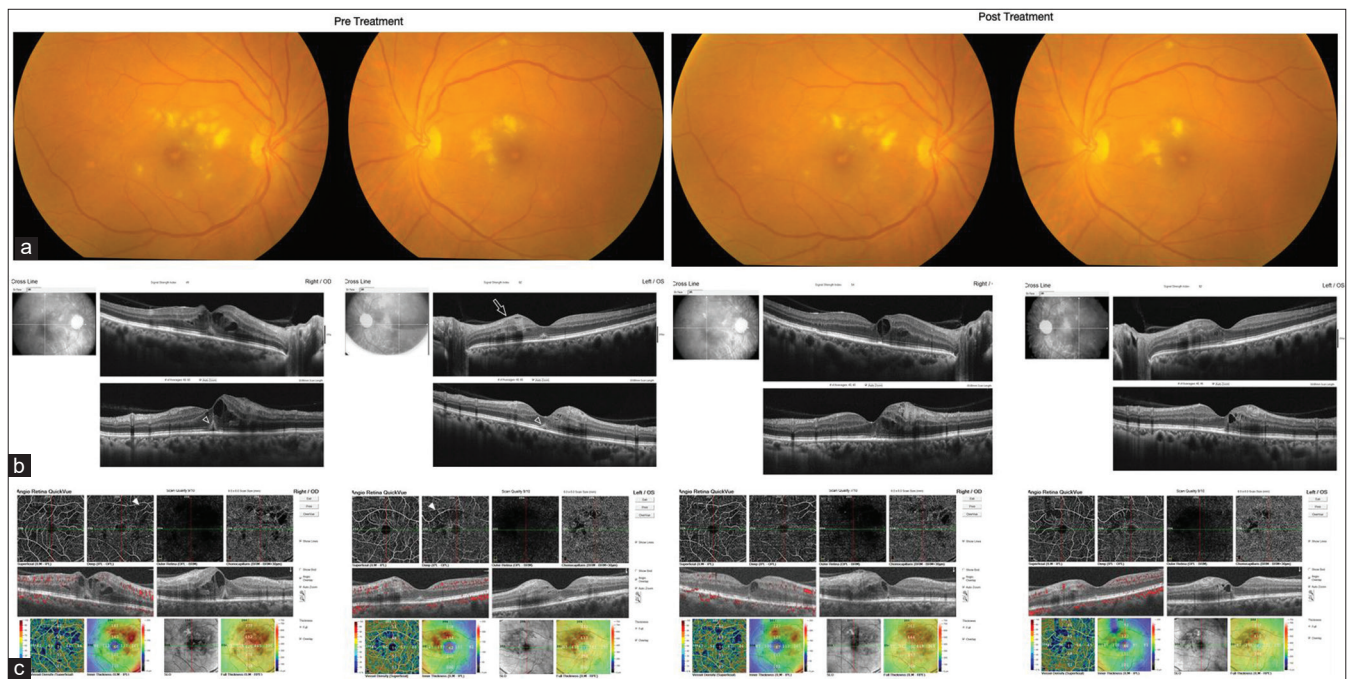
## Dengue Retinitis

Dengue virus belongs to the genus *Flavivirus* of the *Flaviviridae* family and has four serotypes (DENV-1, DENV-2, DENV-3 and DENV-4).<sup>[52]</sup> Dengue fever, an arboviral infection, is the most common mosquito-borne viral disease in humans. It is transmitted by infected female mosquitoes *Aedes aegypti* and *Aedes albopictus*.<sup>[53]</sup> The estimated annual incidence of infection is around 100 million.<sup>[54]</sup> Dengue fever usually presents as a mild self-remitting acute flu-like illness. Presenting symptoms include rash, nausea, vomiting, abdominal discomfort, acute onset high-grade fever, rhinitis and cough, headache, retro-orbital and musculoskeletal pain, and glandular enlargement.<sup>[52]</sup> Dengue haemorrhagic fever or dengue shock syndrome, a severe and potentially fatal form of infection, with plasma leakage, severe bleeding, respiratory distress and multi-organ failure occurs less commonly. Infection with one serotype provides lifelong immunity against subsequent infection by the same serotype but only partial immunity against infection with other serotypes.<sup>[55]</sup>

Clinically dengue infection is diagnosed by NS I antigen assays within the first week of illness, subsequently dengue serology IgM and IgG antibody testing are done.<sup>[56]</sup> Real-Time (RT)-PCR assay is a nucleic acid amplification assay that detects DENV serotypes 1, 2, 3 or 4 RNA from human serum or plasma.<sup>[57]</sup> Dengue fever related ocular involvement is rare, occurring in less than 10% of patients with symptomatic dengue virus infection.<sup>[58]</sup> Bilateral involvement is seen in majority of cases.<sup>[59]</sup> The symptoms and signs of dengue eye disease usually manifest in young individuals when they are at the nadir of thrombocytopenia.<sup>[60]</sup> Average onset time of dengue retinitis was seven days (range 1-28 days) after the onset of fever.<sup>[58]</sup> This five to seven day delay in presentation after the onset of dengue fever is thought to be due to the immune-mediated pathophysiology of dengue-related eye disease.<sup>[59]</sup> The temporal correlation of thrombocytopenia and ocular complications has also been explained to occur due to endothelial dysfunction, immune complex deposition, or retinal capillary ischaemia.<sup>[58]</sup> A transient decrease in C4 levels in majority of patients suggesting immune complex mediated occlusive vasculopathy has been reported.<sup>[61]</sup> Also, visual recovery correlates with improvement of thrombocytopenia.<sup>[60,62,63]</sup> Though the exact mechanism is not clear, it is thought to involve antibody production, immune-complex deposition or production of autoantibodies.<sup>[64]</sup> The change in vascular permeability is believed to be due to FasL/Fas pathway mediated apoptosis of vascular endothelial cells induced by the dengue virus infection.<sup>[65-67]</sup> Though usually visual acuity is worse if there is foveolitis, it has been reported variously to range from 20/20 to counting fingers.<sup>[60,64,68]</sup> Posterior segment manifestations include retinitis [Figs. 6 and 7], retinal hemorrhages, vitreous hemorrhage, to vision threatening ones such as retinal vascular occlusion, foveolitis, macular oedema, and optic disc hyperaemia and oedema.<sup>[58,59,61,68]</sup> Sight-threatening complications have been reported in 5-8% of cases.<sup>[68]</sup> Fundus findings of yellow-orange lesions (foveolitis) corresponding to outer retinal changes on optical coherence tomography (OCT) are seen in 28%–34% patients with dengue maculopathy.<sup>[61,68-71]</sup> Multifocal chorioretinitis with retinal hemorrhages and retinal



**Figure 6:** A 58-year-old male presented with decreased vision in both eyes since 15 days, after an episode of high fever and testing positive for NS1 antigen. Fundus examination of both eyes revealed retinal hemorrhages and cotton wool spots (a). Structural OCT scan showed cystoid macular edema (b). OCT Angiography (c) showed decreased vessel density in deep retinal plexus and flow void areas (arrowhead outline). After treatment, Fundus examination revealed almost resolved retinal hemorrhages (a). OCT scan showed resolved cystoid macular edema (b). OCTA showed reduction in flow void areas (c)



**Figure 7:** A 50-year-old female presented with decreased vision in both eyes, H/o Fever and NS1 antigen was positive. Orange lesion at fovea termed foveolitis (a). Structural OCT scan (b) right eye showed cystoid macular edema, left eye showed inner retinal thickening (arrow outline), and both eyes showed subfoveal outer retinal thickening known as foveolitis (arrowhead outline). OCT A showed decreased vessel density in deep retinal plexus and flow void areas (arrow heads). After treatment reduced cotton wool spots (a). OCT showed resolving CME (b). OCTA showed reduction in flow void areas (c)

vasculitis, which after spontaneous resolution left residual nummular retinochoroiditis scars, has also been reported.<sup>[72]</sup>

Ocular investigations include visual fields, fundus fluorescein angiography (FFA), indocyanine green angiography (ICG),

OCT, SS-OCT angiography (SS-OCTA) and in specific cases to assess optic nerve function electrophysiology tests may be done.<sup>[73]</sup> Visual fields may reveal severe central field loss or sometimes more extensive loss in cases with maculopathy involving larger retinal vessels.<sup>[61]</sup> FFA findings include non-ischemic venular occlusion, vasculitis, arteriolar and/or venular leakage, and RPE hyperfluorescence. ICG in the middle to late phases reveals hypocyanescent spots corresponding to yellow dots and additional spots in areas with subclinical involvement, and large vessel hypercyanescence.<sup>[61]</sup> OCT findings include severe neurosensory retinal detachment, outer neurosensory retina-RPE thickening at the fovea (foveolitis) and neurosensory retina-RPE atrophy.<sup>[61]</sup> Dengue maculopathy has been classified based on OCT patterns into three types: Type 1 – perifoveal diffuse retinal edema, Type 2 – intraretinal CME with photoreceptor disruption, Type 3 – foveolitis with subfoveal outer retinal thickening.<sup>[64]</sup> Acute macular neuroretinopathy (AMN) associated with dengue are best visualized on near-infrared reflectance.<sup>[64,74,75]</sup> OCT changes in AMN are characterised acutely by hyperreflectivity of outer nuclear layer (ONL) and outer plexiform layer (OPL) and later by outer segment disruption and ONL thinning. Swept-source OCT (SS-OCT) analysis can show posterior vitreous cells, OPL and ONL hyperreflectivity, hyporeflexive cystoid spaces in inner nuclear layer (INL) and OPL, conical disruption of foveal contour involving all the retinal layers, OPL edema and disruption of external limiting membrane, ellipsoid zone and interdigitation zone.<sup>[76]</sup> The authors coined the term “dengue-induced inflammatory, ischemic foveolitis and outer maculopathy (DIII-FOM)” for these changes.<sup>[76]</sup> SS-OCTA has been reported to show disruption with distinct flow deficit areas involving superficial capillary plexus in 43.75% eyes, involving the deep capillary plexus in all the eyes, whereas not involving choriocapillaris in any of the eyes.<sup>[76]</sup> Multifocal electroretinography (mfERG) findings of decreased parafoveal or foveal responses have been reported.<sup>[70]</sup> Optic neuropathy, optic disc swelling and hyperemia with vision ranging from 6/6 to no light perception have been reported, though these are uncommon.<sup>[61,77]</sup> Treatment of dengue eye disease has largely been conservative, with spontaneous recovery.<sup>[57,59,73]</sup> In a large series of 41 patients, only 28 symptomatic patients were treated who had visual acuity of 20/40 or worse in the affected eye and had persistent or progressive deterioration of vision.<sup>[61]</sup> Those treated included 11 patients with oral prednisolone alone, 12 patients (with severely depressed (20/200 or worse) visual acuity and/or absence of improvement after 3 days of initial treatment) with intravenous methylprednisolone (IVMP) followed by oral prednisolone, 3 patients (unresponsive to IVMP) with intravenous immunoglobulins and intravenous hydrocortisone followed by oral steroids.<sup>[61]</sup> Additional treatment required in this series was periocular methylprednisolone in 10 eyes, intravitreal triamcinolone acetonide in 2 eyes, and topical prednisolone in 1 eye. Pars plana vitrectomy for vitreous hemorrhage or for retinal hemorrhage secondary to neovascularisation, and laser iridotomies for angle closure glaucoma have been reported.<sup>[58]</sup> Visual recovery from dengue ophthalmic complications has been shown to occur from a few days to a few months. However, persistent central or paracentral scotomas have been reported in about 59.5% eyes at 2-year follow-up.<sup>[64]</sup> Also, mfERG has shown persistence of areas of deranged retinal function corresponding to

scotomas up to a year after disease onset. Photoreceptor and bipolar cell loss have been thought to be responsible for this derangement.<sup>[55]</sup>

Majority of the patients who are suspected to have dengue associated ocular complications resolve on their own. The patients who have significant ocular impairment may be considered for oral or intravenous steroid treatment. Randomized, controlled trials are challenging to formulate considering multitude of presentations and lack of standardization in diagnosing these patients when presenting with ocular manifestations. Various dengue serotypes may cause infection in the same patient later in life and do not provide cross immunity.

It is of paramount importance for physicians to be aware and educate the patients about possible ocular symptoms long after the dengue has been treated.

### West Nile Retinitis

West Nile virus (WNV) infection is a zoonotic disease caused by a single-stranded RNA flavivirus and transmitted to human by a mosquito vector (type *Culex*) with wild birds serving as its reservoir.<sup>[78,79]</sup> The virus is widely distributed in Africa, Europe, Australia, and Asia, and, since 1999, it has spread throughout the Western hemisphere, including the United States, Canada, Mexico, the Caribbean and parts of Central and South America. The vast majority of infected patients are asymptomatic or develop a self-limiting febrile illness.<sup>[78]</sup> However, severe neurologic disease, frequently associated with advanced age and diabetes, was reported to occur in less than 1% of patients. Ocular involvement associated with WNV disease has been recently characterised, and a typical multifocal chorioretinitis was highlighted as the most common ocular manifestation.<sup>[80-83]</sup> Diagnosis of WNV infection is primarily based on clinical features, and is confirmed by positive serologic testing or PCR.<sup>[8]</sup> Prevention remains the mainstay of WNV infection control.

### Chorioretinitis

A typical bilateral or rarely unilateral multifocal chorioretinitis is the most common ocular manifestation of WNV infection, occurring in almost 80% of patients with acute WNV infection associated with neurologic illness.<sup>[80-82]</sup> Most patients have no ocular symptoms or present with mildly reduced vision or floaters. An associated mild or moderate vitreous inflammatory reaction is frequently observed. Active chorioretinal lesions present as circular, deep, yellowish lesions on ophthalmoscopy, with early hypofluorescence and late staining on fluorescein angiography (FA).<sup>[80]</sup> Inactive chorioretinal lesions appear as round, atrophic lesions with or without central pigmentation, and they usually show a typical “target-like appearance” with central hypofluorescence and peripheral hyperfluorescence on FA.<sup>[80-82]</sup> [Fig. 8] Chorioretinal lesions vary in number (from less than 20 to more than 50 per eye) and size (200-1500  $\mu\text{m}$ ). The posterior pole is involved in nearly 2/3 of eyes, the midzone and/or periphery in almost all eyes.<sup>[80-83]</sup> Chorioretinal lesions can be found in a scattered or linear pattern. Chorioretinal streaks are oriented radially in the nasal and peripheral fundus or arranged in a curvilinear pattern in the temporal posterior fundus.<sup>[83]</sup> The linear pattern of chorioretinitis [Fig. 1], appears to be related to the course of retinal nerve fibers<sup>[83]</sup> and represents a prominent feature, occurring in more than 80% of eyes with chorioretinitis. The streaks vary in number, from

one to more than 3 per eye, and in length approximately from 2 to 15 mm.

Indocyanine green angiography (ICGA) shows well-delineated hypofluorescent choroidal spots with more lesions than those appreciated clinically or on FA.<sup>[84]</sup>

Other imaging modalities are useful in the evaluation of chorioretinal involvement associated with WNV including SD-OCT, fundus autofluorescence, and OCTA.<sup>[85,86]</sup>

Retinal vascular involvement can occur in association with WNV infection including retinal hemorrhages, retinal vascular sheathing, retinal vascular leakage on FA, and, rarely, occlusive retinal vasculitis [Fig. 9].<sup>[80-82,86]</sup> Most documented cases of occlusive retinal vasculitis occurred in elderly patients with diabetes mellitus and were associated with severe irreversible visual loss.

Other ocular manifestations of WNV infection include anterior uveitis in the absence of chorioretinitis, retinitis, macular edema, segmental wedge-shaped zones of atrophy and mottling of the retinal pigment epithelium, unilateral acute maculopathy (personal unpublished data), optic disc swelling, optic neuritis, neuroretinitis, papilledema (personal unpublished data), and optic disc staining on FA.<sup>[80-82,87-89]</sup> Other reported neuro-ophthalmic manifestations include ocular nerve palsy and nystagmus. Congenital chorioretinal scarring secondary to intrauterine transmission of WNV infection has been reported.<sup>[81]</sup>

### Management

There is, at present, no proven treatment for WNV infection. In cases of severe systemic disease, intensive supportive therapy is indicated.<sup>[78,81,89]</sup> Antiviral agents, such as ribavirin and interferon, were found to be active only in vitro. Several clinical trials of interferon alpha-2b, interferon beta, and high-titer intravenous immunoglobulin will allow new and more effective therapeutic approaches to emerge in future.<sup>[90-92]</sup>

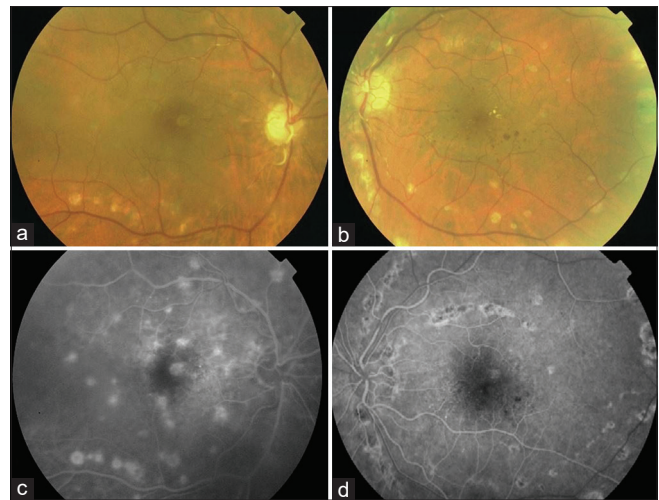
Specific ophthalmic treatments that may be required include topical steroids for anterior uveitis, peripheral retinal photocoagulation for neovascularization owing to occlusive vasculitis, pars plana vitrectomy for non-clearing vitreous hemorrhage or tractional retinal detachment, and intravitreal injection of anti-vascular endothelial growth factor agent for choroidal neovascularization or macular edema.<sup>[81,89,93,94]</sup>

Prevention is the mainstay of WNV infection control. To date, there is no vaccination available for WNV.<sup>[78,89,91]</sup>

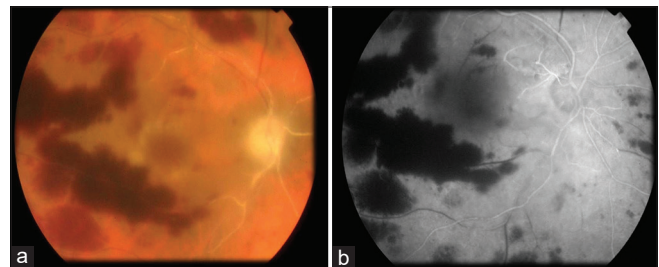
### Chikungunya Retinitis

Chikungunya virus is a single-stranded RNA virus belongs to the genus alphavirus in the family Togaviridae. It is transmitted to humans by the bite of infected Aedes group of mosquitoes, primarily *Aedes aegypti*,<sup>[95]</sup> chikungunya fever is caused by chikungunya virus, first described by Robinson,<sup>[96]</sup> and Lumsden,<sup>[97]</sup> in 1955. Epidemic of chikungunya fever has been reported from different parts of the world.<sup>[98,99]</sup>

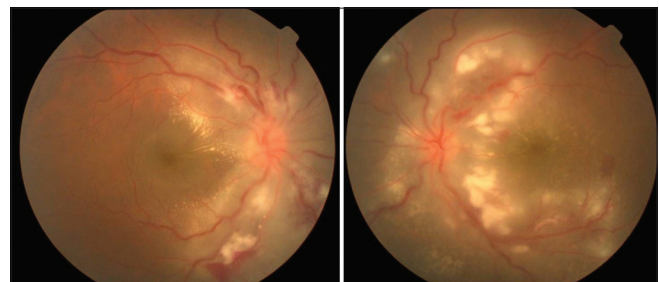
Chikungunya virus was recognized to cause illness that was self limiting and characterised by sudden onset of fever with chills, headache, malaise, arthralgia or arthritis, skin rash, vomiting, lower back ache and myalgia.<sup>[100]</sup> Incubation period



**Figure 8:** (a and b) Fundus photography in a 64-year-old diabetic patient with serologically proven WNV infection shows multiple deep chorioretinal lesions, diffuse periarterial sheathing, and moderate diabetic retinopathy with macular edema. (c and d) Mid-phase fluorescein angiograms shows inactive chorioretinal lesions, with a target-like appearance (central hypofluorescence and peripheral hyperfluorescence) more evident in the left eye. Several chorioretinal lesions extend in a linear pattern from the optic disc. Note the presence of retinal capillary leakage resulting from diabetic maculopathy



**Figure 9:** (a) Fundus photography in a 62-year-old diabetic patient with serologically confirmed WNV infection shows extensive deep retinal hemorrhages, retinal whitening, and diffuse periarterial sheathing. (b) Fluorescein angiography shows extensive areas of retinal capillary non-perfusion consistent with occlusive retinal vasculitis, with associated peripheral inactive chorioretinal lesions



**Figure 10:** A 49-year-old male, presented with complaints of decreased vision in both the eyes for 14 days, after an episode of fever with skin rash 6 weeks back. On investigation, Chikungunya Ig M antibody was positive. Ocular examination revealed vitritis +, hyperemic disc, retinitis, retina hemorrhages in both eyes with incomplete macular star in the right eye secondary to chikungunya retinitis

is about 1-12 days. Although chikungunya fever typically lasts for 3-7 days, certain patients experience persistent joint pain for

months and occasionally years after the initial onset of illness. Neurological complications such as meningoencephalitis have been reported during the Indian outbreak as well as the French Reunion island's outbreak.<sup>[101]</sup>

Ocular manifestations can present along with the systemic illness or after the systemic illness. It can be bilateral or unilateral presentation.<sup>[102]</sup> The systemic manifestation of the fever may be related to viraemia and the exact mechanism of ocular involvement following chikungunya infection remains unknown. Simultaneous occurrence of systemic and ocular disease suggests the possibility of direct viral involvement in the eye. Late involvement of ocular tissue suggests a delayed immune response.<sup>[102]</sup>

Patients may present with history of loss of vision, blurred vision, color vision defect, central or centrocecal scotoma and peripheral field defects. Anterior segment may be normal with normal intraocular pressure. Posterior segment involvement may manifest as retinitis,<sup>[102-107]</sup> neuroretinitis,<sup>[107,108]</sup> choroiditis,<sup>[105,109]</sup> and optic neuritis.<sup>[110,111]</sup> Retinitis usually present with vitritis, hyperaemia of the disc, retinal edema, retinal haemorrhages, [Fig. 10], and retinal vascular involvement.<sup>[112,113]</sup> Fundus fluorescein angiography can show early hypofluorescence with late hyperfluorescence in the areas of retinitis,<sup>[102]</sup> vascular leaks with or without capillary non-perfusion.<sup>[102]</sup> Optical SD-OCT may reveal hyper-reflective lesions in inner retina with after shadowing corresponding to the area of retinitis, with hyporeflectivity corresponding to the areas of serous retinal detachment.<sup>[102]</sup>

The majority of patients with chikungunya retinitis recover well over 10 to 12 weeks, with only subtle retinal pigment epithelial changes. Optic disc pallor and macular ischemic changes account for the poor visual outcome seen in a minority of these patients.<sup>[113]</sup> OCTA can show loss of vascular density in superficial and deep capillary plexus and hyporeflective area suggestive of flow deficit in the choriocapillary layer.<sup>[114,115]</sup>

As a rule, recurrences are not seen, but recently a case of recurrent chikungunya retinitis has been reported by Salceanu *et al.*<sup>[114]</sup> In their case the patient had chikungunya fever 1 year ago before the development of retinitis which responded to systemic steroids but recurred after the taper. Again, the morphology of the lesion in their case (mainly outer retinal involvement) was different than previously reported retinitis lesions.<sup>[102-107]</sup> They speculate CD 4 T lymphocyte mediated cell response and matrix metalloproteinase (MMP-2) responsible for the late manifestation of the disease.<sup>[114]</sup>

Virus isolation using molecular techniques such as PCR and serological tests (IgM and IgG antibodies) are routinely used to diagnose chikungunya infections in clinical practice.<sup>[101]</sup>

Although self-limiting, chikungunya retinitis can be treated with conservative line of management with topical and systemic steroids. Rarely intravitreal steroids are needed for faster resolution of the inflammation or when systemic steroids are contraindicated.<sup>[102]</sup> Unfortunately, there is no vaccine against chikungunya virus, thus prevention of the disease by the use of protective measures against mosquitoes is the mainstay control.

## Zika Retinitis

Zika virus is a flavivirus first isolated in Africa in 1947 in Rhesus monkey with fever in Zika Forest in Uganda,<sup>[116]</sup> the virus transmitted to humans through mosquitoes: *Aedes aegypti*. The first described case in humans occurred in Nigeria in 1952. First cases in Brazil were described in 2015 in Bahia. Samples from 24 patients with fever and skin rash were positive for Zika virus.<sup>[117]</sup> In 2016 an outbreak in the northeast of Brazil revealed a relation between Zika virus infection and malformation in newborns. Several cases of ocular changes and severe neurological malformation including microcephaly were described. Classically in acute infection individuals present with fever, skin rash, itching, and conjunctival hyperaemia (non-purulent conjunctivitis). General symptoms are very similar to those seen in dengue fever and chikungunya therefore the confirmed diagnosis rely on specific laboratory tests. In general, it is a benign disease, although few cases of neurological complications such as Guillain-Barre syndrome have been reported.<sup>[118]</sup>

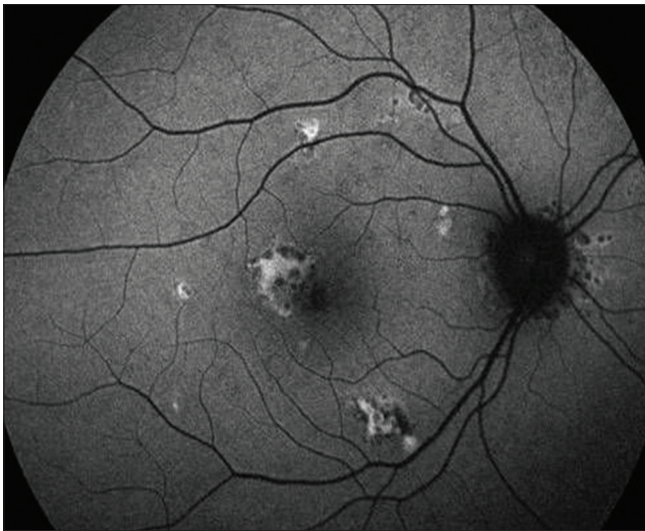
### Ocular disease

Ocular disease secondary to Zika virus infection was first described in newborn from an infected mother during pregnancy. Patient presented with macular atrophy and microcephaly.<sup>[119]</sup> Miranda *et al.* published other cases of congenital zika infection showing expanded spectrum of congenital zika syndrome.<sup>[120]</sup> Ocular changes include: macular atrophic lesion, retinal pigment epithelium mottling, retinal hemorrhages, strabismus, and congenital cataract. First confirmed case of ocular zika infection in Brazil had acute nongranulomatous anterior uveitis<sup>[121]</sup>

Henry *et al.* described a case of a 60-year-old woman from Puerto Rico who presented with impaired visual acuities and fundus changes compatible with resolving unilateral acute maculopathy. The diagnosis was based on a positive PCR in blood although it was performed 7 weeks after prodromal illness. The diagnosis was considered presumed since other causes of infectious uveitis and lymphoma were excluded.<sup>[122]</sup> Other cases were described suggesting an association between acute zika virus infection with retinitis, inner vasculopathy, pigment epithelium abnormalities.<sup>[123-125]</sup> Jimenes *et al.* reported a case of multifocal choroiditis [Fig. 10], secondary to acute zika virus infection. Ocular symptoms started just after onset of flulike illness, arthralgia and skin rash. The diagnosis was confirmed by a positive PCR in peripheral blood within 14 days of systemic symptoms. Despite poor visual acuity in the left eye, the patient was not treated with any medication. Patient was followed for 2 years and showed progressive improvement in visual acuities. OCT changes and autofluorescence findings [Fig. 11] also improved without any specific treatment.<sup>[126]</sup> Zaidi *et al.* described two cases, from Venezuela, of optic neuritis with seropositive anti-ZIKV IgG and negative IgM. Systemic clinical picture was consistent with the diagnosis of acute zika infection although both patients presented with a positive anti dengue virus IgG. In such cases is difficult to establish the exact etiology.<sup>[127]</sup>

It has been shown that Zika virus infect multiple retinal cell types and induces cell death.<sup>[128]</sup> Inoculation of zika virus in mouse eyes caused chorioretinal atrophy. Zika virus preferentially infects retinal-pigmented epithelium and Muller





**Figure 11:** Fundus autofluorescence shows hyper and hypo autofluorescence lesions suggestive of resolving Zika virus retinochoroiditis

cells in animal model. These findings may explain the retinal damage in congenital Zika syndrome and retinal pigmented epithelium changes in acute zika virus infection [Fig. 12].<sup>[129]</sup>

#### Diagnosis

Acute Zika virus infections do not have pathognomic ocular manifestations and it is difficult to differentiate from other arbovirus infections. PCR is the gold standard for the diagnosis, but it is important that it should be done within the first week of the disease from the blood or 14 days of the disease from the urine.<sup>[130]</sup> Serology test is not reliable due to cross reaction with other flavi virus especially dengue.

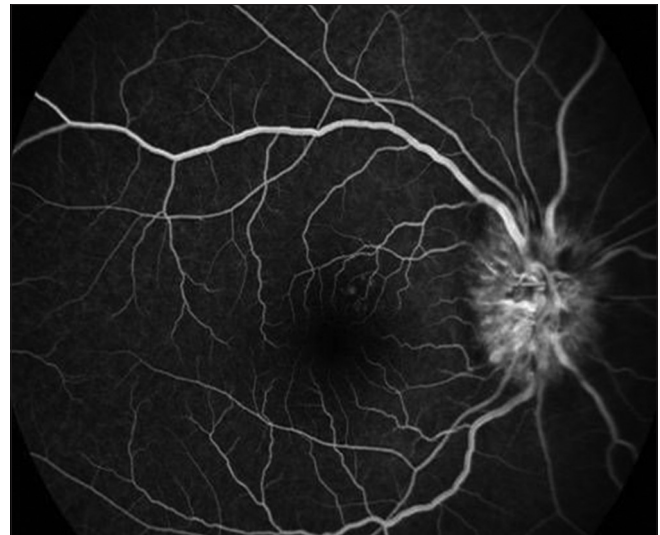#### Treatment

There is no specific treatment available. Treatment is symptomatic and prevention is the only effective action to avoid the disease. In cases of anterior uveitis treatment with topical steroids have shown good response. In congenital zika syndrome rehabilitation includes surgery (strabismus, congenital cataract) and amblyopia treatment. In acute cases close follow-up is important to monitor the resolution which is possible without any treatment.

Zika virus infection can be acquired of congenital. Although rare, intraocular acquired Zika virus infection has a self-limiting course and a good outcome. The diagnosis is based on PCR from peripheral blood during acute phase. Prevention is the only way to avoid zika virus infection.

#### Conclusion

In summary, PFR is a group of infectious or para-infectious uveitides caused by various viral and bacterial agents. Due to its seasonal variation and correlation with community outbreaks as documented for rickettsia, dengue, chikungunya, and similar morphological ophthalmoscopic picture, it has also been named as “epidemic retinitis.”<sup>[2]</sup> Serological investigations and molecular diagnostics are required to pin point exact etiological agent. In most of the cases the course of the disease is self-limiting with good visual outcomes without any recurrences. And hence many authors opt for observation,



**Figure 12:** Fundus fluorescein angiography of the right eye showing early staining of the optic disc head with multiple areas of hyperfluorescence superonasal to the macula

whereas others consider treating bacterial PFR with antibiotics, with or without steroids and viral PFR with systemic, periocular or intraocular steroid therapy. Randomized placebo-controlled trials are needed to recommend standard of care management for PFR.

#### Financial support and sponsorship

Nil.

#### Conflicts of interest

There are no conflicts of interest.

#### References

1. Vishwanath S, Badami K, Sriprakash KS, Sujatha BL, Shashidhar SD, Shilpa YD. Post-fever retinitis: A single center experience from South India. *Int Ophthalmol* 2014;34:851-7.
2. Kawali A, Mahendradas P, Mohan A, Mallavarapu M, Shetty B. Epidemic retinitis. *Ocul Immunol Inflamm* 2019;27:571-7.
3. Rahi M, Gupte MD, Bhargava A, Varghese GM, Arora R. DHR-ICMR Guidelines for diagnosis & management of Rickettsial diseases in India. *Indian J Med Res* 2015;141:417-22.
4. Kato T, Watanabe K, Katori M, Terada Y, Hayasaka S. Conjunctival injection, episcleral vessel dilation, and subconjunctival hemorrhage in patients with new Tsutsugamushi disease. *Jpn J Ophthalmol* 1997;41:196-9.
5. Khairallah M, Ladjimi A, Chakroun M, Messaoud R, Yahia SB, Zaouali S, et al. Posterior segment manifestations of rickettsia conorii infection. *Ophthalmology* 2004;111:529-34.
6. Parola P, Fenollar F, Badiaga S, Brouqui P, Raoult D. First documentation of *Rickettsia conorii* infection (Strain Indian Tick Typhus) in a Traveler. *Emerg Infect Dis* 2001;7:909-10.
7. Kawali A, Mahendradas P, Srinivasan P, Yadav NK, Avadhani K, Gupta K, et al. Rickettsial retinitis-an Indian perspective. *J Ophthalmic Inflamm Infect* 2015;5:37.
8. Balasundaram MB, Manjunath M, Baliga G, Kapadi F. Ocular manifestations of *Rickettsia conorii* in South India. *Indian J Ophthalmol* 2018;66:1840-4.
9. Sankar S, Kulkarni S, Manjoo CS, Murthy NY. Rare ophthalmic manifestations of rickettsial infections. *Int J Adv Res* 2017;5:1027-31.

10. Rathi N, Rathi A. Rickettsial infections: Indian perspective. *Indian Pediatr* 2010;47:157-164.
11. McLeod MP, Qin X, Karpathy SE, Gioia J, Highlander SK, Fox GE, *et al.* Complete genome sequence of *Rickettsia typhi* and comparison with sequences of other rickettsiae. *J Bacteriol* 2004;186:5842-55.
12. Tello-Martin R, Dzul-Rosado K, Zavala-Castro J, Lugo-Caballero C. Approaches for the successful isolation and cell culture of American Rickettsia species. *J Vector Borne Dis* 2018;55:258-64.
13. Mahajan SK, Kashyap R, Kanga A, Sharma V, Prasher BS, Pal LS. Relevance of Weil-Felix test in diagnosis of scrub typhus in India. *J. Assoc. Physicians India* 2006;54:619-21.
14. Mittal V, Gupta N, Bhattacharya D, Kumar K, Ichhpujani RL, Singh S, *et al.* Serological evidence of rickettsial infections in Delhi. *Indian J Med Res* 2012;135:538-41.
15. Ajantha GS, Patil SS, Chitharagi VB, Kulkarni RD. Rickettsiosis: A cause of acute febrile illness and value of Weil-Felix test. *Indian J Public Health* 2013;57:182-3.
16. Roopa KS, Karthika K, Sugumar M, Bammigatti C, Shamanna SB, Harish BN. Serodiagnosis of scrub typhus at a Tertiary Care Hospital from Southern India. *J Clin Diagn Res* 2015;9:DC05-7.
17. Pathania M, Amisha, Malik P, Rathaur VK. Scrub typhus: Overview of demographic variables, clinical profile, and diagnostic issues in the sub-Himalayan region of India and its comparison to other Indian and Asian studies. *J Family Med Prim Care* 2019;8:1189-95.
18. Stephen S, Kandhakumari G, Pradeep J, Vinithra SM, Siva PK, Hanifah M, *et al.* Scrub typhus in South India: A re-emerging infectious disease. *Jpn J Infect Dis* 2013;66:552-4.
19. Scheie HG. Ocular changes in scrub typhus. A study of 451 patients. *Trans Am Ophthalmol Soc* 1947;45:637-77.
20. Nagaki Y, Hayasaka S, Kadoi C, Matsumoto M, Sakagami T. Branch retinal vein occlusion in the right eye and retinal hemorrhage in the left in a patient with classical Tsutsugamushi disease. *Jpn J Ophthalmol* 2001;45:108-10.
21. Kahloun R, Gargouri S, Abroug N, Sellami D, Ben Yahia S, Feki J, *et al.* Visual loss associated with rickettsial disease. *Ocul Immunol Inflamm* 2014;22:373-8.
22. Chawla R, Pundlik GA, Chaudhry R, Thakur C. Rickettsial retinitis: Direct bacterial infection or an immune-mediated response? *Indian J Ophthalmol* 2017;65:1038-41.
23. Ayachit A, Ayachit G, Joshi S, Sameera VV. Commentary: Rickettsial retinitis - Direct bacterial infection or an immune-mediated response? *Indian J Ophthalmol* 2017;65:1041-3.
24. Kawali A, Srinivasan S, Mohan A, Bavaharan B, Mahendradas P, Shetty B. Epidemic retinitis with macular edema -Treatment outcome with and without steroids. *Ocul Immunol Inflamm* 2020;21:1-5.
25. Mahesh M, Arunasri K, Tyagi M, Pappuru RR, Sharma S, Shivaji S. Microbiome of vitreous in patients suffering with post fever retinitis. Poster presented at: The 2018 ARVO. July 28-29, 2018; Hyderabad, India.
26. Mendivil A, Cuartero V. Endogenous endophthalmitis caused by *Rickettsia conorii*. *Acta Ophthalmol Scand* 1998;76:121-2.
27. Biggs HM, Behravesh CB, Bradley KK, Dahlgren FS, Drexler NA, Dumler JS, *et al.* Diagnosis and management of Tickborne Rickettsial diseases: Rocky mountain spotted fever and other spotted fever group Rickettsioses, Ehrlichioses, and Anaplasmosis - United States. *MMWR Recomm Rep* 2016;65:1-44.
28. Raoult D, Drancourt M. Antimicrobial therapy of rickettsial diseases. *Antimicrob Agents Chemother* 1991;35:2457-62.
29. de Schweintz GE. Chapter I. In *The ocular complications of typhoid fever*, de Schweintz GE (eds.) *BiblioBazaar*. 2015. p. 2-5.
30. Prabhushanker M, Topiwalla TT, Ganesan G, Appandaraj S. Bilateral retinitis following typhoid fever. *Int J Retina Vitreous* 2017;10;3:11.
31. Hughes EH, Dick AD. The pathology and pathogenesis of retinal vasculitis. *Neuropathol Appl Neurobiol* 2003;29:325-40.
32. Relhan N, Pathengay A, Albini T, Priya K, Jalali S, Harry W Flynn Jr. A case of vasculitis, retinitis and macular neurosensory detachment presenting post typhoid fever. *J Ophthalmic Inflamm Infect* 2014;4:23.
33. Mathur JS, Nema HV, Char JN, Mehra KS. Post typhoid retinal detachment. *Indian J Ophthalmol* 1970;18:135-7.
34. Agarwal M, Malathi J, Biswas J. Frosted branch angiitis in a patient with typhoid fever. *Ocul Immunol Inflamm* 2018;26:776-8.
35. Sen R, Saxena SN. Typhoid fever in Delhi area: An assessment based on bacteriological and some epidemiological findings. *J Indian Med Assoc* 1968;50:297-304.
36. Parry CM, Wijedoru L, Arjyal A, Baker S. The utility of diagnostic tests for enteric fever in endemic locations. *Expert Rev Anti Infect Ther* 2011;9:711e25.
37. Wain J, Hosoglu S. The laboratory diagnosis of enteric fever. *J Infect Dev Ctries* 2008;2:421e5.
38. World Health Organisation. Background document: The diagnosis, treatment and prevention of typhoid fever. In: Department of Immunization, Vaccines and Biologicals. Geneva: WHO; 2003.
39. Keddy KH, Sooka A, Letsoalo ME, Hoyland G, Chagnat CL, Morrissey AB, *et al.* Sensitivity and specificity of typhoid fever rapid antibody tests for laboratory diagnosis at two sub-Saharan African sites. *Bull World Health Organ* 2011;89:640e7.
40. Coleman W. Short-duration typhoid fever. *Am J Med Sci* 1909;137:781e9.
41. Coleman W, Buxton BH. The bacteriology of the blood in convalescence from typhoid fever. With a theory of the pathogenesis of the disease. *J Med Res* 1909;21:83e93.
42. Watson KC. Laboratory and clinical investigation of recovery of *Salmonella typhi* from blood. *J Clin Microbiol* 1978;7:122e6.
43. Kaye D, Palmieri M, Rocha H. Effect of bile on the action of blood against *Salmonella*. *J Bacteriol* 1966;91:945e52.
44. Zhou L, Pollard AJ. A fast and highly sensitive blood culture PCR method for clinical detection of *Salmonella enterica* serovar Typhi. *Ann Clin Microbiol Antimicrob* 2010;9:14.
45. Zhou L, Pollard AJ. A novel method of selective removal of human DNA improves PCR sensitivity for detection of *Salmonella Typhi* in blood samples. *BMC Infect Dis* 2012;12:164.
46. Darton TC, Zhou L, Blohmke CJ, Claire J, Claire S, Waddington SB, *et al.* Blood culture-PCR to optimise typhoid fever diagnosis after controlled human infection identifies frequent asymptomatic cases and evidence of primary bacteraemia. *J Infect* 2017;74:358-66.
47. Munir T, Lodhi M, Ali S, Hussain Zaidi SB, Razak S. Early diagnosis of typhoid by PCR For *FliC<sub>d</sub>* gene of *salmonella typhi* in patients taking antibiotics early diagnosis of typhoid. *J Coll Physicians Surg Pak* 2015;25;9:662-6.
48. Redhuan NEM, Chin KL, Adnan AS, Ismail A, Balam P, Phua KK. Salivary Anti-50kDa antibodies as a useful biomarker for diagnosis of typhoid fever. *J Clin Diagn Res* 2017;11;6:DC10-3.
49. Acharya P, Ramamurthy LB, Venugopal KC, Manipur SR. Evaluation of posterior segment manifestations following typhoid fever-a clinical study. *Indian J Clin Exp Ophthalmol* 2018;4:421-425.
50. Kujur S, Ranga SN. Varied ocular complications of Enteric fever: A series of 9 cases. *Int J Basic Appl Med Sci* 2016;6:86-88.
51. Belizna C, Hamidou MA, Levesque H, Gillovin L, Shoenfeld Y. Infection and vasculitis. *Rheumatology* 2009;48:475-82.
52. World Health Organization. Dengue and dengue haemorrhagic fever—Fact sheet. 2009. Available from: <http://www.who.int/csr/disease/dengue/en>. [Last accessed on 2011 May 19].

53. Shuman EK. Global climate change and infectious diseases. *N Engl J Med* 2010;362:1061-3.
54. Available from: <https://www.cdc.gov/dengue/epidemiology/index.html>. [Last accessed on 2020 Mar 16].
55. Quek D, Barkham T, Teoh S. Recurrent bilateral dengue maculopathy following sequential infections with two serotypes of dengue virus. *Eye* 2009;23:1471-2.
56. Chan HBY, How CH, Ng CW. Definitive tests for dengue fever: When and which should I use? *Singapore Med J* 2017;58:632-5.
57. Alm E, Lindegren G, Falk KI, Lagerqvist N. One-step real-time RT-PCR assays for serotyping dengue virus in clinical samples. *BMC Infect Dis* 2015;15:493.
58. Yip VC, Sanjay S, Koh YT. Ophthalmic complications of dengue fever: A systematic review. *Ophthalmol Ther* 2012;1:2.
59. Lim WK, Mathur R, Koh A, Yeoh R, Chee SP. Ocular manifestations of dengue fever. *Ophthalmology* 2004;111:2057-64.
60. Chan DP, Teoh SC, Tan CS, Nab GK, Rajagopalan R, Prabhakaragupta MK. Ophthalmic complications of dengue. *Emerg Infect Dis* 2006;12:285-9.
61. Bacsal KE, Chee S, Cheng C, Flores JVP. Dengue-associated maculopathy. *Arch Ophthalmol* 2007;125:501-10.
62. Chlebicki MP, Ang B, Barkham T, Laude A. Retinal hemorrhages in 4 patients with dengue fever. *Emerg Infect Dis* 2005;11:770-2.
63. Tan MH, Tan PEZ, Wong ENXM, Chen FK. Structure and function correlation in a patient with dengue-associated maculopathy. *Clin Exp Ophthalmol* 2014;42:504-7.
64. Teoh SC, Chee CK, Laude A, Goh KY, Barkham T. Optical coherence tomography patterns as predictors of visual outcome in dengue-related maculopathy. *Retina* 2010;30:390-8.
65. Kanlaya R, Pattanakitsakul SN, Sinchaikul S, Chen ST, Thongboonkerd V. The ubiquitin-proteasome pathway is important for dengue virus infection in primary human endothelial cells. *J Proteome Res* 2010;9:4960-71.
66. Chen LC, Yeh TM, Lin YY, Wang YF, Su SJ, Chen CY, *et al.* The envelope glycoprotein domain III of Dengue virus type 2 induced the expression of anticoagulant molecules in endothelial cells. *Mol Cell Biochem* 2010;342:215-21.
67. Liao H, Xu J, Huang J. FasL/Fas pathway is involved in dengue virus induced apoptosis of the vascular endothelial cells. *J Med Virol* 2010;82:1392-9.
68. Su DH, Bacsal K, Chee SP, Flores JV, Lim WK, Cheng BC, *et al.*; Dengue Maculopathy Study Group. Prevalence of dengue maculopathy in patients hospitalized for dengue fever. *Ophthalmology* 2007;114:1743-7.
69. Munk MR, Jampol LM, Cunha Souza E, de Andrade GC, Esmili DD, Sarraf D, *et al.* New associations of classic acute macular neuroretinopathy. *Br J Ophthalmol* 2016;100:389-94.
70. Loh BK, Bacsal K, Chee SP, Cheng BC, Wong D. Foveolitis associated with dengue fever: A case series. *Ophthalmologica* 2008;222:317-20.
71. Ng AW, Teoh SC. Dengue eye disease. *Surv Ophthalmol* 2015;60:106-14.
72. Tabbara K. Dengue retinochoroiditis: A case report. *Ann. Saudi Med* 2012;32:530-3.
73. Solanke VN, Karmarkar MG, Mehta PR. Early dengue diagnosis: Role of rapid NS1 antigen, NS1 early ELISA, and PCR assay. *Trop J Med Res* 2015;18:95-9.
74. Li M, Zhang X, Ji Y, Ye B, Wen F. Acute macular neuroretinopathy in dengue fever: Short-term prospectively followed up case series. *JAMA Ophthalmol* 2015;133:1329-33.
75. Fawzi AA, Pappuru RR, Sarraf D, Lepp, McCannel CA, Sobrin L, *et al.* Acute macular neuroretinopathy: Long-term insights revealed by multimodal imaging. *Retina* 2012;32:1500-13.
76. Agarwal A, Aggarwal K, Dogra M, Kumar A, Akella M, Katoch D, *et al.* Dengue-induced inflammatory, ischemic foveolitis and outer maculopathy: A swept-source imaging evaluation. *Ophthalmol Retina* 2019;3:170-7.
77. Sanjay S, Wagle AM, Au Eong KG. Optic neuropathy associated with dengue fever. *Eye (Lond)* 2008;22:722-4.
78. Bai F, Thompson EA, Vig PJS, Leis AA. Current understanding of West Nile virus clinical manifestations, immune responses, neuroinvasion, and immunotherapeutic implications. *Pathogens* 2019;16:8.
79. Troupin A, Colpitts TM. Overview of West Nile virus transmission and epidemiology. *Methods Mol Biol* 2016;1435:15-8.
80. Khairallah M, Ben Yahia S, Ladjimi A, Zeghidi H, Ben Romdhane F, Besbes L, *et al.* Chorioretinal involvement in patients with West Nile virus infection. *Ophthalmology* 2004;111:2065-70.
81. Garg S, Jampol LM. Systemic and intraocular manifestations of West Nile virus infection. *Surv Ophthalmol* 2005;50:3-13.
82. Chan CK, Limstrom SA, Tarasewicz DG, Lin SG. Ocular features of West Nile virus infection in North America: A study of 14 eyes. *Ophthalmology* 2006;113:1539-46.
83. Khairallah M, Ben Yahia S, Attia S, Zaouali S, Ladjimi A, Messaoud R. Linear pattern of West Nile virus-associated chorioretinitis is related to retinal nerve fibres organization. *Eye (Lond)* 2007;21:952-5.
84. Khairallah M, Ben Yahia S, Attia S, Zaouali S, Jelliti B, Jenzri S, *et al.* Indocyanine green angiographic features in multifocal chorioretinitis associated with West Nile virus infection. *Retina* 2006;26:358-9.
85. Learned D, Nudleman E, Robinson J, Chang E, Stec L, Faia LJ, *et al.* Multimodal imaging of West Nile virus chorioretinitis. *Retina* 2014;34:2269-74.
86. Khairallah M, Kahloun R, Gargouri S, Jelliti B, Sellami D, Ben Yahia S, *et al.* Swept-source optical coherence tomography angiography in West Nile virus chorioretinitis and associated occlusive retinal vasculitis. *Ophthalmic Surg Lasers Imaging Retina* 2017;48:672-5.
87. Shukla J, Saxena D, Rathinam S, Lalitha P, Joseph CR, Sharma S, *et al.* Molecular detection and characterization of West Nile virus associated with multifocal retinitis in patients from southern India. *Int J Infect Dis* 2012;16:e53-9.
88. Sivakumar RR, Prajna L, Arya LK, Muraly P, Shukla J, Saxena D, *et al.* Molecular diagnosis and ocular imaging of West Nile virus retinitis and neuroretinitis. *Ophthalmology* 2013;120:1820-6.
89. Khairallah M, Chee SP, Rathinam SR, Attia S, Nadella V. Novel infectious agents causing uveitis. *Int Ophthalmol* 2010;30:465-83.
90. Kuno G. Serodiagnosis of flaviviral infections and vaccinations in humans. *Adv Virus Res* 2003;61:3-65.
91. Patel S, Sinigaglia A, Barzon L, Fassan M, Sparber F, Landmann SL. Role of NS1 and TLR3 in pathogenesis and immunity of WNV. *Viruses* 2019;11:603.
92. van Tol S, Atkins C, Bharaj P, Johnson KN, Hage A, Freiberg AN. VAMP8 contributes to the TRIM6-mediated type I interferon antiviral response during West Nile virus infection. *J Virol* 2020;94:e01454-19.
93. Seth RK, Stoessel KM, Adelman RA. Choroidal neovascularization associated with West Nile virus chorioretinitis. *Semin Ophthalmol* 2007;22:81-4.
94. Afshar AR, Hariprasad SM, Jampol LM, Sheth VS. Use of intravitreal bevacizumab to treat macular edema in West Nile virus chorioretinitis. *Arch Ophthalmol* 2012;130:396-8.
95. Calisher CH, Shope RE, Brandt W, Casals J, Karabatsos N, Murphy FA, *et al.* Proposed antigenic classification of registered arboviruses I (Togaviridae, Alphavirus). *Intervirology* 1980;14:229-32.

96. Robinson MC. An epidemic of virus disease in Southern Province, Tanganyika Territory, in 1952-53. I. Clinical features. *Trans R Soc Trop Med Hyg* 1955;49:28-32.
97. Lumsden WH. "An epidemic of virus disease in southern province, Tanganyika territory, in 1952-53; II. General description and epidemiology". *Trans Royal Society Trop Med Hyg* 1955;49:33-57.
98. Moizéis RNC, Fernandes TAAM, Guedes PMDM, Pereira HVB, Lanza DCF, Azevedo JWV, *et al.* Chikungunya fever: A threat to global public health. *Pathog Glob Health* 2018;112:182-94.
99. Silva JVJ Jr, Ludwig-Begall LF, Oliveira-Filho EF, Olivera RAS, Durges-carvalho R, Lopes TRR, *et al.* A scoping review of Chikungunya virus infection: Epidemiology, clinical characteristics, viral co-circulation complications, and control. *Acta Trop* 2018;188:213-24.
100. Mourya DT, Mishra AC. Chikungunya fever. *Lancet* 2006;368:186-7.
101. Schuffenecker I, Iteman I, Michault A, Murri S, Frangeul L, Vaney MC, *et al.* Genome microevolution of chikungunya viruses causing the Indian Ocean outbreak. *PLoS Med* 2006;3:e263.
102. Mahendradas P, Avadhani K, Shetty R. Chikungunya and the eye: A review. *J Ophthalmic Inflamm Infect* 2013;3:35. doi: 10.1186/1869-5760-3-35.
103. Mahendradas P, Ranganna SK, Shetty R, Balu R, Narayana KM, Babu RB, *et al.* Ocular manifestations associated with chikungunya. *Ophthalmology* 2008;115:287-291.
104. Parola P, de Lamballerie X, Jourdan J, Rovey C, Vaillant V, Minodier P, *et al.* Novel Chikungunya virus variant in travelers returning from Indian Ocean islands. *Emerg Infect Dis* 2006;12:1493-9.
105. Lalitha P, Rathinam S, Banushree K, Maheshkumar S, Vijayakumar R, Sathe P. Ocular involvement associated with an epidemic outbreak of Chikungunya virus infection. *Am J Ophthalmol* 2008;144:552-6.
106. Murthy KR, Venkataraman N, Satish V, Babu K. Bilateral retinitis following chikungunya fever. *Indian J Ophthalmol* 2008;56:329-31.
107. Mahesh G, Giridhar A, Shedbele A, Kumar R, Saikumar SJ. A case of bilateral presumed chikungunya neuroretinitis. *Indian J Ophthalmol* 2009;57:148-150.
108. Nair AG, Biswas J, Bhende MP. A case of bilateral chikungunya neuroretinitis. *J Ophthalmic Inflamm Infect* 2012;2:39-40.
109. Chanana B, Azad RV, Nair S. Bilateral macular choroiditis following Chikungunya virus infection. *Eye (Lond)* 2007;21:1020-21.
110. Mittal A, Mittal S, Bharati MJ, Ramakrishnan R, Saravanan S, Sathe PS. Optic neuritis associated with Chikungunya virus infection in South India. *Arch Ophthalmol* 2007;125:1381-6.
111. Rose N, Anoop TM, John AP, Jabbar PK, George KC. Acute optic neuritis following infection with Chikungunya virus in southern rural India. *Int J Infect Dis* 2011;15:e147-50.
112. Lee JH, Agarwal A, Mahendradas P, Lee CS, Gupta V, Carlos E, *et al.* Viral posterior uveitis. *Surv Ophthalmol* 2017;62:404-45.
113. Mahendradas P. Chikungunya in Uveitis: Text & Imaging. 1. New Delhi: Jaypee Brothers; 2009. p. 706-12.
114. Salceanu SO, Raman V. Recurrent Chikungunya retinitis. *BMJ Case Rep* 2018: bcr2017222864. doi: 10.1136/bcr-2017-222864.
115. Agarwal A, Choudhary T, Gupta V. Optical coherence tomography angiography features of bilateral retinopathy associated with Chikungunya fever. *Indian J Ophthalmol* 2018;66:142-5.
116. Dick G, Kitchen S, Haddow A. Zika Virus (I). Isolations and serological specificity. *Trans R Soc Trop Med Hyg* 1952;46:509-20.
117. Campos GS, Bandeira AC, Sardi SI. Zika virus outbreak, Bahia, Brazil. *Emerg Infect Dis* 2015;21:1885-6.
118. Broutet N, Krauer F, Riesen M, Khalakdina A, Almiron M, Aldighieri S, *et al.* Zika virus as a cause of neurologic disorders. *N Engl J Med* 2016;374:1506-9.
119. Freitas BP, Dias JRO, Prazeres J, Sacramento GA, Ko AI, Maia M, *et al.* Ocular findings in infants with microcephaly associated with presumed Zika virus congenital infection in Salvador, Brazil. *JAMA Ophthalmol* 2016;134:529-35.
120. Miranda HA 2<sup>nd</sup>, Costa MC, Frazão MAM, Simão N, Franchischini S, Moshfeghi DM. Expanded spectrum of congenital ocular findings in microcephaly with presumed Zika infection. *Ophthalmology* 2016;123:1788-94.
121. Furtado JM, Espósito DL, Klein TM, Teixeira-Pinto T, da Fonseca BA. Uveitis associated with Zika virus infection. *N Engl J Med* 2016;375:394-6.
122. Parke DW 3<sup>rd</sup>, Almeida DR, Albini TA, Ventura CV, Berrocal AM, Mitra RA. Serologically confirmed Zika-related unilateral acute maculopathy in an adult. *Ophthalmology* 2016;123:2432-3.
123. Singh MS, Marquezan MC, Omiadze R, Reddy AK, Belfort R Jr, May WN. Inner retinal vasculopathy in Zika virus disease. *Am J Ophthalmol Case Rep* 2018;10:6-7.
124. Henry CR, Al-Attar L, Cruz-Chacón AM, Davis JL. Chorioretinal lesions presumed secondary to Zika virus infection in an immunocompromised adult. *JAMA Ophthalmol* 2017;135:386-9.
125. Manangeeswaran M, Kielczewski JL, Sen HN, Xu BC, Ireland DDC, McWilliams IL, *et al.* ZIKA virus infection causes persistent chorioretinal lesions. *Emerg Microbes Infect* 2018;7:96.
126. Jimenez P, Kestelman E, Kestelman B, Vizzoni AG, Cerbino-Neto J, Curi ALL. Multifocal choroiditis secondary to acute Zika virus infection. *Ocul Immunol Inflamm* 2019;30:1-4.
127. Zaidi MB, De Moraes CG, Petitto M, Yopez JB, Sakuntabhai A, Simon-Loriere E, *et al.* Noncongenital severe ocular complications of Zika virus infection. *JMM Case Rep* 2018;5:e005152.
128. Zhao Z, Yang M, Azar SR, Soong L, Weaver SC, Sun J, *et al.* Viral retinopathy in experimental models of Zika infection. *Invest Ophthalmol Vis Sci* 2017;58:4355-4365. doi: 10.1167/iovs.17-22016. Erratum in: *Invest Ophthalmol Vis Sci* 2017;58:4799.
129. Singh PK, Guest JM, Kanwar M, Boss J, Gao N, Juzych MS, *et al.* Zika virus infects cells lining the blood-retinal barrier and causes chorioretinal atrophy in mouse eyes. *JCI Insight* 2017;23:e92340.
130. Laundry ML, George K. Laboratory diagnosis of Zika virus infection. *Arch Pathol Lab Med* 2017;114:60-7.