

Unusual presentation of eosinophilic enteritis as multiple strictures of small intestine

Sunil V. Jagtap,¹ Dhiraj B. Nikumbh,¹ Ashok Y. Kshirsagar,² Neha Ahuja¹

¹Department of Pathology; ²Department of Surgery, Krishna Institute of Medical Sciences, (KIMS) University and Krishna Hospital Karad, Maharashtra, India

Abstract

Eosinophilic enteritis is a rare disease of unknown etiology. It is characterized by eosinophilic infiltration of the bowel wall to a variable depth and symptoms associated with gastrointestinal tract depending upon the predominant layer involved. Diagnosis of eosinophilic enteritis requires a high index of suspicion and exclusion of various disorders that are associated with peripheral eosinophilia. We report a case of unusual presentation of eosinophilic enteritis clinically presenting as intestinal obstruction due to multiple strictures of the small bowel in an adult male.

Introduction

Eosinophilic enteritis is an extremely rare disease, involving the entire gastrointestinal tract (GIT), although stomach and duodenum are frequently involved sites.¹ The pathogenesis and etiology of eosinophilic enteritis remains unclear.² It is characterized by eosinophilic infiltration of the bowel wall to a variable depth and symptoms associated with gastrointestinal tract,² and enteritis occurs if there is involvement of the submucosal layer of the GIT. The defect in mucosal integrity may be responsible for localization of various antigens in the gut wall resulting in infiltration of eosinophils in blood and tissues.¹ Eosinophil through toxic cationic protein plays a role in the pathogenesis of this disease. Diagnostic criteria include demonstration of eosinophilic infiltration in the bowel walls, lack of evidence of extraintestinal disease, and exclusion of various disorders that mimic a similar condition.³ This rare disease should be taken into consideration during the differential diagnosis of unexplained gastrointestinal symptoms, especially when they are associated with peripheral eosinophilia. We report a case of eosinophilic enteritis that underwent emergency laparotomy for intestinal obstruction due to eosinophilic enteritis of ileum with multiple strictures.

Case Report

A 54-year-old male presented to the emergency department with complaints of acute onset of abdominal pain and vomiting. He also had history of intermittent dull aching pain in the abdomen since fifteen days prior to this acute episode. The patient denied history of taking any drugs. He had no history of drug allergy, asthma or allergic rhinitis. There was no history of allergy or atopy in family members. There was no past history of fever, diabetes, tuberculosis, asthma, hepatitis or ischemic heart disease.

Physical examination revealed a slightly distended abdomen with rigidity and tenderness. There was no organomegaly. Laboratory investigations showed Hb-11.4 gm/L and total leukocyte count $9.8 \times 10^9/L$. Differential count revealed polymorphs -47%, lymphocytes -24% and eosinophils -29%. Absolute eosinophil count was $2842/mm^3$ ($2.8 \times 10^9/L$). Other laboratory studies with serum IgE were within normal limits.

Chest X-ray was within normal limits. Abdominal X-ray displayed multiple air-filled levels in the small intestine. Emergency laparotomy was performed with a midline incision in view of increasing distension and tenderness of abdomen. Exploration revealed multiple ileal strictures with proximal dilatation. Segmental resection of the ileum and end-to-end anastomosis was performed and a resected specimen sent for histopathology.

Gross examination revealed a segment of small intestine about 24 cm in length with three strictures in the ileum and proximal dilatation of intestine with congestion of serosa (Figure 1). On cutting open, a narrowed lumen due to stricture with congestion of mucosa was noted (Figure 2). Peripheral surgical margins were unremarkable.

Multiple sections of the resected specimen showing layers of small intestine (Figure 3) were studied. All the layers of intestine showed diffuse and dense infiltration of eosinophils of $>40-60$ eosinophils/hpf (Figure 4). All the coats showed congestion and serosa were covered by inflammatory exudates. The section through stricture showed fibrosed wall with dense eosinophilic infiltration (Figure 5). Final histological diagnosis of eosinophilic enteritis with stricture was made presenting as acute intestinal obstruction with peritonitis. The patient recovered well and was free of gastrointestinal symptoms during the follow up period of one year. During this period, upper GI endoscopy and biopsy were performed. These showed no eosinophilic infiltration in the stomach. Postoperative stool examination was negative for ova, cyst or worm infestation on two separate occasions. Occult blood in stool was negative. The patient was

Correspondence: Sunil V. Jagtap, Department of Pathology: Krishna Institute of Medical Sciences, University, Karad (415110), Maharashtra, India. Mob: 9960628672. E-mail: drsvjagtap@gmail.com

Key words: eosinophilic enteritis, acute abdomen, intestinal strictures.

Received for publication: 18 November 2011.

Revision received: 14 December 2011.

Accepted for publication: 17 December 2011.

This work is licensed under a Creative Commons Attribution NonCommercial 3.0 License (CC BY-NC 3.0).

©Copyright S.V. Jagtap et al., 2012
Licensee PAGEPress, Italy
Clinics and Practice 2012; 2:e24
doi:10.4081/cp.2012.e24

given oral prednisolone 10 mg daily for six weeks and tapering thereafter, resulting in a normal hematologic examination.

Discussion

Primary eosinophilic gastroenteritis is defined as a disorder that primarily affects the gastrointestinal tract with eosinophil rich inflammation in the absence of a known cause for eosinophilia, including drug reaction, parasitic infections and malignancy.⁴ Eosinophilic gastroenteritis was first described in 1937 by Kaijser. In 1970, Klein classified the disease according to the predominance of eosinophilic infiltration in different layers of the intestinal wall.⁵ Involvement of different layers of the intestinal wall usually gives rise to different clinical manifestations. The mucosal form of eosinophilic enteritis (most common variant) is characterized by vomiting, abdominal pain, and diarrhea, blood loss in stools, iron deficiency anemia, malabsorption and protein losing enteropathy. The muscularis form is characterized by infiltration of eosinophils predominantly in the muscle layer, leading to the thickness of the bowel wall due to fibrosis, which may result in gastrointestinal obstructive symptoms. Our patient presented with this form of the disease secondary to stricture. The mucosal form occurs in a minority of patients with eosinophilic enteritis with ascites with higher peripheral eosinophils counts compared with the other forms.^{3,4} The serosal form is characterized by exudative ascites. In our case, eosinophils infiltrated all the three layers of the intestinal wall and thickening of the muscle layer leading to stricture causing intestinal obstruction.

Although eosinophilic enteritis can involve any part of the gastrointestinal tract, the stomach and duodenum are the most common sites of involvement.^{3,6,7,8} Eosinophilic gastroenteritis is an extremely rare disease, with less than 200 patients described in the literature. The largest published series includes only 40 patients.^{9,10} Because the pathogenesis and etiology of the disease are not well understood, no standards for the diagnosis of eosinophilic enteritis exist. Tally *et al.*⁹ have identified three main diagnostic criteria: i) presence of gastrointestinal symptoms; ii) biopsies demonstrating eosinophilic infiltration of one or more areas of the gastrointestinal tract; iii) no evidence of parasitic /extraintestinal dis-

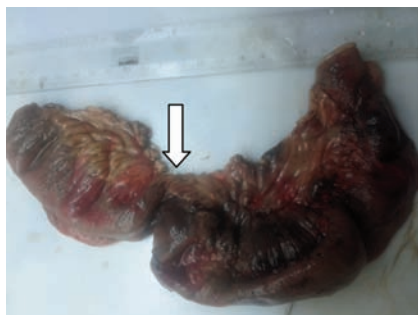

Figure 1. Gross photograph of segment of small intestine with stricture (marked with arrow) and proximal dilatation.

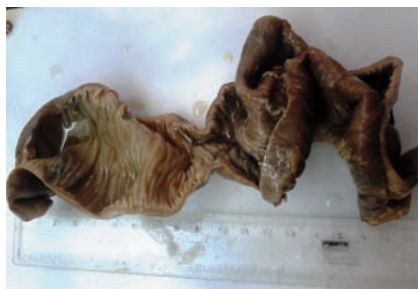

Figure 2. Gross photograph of cut section of intestinal segment showing narrowed lumen due to stricture with congestion of mucosa.

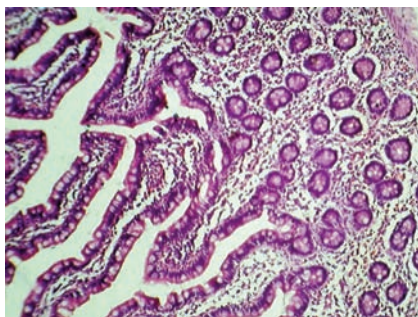


Figure 3. Photomicrograph of small intestine showing mucosa dense and diffusely infiltrated by eosinophils (H & E, x400).

ease. It was reported that peripheral eosinophilia is uniformly associated with the eosinophilic enteritis.^{7,11} Peripheral eosinophilia has been reported in up to 80% of cases by Tally *et al.*⁹ However, the definite diagnosis of eosinophilic enteritis requires histological evidence of eosinophilic infiltration.⁷ Laparotomy or laparoscopic full thickness biopsy is often required to make a diagnosis, especially when there is involvement of the muscular layer, as small biopsies by gastroscopy or colonoscopy are likely to yield a negative result. Patients with predominantly serosal disease have higher eosinophils count (average 8000/dL) than patients with mucosal disease (average 2000/dL) and muscle layer disease (average 1000/dL).¹²

Moreover, a study at the Mayo clinic showed that 50% of patients with eosinophilic enteritis reported a history of allergy, such as asthma, allergic rhinitis, urticaria, drug allergy and eczema.⁹ If eosinophilic enteritis is considered a form of hypersensitivity reaction, the exact nature of the allergens requires investigation. Food, as a natural allergen, is considered to be associated with eosinophilic enteritis. Nevertheless, clinical studies have shown no relationship between food and allergy and eosinophilic enteritis.¹³ Our patient did not have any personal or family history of food allergy.

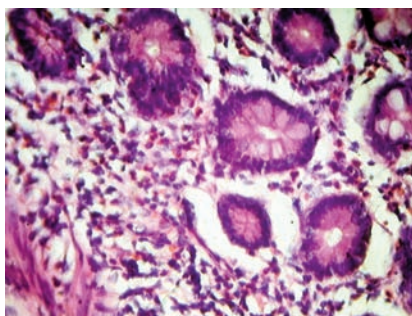


Figure 4. Photomicrograph of small intestine showing submucosa dense and diffusely infiltrated by eosinophils (H & E, x400).

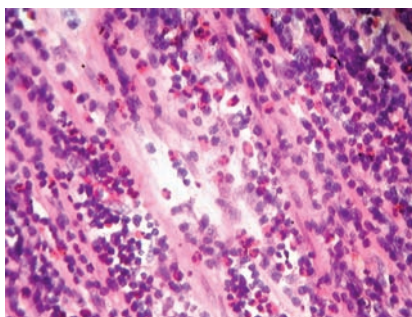


Figure 5. Photomicrograph of stricture showing fibrosed wall diffusely infiltrated by eosinophils (H & E, x400).

Treatment with a steroid is the mainstay in the management of eosinophilic enteritis. In the study by Chen MJ *et al.*,⁶ all 13 patients had successful resolution of symptoms within two weeks. Other therapies have been tried including sodium chromoglycate, ketotifen¹⁴ and montelukast.¹⁵ However, their long-term effectiveness is questionable and requires more prospective clinical trials. Foroughi S *et al.*¹⁶ reported success in an open-label study of 9 patients treated withomalizumab, a monoclonal anti-IgE antibody. Immunosuppressive with azathioprine can be used as an adjunct to steroids.¹⁷

Sodium chromoglycate, a mast cell stabilizer may be used to prevent release of mast cell toxic material; release of histamine and leukotrienes also reduces absorption of antigens by the small bowel. It can be used mainly to treat milk allergy and other GI allergic reactions in children, with as such no role in reducing stricture associated with eosinophilic enteritis.¹⁷

Although surgeons should avoid unnecessary surgery, surgical interventions may sometimes be required when a definite diagnosis cannot be made, or when complications like perforation or obstruction occur, as in our case. Since the natural history of eosinophilic enteritis has not well documented, long-term follow up is required.

Conclusions

Eosinophilic enteritis is a rare, poorly understood condition presenting with a bizarre spectrum of unexplained symptoms mimicking other acute abdominal conditions. Hence, eosinophilic enteritis is a diagnostic dilemma and clinical presentations with investigations are only contributory. Presentation with acute abdomen is even less common, and surgeons should remain vigilant with this rare cause in mind.

References

1. D'souza C, Bhagavan KR, Sunil H, Mohan R. Unusual case of sub acute intestinal obstruction due to eosinophilic enteritis with enteroliths. *Ann Trop Med Public Health* 2010;3:83-5.
2. Yun MY, Cho YU, Park IS, et al. Eosinophilic gastroenteritis presenting as a small bowel obstruction: a case report and review of literature. *World J Gastroenterol* 2007;13:1758-60.
3. Hsu YQ, Lo CY. A case of eosinophilic gastroenteritis. *Hong Kong Med J* 1998;4:226-28.

4. Rothenberg ME. Eosinophilic gastrointestinal disorders (EGID). *J Allergy Clin Immunol* 2004;113:11-28.
5. Klein NC, Hargrove RL, Sleisenger MH, Jeffries GH. Eosinophilic gastroenteritis. *Medicine (Baltimore)* 1970;49:299-319.
6. Chen MJ, Chu CH, Lin SC, et al. Eosinophilic gastroenteritis: clinical experience with 15 patients. *World J Gastroenterol* 2003;9:2813-6.
7. Caldwell JH. Eosinophilic gastroenteritis. *Curr Treat Options Gastroenterol* 2002;5:9-16.
8. Alamo Martinez JM, Ibanez Delgado F, Galindo Galindo A, et al. Intestinal obstruction by eosinophilic jejunitis. *Rev Esp Enferm Dig* 2004;96:279-83.
9. Talley NJ, Shorter RG, Phillips SF, Zinsmeister AR. Eosinophilic gastroenteritis : a clinico pathological study of patients with disease of the mucosa, muscle layer and the subserosal tissue. *Gut* 1990;31:54-8.
10. Kelly KJ. Eosinophilic gastroenteritis. *J Pediatr Gastroenterol Nutr* 2000;30:S28-35.
11. Alexander P, Jacob S, Paul V. Laparoscopy in eosinophilic jejunitis presenting as sub-acute bowel obstruction. A case report. *Trop Gastroenterol* 2003;24:97-8.
12. Maeshima A, Murakami H, Sadakata H, et al. Eosinophilic gastroenteritis presenting with acute pancreatitis. *J Med* 1997;28:265-72.
13. Leinbach GE, Rubin CE. Eosinophilic gastroenteritis: a simple reaction to food allergens? *Gastroenterology* 1970;59:874-89.
14. Suzuki J, Kawasaki Y, Nozawa R, et al. Oral disodium chromoglycate and ketotifen for a patient with eosinophilic gastroenteritis, food allergy and protein losing enteropathy. *Asian Pac J Allergy Immunol* 2003;21:193-7.
15. Schwartz DA, Pardi DS, Murry JA. Use of montelukast as steroid-sparing agent for recurrent eosinophilic gastroenteritis. *Digest Dis Sci* 2001;46:1787-90.
16. Foroughi S, Foster B, Kim N et al. Anti-IgE treatment of eosinophil-associated gastrointestinal disorders. *J Allergy Clin Immunol* 2007;120:594-601.
17. Karande T, Oak SN, Trivedi A, et al. Proximal jejunal obstructive eosinophilic gastroenteritis. *J Postgrad Med* 1996;42:121-3.