

# A nationwide analysis of desmoplastic small round cell tumor

Tao Xiang, MD<sup>a</sup>, Shu-Yang Zhang, MS<sup>b</sup>, Sai-Sai Wang, MD<sup>a</sup>, Ru-Shan Fei, MD<sup>a</sup>, Hui Li, MD<sup>c,\*</sup>

## Abstract

This study aim is to enhance the understanding, diagnosis and treatment of desmoplastic small round cell tumor (DSRCT) and to determine what factors can affect survival of the disease in China.

We report here 8 patients with DSRCT in our center who received a variety of treatment methods. By reviewing the literature published from Chinese database (CNKI, WANGFAN, VIP, CBM, CMCC) in 2000 to 2015 with the terms of “dsrct”, “desmoplastic” and “small round-cell tumor”, 104 eligible cases of DSRCT (including 8 cases in our hospital) were retrospectively analyzed.

Among the 104 patients, Median age was 24 years with a range of 15 to 54 years. The main primary tumor site was the abdomen and/or pelvis in 92/104 patients (88.5%). Only 25% of patients had localized disease. Most of the patients had received adjuvant chemotherapy (87.5%) and 76.9% patients had not experienced adjuvant radiotherapy. One-fourth of the patients underwent grossly complete surgical resection, and 33.7% and 41.3% patients received no surgery and incomplete surgical resection, respectively. Median overall survival for all patients was 26 months (95% CI: 20.29–31.71). Multivariate analysis revealed that Metastatic status (HR: 2.327, 95% CI: 1.136–4.768,  $P=.021$ ), Surgical patterns (HR: 0.673, 95% CI: 0.487–0.928,  $P=.016$ ), and Adjuvant chemotherapy (HR: 0.337, 95% CI: 0.167–0.678,  $P=.002$ ) were significant independent prognostic factors for longer overall survival. It was noteworthy that CD99 were significantly associated with OS ( $P=.002$ ).

Here, we identified the prognostic factors which may facilitate risk-adapted treatments for this rare DSRCT group, which should be further investigated.

**Abbreviations:** DSRCT = desmoplastic small round cell tumor, HR = hazard ratio, OS = overall survival.

**Keywords:** CD99, chemotherapy, metastatic status, prognosis, surgical patterns

## 1. Introduction

Desmoplastic small round cell tumor (DSRCT) is a rare and highly aggressive neoplasm described as a distinct clinicopathological entity in 1989 by Gerald and Rosai.<sup>[1]</sup> The literature regarding this tumor is limited and generally comprises case report. And there is no large sample of national studies, especially in China. DSRCT has a predilection for children and adolescents, and primarily involves the abdomen and pelvis. The tumor is

more common among men than among women. The extent and location of the tumor correlate with symptoms seen at presentation. Abdominal fullness, constipation, and abdominal distension are the most common symptoms.

The histopathology and immunocytochemistry of the disease have been well presented.<sup>[2,3]</sup> The diagnosis is very difficult and correct diagnosis depends on pathological immunohistochemical characteristics, further ectopic EWS-WT1 fusion gene detection needed if possible.<sup>[4–6]</sup>

Owing to diversity in treatment options, there is no proper consensus on the best treatment plan of DSRCT. Current treatment options for the international mainstream is alkylating agent-based chemotherapy, the maximum cytoreductive surgery (>90%) and the whole abdominal radiotherapy.

The prognosis of DSRCT patients is very poor, overall survival is approximately 30% to 55% despite chemotherapy, radiotherapy, and aggressive surgical resection.<sup>[7,8]</sup> The objective of this study was to identify the prognostic risk factors by retrospectively analyzing the 104 mreported cases and review systematically the current knowledge of this unusual tumor to present clinical characteristics, pathologic features, treatment approaches, and prognostic factors of this tumor.

## 2. Materials and methods

### 2.1. Patients

The records of 8 cases of DSRCT diagnosed between 2000 and 2015 were retrieved from the consultation files and database of the First Affiliated Hospital, College of Medicine, Zhejiang University, Hangzhou, China. The clinical characteristics, immunohistochem-

Editor: Undurti N. Das.

The authors have no funding and conflicts of interest to disclose.

The datasets generated during and/or analyzed during the current study are available from the corresponding author on reasonable request.

<sup>a</sup> Department of Colorectal Surgery, The First Affiliated Hospital, Zhejiang University School of Medicine, Hangzhou, <sup>b</sup> Department Of General Surgery, Shaoxing Traditional Chinese Medicine Hospital, Shaoxing, Zhejiang, <sup>c</sup> Surgical Intensive Care Unit, The First Affiliated Hospital, Zhejiang University School of Medicine, Hangzhou, Zhejiang, P.R. China.

\* Correspondence: Hui Li, Surgical Intensive Care Unit, The First Affiliated Hospital, Zhejiang University School of Medicine, Hangzhou, Zhejiang 310006, P. R. China (e-mail: sophie8564@zju.edu.cn).

Copyright © 2020 the Author(s). Published by Wolters Kluwer Health, Inc. This is an open access article distributed under the terms of the Creative Commons Attribution-Non Commercial License 4.0 (CCBY-NC), where it is permissible to download, share, remix, transform, and buildup the work provided it is properly cited. The work cannot be used commercially without permission from the journal.

How to cite this article: Xiang T, Zhang SY, Wang SS, Fei RS, Li H. A nationwide analysis of desmoplastic small round cell tumor. *Medicine* 2020;99:30(e21337).

Received: 25 February 2020 / Received in final form: 14 June 2020 / Accepted: 18 June 2020

<http://dx.doi.org/10.1097/MD.00000000000021337>

**Table 1****Clinical feature and follow up data of 8 DSRCT cases.**

Case	A/S	Primary symptom	Primary tumor site	Tumor size (cm*cm)	Metastasis	Treatment	Outcome
1	32/M	Abdominal distention and mass	Intra-abdominal	7 × 6	Yes	S	DOD 17 month(s)
2	19/M	Cough	Lung	10 × 6	No	S	DOD 10 month(s)
3	34/M	Abdominal pain and distention	Intra-abdominal	9 × 7	Yes	S,C	DOD 36 month(s)
4	25/M	Abdominal pain and mass	Intra-abdominal and pelvic	6.8 × 5.2	Yes	S	DOD 13 month(s)
5	25/F	Abdominal pain and mass	Intra-abdominal and pelvic	9 × 4.8	Yes	S	DOD 4 month(s)
6	44/M	Testis occupation	Testis	5 × 5	Yes	S,C	DOD 11 month(s)
7	16/M	Abdominal pain and diarrhoea	Intra-abdominal and pelvic	14 × 10	Yes	C	AWD 11 month(s)
8	41/M	Abdominal distention and mass	Intra-abdominal and pelvic	8 × 5	Yes	S,C	AWD 3 month(s)

A=age in years at diagnosis, AWD=alive with disease, C=chemotherapy, DOD=dead of disease, S=indicates sex, S=surgery.

ical result, treatment and outcome were collected and summarized as follow (Tables 1 and 2). Written informed consent for study participation was obtained from all patients.

The literature search used the Chinese databases between 2000 and 2015, including CNKI, WANGFAN, VIP, CBM and CMCC. By retrieving the key words of “dsrct”, “desmoplastic tumor” and “small round cell tumor”, we obtained the available clinical data for 96 patients with DSRCT. The database contains patient age, gender, presentation, primary tumor site, metastatic status, pathologic findings, therapy and follow-up data. In addition, the incomplete reports were removed. These references were selected because they presented patient information independent of each other, and all references were reviewed and evaluated by three independent members.

## 2.2. Data collection

The prognostic factors were analyzed: sex, age, tumor primary site, metastatic status, surgery, adjuvant chemotherapy, adjuvant radiation and immunohistochemical indicators. In the present study, the surgery were divided into three groups (1) those who received no surgery, (2) those who received complete surgical resection, and (3) those who received incomplete surgical resection. The complete surgical resection was defined as definitive removal of at least 90% of tumor; otherwise surgery was considered to be incomplete surgical resection. And tumor biopsy at diagnosis was not considered to constitute surgery.

## 2.3. Statistical analysis

All statistical analysis was performed by SPSS16.0 (SPSS Inc, Chicago, IL, USA), including the following variables: sex (male/female), age as a categorical variable using a cutoff of 24 years,

tumor primary site (abdomen/pelvis vs other sites), metastatic status (localized vs disseminated), surgery (no/complete/incomplete), Adjuvant chemotherapy, Adjuvant radiation and immunohistochemical indicators. Overall survival (OS) was estimated using the Kaplan-Meier method. Overall survival was calculated from the date of diagnosis to the date of death from the disease or the last follow-up. Multivariate survival analyses using Cox's proportional-hazards method were performed in order to define the prognostic factors for OS. Hazard ratio and 95% CI (confidence interval) were also estimated. A probability value of less than .05 ( $P < .05$ ) was considered to be statistically significant.

## 3. Results

### 3.1. Baseline characteristics

A total of 104 patients were identified from the database who were diagnosed with DSRCT and met the inclusion criteria. In these cases, DSRCT showed an apparent male predominance (89/104, 85.6%) to female (15/104, 14.4%) and at a mean age of 24 years (range from 15 to 54 years). The clinical manifestations were nonspecific and variable. The predominant clinical manifestations at presentation include abdominal pain or discomfort (49.1%), palpable abdominal mass or distention (43.9%), weight loss (19.3%). Other symptoms or signs, like anorexia, umbilical hernia, Bowel habit change, ascites, constipation, urinary complaint and so on, were also reported. This might be associated with tumor sites.

The tumor primary site, metastatic status and other patient characteristics were summarized in Table 3. The main primary tumor site was the abdomen and/or pelvis in 92/104 patients (88.5%). Primary tumor sites in the other patients were lung,

**Table 2****Immunohistochemical result of 8 DSRCT cases.**

Case	AE1/AE3	VIM	Desmin	EMA	NSE	CGA	SYN	CD56	CD99	PLAP	MyoD1	LCA	S-100
1	+	+	+	+	+	—	—	—	—	—	—	—	—
2	+	+	+	+	—	—	—	—	+	+	—	—	—
3	+	+	+	—	+	+	+	+	—	—	—	—	+
4	+	+	+	+	+	—	—	—	+	—	—	—	—
5	+	+	+	+	+	+	+	+	—	—	—	—	—
6	+	+	+	+	—	—	—	—	—	—	—	—	—
7	+	+	+	+	+	—	NA	NA	—	NA	NA	—	NA
8	+	+	+	+	—	—	NA	NA	—	NA	NA	—	NA

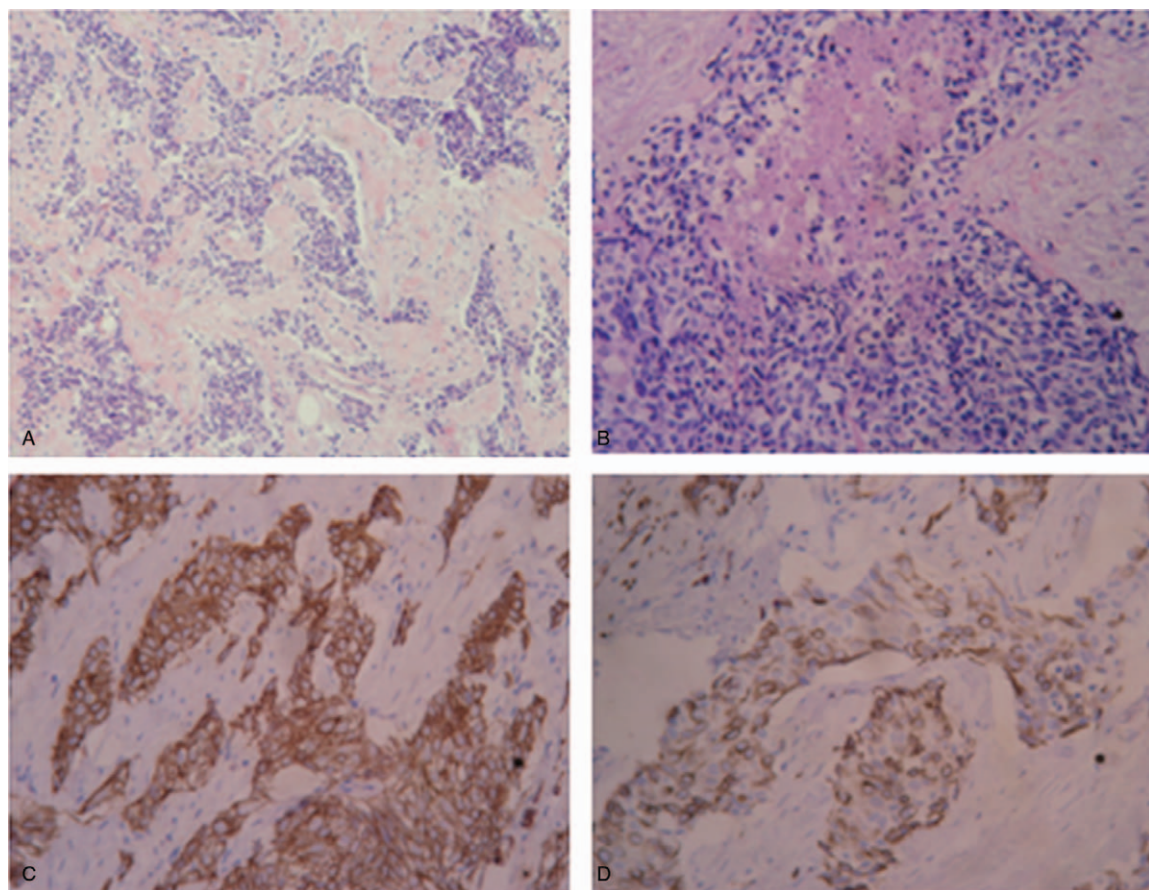
AE1/AE3=pan-cytokeratin, CGA=chromogranin, EMA=epithelial membrane antigen, LCA=leucocyte common antigen, MyoD1=myogenin, NSE=neuron-specific enolase, PLAP=placental alkaline phosphatase, S100=S100 calcium binding protein, SYN=synaptophysin, VIM=vimentin.

<b>Table 3</b>	
<b>Characteristics of all 104 patients.</b>	
<b>Characteristics</b>	<b>Patients, n (%)</b>
Sex	
Male	89 (85.6)
Female	15 (14.4)
Age	
≤24 yr	53 (51.0)
>24 yr	51 (49.0)
Primary tumor site	
Abdomen/pelvis	92 (88.5)
Other sites	12 (11.5)
Metastatic status	
No metastases	26 (25.0)
Metastases	78 (75.0)
Surgery	
No surgery	35 (33.7)
Complete surgery	26 (25.0)
Incomplete surgery	43 (41.3)
Adjuvant chemotherapy	
No	13 (12.5)
Yes	91 (87.5)
Adjuvant radiotherapy	
No	80 (76.9)
Yes	24 (23.1)

testis, cerebellopontine angle, mandible, or heart. Only 25% of patients had localized disease. And 75% patients underwent metastatic disease at the time of diagnosis and therapy, including direct spread to adjacent areas, distant metastasis, lymph node metastasis. Most of the patients had received adjuvant chemotherapy (87.5%), and 12.5% patients had no adjuvant chemotherapy. On the contrary, a few patients received adjuvant radiotherapy (23.1%), and 76.9% patients had not experienced adjuvant radiotherapy. One-fourth of the patients underwent grossly complete surgical resection, and 33.7% and 41.3% patients received no surgery and incomplete surgical resection, respectively.

### 3.2. Histopathology

In our 8 patients, the neoplastic masses were solid, firm, and multilobulated with a gray-white cut surface, sometimes distorted by cystic change and areas of necrosis, ranging from 2 to 17.5 cm. Microscopically, the tumors were composed of sharply demarcated nests of varying size and irregular shape deposited in an abundant desmoplastic stroma (Fig. 1A). The central necrosis was often seen in large tumor nests, the tumor cells appear small and undifferentiated with inconspicuous nucleoli and abundant mitosis (Fig. 1B). Typically, the cellular aggregates are surrounded and separated by abundant fibrous connective tissue



**Figure 1.** Immunohistochemical staining in DSRCT tissue. (A) The tumors were composed of sharply demarcated nests of varying size and irregular shape deposited in an abundant desmoplastic stroma (HE, original magnification  $\times 100$ ). (B) The central necrosis was often seen in large tumor nests, the tumor cells appear small and undifferentiated with inconspicuous nucleoli and abundant mitosis (HE, original magnification  $\times 100$ ). (C) The tumor cells showed diffuse and strong staining for AE1/AE3 (original magnification  $\times 400$ ). (D) Immunostaining for desmin was noted with a distinctive dot-like pattern (original magnification  $\times 400$ ).

**Table 4**  
Results of immunohistochemical studies.

Marker	+/total	%
Desmin	58/62	93.5
Keratin (AE1/AE3)	54/59	91.5
Vimentin	34/34	100
NSE	45/54	83.3
EMA	30/34	88.2
CD99	13/44	29.5
Synaptophysin	10/22	45.5
Chromogranin	4/20	20.0
S-100	2/16	12.5
WT1	31/32	96.9
Leucocyte common antigen	0/11	0
CD56	3/10	30
Actin	2/31	6.5
Myogenin	0/6	0
CAM 5.2	19/23	82.6

with only a scattering of spindle-shaped fibroblasts and myofibroblasts. Occasionally, the tumor cells have more abundant cleared-out or vacuolated cytoplasm of a single ring-like appearance. A relatively common finding is the presence of rhabdoid-like foci in which the tumor cells have paranuclear intracytoplasmic hyaline inclusions composed of aggregates of intermediate filaments. Other rare features include Homer Wright-like rosettes, papillary areas, zones that resemble traditional cell carcinoma.

Table 2 shows the immunohistochemical analysis of our 8 patients. All 8 cases showed diffuse and strong staining for AE1/AE3 (Fig. 1C), VIM and Desmin, some of them also expressed EMA, CD56, CGA, SYN, S-100 and PLAP and none for LCA and MyoD1 a distinctive dot-like intracytoplasmic localization is seen with Desmin (Fig. 1D). And presented in Table 4 is the immunohistochemical profile of DSRCT from the total of 104 patients. Similarly, in the literature review, the Desmin, VIM, EMA, WT1, CAM 5.2, Keratin and NSE were positive in a large percentage of patients.

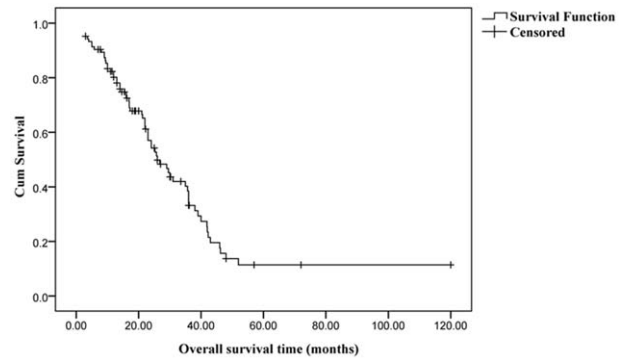
### 3.3. Follow-up and treatment outcome

Among 104 patients, 65 (62.5%) patients had died at the time of analysis and the median duration from diagnosis to death was 26 months (range, 3–120 months). In other words, estimated median OS was 26 months (95% CI: 20.29–31.71). The overall survival rates 1, 2, and 3 years were 80.2%, 54.2%, and 33.2%, respectively (Fig. 2).

### 3.4. Analysis of prognostic factors

Results of univariate and multivariate analyses for analysis of prognostic factors are summarized in Table 5. In univariable analyses, No metastases, surgery (complete and incomplete) and Adjuvant chemotherapy were significantly associated with better OS (Figs. 3–5).

For the patients without metastases, the survival rates 1, 2, and 3 years were 84.6%, 71.1%, and 48.0%, respectively; for metastases, the survival rates were 78.6%, 48.3%, and 28.4%, respectively. The survival rate for those patients with metastases were significantly lower than those with no metastases ( $P = .005$ ) (Fig. 3).



**Figure 2.** Overall survival of all the 104 patients.

For the patients with no surgery, the survival rates 1, 2, and 3 years were 67.4%, 47.0%, and 13.7%, respectively. For incomplete surgery, the survival rates 1, 2, and 3 years after were 76.0%, 51.9%, and 31.1%, respectively. For complete surgery, the survival rates were 92.8%, 61.1%, and 49.6%, respectively. Obviously, the patients with complete surgery had the highest survival rate ( $P = .009$ ) (Fig. 4).

For the patients with receiving adjuvant chemotherapy, the survival rates 1, 2, and 3 years were 83.0%, 56.7%, and 35.1%, respectively. For no chemotherapy, the survival rates 1, 2, and 3 years were 61.5%, 38.5%, and 19.2%, respectively. The survival rate for those patients with receiving adjuvant chemotherapy were significantly higher than those with no chemotherapy ( $P = .026$ ) (Fig. 5).

Univariable modeling in DSRCT patients demonstrated that sex, age, tumor primary site and Adjuvant radiotherapy did not influence OS. Subsequently, three remaining variables (Metastatic status, Surgery and Adjuvant chemotherapy) showed statistical differences in univariate analysis were introduced into the Cox regression model. Results indicated that metastatic status (HR: 2.327, 95% CI: 1.136–4.768,  $P = .021$ ), surgery (HR: 0.673, 95% CI: 0.487–0.928,  $P = .016$ ), and adjuvant chemotherapy (HR: 0.337, 95% CI: 0.167–0.678,  $P = .002$ ) were also independent predictor for DSRCT patients (Table 5).

No data regarding immunohistochemical findings assessment of prognosis was found in other literature about DSRCT. We specially evaluated the immunohistochemical indicators (including EMA, NSE, CD99, CGA and CAM5.2) on prognosis of DSRCT by using univariate analyses. Only CD99 were significantly associated with OS ( $P = .002$ ) (Fig. 6).

## 4. Discussion

DSRCT is an orphan disease and is still poorly understood. It is characterized by nests of small tumor cells surrounded by a cellular and vascular collagenous stroma hence the name desmoplastic small round cell tumor. This tumor is a rare and highly aggressive neoplasm, which usually originates from the abdomen/peritoneum and has been often seen in male adolescents.<sup>[9,10]</sup> Most of the literatures are limited to small, single-center case reports, and their results lack universality. There is no large sample of national studies, especially in China. Then we collected several research reports of DSRCT originating in multiple overseas centers, which was similar to our results (Table 6).<sup>[11–13]</sup>

**Table 5**  
**Univariable and multivariable analysis of prognostic factors.**

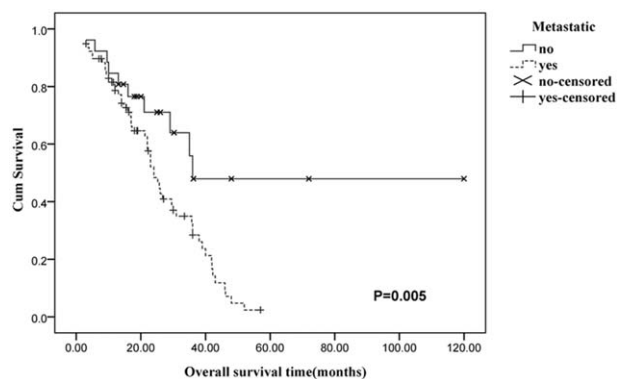
	Univariable analysis		Multivariable analysis	
	Months	P value	HR (95% CI)	P value
Sex		.274		
Male	26.75 (20.975–32.525)			
Female	23.00 (0–46.176)			
Age		.540		
≤24 yr	25.7 (10.354–41.046)			
>24 yr	26.0 (19.996–32.004)			
Primary tumor site		.376		
Abdomen/pelvis	26.0 (19.674–32.326)			
Other sites	35.0 (9.719–60.281)			
Metastatic status		.005*	2.327 (1.136–4.768)	.021*
No metastases	Not reached			
Metastases	24.0 (20.443–27.557)			
Surgery		.009*	0.673 (0.487–0.928)	.016*
No surgery	23.0 (11.421–34.579)			
Incomplete surgery	25.2 (6.489–43.911)			
Complete surgery	30.0 (17.920–42.080)			
Adjuvant chemotherapy		.026*	0.337 (0.167–0.678)	.002*
No	16.0 (10.128–21.872)			
Yes	29.5 (22.761–36.239)			
Adjuvant radiotherapy		.890		
No	29.5 (17.478–41.522)			
Yes	24.0 (19.618–28.382)			

\* Statistical significant.

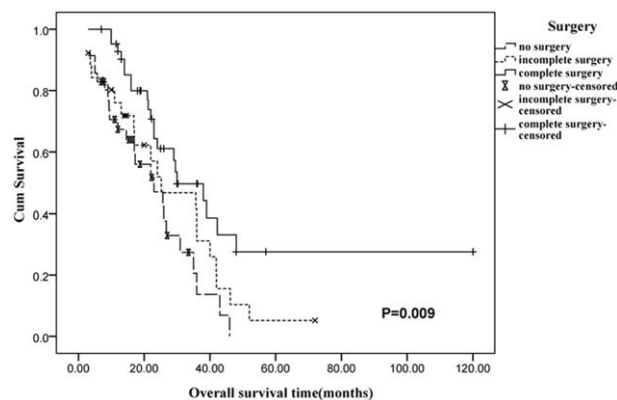
In our study, DSRCT showed an apparent male predominance to female and the gender ratio was 89:15 (85.6%). And in the study by Lal et al the ratio was 60:6 (91%).<sup>[8]</sup> In our series, the main primary tumor site was the abdomen and/or pelvis in 92/104 patients (88.5%). And the predominant clinical manifestations were abdominal pain or discomfort (49.1%), palpable abdominal mass or distension (43.9%) and Weight loss (19.3%), with a small number of patients complaining about Anorexia, Umbilical hernia, Bowel habit change, ascites, constipation, Urinary complaint and ect. According to the study by Gil et al,<sup>[14]</sup> pain (52.1%) and increased abdominal girth (8.4%) were the predominant initial symptom or sign. In a word, DSRCT do not have specific clinical presentation. This might be associated with

tumor sites. On this regard, doctors need to take DSRCT into consideration when the above symptoms are present. And the relevant clinical examination is necessary, such as imaging, cytology, and laboratory blood test.

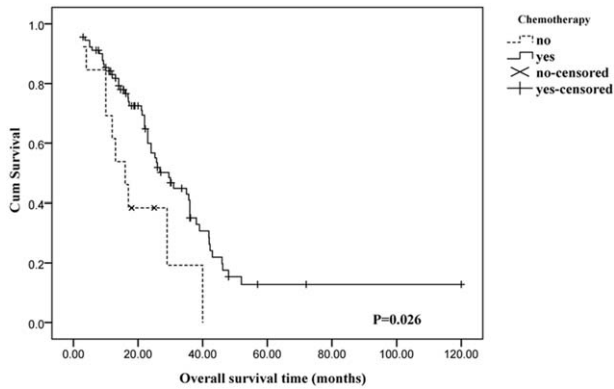
The diagnosis of DSRCT is very difficult, usually based on histologic and immunohistochemical examination. Molecular biology tests looking for the EWS-WT1 fusion gene transcripts are therefore mandatory to confirm the diagnosis.<sup>[15,16]</sup> By investigating 8 patients of our institution, we can see the histological characteristic of DSRCT. Histologically, the tumors were composed of sharply demarcated nests of varying size and irregular shape deposited in an abundant desmoplastic stroma. The central necrosis was often seen in large tumor nests, the



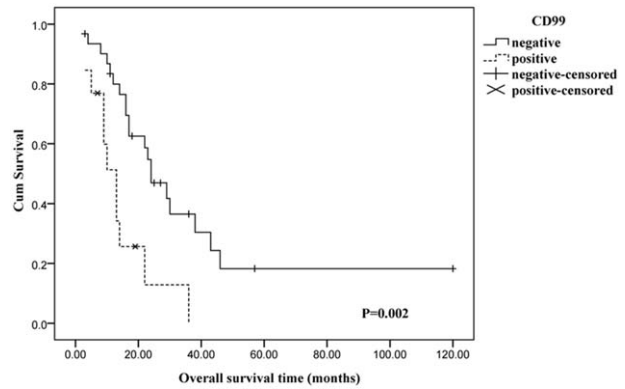
**Figure 3.** Overall survival compared between patients with metastases vs no metastases. The survival rate for those patients with metastases was significantly lower than those with no metastases.



**Figure 4.** Overall survival in patients treated with no surgery vs incomplete surgery vs complete surgery. Complete surgical resection is defined as greater than 90% tumor resection.



**Figure 5.** Overall survival compared between patients treated with adjuvant chemotherapy compared with no chemotherapy.



**Figure 6.** The patients with CD99 negative expression have longer survival.

tumor cells appear small and undifferentiated with inconspicuous nucleoli and abundant mitosis (Fig. 1A, B). these characteristic features of DSRCT distinguish it from other small round cell tumors and tumors with dense stroma. The tumors were found to be the coexpression of neural, mesenchymal and epithelial markers by immunohistochemical examination.<sup>[2,17]</sup> Table 4 describes detailedly immunohistochemical results in our group. The Desmin, Keratin (AE1/AE3), Vimentin, NSE, EMA, WT1 and CAM 5.2 were positive in a large percentage of patients. And Vimentin even reached 100%. The result is similar to the previous literature reports.<sup>[9]</sup> The presence of these is uncommon in other tumors. In general, desmoplastic small round cell tumor is a vexing disease with poor long-term survival. As reported earlier by Lal et al, the survival rate of DSRCT in a 3-year period was 44%.<sup>[18]</sup> But a large sample analysis of 491 patients from Gani et al reported a 3-year survival of 32.3%.<sup>[11]</sup> Our results showed that the three-year overall survival rate is 33.2%, which is somewhat closer to the recent large sample studies.

Multivariate factors analyses showed that metastatic status, surgical patterns and adjuvant chemotherapy had an impact on overall survival independently (Table 5). Metastatic status has a very important impact on prognosis. Our study results also demonstrated that patients with metastatic diseases had significantly reduced survival rates. The patients with no metastases were associated with better OS (3-year OS 48% vs 28.4%,  $P=.005$ ). This suggests that it is desirable to touch the patients with no metastases in order to improve the patient survival rate. Nevertheless, the reality is that DSRCT patients often have tumor metastases when they go to the hospital. Therefore, disease early detection is very important.

Lal et al had reported that complete surgical resection was highly significant in prolonging overall survival. Our study results

also demonstrated that the patients experienced complete surgical resection were significantly associated with best OS (3-year OS 49.6% vs 31.1% vs 13.7%,  $P=.009$ ). Similarly, the survival rate for those patients received adjuvant chemotherapy were significantly higher than those with no chemotherapy (3-year OS 35.1% vs 19.2%,  $P=.026$ ). The most representative chemotherapy regimen is the P6.<sup>[7]</sup> Intraperitoneal chemotherapy (either HIPEC or EPIC) after resection in DSRCT is controversial. The only randomized trial comparing the administration or not of intraperitoneal chemotherapy after resection tumors showed that intraperitoneal chemotherapy has no significant effect on OS.<sup>[18]</sup> Therefore, we suggest that DSRCT patients should accept the treatment protocol with Complete Surgery combined with chemotherapy.

To the best of our knowledge, no studies have reported the influence of immunohistochemical indicators on the prognosis of DSRCT. Here, we specially evaluated the immunohistochemical indicators (including EMA, NSE, CD99, CGA and CAM5.2) on prognosis of DSRCT. In the results of Kaplan-Meier survival analysis, we found that only CD99 was a significant predictor for OS ( $P=.002$ ).

CD99 is a transmembrane glycoprotein encoded by the MIC2 gene, located on the short arm of the X and Y chromosomes.<sup>[19,20]</sup> The protein has recently been involved in cell adhesion, apoptosis, differentiation of T cells and thymocytes, the migration of monocytes and the intercellular adhesion between lymphocytes and endothelial cells, which may play an important role in the development of tumor.<sup>[21-24]</sup> In previous studies, loss of CD99 was found to be associated to poor prognosis in patients with osteosarcoma, pancreatic endocrine tumor and gastric adenocarcinoma.<sup>[25-27]</sup> However, our results suggest that patients with CD99 negative expression have longer survival, which should be further investigated.

**Table 6**  
Desmoplastic small round cell tumors reported in the recent literatures.

Author	Years	Patients	Metastasis (%)	Surgery (%)	Chemotherapy (%)	Radiotherapy (%)	Median OS (mo)
Present study	2000–2015	104	75	66.3	87.5	23.1	26.0
Gani et al <sup>[11]</sup>	2004–2014	491	49.3	41.2	86.5	13	25.9
Scheer et al <sup>[12]</sup>	1997–2015	60	63	67	62	Not listed	19.2
Honoré et al <sup>[13]</sup>	1991–2018	100	25	71	80	26	25.0

In conclusion, the surgical patterns, metastatic status, and adjuvant chemotherapy are independent factors affecting the desmoplastic small round cell tumor prognosis. The survival rates are lower in patients with metastases or no surgery or incomplete surgery or no chemotherapy, suggesting the importance of early diagnosis, early treatment, complete surgery and adjuvant chemotherapy. In addition, we find that CD99 has also a very important impact on prognosis in DSRCT patients.

### Author contributions

**Conceptualization:** Tao Xiang, Hui Li.

**Data curation:** Tao Xiang, Shuyang Zhang, Saisai Wang.

**Formal analysis:** Tao Xiang.

**Funding acquisition:** Tao Xiang.

**Investigation:** Tao Xiang.

**Methodology:** Tao Xiang.

**Project administration:** Tao Xiang.

**Resources:** Tao Xiang.

**Software:** Tao Xiang.

**Validation:** Rushan Fei.

**Writing – original draft:** Tao Xiang.

**Writing – review & editing:** Tao Xiang.

### References

- [1] Gerald WL, Rosai J. Case 2. Desmoplastic small cell tumor with divergent differentiation. *Pediatr Pathol* 1989;9:177–83.
- [2] Ordonez NG. Desmoplastic small round cell tumor: II: an ultrastructural and immunohistochemical study with emphasis on new immunohistochemical markers. *Am J Surg Pathol* 1998;22:1314–27.
- [3] Ordonez NG, El-Naggar AK, Ro JY, et al. Intra-abdominal desmoplastic small cell tumor: a light microscopic, immunocytochemical, ultrastructural, and flow cytometric study. *Hum Pathol* 1993;24:850–65.
- [4] Park BJ, Alexander HR, Libutti SK, et al. Treatment of primary peritoneal mesothelioma by continuous hyperthermic peritoneal perfusion (CHPP). *Ann Surg Oncol* 1999;6:582–90.
- [5] Ladanyi M, Gerald W. Fusion of the EWS and WT1 genes in the desmoplastic small round cell tumor. *Cancer Res* 1994;54:2837–40.
- [6] Gerald WL, Ladanyi M, de Alava E, et al. Clinical, pathologic, and molecular spectrum of tumors associated with t(11;22)(p13;q12): desmoplastic small round-cell tumor and its variants. *J Clin Oncol* 1998;16:3028–36.
- [7] Kushner BH, LaQuaglia MP, Wollner N, et al. Desmoplastic small round-cell tumor: prolonged progression-free survival with aggressive multimodality therapy. *J Clin Oncol* 1996;14:1526–31.
- [8] Lal DR, Su WT, Wolden SL, et al. Results of multimodal treatment for desmoplastic small round cell tumors. *J Pediatr Surg* 2005;40:251–5.
- [9] Lettieri CK, Garcia-Filion P, Hingorani P. Incidence and outcomes of desmoplastic small round cell tumor: results from the surveillance, epidemiology, and end results database. *J Cancer Epidemiol* 2014;2014:680126.
- [10] Hayes-Jordan A, Green HL, Lin H, et al. Complete cytoreduction and HIPEC improves survival in desmoplastic small round cell tumor. *Ann Surg Oncol* 2014;21:220–4.
- [11] Gani F, Goel U, Canner JK, et al. A national analysis of patterns of care and outcomes for adults diagnosed with desmoplastic small round cell tumors in the United States. *J Surg Oncol* 2019;119:880–6.
- [12] Scheer M, Vokuhl C, Blank B, et al. Desmoplastic small round cell tumors: Multimodality treatment and new risk factors. *Cancer Med* 2019;8:527–42.
- [13] Honoré C, Delhorme JB, Nassif E, et al. Can we cure patients with abdominal desmoplastic small round cell tumor? Results of a retrospective multicentric study on 100 patients. *Surg Oncol* 2019;29:107–12.
- [14] Gil A, Gomez PA, Brun EA, et al. Clinical perspective on desmoplastic small round-cell tumor. *Oncology* 2004;67:231–42.
- [15] Ferlicot S, Coue O, Gilbert E, et al. Intraabdominal desmoplastic small round cell tumor: report of a case with fine needle aspiration, cytologic diagnosis and molecular confirmation. *Acta Cytol* 2001;45:617–21.
- [16] Peter M, Gilbert E, Delattre O. A multiplex real-time pcr assay for the detection of gene fusions observed in solid tumors. *Lab Invest* 2001;81:905–12.
- [17] Ordonez NG. Desmoplastic small round cell tumor: I: a histopathologic study of 39 cases with emphasis on unusual histological patterns. *Am J Surg Pathol* 1998;22:1303–13.
- [18] Bonvalot S, Cavalcanti A, Le Pechoux C, et al. Randomized trial of cytoreduction followed by intraperitoneal chemotherapy versus cytoreduction alone in patients with peritoneal sarcomatosis. *Eur J Surg Oncol* 2005;31:917–23.
- [19] Bernstein M, Kovar H, Paulussen M, et al. Ewing's sarcoma family of tumors: current management. *Oncologist* 2006;11:503–19.
- [20] Ramani P, Rampling D, Link M. Immunocytochemical study of 12E7 in small round-cell tumours of childhood: an assessment of its sensitivity and specificity. *Histopathology* 1993;23:557–61.
- [21] Bernard G, Breittmayer JP, de Matteis M, et al. Apoptosis of immature thymocytes mediated by E2/CD99. *J Immunol* 1997;158:2543–50.
- [22] Alberti I, Bernard G, Rouquette-Jazdanian AK, et al. CD99 isoforms expression dictates T cell functional outcomes. *FASEB J* 2002;16:1946–8.
- [23] Schenkel AR, Mamdouh Z, Chen X, et al. CD99 plays a major role in the migration of monocytes through endothelial junctions. *Nat Immunol* 2002;3:143–50.
- [24] Bernard G, Raimondi V, Alberti I, et al. CD99 (E2) up-regulates alpha4beta1-dependent T cell adhesion to inflamed vascular endothelium under flow conditions. *Eur J Immunol* 2000;30:3061–5.
- [25] Manara MC, Bernard G, Lollini PL, et al. CD99 acts as an oncosuppressor in osteosarcoma. *Mol Biol Cell* 2006;17:1910–21.
- [26] Goto A, Niki T, Terado Y, et al. Prevalence of CD99 protein expression in pancreatic endocrine tumours (PETs). *Histopathology* 2004;45:384–92.
- [27] Lee JH, Kim SH, Wang LH, et al. Clinical significance of CD99 down-regulation in gastric adenocarcinoma. *Clin Cancer Res* 2007;13:2584–91.