

Effects of a selective cyclooxygenase-2 inhibitor (celecoxib) on fracture healing in rats

Kang-Hua Li, Liang Cheng, Yong Zhu, Guo-Bing Deng¹, Hai-Tao Long

ABSTRACT

Background: Several studies suggested that celecoxib interferes with bone healing while others contradict these findings. This study was conducted to investigate the effects of celecoxib on bone healing in rats femur mold with a dose based on body surface area conversion.

Materials and Methods: 72 adult female Sprague Dawley rats were randomly divided into three groups after the internal fixation operation of nondisplaced transverse mid diaphyseal fractures of the right femurs. Each group was treated with 1% methylcellulose, celecoxib (21 mg/kg/d) for 1 week, or celecoxib (21 mg/kg/d) for 4 weeks after surgeries respectively. Bone healing scores and callus formation were evaluated by radiographs at 3, 4, 6 weeks after surgeries. Half of these rats were sacrificed for histological analysis at 4 weeks after surgery. The remaining fractured femurs were evaluated by biomechanical tests at 6 weeks after surgery.

Results: The mean radiographic scores for fracture healing of both short and long term groups were lower than that of the control group and the differences among the three groups were statistically significant ($P < 0.05$) at 3, 4, 6 weeks after surgery. The mean bone trabecula density of both groups was smaller than that of the control group and the differences were also statistically significant ($P < 0.05$) at 4 week. The maximum load, total energy and stiffness in both the short term and long term groups were significantly decreased compared with those in the control group ($P < 0.05$) at 6 week.

Conclusion: Both short term and long term sustained use of celecoxib in rat models has significantly inhibitory effects on rat fracture healing.

Key words: Celecoxib, cyclooxygenase-2 inhibitors, fracture healing, prostaglandins

INTRODUCTION

Nonsteroidal antiinflammatory medications are commonly prescribed for the treatment of acute pain after fracture or during the postoperative period after fracture fixation due to their pronounced analgesic potency and antiinflammatory effects.¹ Cyclooxygenase-1 and cyclooxygenase-2 (COX-2) are two Cyclooxygenase genes the former is constitutively expressed in most tissues, including the stomach lining, whereas the latter is expressed

in events such as inflammation.^{2,3} COX-2 specific inhibitors, such as celecoxib has been widely used for common orthopedic conditions and their use have been advocated as part of a multimodality approach for postoperative pain control on account of its analgesic efficacy equivalent to that of conventional non-steroidal anti-inflammatory medications with a lower prevalence of gastrointestinal bleeding and platelet abnormalities.⁴⁻⁶

Inflammation, which occurs at the early phase of fracture healing, is postulated to play a very important role during normal fracture healing.^{2,7} Prostaglandins (PGs) generated from arachidonate by the action of cyclooxygenase isoenzymes, are believed to stimulate bone formation and resorption by mediating certain events in fracture healing.⁸ So the COX-2 inhibitors may modify the inflammation phase and delay bone healing. In the past decades, some studies put forward that COX-2-selective non-steroidal antiinflammatory drug treatment can impair fracture healing in the animal models.^{2,9-11} While other studies show no or only transient inhibitory effects on bone healing.^{3,5,6,12,13} In addition, the dose of selective COX-2 inhibitors used in animals models varies with no unified standard. Thus, the use of COX-2 inhibitors for the management of pain and inflammation caused by operations of fractures remains controversial.

Departments of Orthopaedics, Xiangya Hospital, Central South University, Changsha and ¹Chenzhou People's Hospital, Chenzhou, 423000, Hunan, China

Address for correspondence: Dr. Yong Zhu,
Department of Orthopaedics, Xiangya Hospital, Central South University,
Changsha, 410008, Hunan, China.
E-mail: doczhu2004@163.com

Access this article online	
Quick Response Code:	Website: www.ijoonline.com
	DOI: 10.4103/0019-5413.114930

We calculated the dose of celecoxib for rat model based on body surface area conversion and the purpose of this study was to determine whether the postoperative short term and long term administration of celecoxib would affect fracture healing or not.

MATERIALS AND METHODS

Animals

The study protocol was reviewed and approved by our institutional animal care and use committee. A total of 72 Sprague-Dawley female rats (276 ± 12 g, 11 ± 2 weeks) were used for this study. All animals were fed in the laboratory for a week before operation for adaptation to the new environment. Two or three rats were housed in each cage and provided fresh water and chow *ad libitum* with a 12-12 h light-dark cycle. All the animals were killed by administering a lethal dose of sodium pentobarbital.

Operative procedure

After general anesthesia induced by the intraperitoneal injection of 10% chloral hydrate (3 mL/kg), the rat was fixed on the customized operating table. The animal's right femur was prepped with betadine and sterile draped. A 1-cm longitudinal incision was made over the lateral side of the right femur. After separating the soft tissue around the middle of the femoral diaphysis, a transverse femoral diaphysis fracture was made by fretsaw. The skin and underlying soft tissues over the knee was incised lateral to the patellar tendon. The tendon was displaced medially and then an intramedullary Kirschner wire (0.8 mm steel K-wire) was inserted until meeting with resistance of the underlying bone of the trochanter by using a hand held drill and it was then slightly retracted, cut, reinserted and buried under soft tissue. The incision was closed with sutures in two layers. The rats were administered penicillin 80 U IM as a prophylactic antibiotic every 12 h for 3 days. The rats were permitted free weight bearing and unrestricted use of their limbs after operation.

Drug treatment groups

Drugs were delivered by oral gavage once a day beginning at 4 h after fracture operation. Celecoxib (Pfizer, New York, NY) was suspended in 1% methylcellulose and the 1% methylcellulose was delivered in a volume of 2 mL/300 g rat. The rats were randomized into three groups ($n = 24$ in each group) after operations. They were separately administered 1% methylcellulose (2 ml/d) for 4 weeks (control group), celecoxib (21 mg/kg/d) for 1 week and then 1% methylcellulose for 3 week (short term group), celecoxib (21 mg/kg/d) for 4 weeks (long term group). The dose of celecoxib given to rats was equivalent the human dosing regimen of 200 mg/day based on body surface area conversion (animal

dose (mg/kg) = human equivalent dose (mg/kg) \times 6.2, assuming that an adult person weighs 60 kg).¹⁴

Radiographic analysis

Radiographs of bilateral femurs were made at the time point of immediately after operation, 2, 3, 4, 6 weeks after surgery by using Faxitron Cabinet X-ray System (Faxitron X-ray corporation, Model 43855A, USA) and Kodak X-OMAT BT film (Eastman Kodak, Rochester, New York, USA). The radiographs of 3, 4, 6 weeks were evaluated according to a scoring system for fracture healing as previously described.¹⁵ The system consists of three categories: periosteal reaction (0-3), bone union (0-3) and remodeling (0-2). For evaluation, the radiographs were scored by two orthopedic radiologists with randomized blinded selection of films.

Histologic analysis

Half rats of each group were randomly selected for euthanization at 4 weeks postfracture. The soft tissue of the fracture femurs was dissected, dissection was extraperiosteal and the K-wire was carefully removed. The femurs with their callus were fixed in 4% paraformaldehyde in phosphate buffered saline solution at 4°C for 48 h before undergoing decalcification in 7% formic acid. After decalcification, specimens were then embedded in paraffin, from which 7 μ m sections were cut, mounted on slides and stained with hematoxylin and eosin. Slides were observed under a light microscope and new bone density of the visual fields was analyzed by medical image analysis system (Beihang University, Beijing, China).

Mechanical analysis

The remaining rats were euthanized at 6 weeks post-fracture. At the time of harvest, the soft tissue of the fracture femurs was dissected and the K-wire was carefully removed. The samples were immediately wrapped in saline-soaked gauze, double-bagged and placed in a -20°C freezer (Thermo Electron Corporation, Boston, Massachusetts, USA). The night before biomechanical testing, samples were thawed over-night in an 8°C refrigerator. Evaluations were made using a three-point bending test with a servohydraulic testing machine (Model 858 Table Top system, MTS Systems Corporation, USA). Specimens were placed on a special metal holding device with supports located at a distance of 17 mm and were deflected at a rate of 5 mm/min until fracture occurred. Both the fractured right femurs and the intact left femurs were tested and the maximum load, total energy and bending stiffness were determined from the load-deformation curve. The ratios between the right and the left femur for the three mechanical properties were calculated. Nonunions were given no values.

Statistical analysis

The radiographic scores, histologic grade and data from the mechanical tests were analyzed using the one-way analysis of variance (ANOVA) and *post-hoc* tests at each time point. For the analysis of the results, we used the statistical software program SPSS for Windows version 18 (SPSS Inc., Chicago, Illinois) and a significance level of $P < 0.05$ was used for all comparisons. During the intervention, animals in which there was evidence of fixation loss or infection were excluded from the study and humanely euthanized.

RESULTS

At the time point of 3 weeks after fracture, 2 rats in group A, 3 rats in group B and 1 rat in group C were humanely euthanized based on the evidence of fixation loss or infection [Table 1].

Results of radiographic analysis

Representative radiographs of the control group showed that the fracture line started to become vague and there was some callus around the fracture site by 2 weeks; then the callus was seen apparently after the third postoperative week; at the time point of 4 week postfracture, the fracture site was enclosed by continuous callus and the fracture line had become more vague or disappeared; at the time point of 6 week after fracture, the fracture remodelled and the medullary cavity of the fracture had recanalized too. Looking at the representative radiographs of the short term group, the fracture line started to become vague and there was little callus around the fracture site at 3 weeks postoperation; The fracture site gap was partially connected by callus and the fracture line disappeared 4 weeks after fracture; After 6 weeks, the fracture bone had healed. Looking at the radiographs of the long term group, the fracture line was still clearly visible and there were little callus at the time of 4 week postoperation; when the time came to 6 week postoperation, there were little callus around the fracture site and the healing was not complete [Figure 1]. The mean radiographic scores of both short and long term group were smaller than those of the control group [Figure 2] and the difference was statistically significant ($P < 0.05$) at any time-interval.

Results of histological analysis

At 4 weeks, both the short term group and the long term

group showed significantly more fibrous tissue and less woven bone formation than that of the control group [Figure 3]. The mean bone trabecula density (%) (new bone trabecula area/total area, mean of 10 high power fields) of both short term and long term groups were smaller than that of the control group and the differences between each other were statistically significant ($P < 0.05$) [Figure 4].

Results of mechanical analysis

At 6 weeks, the maximum load, total energy and stiffness in both the short term and long term groups were significantly decreased compared with those in the control group, also these differences were statistically significant ($P < 0.05$) [Figure 5].

DISCUSSION

Bone fractures are characterized by localized tissue swelling, inflammation and pain. COX-2 selective inhibitors are commonly used for postoperative pain control due to their function of alleviation of local inflammation and pain by inhibiting cyclooxygenase, which is the rate limiting enzyme in the conversion of arachidonic acid to pro-inflammatory PGs. As a result, COX-2 selective inhibitors impede inflammation and alleviate swelling and pain by reducing PGs levels. However, some studies have shown that the administration of COX-2 selective inhibitors can impair or delay bone healing and decrease the mechanical integrity of the healing bone, compelling many surgeons to avoid this class of medication in patients with healing fractures, osteotomies and fusions.¹⁶

In this study, the influence of celecoxib on bone healing was examined by use a rat femoral osteotomy model. According to radiographic, histological and mechanical analysis, the results indicate that celecoxib treatment, in doses analogous to those in humans, significantly impaired fracture healing in rats model. Histological sections showed that there is more fibrous tissue and less woven bone formation than those in the control group both in the short term and long term groups the results are consistent with the previous studies.^{2,17} Some studies have confirmed that even short term administration of COX-2 selective inhibitors have a negative effect on the healing process,^{18,19} which was also observed in our study. Moreover, fractures in animals administered celecoxib for

Table 1: Disposition and group sizes of animals used in the present study

Treatment group	Postoperation	Radiographic analysis			Histologic analysis	Mechanical analysis
		3 weeks	4 weeks	6 weeks	4 weeks	6 weeks
A (Control group)	24	22 ^A	22	11	11	11
B (Short term group)	24	21 ^A	21	11	10	11
C (Long term group)	24	23 ^A	23	11	12	11
Totals	72	66	66	33	33	33

^AAnimals with incision infection or loss of fixation were excluded

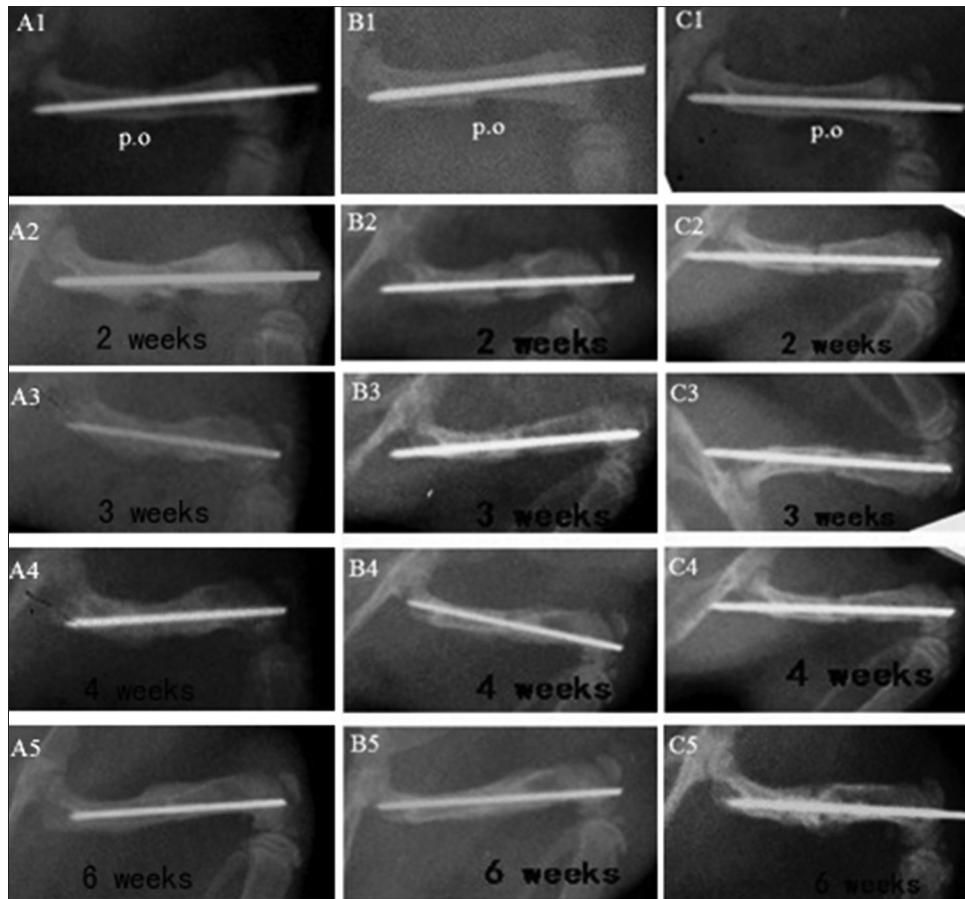


Figure 1: Representative radiographs of fracture femurs 2, 3, 4 and 6 weeks after the fracture. A1-A5 belong to control group, B1-B5 belong to short term group and C1-C5 belong to long term group

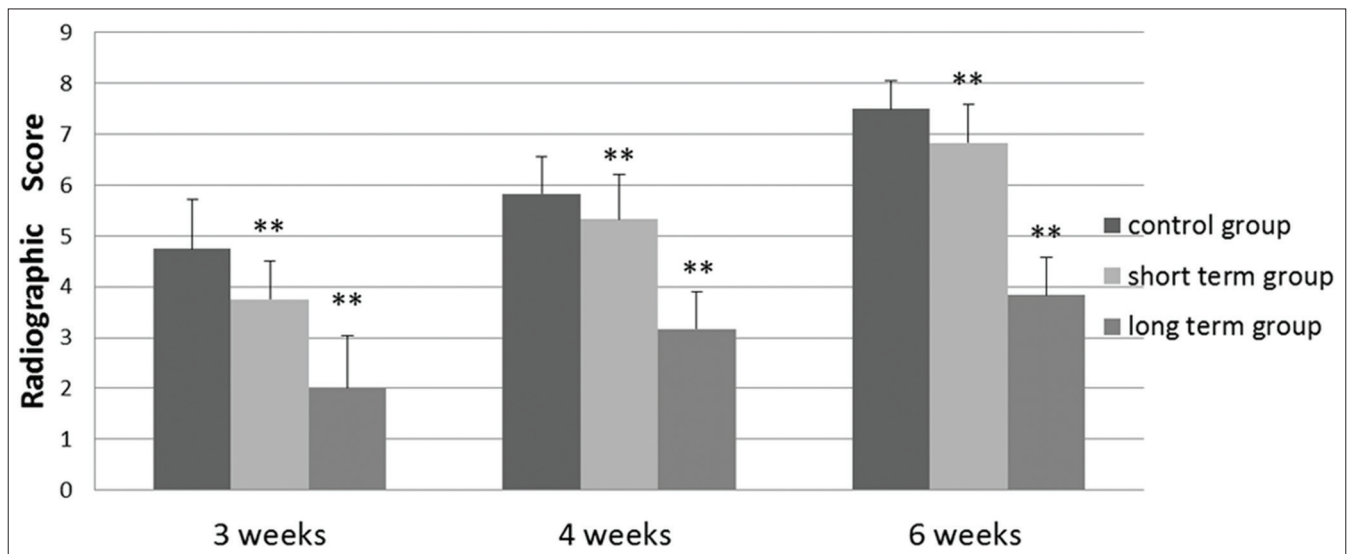


Figure 2: Histograms present the radiographic scores of different groups in different time. ** $P < 0.05$ compared with the value for the control group

a short time period had better signs of healing compared to those administered for a longer period in the present study, the differences between the groups demonstrated that the impairing effect of celecoxib on bone healing is time-dependent, which is consistent with previous experiment.²

In most of the previous studies about celecoxib that the ultimate time points for the test were 8 week or 12 week and the drug was given to animals until harvest time.^{4,5,12,13} However, we chose 4 week for histological analysis, 6 week for mechanical analysis and compared the differences

between the short term group and long term group, which is different than ever before. As Simon *et al.*²⁰ have found that fractured rat femurs regained nearly 100% of their structural properties (peak torque and torsional rigidity) and approximately 50% of the material properties (maximum shear stress and shear modulus) after 8 weeks.

Body surface area conversion is recommended as the standard way to approximate equivalent exposure of drugs

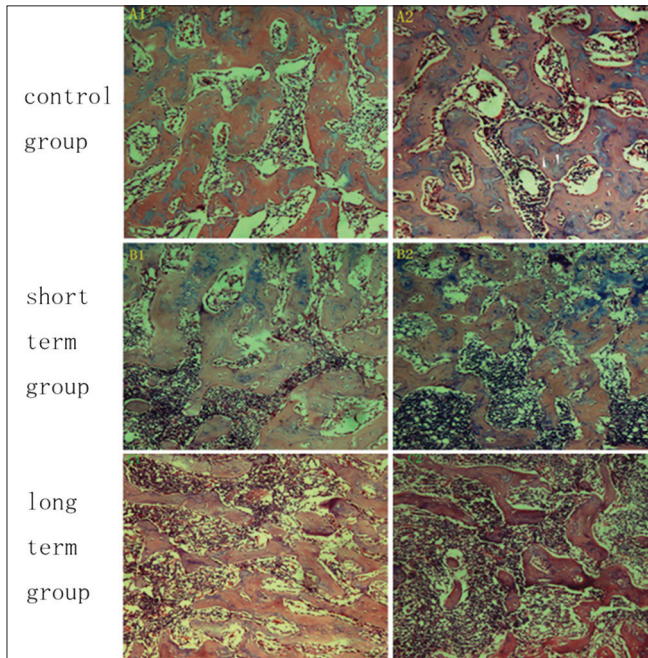


Figure 3: Histological sections demonstrating bone growth and organization 4 weeks after the fracture (×100)

among different kind of animals.¹⁴ However, in most of the previous studies, researchers simply administered human doses, corrected for weight, to rats or rabbits. Taking celecoxib as an example, the daily therapeutic dose for an adult is 200 mg or 400 mg (3.3 mg/kg or 6.6 mg/kg assuming that an adult person weighs 60 kg) and 3-4 mg/kg/d or 6-8 mg/kg/d was the most common administered dose for animal models in literatures.^{2,4,9,13} The dose of celecoxib used previously was much smaller than equivalent exposure of human therapy dose based on body surface area conversion, so the results of previous experiments may not truly reflected the celecoxib effect on bone healing of human. The dose of celecoxib administered in the present study (21 mg/kg/d) was equivalent the human dosing regimen of 200 mg/day with the use of the dose calculator based on body surface area approved by the United States Food and Drug Administration and also it was applied to rat model for the first time. Little is known about the effects of COX-2 selective inhibitors on healing fractures; thus, the mechanism by which celecoxib inhibits fracture-healing is also not fully understood by now. Some theories trying to illustrate the mechanism have been advocated and the most popular and widely acknowledged mechanism is related to PGs.

Bone turnover is the result of bone resorption and formation and both processes can be regulated by PGs. PGs have a direct effect on bone resorption through increasing osteoclastic activity. However, after a fracture, the release of PGs increased, which can stimulate the replication and differentiation of the osteoblasts, resulting

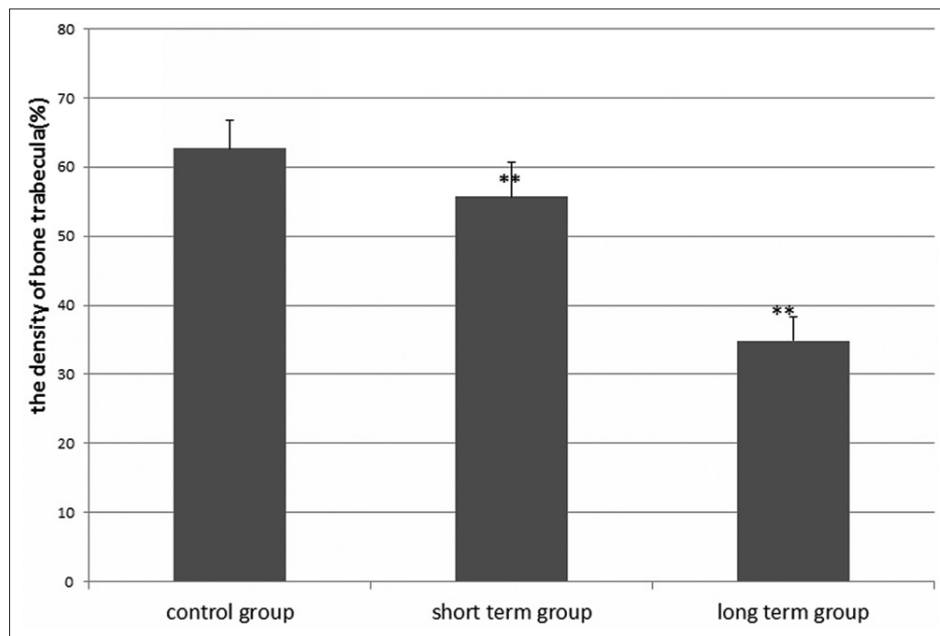


Figure 4: Bar diagram showing graphic representation of percentage of the density of bone trabecula (area ratio of bone trabecula at high magnification) 4 weeks after fracture. ** $P < 0.05$ compared with the value for the control group

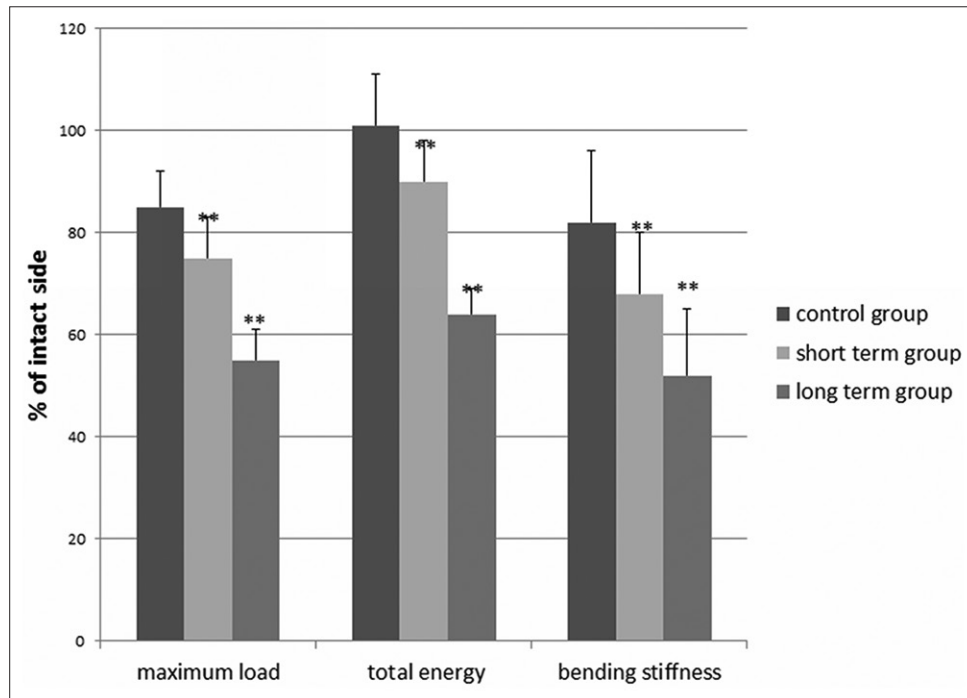


Figure 5: Bar diagram showing average maximum load, total energy and stiffness were presented as the percentage of the intact left femora 6 weeks after fracture. ** $P < 0.05$ compared with the value for the control group

in enhanced bone formation.^{21,22} Furthermore, it can stimulate osteoblastic differentiation in marrow stromal cell and primary calvarial cell cultures.^{23,24} It was reported that the Wnt/ β -catenin signaling pathway, known to be an important regulator of bone mass, is triggered by PGs in osteocytes in response to loading to transmit anabolic signals of mechanical loading to cells on the bone surface.²⁵ Genetos *et al.*²⁶ found that Prostaglandin E₂(PGE₂) can decrease SOST (sclerostin) (an important negative regulator gene of Wnt signaling) expression and thereby increase Wnt signaling in osteoblastic cells. Meanwhile, they made it clear that this effect was mediated through the PGE₂ and Cyclic adenosine monophosphate (cAMP) and involved mitigation of endogenous Bone morphogenetic protein (BMP) and Myocyte enhancer factor-2(Mef2) signaling. Thus, PGs are partly responsible for ensuring the balance between bone resorption and bone formation. As a result, COX-2 induced at inflammation sites is considered to be essential for PGs production and required for both intramembranous and endochondral bone formation during fracture healing.^{20,23} What's more, some investigations have demonstrated that COX-2 dependent PGs promotes angiogenesis in rat sponge implants as well as tumor cells,^{27,28} and angiogenesis is also required for fracture healing.²⁹

Gerstenfeld *et al.* found that COX-2 mRNA levels showed peak expression during the first 14 days of healing and returned to basal levels by day 21 in fracture callus in rats.³⁰

Due to this, inhibition of COX-2 during the early period after injury or surgery seems to have the most detrimental effects on tissue healing. Furthermore, this was demonstrated by Simon and O'Connor.² In their study, they found that inhibiting the early inflammation phase of fracture-healing can ultimately impair fracture-healing at later times. In the present study, results also indicated that short term celecoxib administration can impair bone healing.

Our study has some drawbacks that should be noted. First, the amount of the sample is a little small, only 24 animals received operation in each group, that may decreased the statistical power. In addition, the evaluating indicators for radiographic and histological analysis are relatively subjective. If objective and quantitative methods have been introduced in this study, the result may be more powerful. Third, only structural properties of the bone were tested without the material properties. Thus, further studies are needed to resolve these issues.

In conclusion, this study confirms that celecoxib can inhibit bone healing in rats femur mold with a dose based on body surface area conversion. Results of experimental animal studies may cannot be directly extrapolated to the human clinical setting, however, care should always be taken in patient's selection for COX-2 inhibitors prescription especially those fractures with known healing problems, osteotomies, after bone grafting procedures and implant surgery where bone ingrowth is essential.

REFERENCES

1. Steinmeyer J. Pharmacological basis for the therapy of pain and inflammation with nonsteroidal anti-inflammatory drugs. *Arthritis Res* 2000;2:379-85.
2. Simon AM, O'Connor JP. Dose and time-dependent effects of cyclooxygenase-2 inhibition on fracture-healing. *J Bone Joint Surg Am* 2007;89:500-11.
3. Tiseo BC, Namur GN, de Paula EJ, Junior RM, de Oliveira CR. Experimental study of the action of COX-2 selective nonsteroidal anti-inflammatory drugs and traditional anti-inflammatory drugs in bone regeneration. *Clinics (Sao Paulo)* 2006;61:223-30.
4. Brown KM, Saunders MM, Kirsch T, Donahue HJ, Reid JS. Effect of COX-2-specific inhibition on fracture-healing in the rat femur. *J Bone Joint Surg Am* 2004;86-A: 116-23.
5. Mullis BH, Copland ST, Weinhold PS, Miclau T, Lester GE, Bos GD. Effect of COX-2 inhibitors and non-steroidal anti-inflammatory drugs on a mouse fracture model. *Injury* 2006;37:827-37.
6. Hak DJ, Schulz KS, Khoie B, Hazelwood SJ. The effect of Cox-2 specific inhibition on direct fracture healing in the rabbit tibia. *J Orthop Sci* 2011;16:93-8.
7. Pountos I, Georgouli T, Calori GM, Giannoudis PV. Do nonsteroidal anti-inflammatory drugs affect bone healing? A critical analysis. *Scientific World Journal* 2012;2012:606404.
8. Li M, Thompson DD, Paralkar VM. Prostaglandin E (2) receptors in bone formation. *Int Orthop* 2007;31:767-72.
9. Bergenstock M, Min W, Simon AM, Sabatino C, O'Connor JP. A comparison between the effects of acetaminophen and celecoxib on bone fracture healing in rats. *J Orthop Trauma* 2005;19:717-23.
10. O'Connor JP, Capo JT, Tan V, Cottrell JA, Manigrasso MB, Bontempo N, *et al.* A comparison of the effects of ibuprofen and rofecoxib on rabbit fibula osteotomy healing. *Acta Orthop* 2009;80:597-605.
11. Gerstenfeld LC, Al-Ghawas M, Alkhiary YM, Cullinane DM, Krall EA, Fitch JL, *et al.* Selective and nonselective cyclooxygenase-2 inhibitors and experimental fracture-healing. Reversibility of effects after short-term treatment. *J Bone Joint Surg Am* 2007;89:114-25.
12. Long J, Lewis S, Kuklo T, Zhu Y, Riew KD. The effect of cyclooxygenase-2 inhibitors on spinal fusion. *J Bone Joint Surg Am* 2002;84-A: 1763-8.
13. Iwamoto, Azusa S, Matsumoto H, Uzawa M. Celecoxib does not significantly delay bone healing in a rat femoral osteotomy model: a bone histomorphometry study. *Orthop Res Rev* 2011;3:39.
14. Reagan-Shaw S, Nihal M, Ahmad N. Dose translation from animal to human studies revisited. *FASEB J* 2008;22:659-61.
15. An YH, Friedman RJ, Draughn RA. Animal models of bone fracture or osteotomy. In: An YH, Friedman RJ (editors). *Animal Models in Orthopaedic Research*. Boca Raton, FL: CRC Press; 1999. p. 197-217.
16. Dodwell ER, Latorre JG, Parisini E, Zwettler E, Chandra D, Mulpuri K, *et al.* NSAID exposure and risk of nonunion: A meta-analysis of case-control and cohort studies. *Calcif Tissue Int* 2010;87:193-202.
17. Murnaghan M, Li G, Marsh DR. Nonsteroidal anti-inflammatory drug-induced fracture nonunion: An inhibition of angiogenesis? *J Bone Joint Surg Am* 2006;88 Suppl 3:140-7.
18. Meunier A, Aspenberg P. Parecoxib impairs early metaphyseal bone healing in rats. *Arch Orthop Trauma Surg* 2006;126:433-6.
19. Dimmen S, Nordsetten L, Madsen JE. Parecoxib and indomethacin delay early fracture healing: A study in rats. *Clin Orthop Relat Res* 2009;467:1992-9.
20. Simon AM, Manigrasso MB, O'Connor JP. Cyclo-oxygenase 2 function is essential for bone fracture healing. *J Bone Miner Res* 2002;17:963-76.
21. Harada SI, Balena R, Rodan GA, Rodan SB. The role of prostaglandins in bone formation. *Connect Tissue Res* 1995;31:279-82.
22. Mori S, Jee WS, Li XJ, Chan S, Kimmel DB. Effects of prostaglandin E2 on production of new cancellous bone in the axial skeleton of ovariectomized rats. *Bone* 1990;11:103-13.
23. Zhang X, Schwarz EM, Young DA, Puzas JE, Rosier RN, O'Keefe RJ. Cyclooxygenase-2 regulates mesenchymal cell differentiation into the osteoblast lineage and is critically involved in bone repair. *J Clin Invest* 2002;109:1405-15.
24. Blackwell KA, Raisz LG, Pilbeam CC. Prostaglandins in bone: Bad cop, good cop? *Trends Endocrinol Metab* 2010;21:294-301.
25. Bonewald LF, Johnson ML. Osteocytes, mechanosensing and Wnt signaling. *Bone* 2008;42:606-15.
26. Genetos DC, Yellowley CE, Loots GG. Prostaglandin E2 signals through PTGER2 to regulate sclerostin expression. *PLoS One* 2011;6:e17772.
27. Katoh H, Hosono K, Ito Y, Suzuki T, Ogawa Y, Kubo H, *et al.* COX-2 and prostaglandin EP3/EP4 signaling regulate the tumor stromal proangiogenic microenvironment via CXCL12-CXCR4 chemokine systems. *Am J Pathol* 2010;176:1469-83.
28. Majima M, Hayashi I, Muramatsu M, Katada J, Yamashina S, Katori M. Cyclo-oxygenase-2 enhances basic fibroblast growth factor-induced angiogenesis through induction of vascular endothelial growth factor in rat sponge implants. *Br J Pharmacol* 2000;130:641-9.
29. Hausman MR, Schaffler MB, Majeska RJ. Prevention of fracture healing in rats by an inhibitor of angiogenesis. *Bone* 2001;29:560-4.
30. Gerstenfeld LC, Thiede M, Seibert K, Mielke C, Phippard D, Svarg B, *et al.* Differential inhibition of fracture healing by non-selective and cyclooxygenase-2 selective non-steroidal anti-inflammatory drugs. *J Orthop Res* 2003;21:670-5.

How to cite this article: Li K, Cheng L, Zhu Y, Deng G, Long H. Effects of a selective cyclooxygenase-2 inhibitor (celecoxib) on fracture healing in rats. *Indian J Orthop* 2013;47:395-401.

Source of Support: This study was supported by the grants from the National 863 project of China (2011AA030101). We also wish to acknowledge that the Celecoxib was provided freely by Pfizer, **Conflict of Interest:** None.