

OPEN

Microvesicular Steatosis and Severe Cardiac Allograft Dysfunction

Xingchen Mai, MD,¹ Paulino A. Alvarez, MD,¹ E. Rene Rodriguez, MD,² Carmela D. Tan, MD,² and Gerard J. Boyle, MD³

INTRODUCTION

Cardiac allograft dysfunction due to rejection is a potentially fatal phenomenon that requires rapid evaluation and treatment. Myocardial steatosis refers to the accumulation of lipids in the myocardium and can be defined as macrovesicular or microvesicular depending on the lipid droplet size.

We report on 3 patients who presented with acute severe cardiac allograft dysfunction and microvesicular steatosis.

CASE REPORT

Patient 1

A 16-mo-old girl with a history of restrictive cardiomyopathy probably associated with MHY7 mutation presented with cardiogenic shock 1 mo after heart transplantation because of severe biventricular dysfunction. The patient had preexisting donor-specific antibodies (DSAs), but repeat DSA testing on admission revealed de novo DSAs and increased mean fluorescence intensity of preexisting DSAs (Table 1). She was started on intravenous milrinone and treated with high-dose corticosteroids for presumed acute allograft rejection. Endomyocardial biopsy (EMB) showed mild acute cellular rejection (ACR) (International Society for Heart and Lung Transplantation [ISHLT] grade 1R) with negative immunofluorescence staining

for markers of antibody-mediated rejection (AMR)—C3d and C4d; however, the myocytes showed numerous small vacuoles in the sarcoplasm on hematoxylin and eosin that stained positive for fat on oil red O (ORO) stain in frozen sections. The initial working diagnosis was microvesicular steatosis, probably related to an adverse drug reaction. Her medications included mycophenolate, tacrolimus, sulfamethoxazole-trimethoprim, valganciclovir, Nystatin, melatonin, furosemide, and famotidine. Given previous reports of calcineurin inhibitors (CNIs) associated with hepatic steatosis after liver transplant, tacrolimus was held.¹ There were no rash or eosinophilia on admission. Notably, the patient was not on steroids per standard pediatric transplant protocol. Laboratory findings were not consistent with carnitine deficiency. Liver enzymes were normal, and ultrasound and liver biopsy did not reveal hepatic steatosis. Over the next few days, cardiac function and hemodynamics improved, and immunosuppressants were restarted. On hospital day 9, she progressed to worsening cardiogenic shock. Repeat cardiac biopsy still exhibited microvesicular steatosis but was less extensive; however, immunofluorescence for C3d and C4d were now positive, and DSAs continued to rise. Plasmapheresis and intravenous immunoglobulin (IVIG) were administered. Hemodynamics recovered, DSA values stabilized, and a third cardiac biopsy showed resolution of microvesicular steatosis. She was discharged on hospital day 33. The patient has been doing well with no recurrent allograft dysfunction or pathologic findings of microvesicular steatosis in the subsequent 6 y. There has been no evidence of cardiac allograft vasculopathy in recent follow-up coronary angiograms.

Patient 2

An 8-y-old girl with dilated cardiomyopathy presented with dyspnea, epigastric discomfort, and emesis 4 mo after her second heart transplant with cardiogenic shock because of severe biventricular dysfunction.

The patient received high-dose corticosteroids and intravenous milrinone. EMB performed on day 1 of hospitalization revealed moderate ACR (ISHLT grade 2R) and no histopathological or immunopathological evidence of AMR. DSA testing on admission did not show de novo DSAs or increased intensity of preexisting DSAs (Table 1). Acylcarnitine profile showed reduced concentrations of total and free carnitine in plasma (carnitine: 15.8 $\mu\text{mol/L}$ [29.1–73.0]; free carnitine: 10.9 $\mu\text{mol/L}$ [23.3–57.9]) and urine (carnitine, total: 52.97 $\mu\text{mol/g}$ creatinine [62.2–369.3]; carnitine, free: 3.54 $\mu\text{mol/g}$ creatinine [7.7–254.1]). Six years prior, the patient had a normal serum carnitine profile.

Received 19 October 2021. Revision received 30 November 2021.

Accepted 15 December 2021.

¹ Department of Cardiology, Heart Failure and Transplant Section, Cleveland Clinic, Cleveland, OH.

² Department of Pathology, Cleveland Clinic, Cleveland, OH.

³ Department of Pediatric Cardiology, Cleveland Clinic, Cleveland, OH.

The authors declare no funding or conflicts of interest.

X.M. provided care of the adult patient and participated in writing and editing the article. P.A.A. provided care of the adult patient and coordinated and participated in writing and editing the article. E.R.R. provided pathology images and critically reviewed the article. C.D.T. provided pathology images and critically reviewed the article. G.J.B. provided and cared for the pediatric patients and helped with editing and critical review of the article.

Correspondence: Paulino A. Alvarez, Department of Cardiology, Heart Failure and Transplant Section, Cleveland Clinic, 9500 Euclid Avenue/J3-4, Cleveland, OH 44195. (alvarezp3@ccf.org).

Copyright © 2022 The Author(s). Transplantation Direct. Published by Wolters Kluwer Health, Inc. This is an open-access article distributed under the terms of the Creative Commons Attribution-Non Commercial-No Derivatives License 4.0 (CCBY-NC-ND), where it is permissible to download and share the work provided it is properly cited. The work cannot be changed in any way or used commercially without permission from the journal.

ISSN: 2373-8731

Transplantation Direct 2022;8: e1290; doi: 10.1097/TXD.0000000000001290.

TABLE 1.
Patient characteristics

	Case 1	Case 2	Case 3
Age	16 mo	8 y	61 y
Gender	Female	Female	Female
Presentation after transplant (mo)	1	4	27
Baseline immunotherapy	MMF Tacrolimus	MMF Prednisone Tacrolimus	MMF Prednisone Tacrolimus
Donor: age, gender; cause of death; left ventricular ejection fraction	19 mo old, female; MVA; LVEF 63%	12 y old, male; MVA; LVEF 60%	28 y old, female; MVA; LVEF 55%
Recipient/donor CMV	±	±	+/+
CMV PCR on admission	Negative	Negative	Negative
Recipient/donor EBV	-/-	+/+	±
LVEF on presentation	45%	44%	15%
WBC (k/ μ L)	5.32	10.90	13.19
Hemoglobin (g/dL)	8.1	10.1	8.6
BUN (mg/dL)	40	46	37
Creatinine (mg/dL)	0.41	1.62	2.92
Bilirubin (mg/dL)	0.4	0.4	0.2
AST (U/L)	47	33	20
ALT (U/L)	41	32	41
CK (U/L)	146	134	77
Troponin T (ng/mL)	0.979	0.62	0.260
DSAs before admission	Yes: DQ 9 (3000)	Yes DQ 6	No
De novo DSAs (median fluorescence intensity)	Yes: A26 (5229 and C1Q positive), B58 (3042), Cw15 (2668), DR13 (1380), and DQ9 (7417)	No	Donor-specific HLA antibodies to B8 (2008), DQ4 (1465), de novo Cw7 (5007), and de novo DQ2 (8841)
DSA intensity on admission	Higher	DSA to DQ6 is no longer detectable.	MFI from previous DSA decreasing
ACR	1R	2R	1R
AMR	Initially negative C3d/C4d; subsequent positive C3d/C4d	Negative C3d/C4d	Negative C3d/C4d
MCS	No	No	Impella
Treatment			
Pulse steroids	Yes	Yes	Yes
Thymoglobulin	No	No	Yes
Plasmapheresis	Yes	Yes	Yes
IVIg	Yes	Yes	Yes
Rituximab	No	Yes	No
Outcome	Alive and well	Expired during admission	Expired during admission

ACR, acute cellular rejection; ALT, alanine transaminase; AMR, antibody-mediated rejection; AST, aspartate transaminase; BUN, blood urea nitrogen; CK, Creatine kinase; CMV, cytomegalovirus; DSA, donor-specific antibody; EBV, Epstein-Barr virus; IVIG, intravenous immunoglobulin; LVEF, left ventricular ejection fraction; MCS, mechanical circulatory support; MFI, mean fluorescence intensity; MMF, mycophenolate mofetil; MVA, motor vehicle accident; PCR, polymerase chain reaction; WBC, white blood cell count.

The patient's hemodynamics deteriorated, requiring multiple inotropic and vasopressor agents. Although the biopsy did not suggest AMR, she was started on plasmapheresis, IVIG, and rituximab in the setting of refractory shock. Despite aggressive therapy, the patient progressed into multisystem organ failure and expired on hospital day 27. Postmortem tissue analysis found extensive vacuolization of the cardiomyocytes, hepatocytes, and renal tubular epithelial cells. ORO staining confirmed microvesicular steatosis in these cells. The donor's heart showed mild cellular rejection, negative C3d and C4d staining, and no evidence of allograft vasculopathy. Previous heart allograft did not show evidence of microsteatosis.

Patient 3

A 61-y-old woman with a history of heart transplant 2 y prior for advanced heart failure due to nonischemic cardiomyopathy presented to the Emergency Department with cardiogenic shock. Five weeks before presentation, she was

diagnosed with COVID-19 by polymerase chain reaction test via nasopharyngeal swab and reported mild symptoms. Left ventricular ejection fraction was 15%. Repeat SARS-CoV-2 nasopharyngeal swab polymerase chain reaction test was negative. She was given high-dose corticosteroids, antithymocyte globulin, dobutamine, and an intra-aortic balloon pump was placed. Mechanical circulatory support was exchanged for an axillary Impella 5.5 due to refractory shock. EMB on the first day of her hospitalization showed ACR ISHLT grade 1R and no AMR. There was focal mild myocyte vacuolization positive for ORO staining, consistent with microvesicular steatosis.

Admission DSA testing revealed de novo DSAs with significantly elevated mean fluorescence intensity (Table 1). She had no DSAs and no history of AMR before this admission. After initial therapies, the patient improved allograft function to left ventricular ejection fraction 35%, and hemodynamics allowed mechanical and inotropic support removal. Repeat biopsy on hospital day 9 revealed more extensive

microvesicular steatosis, markedly increased from the previous biopsy, with stable ACR and no AMR (Figure 1A and B). Cardiogenic shock recurred, requiring inotrope and intra-aortic balloon pump. She underwent plasmapheresis and IVIG. Additional EMB on hospital day 16 did not show any change in ACR and still no AMR, but there was a significant reduction in microvesicular steatosis (Figure 1C). Electron microscopy did not reveal viral particles (Figure 1D). The patient developed intracranial hemorrhage on hospital day 21 and

multisystem organ failure, and she expired on hospital day 29. An angiogram performed 12 mo before admission showed no evidence of cardiac allograft vasculopathy.

DISCUSSION

To our knowledge, this is the first report describing the presence of myocardial microvesicular steatosis in patients presenting with severe cardiac allograft dysfunction.

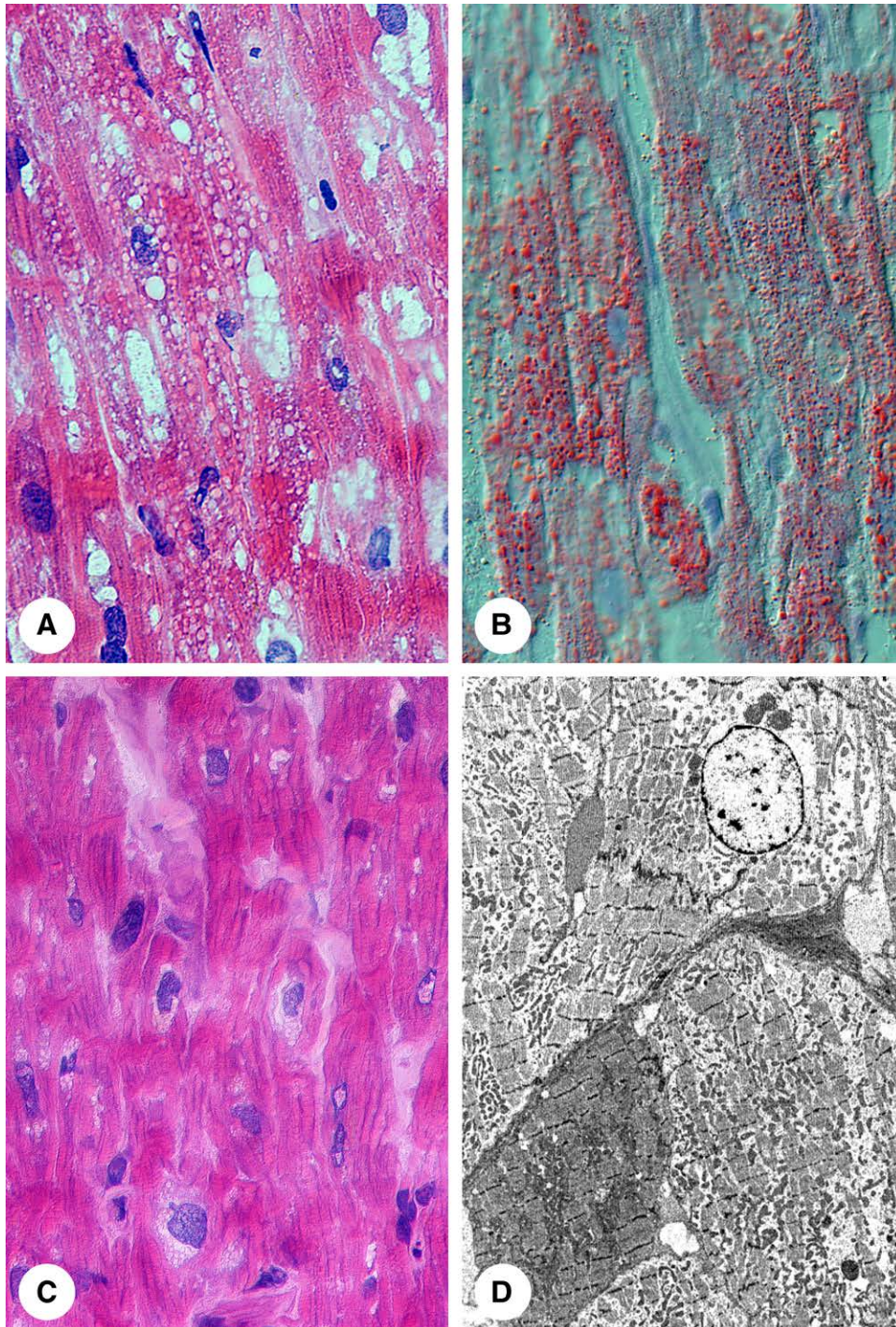


FIGURE 1. Pathology of microvesicular steatosis. A, Frozen section of transplant biopsy of patient 3 showing multiple small vacuoles in the sarcoplasm of the myocytes. B, Oil red O stain reveals accumulation of fat stained in red corresponding to the empty vacuoles seen on the H&E slide in A. C, Follow-up biopsy shows resolution of the microvesicular steatosis. D, Electron microscopy reveals no abnormalities of the mitochondria, absence of fat vacuoles, and absence of viral particles. H&E, hematoxylin and eosin.

In humans, myocardial steatosis has been reported in coronary artery disease and aortic stenosis.^{2,3} Decreased fatty acid utilization, reduced energy production by a reduction in the respiratory chain and adenosine triphosphatase activity, and decreased availability of high energy phosphates are among the metabolic abnormalities described in heart failure.⁴ Animal models have shown that cardiac-restricted long-chain acyl CoA synthase overexpression, administration of pyruvate kinase inhibitors, and inactivation of pituitary adenylate cyclase-activating polypeptide can all disrupt mitochondrial fatty acid metabolism and lead to lipid vacuolization in multiple tissues, including the heart, liver, and skeletal muscle.⁵⁻⁷

Microvesicular fat accumulation in multiple organs is a hallmark of Reye syndrome.⁸⁻¹⁰ This disorder is characterized by rapidly progressive encephalopathy, usually occurring after recovery from a viral illness, such as influenza and varicella, and is strongly associated with salicylate use.¹¹ Neither of the pediatric patients in our cohort had known salicylate exposure.

In patient 1, CNI were placed on hold because of their potential relationship with microsteatosis in liver transplantation.¹² The adverse metabolic effects of CNI have been well described. Still, their link to the development of steatosis is uncertain.¹ Drugs that have been associated with microvesicular steatosis include amiodarone, aspirin, steroids, and ibuprofen. Our patient was not exposed to any other potential medication. Holding the CNI leads to the expression of graft rejection as the possible mechanism of allograft dysfunction. The relationship of microsteatosis as an initial marker of metabolic stress in the context of early rejection cannot be ruled out.

In patient 2, moderate cellular rejection and allograft dysfunction were the presenting features and clinical course worsening despite aggressive immunosuppression. Microvesicular steatosis in cardiac allograft, liver, and kidneys makes the case of immunological mediated injury unlikely. Interestingly, acylcarnitine serum levels were low despite normal serum concentrations 6 y prior. The link between hemodynamic stress, multiorgan failure, and acquired carnitine deficiency leading to multiorgan microsteatosis has not been described but is biologically plausible.¹³

Patient 3 presented with severe allograft dysfunction and microsteatosis that resolved with antirejection therapy. Whether hemodynamic stress or biopsy-negative rejection were the causes leading to steatosis is unknown.¹⁴ Patient 3 was on daily aspirin 81 mg, but there is no known evidence suggesting adult salicylate use is a risk factor for Reye syndrome. Patient 3 did acquire a viral illness with COVID-19 5 wk antecedent to her admission. COVID-19 myocarditis has led to cases of cardiogenic shock, and viral particles of SARS-CoV-2 have been identified within the myocardium¹⁵; however, no viral particles were discovered on the electron microscopy of patient 3. Myocardial microvesicular lipid infiltration has been reported in a case of toxic shock syndrome, but none of our patients met the criteria for this condition.¹⁶

Gene expression profiling studies have shown that myocardial samples obtained during an episode of rejection have decreased activity of mitochondrial-related genes and increased activity of immune response genes.¹⁷ Chronic tumour necrosis factor- α exposure alters mitochondrial function through the activation of nuclear factor- κ B.¹⁸ Anticardiac antibodies directed against ATP synthase have been reported in end-stage heart failure.¹⁹ A potential diagnostic and therapeutic approach to microsteatosis in an EMB

includes: (1) rule out potential medications associated with steatosis; (2) evaluate the presence of metabolic disorders related to steatosis; (3) evaluate and treat causes of metabolic stress such as allograft rejection and cardiogenic shock.

Magnetic resonance spectroscopy can measure myocardial triglyceride content and correlates well with histological quantification providing a potential tool for the noninvasive diagnosis of myocardial steatosis.³

In conclusion, we reported 3 cases of microsteatosis detected in the EMB sample obtained in the context of cardiac allograft dysfunction. Further research is needed to understand the significance and potential links between microvesicular steatosis and cardiac allograft dysfunction and whether these findings may be a response to injury or treatments.

REFERENCES

1. Taneja S, Roy A. Nonalcoholic steatohepatitis recurrence after liver transplant. *Transl Gastroenterol Hepatol.* 2020;5:24.
2. Mazzali G, Fantin F, Zoico E, et al. Heart fat infiltration in subjects with and without coronary artery disease. *J Clin Endocrinol Metab.* 2015;100:3364–3371.
3. Mahmood M, Bull S, Suttie JJ, et al. Myocardial steatosis and left ventricular contractile dysfunction in patients with severe aortic stenosis. *Circ Cardiovasc Imaging.* 2013;6:808–816.
4. Neubauer S. The failing heart—an engine out of fuel. *N Engl J Med.* 2007;356:1140–1151.
5. Lee Y, Naseem RH, Duplomb L, et al. Hyperleptinemia prevents lipotoxic cardiomyopathy in acyl CoA synthase transgenic mice. *Proc Natl Acad Sci U S A.* 2004;101:13624–13629.
6. Jones HB, Reens J, Johnson E, et al. Myocardial steatosis and necrosis in atria and ventricles of rats given pyruvate dehydrogenase kinase inhibitors. *Toxicol Pathol.* 2014;42:1250–1266.
7. Marelli-Berg FM, Aksentijevic D. Immunometabolic cross-talk in the inflamed heart. *Cell Stress.* 2019;3:240–266.
8. Trauner DA. Pathologic changes in a rabbit model of Reye's syndrome. *Pediatr Res.* 1982;16:950–953.
9. Morales AR, Bourgeois CH, Chulacharit E. Pathology of the heart in Reye's syndrome (encephalopathy and fatty degeneration of the viscera). *Am J Cardiol.* 1971;27:314–317.
10. Lajoie J, Sagy M, Gonzalez R. Reye's syndrome associated with acute myocarditis and fatal circulatory failure. *Pediatr Emerg Care.* 1991;7:226–228.
11. Pugliese A, Beltramo T, Torre D. Reye's and Reye's-like syndromes. *Cell Biochem Funct.* 2008;26:741–746.
12. Acampa M, Lazzarini PE, Guideri F, et al. Ischemic stroke after heart transplantation. *J Stroke.* 2016;18:157–168.
13. Flanagan JL, Simmons PA, Vehige J, et al. Role of carnitine in disease. *Nutr Metab (Lond).* 2010;7:30.
14. Fishbein MC, Kobashigawa J. Biopsy-negative cardiac transplant rejection: etiology, diagnosis, and therapy. *Curr Opin Cardiol.* 2004;19:166–169.
15. Albert CL, Carmona-Rubio AE, Weiss AJ, et al. The enemy within: sudden-onset reversible cardiogenic shock with biopsy-proven cardiac myocyte infection by severe acute respiratory syndrome coronavirus 2. *Circulation.* 2020;142:1865–1870.
16. Smith JH, Krull F, Cohen GH, et al. A variant of toxic shock syndrome. Clinical, microbiologic, and autopsy findings in a fatal case. *Arch Pathol Lab Med.* 1983;107:351–357.
17. Romero E, Chang E, Tabak E, et al. Rejection-associated mitochondrial impairment after heart transplantation. *Transplant Direct.* 2020;6:e616.
18. Gray SL, Cummings KJ, Jirik FR, et al. Targeted disruption of the pituitary adenylate cyclase-activating polypeptide gene results in early postnatal death associated with dysfunction of lipid and carbohydrate metabolism. *Mol Endocrinol.* 2001;15:1739–1747.
19. Youker KA, Assad-Kottner C, Cordero-Reyes AM, et al. High proportion of patients with end-stage heart failure regardless of aetiology demonstrates anti-cardiac antibody deposition in failing myocardium: humoral activation, a potential contributor of disease progression. *Eur Heart J.* 2014;35:1061–1068.