

Surgical Management of Mitral Regurgitation in Patients with Marfan Syndrome during Infancy and Early Childhood

Eung Re Kim, M.D.¹, Woong-Han Kim, M.D., Ph.D.¹, Eun Seok Choi, M.D.¹, Sungkyu Cho, M.D.¹,
Woo Sung Jang, M.D.², Yong Jin Kim, M.D.³

Background: Mitral regurgitation is one of the leading causes of cardiovascular morbidity in pediatric patients with Marfan syndrome. The purpose of this study was to contribute to determining the appropriate surgical strategy for these patients. **Methods:** From January 1992 to May 2013, six patients with Marfan syndrome underwent surgery for mitral regurgitation in infancy or early childhood. **Results:** The median age at the time of surgery was 47 months (range, 3 to 140 months) and the median follow-up period was 3.6 years (range, 1.3 to 15.5 years). Mitral valve repair was performed in two patients and four patients underwent mitral valve replacement with a mechanical prosthesis. There was one reoperation requiring valve replacement for aggravated mitral regurgitation two months after repair. The four patients who underwent mitral valve replacement did not experience any complications related to the prosthetic valve. One late death occurred due to progressive emphysema and tricuspid regurgitation. **Conclusion:** Although repair can be an option for some patients, it may not be durable in infantile-onset Marfan syndrome patients who require surgical management during infancy or childhood. Mitral valve replacement is a feasible treatment option for these patients.

Key words: 1. Marfan syndrome
2. Infant
3. Mitral valve insufficiency

INTRODUCTION

Marfan syndrome is an autosomal dominant heritable disorder of the connective tissue involving the skeletal, ocular, and cardiovascular systems. Cardiovascular complications such as aortic rupture and mitral valve dysfunction affect the life expectancy of patients with this disorder [1]. While aortic disease is known to be responsible for most premature and sudden mortalities in adults with Marfan syndrome, mitral valve dysfunction is the most common cause of morbidity

and mortality in infantile-onset Marfan syndrome [2]. However, the choice between replacement and repair remains controversial, especially in infants and young children, because of the underlying degenerative process, their smaller heart size, and the necessity of anticoagulation therapy. We report our experience in the surgical management of mitral regurgitation in younger Marfan syndrome patients, in order to contribute to the ongoing search for the optimal surgical management of such patients.

¹Department of Thoracic and Cardiovascular Surgery, Seoul National University Children's Hospital, Seoul National University College of Medicine, ²Department of Thoracic and Cardiovascular Surgery, Kyungpook National University Hospital, ³Department of Thoracic and Cardiovascular Surgery, Seoul National University Bundang Hospital, Seoul National University College of Medicine

Received: August 13, 2014, Revised: September 26, 2014, Accepted: October 2, 2014, Published online: February 5, 2015

Corresponding author: Woong-Han Kim, Department of Thoracic and Cardiovascular Surgery, Seoul National University Children's Hospital, Seoul National University College of Medicine, 101 Daehak-ro, Jongno-gu, Seoul 110-744, Korea
(Tel) 82-2-2072-2347 (Fax) 82-2-764-3664 (E-mail) woonghan@snuh.ac.kr

© The Korean Society for Thoracic and Cardiovascular Surgery. 2015. All rights reserved.

© This is an open access article distributed under the terms of the Creative Commons Attribution Non-Commercial License (<http://creativecommons.org/licenses/by-nc/3.0>) which permits unrestricted non-commercial use, distribution, and reproduction in any medium, provided the original work is properly cited.

Table 1. Clinical characteristics of the patients

Case	Sex	Age at diagnosis (mo)	Familial history	Ectopia lentis	Fibrillin 1 mutation	Emphysematous lung	Aortic root Z-value
1	F	24	-	+	-	-	9.8
2	F	60	-	+	-	-	4.2
3	M	3	-	+	-	+	7.8
4	M	3	+	+	+	-	6.4
5	M	20	-	+	+	+	9.2
6	F	3	-	+	+	-	9.3

F, female; M, male.

Table 2. Preoperative status

Case	Heart failure	New York Heart Association functional classification	Preoperative echocardiographic findings				MV pathology		
			Left ventricle internal diameter (d/s) ^{a)}	Mitral regurgitation	Tricuspid regurgitation	Aortic regurgitation	MV prolapse	MV annulus (mm)	MV annulus Z-value
1	+	3	50/39	Severe	Mild	Moderate	+	39.5	6.2
2	-	3-4	47/30	Moderate	Mild	Trivial	+	40.0	3.0
3	+	4	38/26	Severe	Mild	Trivial	+	30.0	6.9
4	+	4	48/22	Severe	Moderate	-	+	42.0	5.2
5	+	3	55/34	Severe	Mild	Trivial	+	48.0	7.9
6	+	4	45/34	Severe	Mild	-	+	35.0	7.7

MV, mitral valve.

^{a)}Diastole/systole.

METHODS

From January 1992 to May 2013, six patients diagnosed with Marfan syndrome underwent operations in infancy or early childhood to treat mitral regurgitation. The diagnosis of Marfan syndrome was based on the Ghent nosology [3].

Standard surgical techniques were used for the repair or replacement of mitral valves. After a median sternotomy, cardiopulmonary bypass was established using ascending aortic and bicaval venous cannulation. The aorta was cross-clamped and cold crystalloid cardioplegia was infused to achieve cardiac arrest. The mitral valve was exposed through a lateral incision on the left atrium. If exposure was poor, the mitral valve was approached transeptally. The anatomy of the valve was inspected carefully, evaluating the degree of annular dilatation, elongation, or rupture of the chordae tendinae, as well as the redundancy of the leaflet. Mitral valve repair was attempted if it seemed feasible. If valve repair was unsat-

isfactory or repair seemed impossible, mitral valve replacement was performed with a prosthetic mechanical valve. The medical records of the patients, including serial echocardiography, were reviewed retrospectively.

RESULTS

Of the six patients, three were boys and three were girls (Table 1). They were diagnosed with Marfan syndrome at a median of 11.5 months old (range, 3 to 60 months) based on family history, genetic testing, and characteristic skeletal, ocular, and cardiovascular manifestations. Their median aortic root Z-value was 8.5 (range, 4.2 to 9.8).

The median age at the time of the operation was 47 months (range, 3 to 140 months) (Table 2). The median interval from diagnosis to surgery was 25 months (range, 0 to 115 months). At the time of operation, all patients were in New York Heart Association class III or IV. Five out of the

Table 3. Operation and prognosis

Case	Age at operation (mo)	Operative procedures	Prosthetic valve size (mm)	Mortality	Reoperation	Follow-up duration (yr)	Last echocardiographic findings		
							Mitral regurgitation	Left ventricle ejection fraction (%)	Other findings
1	48	MVR, TAP	27	-	David operation, aortic valve replacement	6.8	-	23	
2	140	MVP	-	-	-	15.5	Mild	61	
3	3	MVP, TAP, LA reduction-plasty	-	+ ^{a)}	MVR, LVRS	1.5	-		
4	118	MVR, TAP	27	-	-	5.3	-	58	
5	46	MVR	31	-	-	1.8	-	50	Moderate TR
6	9	MVR	23	-	-	1.3	-	51	Moderate TR

MVR, mitral valve replacement; TAP, tricuspid annuloplasty; MVP, mitral valvuloplasty; TR, tricuspid regurgitation; LA, left atrium; LVRS, lung volume reduction surgery.

^{a)}Late mortality.

six patients showed symptoms of congestive heart failure, and four of them required intravenous inotropic support in the intensive care unit. Preoperative echocardiography revealed that all of the patients had mitral valve prolapse of both leaflets, leading to mitral regurgitation over nearly the entire area of the valve orifice. Their median mitral valve annulus Z-score was 6.5 (range, 3.0 to 7.9).

Mitral valve repair was done in two patients, and four patients underwent mitral valve replacement with mechanical prostheses (Table 3). Whether to repair or replace a valve was decided by the surgeon, based on the morphology of the native valve. Attempts to repair were made in patient 1 and patient 5, but they eventually underwent replacement due to persistent mitral regurgitation. The median follow-up duration was 3.6 years (range, 1.3 to 15.5 years). In patient 2, the mitral valve repair has been successful for 15.5 years. The repair technique used in this patient included the quadrangular resection of the P2 segment, anterolateral commissuroplasty, and ring annuloplasty. However, patient 3 had to undergo valve replacement for aggravated mitral regurgitation two months after repair. Although immediate postoperative echocardiography showed only mild mitral regurgitation, it quickly progressed to severe mitral regurgitation. Four patients who underwent mitral valve replacement did not experience any prosthetic valve-related complications such as bleeding, atrio-

ventricular heart block, endocarditis, embolism, or paravalvular leakage. All valves were well-functioning until the last follow-up. There was no operative mortality and the only significant morbidity was a small subdural hemorrhage in patient 3, which resolved without extra treatment. There was one loss of follow-up after 6.8 years. One late death occurred 18 months after mitral valve repair and 16 months after reoperation. Although patient 3 underwent lung volume reduction surgery because of severe emphysema of the lung, the condition continued to progress. The patient died of respiratory failure and severe tricuspid regurgitation.

DISCUSSION

Marfan syndrome is caused by mutations in the gene coding for fibrillin-1, which is a major component of extracellular microfibrils [4]. The revised Ghent criteria are the most recent nosology for the diagnosis of Marfan syndrome [5]. A specific combination of clinical features is required for a diagnosis of Marfan syndrome, including aortic dilation, ectopia lentis, distinguishing systemic characteristics, family history, and FBN1 mutation. Most cases of Marfan syndrome present in the teenage years or in early adulthood.

Infantile-onset Marfan syndrome is a rare phenotype of this disease with both genotypic and phenotypic differences com-

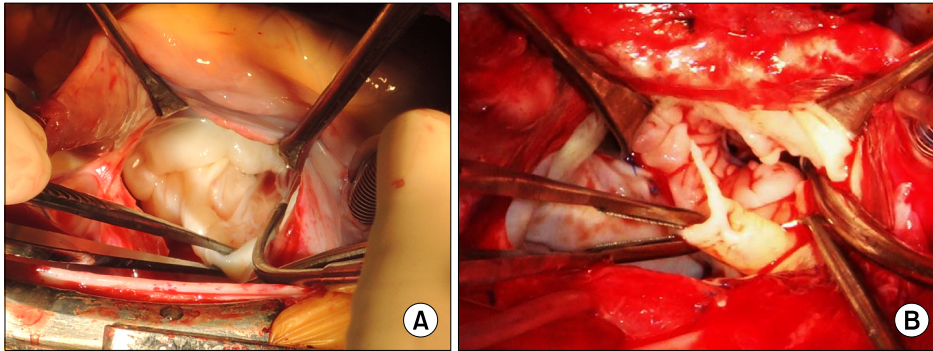


Fig. 1. Clinical pictures showing deformed mitral valves. (A) Patient 5 had severe mitral leaflet prolapse with diffuse chordae tendinae elongation. (B) During the reoperation of patient 3, myxomatous change of mitral leaflets and ruptured chordae tendinae could be observed.

pared to classical Marfan syndrome. Faivre et al. [6] reported that mutations in exons 24–31 are present in around 90% of Infantile-onset Marfan syndrome patients but in only 20% of classic cases. While aortic regurgitation is less frequent, other cardiac manifestations including mitral valve prolapse and mitral, tricuspid, and pulmonary regurgitations were more prevalent in infantile-onset Marfan syndrome.

The prognosis of infantile-onset Marfan syndrome is poor due to its association with severe cardiovascular manifestations. Geva et al. [7] reported nine infants with infantile-onset Marfan syndrome. All of these patients had mitral valve prolapse, leading to mitral regurgitation in eight. As well, all of these patients had tricuspid valve prolapse, with tricuspid regurgitation present in six. All had dilatation of the aortic root greater than two standard deviations above the norm for their age. Seven of the patients showed symptoms of congestive heart failure, and four died within the first year of life. While the main cause of death in classical Marfan syndrome patients is aortic dissection or rupture, infantile-onset Marfan syndrome patients die mostly from congestive heart failure associated with mitral and tricuspid regurgitation.

However, treatment options for infantile-onset Marfan syndrome are limited. Medical treatment often fails to delay the progression of valvular dysfunction or to control the symptoms of congestive heart failure. Compared to classical Marfan syndrome, these patients tend to require surgical management as early as infancy or early childhood. In our experience, four out of the six patients needed surgical management for mitral regurgitation before the age of five. Patients 3 and 6 had to undergo an emergency surgery at less than one year of age because of the rapid progression of heart failure.

Cameron [8] suggested several features that support the

feasibility of repair. Isolated dilatation of the annulus or dilatation associated with prolapse of only a portion of the posterior mitral leaflet is relatively easy to repair and has outcomes that are more favorable. However, valve repair is impossible or associated with poor durability when both leaflets are severely prolapsed or when several chordae tendinae are ruptured or markedly elongated, especially if they are inserted into the anterior mitral leaflet. This corresponds to our experience. Patient 1 showed severely elongated chordae tendinae with leaflet prolapse. Repair was initially attempted, but intraoperative transesophageal echocardiography confirmed moderate residual mitral regurgitation. Patient 5 showed severe leaflet prolapse with diffuse chordae tendinae elongation (Fig. 1). An attempt to repair the valve resulted in severe residual regurgitation with systolic anterior motion of the mitral valve on intraoperative transesophageal echocardiography. Consequently, valve replacement with mechanical prosthesis was performed in both patients. In patient 3, both mitral leaflets were dysplastic with diffuse severe prolapse. Although intraoperative transesophageal echocardiography showed only mild mitral regurgitation after the repair, it quickly became severe within two months.

Several reports have shown good results and durability of mitral valve repair in patients with classical Marfan syndrome. Fuzellier et al. [9] reported that 87.1% of 33 Marfan syndrome patients who underwent mitral valve repair for mitral valve regurgitation did not undergo reoperation within 10 years. Bhudia et al. [10] also reported excellent results with only one reoperation among 16 mitral valve repairs at 10 years. However, these patients were mostly adults, with a mean age of 30 and 38 years, respectively. Given the severity and rapid progression of valve dysfunction in infantile-onset

Marfan syndrome compared to classical Marfan syndrome, the durability of valve repair is questionable. In our experience, the two patients who underwent mitral valve repair were 140 and three months old at the time of the operation, respectively. While the mitral valve of the older patient (patient 2) retained good function over 15 years of follow up, the younger patient (patient 3) required a valve replacement after only two months. During the second operation on patient 3, we found elongation and rupture of the chordae tendinae along with degenerative changes around previous leaflet suture sites (Fig. 1). The different prognosis of these patients suggests that mitral valve repair is not necessarily durable in infantile-onset Marfan syndrome patients, especially in those who present with severe mitral regurgitation early in life. Therefore, valve replacement is preferable to valve repair for this group of patients.

Valve replacement in infants is associated with significant mortality and morbidity, including complete heart block, thrombosis, and stroke [10]. However, the long-term mortality is quite favorable despite the need of reoperation for second valve replacements and long-term anticoagulation therapy. Mitral valve replacement in infants or young children usually involves two considerations that optimize the long-term results. First, because of the substantial life expectancy of the patient, a mechanical prosthesis is preferable to tissue prosthesis. The second consideration relates to the optimal valve size. It is preferable to put in larger prosthetic valves in order to avoid the potential development of valve-patient mismatch resulting in reoperation as the child grows. Caldarone et al. [11] suggested that an increased valve size/body weight ratio is a predictor of increased early mortality associated with initial mitral valve replacement. While the one-year survival associated with a size/weight ratio of two is 91% (corresponding to a 16 mm prosthesis in an 8 kg infant), it drops significantly to 61% when the size/weight ratio is four. However, a large portion of these patients (74/139, 53.2%) had either complete atrioventricular canal defect or Shone's syndrome, which are associated with anatomic relationships that may account for higher mortality. In Marfan syndrome patients, the substantially dilated mitral annulus is usually large enough to fit in prosthetic valves with a large diameter without affecting the geometry of the heart. In our experi-

ence, patient 6 was the youngest and smallest, at nine months old and 7.6 kg at the time of operation. The patient's mitral annulus size was 35 mm and we had no problem placing a 23 mm prosthetic valve. Nevertheless, one has to be aware of the possibility of oversizing the mitral valve prosthesis.

In conclusion, mitral valve repair may not be feasible or durable in Marfan syndrome patients who require surgical management of mitral valve regurgitation during infancy or childhood. Although valve replacement in infants involves certain risks, our results suggest that mitral valve replacement with a mechanical prosthesis can be a good option for these patients. In addition, frequent follow-up is vital for determining the optimal timing of surgical management, in light of the rapid progressive nature of infantile-onset Marfan syndrome.

CONFLICT OF INTEREST

No potential conflict of interest relevant to this article was reported.

ACKNOWLEDGMENTS

This study was supported by a Grant of the Samsung Vein Clinic Network (Daejeon, Anyang, Cheongju, Cheonan) (Fund No. KTCS04-018).

REFERENCES

1. Silverman DI, Burton KJ, Gray J, et al. *Life expectancy in the Marfan syndrome*. Am J Cardiol 1995;75:157-60.
2. Pyeritz RE, Wappel MA. *Mitral valve dysfunction in the Marfan syndrome: clinical and echocardiographic study of prevalence and natural history*. Am J Med 1983;74:797-807.
3. De Paepe A, Devereux RB, Dietz HC, Hennekam RC, Pyeritz RE. *Revised diagnostic criteria for the Marfan syndrome*. Am J Med Genet 1996;62:417-26.
4. Kainulainen K, Pulkkinen L, Savolainen A, Kaitila I, Peltonen L. *Location on chromosome 15 of the gene defect causing Marfan syndrome*. N Engl J Med 1990;323:935-9.
5. Loeys BL, Dietz HC, Braverman AC, et al. *The revised Ghent nosology for the Marfan syndrome*. J Med Genet 2010;47:476-85.
6. Faivre L, Masurel-Paulet A, Collod-Beroud G, et al. *Clinical and molecular study of 320 children with Marfan syndrome and related type I fibrillinopathies in a series of 1009 pro-*

- bands with pathogenic FBN1 mutations. Pediatrics* 2009;123:391-8.
7. Geva T, Sanders SP, Diogenes MS, Rockenmacher S, Van Praagh R. *Two-dimensional and Doppler echocardiographic and pathologic characteristics of the infantile Marfan syndrome. Am J Cardiol* 1990;65:1230-7.
 8. Cameron DE. *Mitral valve surgery in children with the Marfan syndrome. Prog Pediatr Cardiol* 1996;5:205-10.
 9. Fuzellier JF, Chauvaud SM, Fornes P, et al. *Surgical management of mitral regurgitation associated with Marfan's syndrome. Ann Thorac Surg* 1998;66:68-72.
 10. Bhudia SK, Troughton R, Lam BK, et al. *Mitral valve surgery in the adult Marfan syndrome patient. Ann Thorac Surg* 2006;81:843-8.
 11. Caldarone CA, Raghuvver G, Hills CB, et al. *Long-term survival after mitral valve replacement in children aged <5 years: a multi-institutional study. Circulation* 2001;104(12 Suppl 1):I143-7.