

## LETTERS

DOI 10.1002/art.41702

### COVID-19 disease in patients with recurrent pericarditis during treatment with anakinra: comment on the article by Navarro-Millán et al

To the Editor:

We read with interest the article by Dr. Navarro-Millán and colleagues about the use of anakinra to prevent mechanical ventilation in patients with COVID-19 (1). However, it is also important to consider patients who develop COVID-19 while being treated with anakinra for their underlying condition (2).

We describe 5 patients, median age 43 years, with recurrent pericarditis (post-pericardiotomy in 1 case; idiopathic pericarditis in 4 cases) who developed COVID-19 disease during treatment with anakinra. Median duration of recurrent pericarditis was 48 months. All patients were being treated with anakinra when COVID-19 disease occurred, after having initially received treatment with glucocorticoids and/or nonsteroidal antiinflammatory drugs (including colchicine) (Table 1).

The patients developed COVID-19 disease between March 2020 and October 2020. Symptoms, usually mild, included fever, cough, ageusia, anosmia, headache, diarrhea, dyspnea, and chest pain (Table 1). SARS-CoV-2 was diagnosed by nasopharyngeal swab in 4 patients, and by serologic test in 1 patient, after symptoms began. Two patients went to the emergency room; in one case, chest radiograph showed a small lung infiltrate,

but neither of the patients required hospitalization. Treatment with anakinra was continued unchanged, and 3 patients received additional therapies after the development of COVID-19 disease (Table 1). All patients recovered completely within 15 days and had no recurrence of pericarditis.

Polytherapy is often necessary in patients with recurrent pericarditis and treatment with an interleukin-1 receptor antagonist may lead to resolution of symptoms (3); however, a concern may be raised that biologic therapy could aggravate the clinical course of COVID-19. Our small case series shows that anakinra therapy in patients with recurrent pericarditis may be associated with a benign clinical course. We propose that there is no reason to discontinue anakinra therapy if a patient with recurrent pericarditis develops COVID-19 disease (4–7). Our recommendation is consistent with the findings obtained in the study by Dr. Navarro-Millán et al (1).

*Dr. Brucato has received research support from Sobi and Acarpia. Dr. Imazio has received consulting fees or honoraria from Kiniksa and Sobi (less than \$10,000 each).*

Enrica Negro, MD   
Lucia Trotta, MD  
Massimo Pancrazi, MD  
Emanuele Bizzi, MD  
Martino Brenna, MD  
Fatebenefratelli Hospital  
Milan, Italy

**Table 1.** Summary of main features of patients\*

Patient/age/sex	Pericardial disease duration, months	Therapy when COVID-19 occurred	COVID-19 clinical features	Adjusted/additional therapies during COVID-19	Hospitalization or ER visit	Duration of COVID-19 symptoms, days
1/54/M	12	Anakinra (100 mg every 48 hours)	Fever; cough; infiltrate in right middle lobe on chest radiograph; CRP and D-dimer elevation	Azithromycin	ER visit	5
2/15/M	21	Anakinra (100 mg every 3 days); colchicine (1 mg/day)	Low-grade fever; asthenia	None	None	2
3/43/F	48	Anakinra (100 mg every 4 days); colchicine (1 mg/day)	Fever; cough for 4 days; ageusia; anosmia; diarrhea; headache	None	None	15
4/35/F	54	Anakinra (100 mg/day); colchicine (1.5 mg/day); nadolol	Dry cough; fever for 3 days; asthenia; diarrhea; chest pain; normal CRP	Prednisone (25 mg/day for 5 days) then 12.5 mg/day; indomethacin	ER visit	10
5/78/F	60	Anakinra (100 mg/day); colchicine (1 mg/day); prednisone (2.5 mg every 2 days)	Low-grade fever for 2 days; dyspnea	Prednisone (2.5 mg/day); acetaminophen; amoxicillin-clavulanic acid	None	15

\* ER = emergency room; CRP = C-reactive protein.

Vartan Mardigyan, MD  
 McGill University  
 and Jewish General Hospital  
 Montreal, Quebec, Canada  
 Massimo Imazio, MD   
 Azienda Ospedaliero Universitaria Città della Salute e della  
 Scienza di Torino  
 Turin, Italy  
 Antonio Brucato, MD   
 Università di Milano  
 and Fatebenefratelli Hospital  
 Milan, Italy

1. Navarro-Millán I, Sattui SE, Lakhanpal A, Zisa D, Siegel CH, Crow MK. Use of anakinra to prevent mechanical ventilation in severe COVID-19: a case series. *Arthritis Rheumatol* 2020;72:1990–7.
2. Imazio M, Brucato A, Lazaros G, Andreis A, Scarsi M, Klein A, et al. Anti-inflammatory therapies for pericardial diseases in the COVID-19 pandemic: safety and potentiality [review]. *J Cardiovasc Med (Hagerstown)* 2020;21:625–9.
3. Klein AL, Imazio M, Brucato A, Abbate A, Fang F, Insalaco A, et al. Phase 3 trial of interleukin-1 trap rilonacept in recurrent pericarditis. *N Engl J Med* 2020;2021;384:31–41.
4. Putman M, Chock YP, Tam H, Kim AH, Sattui SE, Berenbaum F, et al. Antirheumatic disease therapies for the treatment of COVID-19: a systematic review and meta-analysis. *Arthritis Rheumatol* 2021;73:36–47.
5. Chau AS, Weber AG, Maria NI, Narain S, Liu A, Hajizadeh N, et al. The longitudinal immune response to coronavirus disease 2019: chasing the cytokine storm [review]. *Arthritis Rheumatol* 2021; 73:23–35.
6. Scarsi M, Piantoni S, Colombo E, Airó P, Richini D, Miclini M, et al. Association between treatment with colchicine and improved survival in a single-centre cohort of adult hospitalised patients with COVID-19 pneumonia and acute respiratory distress syndrome. *Ann Rheum Dis* 2020;79:1286–9.
7. Aomar-Millán A, Salvatierra J, Torres-Parejo Ú, Faro-Miguez N, Callejas-Rubio JL, Ceballos-Torres Á, et al. Anakinra after treatment with corticosteroids alone or with tocilizumab in patients with severe COVID-19 pneumonia and moderate hyperinflammation: a retrospective cohort study. *Intern Emerg Med* 2021;16:843–52.

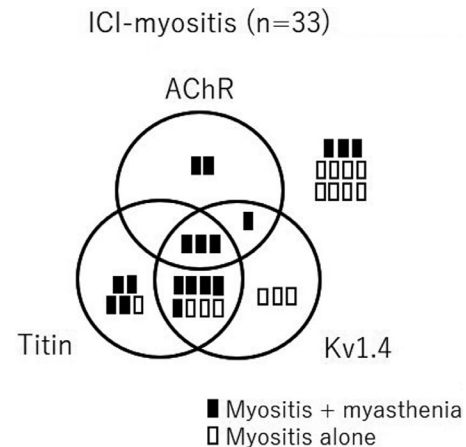
DOI 10.1002/art.41713

### Significance of antistriational antibodies for immune checkpoint inhibitor-related myositis: comment on the article by Aldrich et al

To the Editor:

In their recent study, Dr. Aldrich and colleagues clearly described the clinical features of immune checkpoint inhibitor-related myositis (ICI-myositis) differentiated according to the presence or absence of myasthenia gravis (MG) (1). From the viewpoint of a neurologist, I emphasize that making a diagnosis of MG that has occurred as an immune-related adverse event is difficult when anti-acetylcholine receptor (anti-AChR) antibodies are undetectable.

First, MG is characterized by the fluctuation of muscle weakness and easy fatigability. Since disease progression is relatively rapid, fluctuation is observed less frequently in patients with ICI-related MG than in those with idiopathic MG. In addition, since cancer patients frequently experience fatigue, it is difficult to evaluate whether easy



**Figure 1.** Schema showing the distribution of patients with immune checkpoint inhibitor-related myositis (ICI-myositis) with or without myasthenia, stratified according to the presence of or combinations of anti-acetylcholine receptor (AChR), anti-titin, and anti-Kv1.4 antibodies.

fatigability is present. Second, interpretation of the results of edrophonium tests can be controversial. It is unlikely that there would be a notable response to cholinesterase inhibitors in patients with ICI-related MG. Likewise, the results of an ice pack test showing improvement of ptosis are not conclusive. Third, a decreased response on the repetitive nerve stimulation test indicating increased muscle fatigue and weakness is demonstrated in limited cases of ICI-related MG. Assessing the jitter phenomenon using single-fiber electromyography is the most sensitive method for showing impairment of neuromuscular transmission. However, the number of facilities in which this method can be performed is limited. Fourth, titers of anti-AChR antibodies tend to be borderline, and therefore are equivocal for determining antibody status in patients with ICI-related MG compared to those with idiopathic MG (2). Neurologists may hesitate to conclude that a patient is positive for anti-AChR antibodies.

Aldrich and colleagues found that testing antistriational antibodies was useful for diagnosing ICI-myositis (1). My group also examined 33 Japanese patients with ICI-myositis who were referred for autoantibody detection between 2016 and 2020 (3). Consulting neurologists diagnosed concomitant MG in 18 (55%) of these patients. The autoantibody test results showed that 6 patients (18%) were positive for anti-AChR antibodies (Figure 1). Using cytometric cell-based assays, anti-titin and anti-Kv1.4 antibodies were detected in 16 patients (48%) and 15 patients (45%), respectively (4). Among 33 patients with ICI-myositis, 20 (61%) had at least 1 antistriational antibody.

The standard method for detecting antistriational antibodies is indirect immunofluorescence of skeletal muscle tissue. Aldrich and colleagues observed seropositivity in 11 (46%) of 24 patients (1). Although the cytometric cell-based assays are only available in Japan, they have better sensitivity and specificity than conventional detection methods. A limitation of these assays is that autoantibodies to other muscle proteins, such as ryanodine