



Functional and structural connectivity of the amygdala in obsessive-compulsive disorder



Oana Georgiana Rus^{a,b,d,*}, Tim Jonas Reess^{a,b,d}, Gerd Wagner^e, Claus Zimmer^a, Michael Zaudig^c, Kathrin Koch^{a,b,d}

^aDepartment of Neuroradiology, Klinikum rechts der Isar, Technische Universität München, Ismaningerstrasse 22, 81675 Munich, Germany

^bTUM-Neuroimaging Center (TUM-NIC) of Klinikum rechts der Isar, Technische Universität München TUM, Ismaninger Strasse 22, 81675 Munich, Germany

^cWindach Institute and Hospital of Neurobehavioural Research and Therapy (WINTR), Windach, Schützenstraße 100, 86949 Windach, Germany

^dGraduate School of Systemic Neurosciences GSN, Ludwig-Maximilians-Universität, Biocenter, Großhaderner Strasse 2, 82152 Munich, Germany

^eDepartment of Psychiatry and Psychotherapy, Jena University Hospital, Philosophenweg 3, 07743 Jena, Germany

ARTICLE INFO

Article history:

Received 25 July 2016

Received in revised form 4 December 2016

Accepted 8 December 2016

Available online 10 December 2016

Keywords:

Obsessive-compulsive disorder

OCD

Functional connectivity

Structural connectivity

DTI

gPPI

ABSTRACT

Background: The amygdala is known to be involved in anxiety processing, but its role in the psychopathology of obsessive-compulsive disorder (OCD) is still unclear.

Aims: In this MRI study we investigated potential alterations in structural and functional connectivity of the amygdala in 42 adult patients with OCD and 37 healthy subjects.

Method: Psychophysiological interaction analysis was used to explore amygdala functional connectivity during a negative affective task. Probabilistic tractography was then employed to study structural connectivity and integrity of underlying white matter fiber tracts.

Results: Compared to controls, OCD patients showed a significantly increased functional connectivity of the left amygdala with mostly parieto-occipital regions during task. No structural connectivity differences could be found between the groups. In addition, only patients showed a significant association between functional and structural connectivity of these regions. Moreover, symptom severity was negatively associated with structural integrity of the underlying white matter tracts.

Conclusions: Present results emphasize the relevance of the amygdala for OCD and may reflect that neuronal alterations in structural connectivity could be associated with functional connectivity alterations in broader networks.

© 2016 The Authors. Published by Elsevier Inc. This is an open access article under the CC BY-NC-ND license (<http://creativecommons.org/licenses/by-nc-nd/4.0/>).

1. Introduction

Obsessive-compulsive disorder (OCD) is a psychiatric illness characterized by repetitive thoughts (i.e., obsessions) and actions (i.e., compulsions). It is a rather common disorder with a lifetime prevalence of 2.3% (Ruscio et al., 2010). The neurobiological model of the disorder states a disrupted cortico-striato-thalamo-cortical circuit (CSTC) (Saxena et al., 1998). More recent work discussed an extension of this model by limbic structures including the amygdala, anterior cingulate, and hippocampus (Lawrence et al., 1998; Menzies et al., 2008; Phillips et al., 2003). Since the manifestation of obsessions and compulsions is

usually accompanied by strong negative affect, such as anxiety, and the amygdala is a region known to mediate anxiety (Milad and Rauch, 2012), a pathogenetic involvement of limbic regions (i.e., predominantly the amygdala) in the disorder is very plausible. However, their exact role in the pathophysiology of OCD remains to be clarified.

Accordingly, fMRI studies using the method of symptom provocation by confronting patients with symptom related picture material provided support for the assumption that the amygdala is a key structure in anxiety disorders in general as well as across OCD symptom dimensions (Breiter et al., 1996; Olatunji et al., 2013; Simon et al., 2014; Simon et al., 2010; Via et al., 2014). Most of these studies reported hyperactivity of the amygdala during symptom provocation. This hyperactivity was found in medicated (Olatunji et al., 2013), as well as unmedicated patients (Simon et al., 2014; Simon et al., 2010), but also in symptom specific populations with predominant contamination fears (Mataix-Cols et al., 2004; Olatunji et al., 2014; van den Heuvel et al., 2004), as well as in multi-symptomatic patients (Simon et al., 2014).

Apart from evidence for alterations in activation in patients with OCD an increasing amount of studies provided evidence for alterations

Abbreviations: restFC, resting state functional connectivity; taskFC, task dependent functional connectivity; SC, structural connectivity; WM tract, white matter tract; probFT, probabilistic fiber tracking.

* Corresponding author at: Department of Neuroradiology, Klinikum rechts der Isar, Technische Universität München, Ismaningerstrasse 22, 81675 Munich, Germany.

E-mail addresses: georgiana.rus@tum.de (O.G. Rus), tim.reess@tum.de (T.J. Reess), wagner.gerd@uni-jena.de (G. Wagner), claus.zimmer@tum.de (C. Zimmer), m.zaudig@klinik-windach.de (M. Zaudig), kathrin.koch@tum.de (K. Koch).

in task dependent functional connectivity (taskFC). Several studies evaluated taskFC in OCD in various contexts (such as, e.g., reinforcement learning (Beucke et al., 2012), working memory (de Vries et al., 2014) or reward processing (Jung et al., 2013)) and brought evidence for disturbances in a network involving the CSTC, orbitofrontal regions (OFC) but also limbic structures. Surprisingly, only few OCD studies explored taskFC using symptom-provoking paradigms based on negative affective stimuli. Findings from these studies showed taskFC disruptions in OCD patients, also mainly in striatal and limbic regions (Jhung et al., 2014), with the latter showing connectivity disruptions in OCD also during rest (Anticevic et al., 2014; Beucke et al., 2013; Gottlich et al., 2014; Harrison et al., 2009). Moreover, alterations in limbic (i.e., amygdala) resting state functional connectivity (restFC) were found to be positively associated with response to treatment (i.e., CBT), underlining the potential relevance of limbic/amygdala disturbances for therapy outcome (Gottlich et al., 2015).

When viewing the previous findings from a network point of view, it seems reasonable to assume that disruptions in the functional circuitry of the brain may go along with underlying structural alterations. Most of the relevant OCD studies bring evidence for whole brain structural alterations in areas within the CSTC but also outside of this circuit (i.e., in temporal, parietal and occipital areas) (Piras et al., 2015). A recent meta-analysis on structural connectivity studies in OCD pointed out that findings are rather heterogeneous, although most studies reported decreased fractional anisotropy (FA) in OCD patients in the cingulate bundle, the corpus callosum, and the anterior limb of the internal capsule (Koch et al., 2014). Moreover, fronto-basal pathways targeting the orbitofrontal cortex and the anterior cingulate cortex are reported while intra-hemispheric white matter bundles linking specific areas of the prefrontal cortex to posterior parietal and occipital association cortices have also repeatedly been found to be altered in OCD (Piras et al., 2013).

In sum, existing MRI studies investigating functional activation, functional connectivity or structural connectivity, suggest with some consistency that OCD may be characterized by network alterations which are not restricted to the frequently reported cortico-striatal circuit but which affect, amongst others, also the limbic network. Moreover, previous findings indicate that these alterations might be linked and therefore their altered interplay might be of psychopathological relevance.

Surprisingly, there are only few studies analyzing the link between functional and structural neural correlates in OCD. One of the few studies exploring both structure and function in OCD was a study by Admon et al. (2012). Using a gambling task, they showed a deficit in limbic-frontal connectivity both on a functional and a structural level which was associated with the severity of OCD symptoms. Of note, they also found increased amygdala activation to threat stimuli. Despite increasing support of altered functional or structural alterations in a widespread network including cortico-striatal but also limbic/amygdalar areas in OCD, most studies focused on either functional or structural connectivity, whereas a potential association between both measures has been barely investigated up to know.

Against this background and taking into account the relevance of the amygdala for anxiety in OCD, the aim of the present study was to evaluate potential alterations in functional connectivity of the amygdala using a negative affective paradigm. Moreover, we aimed at investigating a potential association with structural connectivity (SC) properties of underlying white matter fiber tracts and with symptom severity to find out more about the clinical relevance of these potential alterations.

Based on the assumption that structural connectivity alterations may underlie functional connectivity changes, we hypothesized that during exposure to negative affective stimuli, OCD patients would show a significantly increased task dependent functional connectivity of the amygdala and that this altered functional connectivity would be related to alterations in morphological properties of underlying white matter fiber tracts (integrity, connectivity, number of tracts).

2. Methods

2.1. Participants

The study included a right-handed sample of 42 OCD patients and 37 healthy controls matched for age and gender (Table 1 in Appendix A).

Handedness was assessed using Annett's questionnaire (Annett, 1970). Exclusion criteria for both groups were a history of clinically important head injuries, seizures or neurological diseases. Healthy controls with a history of psychiatric illness were excluded.

The patients were recruited from the in-patient hospital ward specialized on OCD of the Windach Institute and Hospital of Neurobehavioural Research and Therapy, Germany. This ward has a standardized admission process where all patients receive a psychopathological screening and a disorder history assessment performed by an experienced psychiatrist. The final diagnosis is based on DSM-IV criteria. Prior to the scanning session, we additionally assessed the severity of symptoms and the characteristics of the disorder using the Yale-Brown Obsessive Compulsive Scale (Y-BOCS) (Goodman et al., 1989) and the Obsessive-Compulsive Inventory – Revised (OCI-R) (Foa et al., 2002). Patients also completed the Beck Depression Inventory (BDI) (Beck et al., 1961) which measures characteristic attitudes and symptoms of depression. All participants completed a disgust sensitivity questionnaire (Fragebogen zur Erfassung der Ekelempfindlichkeit, FEE) (Schienle et al., 2002). We also included patients with medication and comorbidities, provided that OCD was the primary diagnosis.

All participants gave written informed consent to the study protocol. The protocol is in accordance with the Declaration of Helsinki and was approved by the Ethics Committee of the Technische Universität München, Medical School.

2.2. Experimental design

All participants underwent one MRI scanning session including a structural (T1), a diffusion tensor imaging (DTI) and a functional (fMRI) scan. Participants were informed about the order of the scans and instructed that in the fMRI scan they would see alternating blocks of neutral and unpleasant pictures which they had to attend to.

The negative affective blocks consisted of pictures with OCD relevant content carefully selected from the International Affective Picture System (IAPS) and the internet and included scenes or objects related to disgust or contamination. Previous work (Simon et al., 2014) has shown that the presentation of contamination related picture material is a highly effective method for evoking amygdala activation in OCD. Based on this motivation we chose picture material with a clear contamination related content.

The neutral blocks consisted of pictures from nature or landscapes which served as a baseline. Before each block the participants were instructed to watch the pictures carefully. To evaluate the compliance to the instruction, all participants were debriefed after the scanning with regard to the potential impact of these pictures (e.g. arousal, unpleasantness). The fMRI task was created using the Presentation® software (Version 16.3, <http://www.neurobs.com/>). The task which was modeled as a block design had the following sequence: instruction (4 s), negative affective block (4 pictures shown for 6 s each), fixation cross (4 s) followed again by instruction (4 s), neutral block (3 pictures shown for 6 s each). In total, 16 blocks of pictures (8 negative affective and 8 neutral blocks) were presented resulting in a total task duration of about 7 min.

2.3. Image acquisition

Data were collected on a Philips Ingenia 3.0 T whole body system equipped with a 12-element receive-only head matrix coil. Foam pads were used to position and immobilize the subject's head within the coil.

2.3.1. High resolution imaging

High-resolution anatomical T1-weighted scans were obtained using a magnetization-prepared rapid acquisition gradient echo (MPRAGE) sequence with the following scanning parameters: repetition time (TR) = 9 ms, echo time (TE) = 4 ms, inversion time = 1000 ms, flip angle = 8°, field of view (FOV) = 240 × 240 × 170 mm, matrix size = 240 × 240, number of slices = 170, acceleration factor (SENSE) = 2 with an isotropic resolution of 1 × 1 × 1 mm³.

2.3.2. Functional imaging

T₂* weighted images were obtained using echo-planar imaging (EPI) with the following parameters: TR = 2.0 ms, TE = 30 ms, flip angle = 90°, FOV = 192 × 192 × 122 mm, matrix size = 64 × 64. We acquired 37 transverse slices with 3.0 mm thickness, covering the entire brain with a resolution of 3 × 3 × 3 mm. A series of 224 whole-brain volumes were recorded, with the first three images of each series being discarded.

2.3.3. Diffusion Tensor Imaging

Diffusion tensor images were acquired using an EPI sequence with the following parameters: TR = 9000 ms, TE = 57 ms, flip angle = 90°, FOV = 224 × 224 × 120 mm, in-plane resolution = 2 mm², slice thickness = 2 mm, number of slices = 60, matrix size = 112 × 112, SENSE = 2. Diffusion-sensitizing gradient encoding was applied in 32 directions with a diffusion-weighted factor of b = 1000 s/mm² and two b₀ (b = 0) images. Images were acquired parallel to the anterior-posterior commissure.

2.4. Data analysis

The single analysis steps were based on each other, meaning that the functional data analysis was based on the task activation maps, and the structural data analysis was based on the results from the functional data analysis.

2.4.1. Functional data

Preprocessing and statistical analysis of the fMRI data was performed using SPM8 (<http://www.fil.ion.ucl.ac.uk/spm>) data were corrected for differences in time of acquisition by sinc interpolation, realigned to the mean image of the session and linearly and non-linearly normalized to the Montreal Neurological Institute (MNI, Montreal, Canada) reference brain (MNI 152). Data were spatially smoothed with a Gaussian kernel (8 mm, full-width at half-maximum) and high-pass filtered with a 128 s cut-off. All data were inspected for movement artifacts. Three healthy controls and one patient with movement parameters exceeding 3 mm translation on the x-, y-, or z-axis or 3° rotation were excluded, resulting in a final study sample of 79 participants. In addition, individual movement parameters entered analyses as covariates of no interest.

On the first level, brain activations were then analyzed voxel-wise to calculate statistical parametric maps of t-statistics for the negative affective compared to neutral pictures condition.

Blood oxygenation level dependent (BOLD) signal changes for the different conditions were modeled as a covariate of variable length box-car functions and convolved with a canonical hemodynamic response function (HRF). These HRFs were then used as individual regressors within the general linear model (GLM).

To investigate taskFC of the amygdala functional imaging data were then analyzed using the generalized form of context-dependent psychophysiological interaction (gPPI) (McLaren et al., 2012) analysis implemented as gPPIv13 toolbox in SPM8.

2.4.1.1. Task dependent functional connectivity. We used the gPPI analysis to investigate potential alterations in taskFC between each of the two seed ROIs – left and right amygdala – and the rest of the brain. Amygdala

seed ROIs were identified based on the peak activation from the second-level analysis (i.e., negative affective vs. neutral images, one-sample t-test with a familywise error correction (FWE) $p < 0.0001$ at a voxel level). In patients seed ROIs were left amygdala with activation maximum: $x = -22$, $y = -4$, $z = -18$, ROI size = 275 voxels and right amygdala with activation maximum: $x = 26$, $y = -6$, $z = -16$, ROI size = 146 voxels. In healthy controls seed ROIs were left amygdala with activation maximum: $x = -20$, $y = -4$, $z = -22$, ROI size = 110 voxels and right amygdala with activation maximum: $x = 26$, $y = -2$, $z = -20$, ROI size = 83 voxels. In order to get the common amygdala activation seed (i.e., those amygdala voxels which were activated in both groups) we overlapped the amygdala clusters from both groups using the SPM toolbox MarsBaR 0.21 (Brett et al., 2002) and used the intersection (left amygdala: $x = -23.1$, $y = -5.2$, $z = -18.8$, ROI size = 102 voxels; right amygdala: $x = 24.3$, $y = -3.6$, $z = -18.4$, ROI size = 67 voxels) as seed ROIs for both patients and controls for further gPPI analyses (see Fig. 1, left section in Appendix A).

Next, we extracted the individual time series from the common amygdala ROI clusters (left and right) for each participant. These time series constituted the physiological component of the gPPI, which is based on bilinear interaction terms. The contrast between the two conditions of the fMRI-task “negative affective vs. neutral pictures” constituted the psychological component. The interaction between the two previously defined components was used as a gPPI regressor in the analysis. Thus, a significant activation of a certain area reflects increased taskFC with the seed ROI (i.e., left/right amygdala) during “negative affective vs. neutral pictures”.

To illustrate the regions functionally connected with the amygdala ROIs in each group we computed a one-sample t-test. To compare connectivity between the groups we used a two-sample t-test with a false discovery rate correction (FDR) $p < 0.05$ at a voxel level. The expected number of voxels per cluster was used as an extent threshold.

2.4.2. Structural data

Diffusion tensor imaging (DTI) data analysis was performed using FSL (FMRIB Software Library, FMRIB, Oxford, UK) software package, more specifically the FMRIB's Diffusion Toolbox – FDT v2.0 toolbox from FSL (Behrens et al., 2007). First, data were corrected for the effects of head movement and eddy currents. After creating a brain mask the diffusion tensor model fit was performed to create individual fractional anisotropy (FA) and mean diffusivity (MD). We used FA and MD maps in the further analysis of probabilistic fiber tracking (probFT). DTI data were further analyzed using probFT, a method which allows to delineate white matter fiber tracts (WM tracts) in the brain between predefined ROIs, while counting in the expected uncertainty into the tracking algorithm, and to produce a connectivity distribution value for each voxel (Behrens et al., 2007).

2.4.2.1. Structural connectivity. After identifying the regions showing an altered taskFC with the amygdala in OCD we then proceeded with exploring potential alterations in SC between those regions showing an altered FC in patients. To this aim we performed a probFT analysis. This analysis requires a seed region, i.e., the left amygdala, which showed a significantly altered taskFC with a left parieto-occipital region in OCD (see results section). This latter region constituted the target ROI (i.e., largest cluster in the left hemisphere, see results section) for the probFT analysis. Moreover, for the probFT analysis prior knowledge about WM tract anatomy should be taken into account. According to Catani and de Schotten (2012) a potential WM tract connecting the amygdala with these occipital regions could be the inferior longitudinal fasciculus (ILF). As there were no significant group differences in taskFC for the right amygdala (see results section), SC analyses were restricted to the left amygdala.

We analyzed two characteristics for SC, the number of WM tracts connecting the amygdala ROI with the target region, and the average

connectivity distribution values of the WM tracts connecting the seed and the target region.

Next, we ran the preparatory steps for probFT using the FDT integrated function of Bayesian estimation of diffusion parameters obtained using sampling techniques (bedpostX). This step estimates the individual diffusion parameters at each voxel and automatically takes into account the number of crossing fibers per voxel. We used the default parameters implemented in FDT: 2 fibers per voxel, weight 1, burning period 1000. Subsequently, we used the previously computed diffusion parameters to run the tractography analysis using the FDT integrated function *protrackx2*. As a seed mask we applied the amygdala ROI from the previous gPPI analysis and as a target region the parieto-occipital cluster, using the option “waypointmask” implemented in *protrackx2*. Both masks were previously converted to the individual diffusion space. This analysis step generates connectivity distributions from the specified seed voxels.

For the tracking algorithm we used the default parameters: 5000 samples per voxel, path length of 2000×0.5 mm steps, curvature threshold of 80° and loop checking criteria enabled.

The result is a single image per participant (*fdt_paths*) visualizing the WM tracts connecting seed and target region, where each voxel value represents the connectivity distribution value between that voxel and the seed voxel (i.e., from the amygdala seed region). Another individual output is the total number of generated WM tracts (*waytotal*) between the amygdala and the target region. To extract the average SC distribution value, i.e., the connectivity distribution values of the obtained WM tracts, we normalized the output image from the probFT step, by dividing the individual WM tracts image by the individual number of generated WM tracts (Arnold et al., 2012; Zhang et al., 2010). The normalization is necessary because of the high intersubject variability in terms of individual number of generated WM tracts, which was also due to the fact that probFT analysis is usually processed in the individual diffusion space of each participant.

2.4.2.2. Structural integrity. In order to additionally assess the structural integrity of the WM tracts connecting the seed region (i.e., left amygdala) with the target region (i.e., parieto-occipital cluster) we extracted FA and MD of these fiber tracts for both patients and controls. To this end, we multiplied the binarized individual WM tract images from the probFT analysis with the individual FA and MD images from the DTI data analysis. From the WM tracts of the resulting image we extracted the individual average FA and MD.

2.4.3. Statistical analysis

Statistical analyses were conducted using SPSS Inc. (2002) (SPSS 11.5.1., Chicago) and MATLAB and the Statistics Toolbox (Release 2013a, The MathWorks, Inc., Natick, Massachusetts, United States).

To explore potential group differences in SC (i.e., number of WM tracts, average connectivity distribution values of WM tracts) and integrity (i.e., FA and MD) two-sided Bonferroni corrected parametric tests were used.

Pearson's correlation analyses were conducted to investigate potential associations between taskFC (i.e., betas of gPPI connectivity map results) and SC measures as well as between taskFC and structural integrity measures in each group. Finally, all functional and structural measures were correlated with symptom severity (i.e., Y-BOCS total scores).

A two-sided parametric test was performed to analyze the difference in disgust sensitivity score between the groups. To investigate whether disgust sensitivity was associated with the taskFC we performed a Pearson correlation.

To control for the possible effect of comorbidity on the present results we also investigated a potential correlation between the above mentioned functional and structural connectivity measures and the depression score (BDI total score).

To explore if medication affected taskFC or SC differences between patients and controls, we furthermore performed an ANCOVA with taskFC or SC parameters as dependent variables, medication status as independent variable, and age and gender as covariates.

3. Results

3.1. Task dependent activation

OCD patients showed an increased activation during the task mainly in middle occipital gyrus, amygdala, precentral and inferior frontal regions. The control group showed a significantly increased activation during the task in similar brain areas, i.e., mainly in inferior occipital, inferior frontal and amygdala (for more details see Tables 4, 5 and Fig. 2 in Supplement). No significant group difference in activation during the task could be found.

3.2. Task dependent functional connectivity

OCD patients had a significantly increased taskFC of the left amygdala to a network comprising bilateral occipital, parietal and temporal areas (Table 2, Fig. 1, middle section in Appendix A), as well as a significantly increased taskFC of the right amygdala and a network comprising mainly occipital areas (Table 2, Fig. 1, middle section in Appendix A). No significant amygdala taskFC could be found in the control group.

The between group gPPI analysis yielded a significantly increased taskFC in OCD patients between the left amygdala and mostly left-lateralized occipital, parietal, temporal and frontal areas, as well as right parietal, occipital, thalamus areas and bilateral cerebellar areas (Table 3, Fig. 1, middle section in Appendix A). The right amygdala showed no significant differences in taskFC between the groups.

3.3. Structural connectivity

There was no significant group difference in number of WM tracts (mean patients: 2386.64, SD = 4810.43, mean controls: 4249.08, SD = 9360.36, $t = 1.13$, $p = 0.26$) connecting the left amygdala with the left parieto-occipital cluster. There was also no significant group difference in connectivity distribution values of the WM tracts (mean patients: 0.02, SD = 0.02, mean controls: 0.03, SD = 0.04, $t = -1.41$, $p = 0.16$).

3.4. Structural integrity

There were no significant between group differences in FA or MD (FA patients: 0.3418, SD = 0.0235, FA controls: 0.3427, SD = 0.0241, $t = 0.15$, $p = 0.88$; MD patients: 9.0260×10^{-4} , SD = 4.4107×10^{-5} , MD controls: 9.0208×10^{-4} , SD = 4.2405×10^{-5} , $t = -0.05$, $p = 0.96$).

3.5. Associations of brain function, structure and symptom severity

3.5.1. Functional and structural connectivity

In OCD patients, a significant positive correlation between taskFC and connectivity distribution values of the WM tracts was found ($r = 0.32$, $p = 0.04$). No significant association between taskFC and SC could be found in controls. There was no significant association between taskFC and the number of white matter fiber tracts in none of the groups.

3.5.2. Functional connectivity and structural integrity

There was no significant correlation between taskFC and structural integrity measures neither in patients nor in controls (patients: gPPI betas and FA $r = 0.15$, $p = 0.35$, gPPI betas and MD $r = -0.23$, $p = 0.15$; controls: gPPI betas and FA $r = -0.24$, $p = 0.15$, gPPI betas and MD $r = 0.09$, $p = 0.60$).

3.5.3. Connectivity and symptoms

There was a significant negative association between symptom severity (Y-BOCS total) and structural integrity (FA) in OCD patients ($r = -0.33$, $p = 0.04$). There was no significant association between the symptom severity score (Y-BOCS total) and taskFC or SC, the same applied to the correlation between depression score (BDI total) and taskFC or SC in OCD patients.

3.6. Effect of medication

We found that medication status of the patients affected the taskFC group difference ($F = 14.07$, $p < 0.01$), i.e., medicated patients showed a significantly higher taskFC in the parieto-occipital cluster than controls (post hoc t-test: medicated patients ($N = 27$): mean = 0.38, SD = 0.35, controls ($N = 37$): mean = -0.08 , SD = 0.37, $t = 4.95$, $p < 0.01$), as well as compared to unmedicated patients (unmedicated patients ($N = 15$): mean = 0.11, SD = 0.18, $t = -2.75$, $p = 0.01$).

3.7. Disgust sensitivity

Patients had a significantly increased disgust sensitivity score compared to controls (patients ($N = 42$): mean = 2.43, SD = 0.55, controls ($N = 37$): mean = 2.01, SD = 0.61, $t = 3.22$, $p = 0.002$). No association between disgust sensitivity and taskFC could be found in OCD patients.

4. Discussion

The aim of the present study was to investigate if amygdala shows taskFC disturbances in patients with OCD during attendance to negative affective stimuli and to evaluate if these functional disturbances are linked to alterations in structural properties (connectivity and integrity) of underlying WM tracts. As a main finding, our study demonstrated that OCD patients showed a significantly increased left-lateralized taskFC from the left amygdala to the parieto-occipital cortex and that this increased functional connectivity was positively associated with the structural connectivity (SC distribution values) of the underlying WM tracts. In addition, the structural integrity of these WM tracts was negatively correlated with symptom severity (i.e., an increase in symptom severity was associated with a decrease in structural integrity of WM tracts FA).

4.1. Task dependent functional connectivity

More specifically, the significantly increased left amygdala taskFC to the parieto-occipital cortex during exposure to negative affective stimuli suggests a stronger interplay in patients between a core limbic area (i.e., the amygdala), which is predominantly responsible for emotional processing, and a network known to be responsible mainly for attention and visual processing (Goncalves et al., 2010).

Previous studies in healthy subjects showed that the presentation of emotional content goes along not only with increased activation in “classical” emotion related regions such as the amygdala and inferior-temporal areas but also with an increased activation in extra-striate and ventral stream visual areas (Wendt et al., 2011). Our study results reveal that in OCD the functional coupling between these regions seems to be altered when attending to stimuli with a negative valence. As OCD patients reported also a significantly increased disgust sensitivity a more sensible and affective perception of these mainly contamination related stimuli may be one mechanism underlying this increased functional coupling between emotional and visual processing areas. Thus, we speculate that in OCD both the affective perception as well as the visual processing of these specific stimuli might be altered.

Furthermore, regarding the psychopathological importance of these areas found to be hyperconnected in OCD, a review by Menzies et al. (2008) pointed out the need to consider the relevance of these posterior brain regions in the pathogenesis of the disorder. Study results of

Olatusji et al. (2013) support this, by showing that visual areas might play a central role in the mechanisms of emotional processing, especially during symptom provocation, in OCD.

The finding that patients showed a rather normal neural activation similar to healthy subjects during task along with an altered functional coupling could indicate that although the processing of anxiety partly taking place in the amygdala might not be disturbed, the “communication” with visual areas might be more intense in patients, possibly going along with higher stimulus attendance and a more intensive sensation of negative stimulus valence.

Accordingly, previous studies likewise showed alterations in visual attention in OCD, such as problems with disengaging attention from salient stimuli (Cisler and Olatusji, 2010) or processing abnormalities when OCD-relevant material had to be visualized (Moritz et al., 2009). Overall, these findings together with our results speak in favor of the idea that OCD patients may have a certain attentional bias, more specifically in the processing and attribution of emotional valence, towards disorder relevant stimuli.

Moreover, present findings of a subcortical-cortical hyperconnectivity confirm results of a review by Diniz et al. (2012) who concluded that besides neural disruptions comparable to those in other anxiety disorders, OCD patients seem to be affected by additional alterations within the amygdalo-cortical circuitry, which plays a major role in processes of fear conditioning and extinction. Our results complement this by showing that dysfunctions within these networks are visible already during the perception and processing of negative, fear-provoking stimuli. Future studies should investigate this aspect in more detail.

Regarding the role of the amygdala it has been shown that the amygdala is more strongly involved in the processing of immediate fear while other areas such as the insula are more relevant for the processing of potential threats (Fiddick, 2011). Considering that exactly these anxiety-associated regions showed altered functional connectivity while patients were perceiving pictures with negative affective content emphasizes the necessity to more strongly focus on exploring neural activity in OCD during exposition to feared objects or situations.

Several attempts have been made to identify symptom specific neural patterns in OCD (Mataix-Cols and van den Heuvel, 2006; Mataix-Cols et al., 2004; van den Heuvel et al., 2009). It is therefore a valid question if the present results represent a general or symptom specific pattern of OCD psychopathology.

Interestingly, a recent study by Simon et al. (2014) showed that amygdala hyperactivation during symptom provocation was present across different OCD symptom dimensions and suggested that it might constitute a common correlate which links OCD to other anxiety disorders. Our findings complement and support this assumption by giving insights into the functional coupling of this same region and by showing that, although a multi-symptomatic group was exposed to negative affective (mainly contamination related) stimuli, alterations in amygdala function were still present. Thus, present findings indicate that limbic areas might be involved in a more general rather than a symptom specific neural mechanism of the disorder.

4.2. Left lateralized connectivity

It is noteworthy that only left amygdala showed a between group taskFC connectivity difference. This finding is in accordance with other studies reporting an asymmetry in OCD patients, both structurally (Cannistraro et al., 2007) as well as functionally (Simon et al., 2014). Interestingly, this lateralization was also often reported in animal models of OCD (Ahmari et al., 2013) or in transcranial magnetic stimulation (TMS) studies with treatment resistant OCD patients (Mondino et al., 2015), where a left-lateralized stimulation seemed to be more effective than stimulation of the right side.

According to Phelps et al. (2001) there is a left-hemispheric amygdala engagement when the emotional property of a stimulus is cognitively learned, while there tends to be right-sided amygdala response when

the emotional property of the stimulus is obvious and visual (e.g., in the case of generally aversive, threatening stimuli). Moreover, the authors speculate that the difference in laterality of amygdala activation may be dependent on the modality in which the stimulus is represented (visual, verbal, obvious etc.) and its elaboration and interpretation by the subject. In our study, all subjects received the same negative affective visual stimuli with a mostly contamination related content, but with no direct threat component, with the instruction to carefully attend to these stimuli. As a consequence, an increased coupling between left amygdala and visual areas could be observed. Moreover, the OCD symptomatic model shows that OCD symptoms are mostly based on learned negative attribution to specific stimuli, which evoke anxiety and then lead to obsessions and repetitive behaviors (compulsions) to reduce anxiety.

Against this background and in light of Phelps et al. (2001) conclusions there is reason to speculate that this increased left amygdala connectivity in OCD might reflect the fact that patients generally attribute higher emotional valence to these stimuli than controls. In other terms, stimuli might be emotionally overvalued and interpreted in relation to personal obsessions or compulsions.

4.3. Structural connectivity

Interestingly, despite the significantly increased taskFC in patients compared to controls the structural connectivity and integrity measures per se did not show any significant difference between the groups.

In contrast to this finding, previous OCD studies do report structural alterations in main WM tracts (Koch et al., 2014). One potential reason for this inconsistency is that – instead of investigating whole brain SC – we restricted our analysis to a specific WM tract of the functionally coupled areas, following a results driven approach. The WM tracts we found in the present study represent most probably major parts of the inferior longitudinal fasciculus (ILF) (Catani and de Schotten, 2012). Alterations in these specific fiber bundles have been reported in adolescent OCD patients (Jayarajan et al., 2012; Zarei et al., 2011) as well as in OCD adults (Garibotto et al., 2010). Although results regarding the direction of disruption (increased vs. decreased) or characteristics of the WM tracts (FA, axial, radial diffusivity or directionality of tracts) were heterogeneous, they overall point to the potential relevance of the ILF for the disorder. A review of Piras et al. (2013) showed that alterations in intra-hemispheric bundles linked to posterior parietal and occipital association cortices are also consistently reported in the OCD literature. Our findings support these results.

4.4. Association between function, structure and symptoms

According to Jones et al. (2013) the measures obtained from tractography, indicating connectivity distribution or connectivity extent, can be considered as good estimates for the variations in the anatomical connections and as a good direct estimate of connection strength at the macroscopic level of an anatomical structure. Our study results revealed that exactly this structural connectivity characteristic of the WM tracts, i.e., strength or extent of WM tracts, was associated with an increase in functional connectivity of the connected areas only in the OCD group.

This finding suggests that an increased extent of WM tracts may constitute the basis of an increased functional connectivity in patients. Thus, stronger structural connectivity (in terms of higher connectivity distribution values of the ILF) might reflect an increased efficiency in transmitting information which, in turn, is reflected by a stronger functional connectivity between the respective regions connected by the ILF (i.e., amygdala and parieto-occipital areas) in patients. Although it is a matter of debate which neurophysiological characteristics (e.g., varying degree of myelination, axonal branching, fiber complexity, diameter) are mainly mirrored by connectivity distribution, microstructural characteristics have been shown to change with experience (Zatorre et al.,

2012). Myelinogenesis, caused by neural activity in fiber tracts during intensive processing or training, is one possible mechanism underlying increased structural connectivity. Mice studies have demonstrated that increasing neuronal electrical activity by the use of specific neurotoxins known to increase the firing of neurons caused increased myelination (Demerens et al., 1996). Transferred to the present findings, it can be speculated that the more intensive visual perception, as discussed above, may be the mechanism underlying increased structural and functional connectivity in patients in respective regions and their connecting white matter fiber tracts.

Finally, our results reveal that a specific characteristic of this group, i.e. symptom severity, goes along with a decrease in WM tract integrity (FA), which is considered a stable indicator of altered myelination.

Although present correlation results need to be interpreted with caution as they were not corrected for multiple comparisons, they still give reason to assume that the functional connectivity disruptions may underlie alterations in structural connectivity, indicating that structural disruptions may be the basis of broader network functional disruptions. The negative association of structural integrity and symptom severity underlines the psychopathological relevance of these structural changes for the disorder and confirms previous studies which also showed that structural impairments can go along with symptom severity increase despite the directionality of this association being inconsistent.

Moreover, one should keep in mind that our analysis was restricted to specific regions and that further research on this association is needed to find out whether the association of functional and structural characteristics is detectable in other OCD relevant networks also.

There are several limitations that need to be taken into account when interpreting the present findings. First, we used only the OCI-R to assess the symptom spectrum of each participant which has the disadvantage that patients can score high on several subscales. Hence, using the Y-BOCS dimensional symptom checklist would have been more appropriate in order to identify the most prevalent symptom dimensions in this patient sample. As another limitation it should be noted that no quantitative data on the level of arousal and unpleasantness experienced during observation of the negative pictures are available as debriefing was done only in the form of an unstructured interview after the scanning. Future similar tasks should assess the level of experienced arousal and unpleasantness as an additional parameter to support and facilitate interpretation of observed neural activity.

Finally, although our sample had the primary diagnosis OCD, it should not go unmentioned that patients were not comorbidity- and medication-free, which may have influenced our results to some extent. As our results showed, medicated patients had higher taskFC values than unmedicated patients and controls. Hence, we cannot exclude the fact that our increased taskFC results could have been influenced by medication to some extent. Further studies with an age and gender matched sample of medicated and unmedicated or medication naive patients are needed to clarify this effect.

5. Conclusion

To the best of our knowledge, this is the first study to explore the relationship between amygdala task dependent functional and structural connectivity in OCD. The main contribution of our study is the comprehensive assessment of functional and structural connectivity of the amygdala, a region previously discussed as OCD relevant, and the direct association between these measures. Our study demonstrated that besides the well-known CSTC circuit, limbic brain regions, responsible for emotional processing, and their parieto-occipital connections, need to be taken into account to increase our understanding of the neuronal mechanisms underlying the OCD psychopathology.

Conflict of interest

We declare that we have no conflict of interest to report.

Acknowledgements

We thank the Windach Institute and Hospital of Neurobehavioural Research and Therapy, Windach, Germany, for giving us the opportunity

to recruit our patient sample at their institution. This study was supported by a Deutsche Forschungsgemeinschaft (DFG) grant to KK (KO 3744/2-1). This work was supported by the German Research Foundation (DFG) and the Technische Universität München within the funding programme Open Access Publishing. We also thank the Graduate School of Systemic Neurosciences (GSN) for making it possible to share the results with the neuroscientific community at various occasions such as conferences, retreats and symposia.

Appendix A

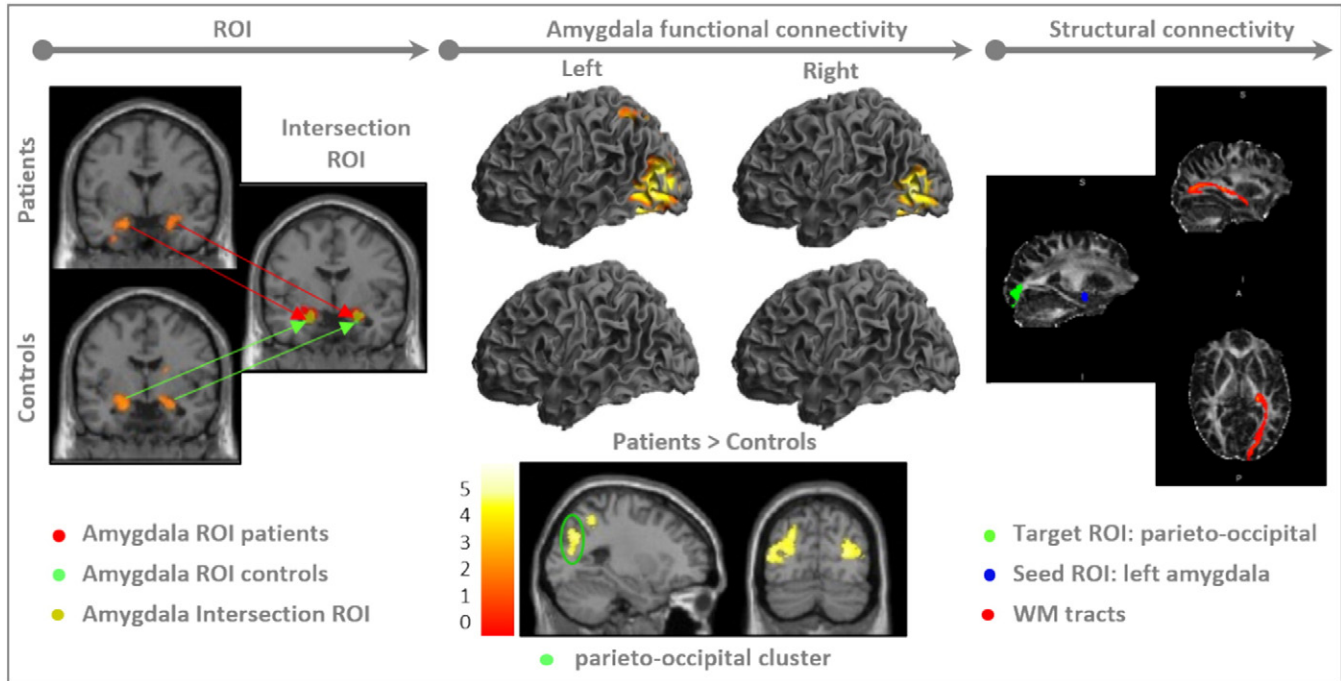


Fig. 1. Left section: Construction of ROI. (left images) Amygdala activation cluster resulting from one-sample t-tests ($p < 0.05$, FWE corrected at voxel level) for the contrast “negative affective vs. neutral pictures” in OCD patients (top) and in controls (bottom). (right image) Amygdala seed ROI for the connectivity analyses (i.e., intersection of group specific activation clusters). Middle section: Functional connectivity analysis results. Brain regions showing increased taskFC (negative affective vs. neutral pictures) with the amygdala separately in both groups (first two rows) and in group contrast last row: (top row) brain regions (bilateral occipital, parietal areas) showing an increased taskFC with the left and right amygdala in the patient group. (middle row) no significant increase in taskFC of left amygdala in the control group (right). (bottom row) brain regions showing an increased taskFC with the left amygdala in OCD patients compared to controls. Color bar represents t-values ($p < 0.05$, FDR corrected at voxel level). Marked in green is the target cluster for the probabilistic fiber tracking. Shown is the left side (slice: $x = -26$). No differences in taskFC of the right amygdala between the groups. Right section: Results from the probabilistic fiber tracking analysis. (left image) intersection ROIs used for the analysis (i.e., probFT analysis) for both groups (seed ROI marked in blue, target ROI marked in green). (right image) output images from the probFT in individual space. Shown are the WM tracts connecting the seed ROI amygdala (marked in blue) with the target ROI (marked in green) in sagittal and axial orientation.

Table 1

Demographic and clinical data of participants.

	OCD (N = 42)	Controls (N = 37)	Group difference
Characteristic	Mean (SD)	Mean (SD)	p-value
Sex, male:female	15:27	15:22	n.s. ($p = 0.48$)
Age, Years	32.50 (9.95)	30.99 (7.56)	n.s. ($p = 0.45$)
Medication, yes/no	27/15		NA
Medication type	17 SSRI 3 SNRI 4 TrA 1 Benzo 2 no info		
Patients with more than one drug:	3 Antipsy 1 NDRI		
Comorbidities Present/not present	24/18		NA
Comorbidity type	14 depression 3 anxiety disorders 5 depression & anxiety disorder 1 personality disorder 1 impulse control disorder-not otherwise specified		

Table 1 (continued)

	OCD (N = 42)	Controls (N = 37)	Group difference
Years since onset	16.23 (10.64)		NA
YBOCS total	20.71 (5.58)		NA
– obsessions	10.90 (3.24)		
– compulsions	9.76 (3.77)		
OCI-R total	24.07 (10.09)		NA
– Hoarding	2.48 (2.90)		
– Checking	5.52 (3.51)		
– Ordering	3.33 (3.75)		
– Neutralizing	2.17 (4.19)		
– Washing	4.31 (3.65)		
– Obsessing	6.62 (3.26)		
BDI	17.60 (11.53)		
FEE	2.43 (0.55)	2.01 (0.61)	s. (p = 0.002)

*Y-BOCS = Yale-Brown Obsessive Compulsive Scale.

*OCI-R = Obsessive-Compulsive Inventory – Revised;

*BDI = Beck Depression Inventory.

*FEE = disgust sensitivity questionnaire.

*n.s. = not significant.

*NA = not applicable.

*M (SD) = mean (standard deviation).

*SSRI = selective serotonin reuptake inhibitor; SNRI = serotonin-norepinephrine reuptake inhibitor; TrA = tricyclic antidepressant; Benzo = benzodiazepine; Antipsy = Antipsychotic; NDRI = Norepinephrine-dopamine reuptake inhibitor.

Table 2

MNI coordinates of activation maxima for taskFC (negative affective vs. neutral pictures) in patients with the left amygdala as seed region and the right amygdala as seed region (one sample t-test at $p < 0.05$, FDR corrected at voxel level). The expected voxels per cluster ($k = 12$ for left, $k = 16$ for right) were then taken as a spatial extent threshold.

Brain regions	side	k	p FDR	T	x, y, z
Left amygdala connectivity					
Fusiform gyrus, middle temporal gyrus, middle occipital gyrus, precuneus, cuneus	L	3694	0.001	6.68	–38 –60 18
Middle occipital gyrus, fusiform gyrus, cuneus, precuneus	R	3502	0.001	6.44	40 –80 14
Superior parietal lobule, precuneus	L	415	0.001	4.87	–30 –56 54
Parahippocampal gyrus	L	38	0.004	4.11	–16 –4 –14
Inferior parietal gyrus	L	61	0.008	3.78	–38 –36 40
Right amygdala connectivity					
Temporal lobe, fusiform gyrus, inferior temporal gyrus, lingual gyrus	L	1779	0.005	5.96	–40 –56 –18
Occipital lobe, inferior occipital gyrus, fusiform gyrus, inferior occipital gyrus, middle occipital gyrus	R	1037	0.005	5.61	40 –62 –12

*L/R = left/right side; k = number of voxels in cluster; p = FDR correction at voxel level; T = t value; x, y, z = MNI coordinates in mm.

Table 3

MNI coordinates of activation maxima for increased taskFC (negative affective vs. neutral pictures) in patients compared to controls with the left amygdala as seed region (two sample t-test at $p < 0.05$, FDR correction at voxel level). Expected voxels per cluster ($k = 12$) were then taken as a spatial extent threshold.

Brain regions	Side	k	p FDR	T	x, y, z
Inferior parietal lobule, superior parietal lobule, precuneus	L	303	0.026	5.07	–36 –50 56
Middle occipital gyrus, middle temporal gyrus	R	623	0.026	4.79	34 –78 16
Posterior lobe, Cerebellum	R	92	0.026	4.48	16 –76 44
Middle occipital gyrus, superior parietal lobule, precuneus	L	554	0.026	4.44	–46 –76 14
Occipital lobe, fusiform gyrus	L	127	0.026	4.40	–34 –58 12
Anterior lobe, Cerebellum	R	42	0.027	4.18	24 –54 28
Parietal lobe, Inferior parietal lobule	L	128	0.027	4.02	–38 –36 36
Anterior lobe, Cerebellum	L	32	0.028	3.97	–18 –52 26
Posterior lobe, Cerebellum	L	22	0.029	3.93	–14 –62 38
Temporal lobe, superior temporal gyrus	L	14	0.030	3.88	–36 12 30
Frontal lobe, middle frontal gyrus	L	34	0.030	3.87	–30 –2 42
Parietal lobe, Superior parietal lobule	R	110	0.031	3.83	28 –70 48
Parietal lobe, inferior parietal lobule	L	36	0.031	3.81	–58 –18 28
Sub lobar, thalamus	R	14	0.035	3.68	2 –14 12

*L/R = left/right side; k = number of voxels in the cluster; p = FDR correction at voxel level; T = t value; x, y, z = MNI coordinates in mm; bold = target parieto-occipital cluster used for further analysis.

Appendix B. Supplementary data

Supplementary data to this article can be found online at <http://dx.doi.org/10.1016/j.nicl.2016.12.007>.

References

- Admon, R., Bleich-Cohen, M., Weizmant, R., Poyurovsky, M., Faragian, S., Hendler, T., 2012. Functional and structural neural indices of risk aversion in obsessive-compulsive disorder (OCD). *Psychiatry Res.* 203, 207–213.
- Ahmari, S.E., Spellman, T., Douglass, N.L., Kheirbek, M.A., Simpson, H.B., Deisseroth, K., Gordon, J.A., Hen, R., 2013. Repeated cortico-striatal stimulation generates persistent OCD-like behavior. *Science* 340, 1234–1239.
- Annett, M., 1970. A classification of hand preference by association analysis. *Br. J. Psychol.* 61, 303–321.
- Anticevic, A., Hu, S., Zhang, S., Savic, A., Billingslea, E., Wasyluk, S., Repovs, G., Cole, M.W., Bednarski, S., Krystal, J.H., Bloch, M.H., Li, C.S., Pittenger, C., 2014. Global resting-state functional magnetic resonance imaging analysis identifies frontal cortex, striatal, and cerebellar dysconnectivity in obsessive-compulsive disorder. *Biol. Psychiatry* 75, 595–605.
- Arnold, J.F., Zwiers, M.P., Fitzgerald, D.A., van Eijndhoven, P., Becker, E.S., Rinck, M., Fernandez, G., Speckens, A.E., Tendolcar, I., 2012. Fronto-limbic microstructure and structural connectivity in remission from major depression. *Psychiatry Res.* 204, 40–48.
- Beck, A.T., Ward, C.H., Mendelson, M., Mock, J., Erbaugh, J., 1961. An inventory for measuring depression. *Arch. Gen. Psychiatry* 4, 561–571.
- Behrens, T.E., Berg, H.J., Jbabdi, S., Rushworth, M.F., Woolrich, M.W., 2007. Probabilistic diffusion tractography with multiple fibre orientations: what can we gain? *NeuroImage* 34, 144–155.
- Beucke, J.C., Kaufmann, C., Linnman, C., Gruetzmann, R., Endrass, T., Deckersbach, T., Dougherty, D.D., Kathmann, N., 2012. Altered cingulo-striatal coupling in obsessive-compulsive disorder. *Brain Connect* 2, 191–202.
- Beucke, J.C., Sepulcre, J., Talukdar, T., Linnman, C., Zschenderlein, K., Endrass, T., Kaufmann, C., Kathmann, N., 2013. Abnormally high degree connectivity of the orbitofrontal cortex in obsessive-compulsive disorder. *JAMA Psychiatry* 70, 619–629.
- Breiter, H.C., Rauch, S.L., Kwong, K.K., Baker, J.R., Weisskoff, R.M., Kennedy, D.N., Kendrick, A.D., Davis, T.L., Jiang, A., Cohen, M.S., Stern, C.E., Belliveau, J.W., Baer, L., O'Sullivan, R.L., Savage, C.R., Jenike, M.A., Rosen, B.R., 1996. Functional magnetic resonance imaging of symptom provocation in obsessive-compulsive disorder. *Arch. Gen. Psychiatry* 53, 595–606.
- Brett, M., Anton, J.-L., Valabregue, R., Poline, J.B., 2002. Region of interest analysis using an SPM toolbox [abstract]. Presented at the 8th International Conference on Functional Mapping of the Human Brain. Vol 16. Available on CD-ROM in *NeuroImage* (No. 2, abstract 497, Sendai, Japan).
- Cannistraro, P.A., Makris, N., Howard, J.D., Wedig, M.M., Hodge, S.M., Wilhelm, S., Kennedy, D.N., Rauch, S.L., 2007. A diffusion tensor imaging study of white matter in obsessive-compulsive disorder. *Depress Anxiety* 24, 440–446.
- Catani, M., de Schotten, M.T., 2012. *Atlas of Human Brain Connections*. Oxford University Press, New York.
- Cisler, J.M., Olatunji, B.O., 2010. Components of attentional biases in contamination fear: evidence for difficulty in disengagement. *Behav. Res. Ther.* 48, 74–78.
- de Vries, F.E., de Wit, S.J., Cath, D.C., van der Werf, Y.D., van der Borden, V., van Rossum, T.B., van Balkom, A.J., van der Wee, N.J., Veltman, D.J., van den Heuvel, O.A., 2014. Compensatory frontoparietal activity during working memory: an endophenotype of obsessive-compulsive disorder. *Biol. Psychiatry* 76, 878–887.
- Demerets, C., Stankoff, B., Logak, M., Anglade, P., Allinquant, B., Couraud, F., Zalc, B., Lubetzki, C., 1996. Induction of myelination in the central nervous system by electrical activity. *Proc. Natl. Acad. Sci. U. S. A.* 93, 9887–9892.
- Diniz, J.B., Miguel, E.C., de Oliveira, A.R., Reimer, A.E., Brandao, M.L., de Mathis, M.A., Batistuzzo, M.C., Costa, D.L., Hoexter, M.Q., 2012. Outlining new frontiers for the comprehension of obsessive-compulsive disorder: a review of its relationship with fear and anxiety. *Rev. Bras. Psiquiatr.* 34 (Suppl. 1), S81–S91.
- Fiddick, L., 2011. There is more than the amygdala: potential threat assessment in the cingulate cortex. *Neurosci. Biobehav. Rev.* 35, 1007–1018.
- Foa, E.B., Huppert, J.D., Leiberg, S., Langner, R., Kichic, R., Hajcak, G., Salkovskis, P.M., 2002. The obsessive-compulsive inventory: development and validation of a short version. *Psychol. Assess.* 14, 485–496.
- Garibotto, V., Scifo, P., Gorini, A., Alonso, C.R., Brambati, S., Bellodi, L., Perani, D., 2010. Disorganization of anatomical connectivity in obsessive compulsive disorder: a multi-parameter diffusion tensor imaging study in a subpopulation of patients. *Neurobiol. Dis.* 37, 468–476.
- Goncalves, O.F., Marques, T.R., Lori, N.F., Sampaio, A., Branco, M.C., 2010. Obsessive-compulsive disorder as a visual processing impairment. *Med. Hypotheses* 74, 107–109.
- Goodman, W.K., Price, L.H., Rasmussen, S.A., Mazure, C., Fleischmann, R.L., Hill, C.L., Heninger, G.R., Charney, D.S., 1989. The Yale-Brown obsessive compulsive scale. I. Development, use, and reliability. *Arch. Gen. Psychiatry* 46, 1006–1011.
- Gottlich, M., Kramer, U.M., Kordon, A., Hohagen, F., Zurovski, B., 2014. Decreased limbic and increased fronto-parietal connectivity in unmedicated patients with obsessive-compulsive disorder. *Hum. Brain Mapp.* 35, 5617–5632.
- Gottlich, M., Kramer, U.M., Kordon, A., Hohagen, F., Zurovski, B., 2015. Resting-state connectivity of the amygdala predicts response to cognitive behavioral therapy in obsessive compulsive disorder. *Biol. Psychiatry* 111, 100–109.
- Harrison, B.J., Soriano-Mas, C., Pujol, J., Ortiz, H., Lopez-Sola, M., Hernandez-Ribas, R., Deus, J., Alonso, P., Yucel, M., Pantelis, C., Menchon, J.M., Cardoner, N., 2009. Altered corticostriatal functional connectivity in obsessive-compulsive disorder. *Arch. Gen. Psychiatry* 66, 1189–1200.
- Jayarajan, R.N., Venkatasubramanian, G., Viswanath, B., Janardhan Reddy, Y.C., Srinath, S., Vasude, M.K., Chandrashekar, C.R., 2012. White matter abnormalities in children and adolescents with obsessive-compulsive disorder: a diffusion tensor imaging study. *Depress Anxiety* 29, 780–788.
- Jhung, K., Ku, J., Kim, S.J., Lee, H., Kim, K.R., An, S.K., Kim, S.I., Yoon, K.J., Lee, E., 2014. Distinct functional connectivity of limbic network in the washing type obsessive-compulsive disorder. *Prog. Neuro-Psychopharmacol. Biol. Psychiatry* 53, 149–155.
- Jones, D.K., Knosche, T.R., Turner, R., 2013. White matter integrity, fiber count, and other fallacies: the do's and don'ts of diffusion MRI. *NeuroImage* 73, 239–254.
- Jung, W.H., Kang, D.H., Kim, E., Shin, K.S., Jang, J.H., Kwon, J.S., 2013. Abnormal corticostriatal-limbic functional connectivity in obsessive-compulsive disorder during reward processing and resting-state. *Neurol. Clin.* 3, 27–38.
- Koch, K., Reess, T.J., Rus, O.G., Zimmer, C., Zaudig, M., 2014. Diffusion tensor imaging (DTI) studies in patients with obsessive-compulsive disorder (OCD): a review. *J. Psychiatr. Res.* 54, 26–35.
- Lawrence, A.D., Sahakian, B.J., Robbins, T.W., 1998. Cognitive functions and corticostriatal circuits: insights from Huntington's disease. *Trends Cogn. Sci.* 2, 379–388.
- Mataix-Cols, D., van den Heuvel, O.A., 2006. Common and distinct neural correlates of obsessive-compulsive and related disorders. *Psychiatr Clin North Am* 29, 391–410 (viii).
- Mataix-Cols, D., Wooderson, S., Lawrence, N., Brammer, M.J., Speckens, A., Phillips, M.L., 2004. Distinct neural correlates of washing, checking, and hoarding symptom dimensions in obsessive-compulsive disorder. *Arch. Gen. Psychiatry* 61, 564–576.
- McLaren, D.G., Ries, M.L., Xu, G., Johnson, S.C., 2012. A generalized form of context-dependent psychophysiological interactions (gPPI): a comparison to standard approaches. *NeuroImage* 61, 1277–1286.
- Menzies, L., Chamberlain, S.R., Laird, A.R., Thelen, S.M., Sahakian, B.J., Bullmore, E.T., 2008. Integrating evidence from neuroimaging and neuropsychological studies of obsessive-compulsive disorder: the orbitofronto-striatal model revisited. *Neurosci. Biobehav. Rev.* 32, 525–549.
- Milad, M.R., Rauch, S.L., 2012. Obsessive-compulsive disorder: beyond segregated corticostriatal pathways. *Trends Cogn. Sci.* 16, 43–51.
- Mondino, M., Haesebaert, F., Poulet, E., Saoud, M., Brunelin, J., 2015. Efficacy of cathodal transcranial direct current stimulation over the left orbitofrontal cortex in a patient with treatment-resistant obsessive-compulsive disorder. *J ECT* 31 (4):271–272. <http://dx.doi.org/10.1097/YCT.0000000000000218>.
- Moritz, S., Von Muhlenen, A., Randjbar, S., Fricke, S., Jelinek, L., 2009. Evidence for an attentional bias for washing- and checking-relevant stimuli in obsessive-compulsive disorder. *J. Int. Neuropsychol. Soc.* 15, 365–371.
- Olatunji, B.O., Ferreira-Garcia, R., Caseras, X., Fullana, M.A., Wooderson, S., Speckens, A., Lawrence, N., Giampietro, V., Brammer, M.J., Phillips, M.L., Fontenelle, L.F., Mataix-Cols, D., 2013. Predicting response to cognitive behavioral therapy in contamination-based obsessive-compulsive disorder from functional magnetic resonance imaging. *Psychol. Med.* 43, 1–13.
- Olatunji, B.O., Ferreira-Garcia, R., Caseras, X., Fullana, M.A., Wooderson, S., Speckens, A., Lawrence, N., Giampietro, V., Brammer, M.J., Phillips, M.L., Fontenelle, L.F., Mataix-Cols, D., 2014. Predicting response to cognitive behavioral therapy in contamination-based obsessive-compulsive disorder from functional magnetic resonance imaging. *Psychol. Med.* 44, 2125–2137.
- Phelps, E.A., O'Connor, K.J., Gatenby, J.C., Gore, J.C., Grillon, C., Davis, M., 2001. Activation of the left amygdala to a cognitive representation of fear. *Nat. Neurosci.* 4, 437–441.
- Phillips, M.L., Drevets, W.C., Rauch, S.L., Lane, R., 2003. Neurobiology of emotion perception I: the neural basis of normal emotion perception. *Biol. Psychiatry* 54, 504–514.
- Piras, F., Piras, F., Caltagirone, C., Spalletta, G., 2013. Brain circuitries of obsessive compulsive disorder: a systematic review and meta-analysis of diffusion tensor imaging studies. *Neurosci. Biobehav. Rev.* 37, 2856–2877.
- Piras, F., Piras, F., Chiapponi, C., Girardi, P., Caltagirone, C., Spalletta, G., 2015. Widespread structural brain changes in OCD: a systematic review of voxel-based morphometry studies. *Cortex* 62, 89–108.
- Ruscio, A.M., Stein, D.J., Chiu, W.T., Kessler, R.C., 2010. The epidemiology of obsessive-compulsive disorder in the National Comorbidity Survey Replication. *Mol. Psychiatry* 15, 53–63.
- Saxena, S., Brody, A.L., Schwartz, J.M., Baxter, L.R., 1998. Neuroimaging and frontal-subcortical circuitry in obsessive-compulsive disorder. *Br J Psychiatry Suppl* 26–37.
- Schienenle, A., Walter, B., Stark, R., Vaitl, D., 2002. Ein Fragebogen zur Erfassung der Ekelempfindlichkeit. *Z. Klin. Psychol. Psychother.* 31, 110–120.
- Simon, D., Adler, N., Kaufmann, C., Kathmann, N., 2014. Amygdala hyperactivation during symptom provocation in obsessive-compulsive disorder and its modulation by distraction. *Neurol. Clin.* 4, 549–557.
- Simon, D., Kaufmann, C., Musch, K., Kischkel, E., Kathmann, N., 2010. Fronto-striato-limbic hyperactivation in obsessive-compulsive disorder during individually tailored symptom provocation. *Psychophysiology* 47, 728–738.
- van den Heuvel, O.A., Remijnse, P.L., Mataix-Cols, D., Vrenken, H., Groenewegen, H.J., Uylings, H.B., van Balkom, A.J., Veltman, D.J., 2009. The major symptom dimensions of obsessive-compulsive disorder are mediated by partially distinct neural systems. *Brain* 132, 853–868.
- van den Heuvel, O.A., Veltman, D.J., Groenewegen, H.J., Dolan, R.J., Cath, D.C., Boellaard, R., Mesina, C.T., van Balkom, A.J., van Oppen, P., Witter, M.P., Lammertsma, A.A., van Dyck, R., 2004. Amygdala activity in obsessive-compulsive disorder with contamination fear: a study with oxygen-15 water positron emission tomography. *Psychiatry Res.* 132, 225–237.
- Via, E., Cardoner, N., Pujol, J., Alonso, P., Lopez-Sola, M., Real, E., Contreras-Rodriguez, O., Deus, J., Segalas, C., Menchon, J.M., Soriano-Mas, C., Harrison, B.J., 2014. Amygdala activation and symptom dimensions in obsessive-compulsive disorder. *Br. J. Psychiatry* 204, 61–68.

- Wendt, J., Weike, A.I., Lotze, M., Hamm, A.O., 2011. The functional connectivity between amygdala and extrastriate visual cortex activity during emotional picture processing depends on stimulus novelty. *Biol. Psychol.* 86, 203–209.
- Zarei, M., Mataix-Cols, D., Heyman, I., Hough, M., Doherty, J., Burge, L., Winmill, L., Nijhawan, S., Matthews, P.M., James, A., 2011. Changes in gray matter volume and white matter microstructure in adolescents with obsessive-compulsive disorder. *Biol. Psychiatry* 70, 1083–1090.
- Zatorre, R.J., Fields, R.D., Johansen-Berg, H., 2012. Plasticity in gray and white: neuroimaging changes in brain structure during learning. *Nat. Neurosci.* 15, 528–536.
- Zhang, D., Snyder, A.Z., Shimony, J.S., Fox, M.D., Raichle, M.E., 2010. Noninvasive functional and structural connectivity mapping of the human thalamocortical system. *Cereb. Cortex* 20, 1187–1194.