

Antigens under cover—The preservation and demasking of selected antigens for successful poststaining immunocytochemistry of effusion, brain smears, and lymph node aspirates

Stefanie Dörfelt¹ | Lara A. Matiasek^{1,2} | Sandra Felten¹ | Laura Sangl¹ |
Katrin Hartmann¹ | Kaspar Matiasek³

¹Clinic of Small Animal Medicine, Centre for Clinical Veterinary Medicine, Ludwig-Maximilians-Universität, Munich, Germany

²Anicura Small Animal Clinic, Babenhausen, Germany

³Section of Clinical & Comparative Neuropathology, Centre for Clinical Veterinary Medicine, Ludwig-Maximilians-Universität, Munich, Germany

Correspondence

Kaspar Matiasek, Section of Clinical & Comparative Neuropathology, Centre for Clinical Veterinary Medicine, Ludwig-Maximilians-Universität, Munich, Germany.
Email: kaspar.matiasek@neuropathologie.de

Abstract

Background: In clinical cytology, the applicability of an ancillary test such as immunocytochemistry is too often limited by low sample volume, poor cell representation, and sample preservation. Diagnosticians often read Romanowsky-stained cytology, although specific techniques such as immunocytochemistry are often essential for a definitive diagnosis.

Objectives: The goal of the present study aimed to investigate if immunocytochemistry on previously-stained cytologic specimens was possible. Different pretreatments were examined to determine which treatment preserved antigenicity best.

Methods: One hundred and twenty-two impression smears and 64 fine-needle aspirate preparations of brain and lymph nodes were processed and evaluated microscopically. The impact of staining cytologic preparations with a modified Wright's stain, using a destaining method, performing a coverslipping and decoverslipping process, and subjecting smears to a microwave treatment (MWT) were examined for the immunolabeling of selected nuclear, cytoplasmic, and plasmalemmal antigens, as well as intracellular feline coronavirus (FCoV). Biotinylated secondary antibodies were used, and the bound primary antibody was visualized using an ABC amplification kit.

Results: Cellular antigens were reliably detected with immunocytochemistry after smears were stained with a Romanowsky stain and were coverslipped early after staining and stayed coverslipped until immediately before immunolabeling. The staining intensity reached the same levels as that of the controls if the films underwent MWT in citrate buffer. In contrast, FCoV antigen detection was abolished after any physicochemical interference.

Conclusions: Poststaining immunocytochemistry represents a practical tool for additional investigations on prestained cytologic specimens when searching for cellular antigens. Paired untreated samples should be kept in case the workup requires testing for more vulnerable viral antigens.

KEYWORDS

coverslip, destaining, feline infectious peritonitis, microwave, neurocytology

1 | INTRODUCTION

Investigation of cytologic specimens obtained by fine-needle aspiration (FNA) is the least invasive approach to obtain a diagnosis of disease.^{1–3} Cytomorphology, however, can provide only limited insights into the biology of a neoplastic disorder or the etiology of an infectious process. It may be necessary to combine cytomorphology with specific disease markers to elucidate the underlying disease and collect predictive data.² In contrast to histologic investigations, which allow for multiple tissue sections that can examine individual cells, repetitive impression smears and FNA of the same tissue can by no means reproduce the same composition of cells and tissue components.² In addition to these technological limitations, the type and distribution of a lesion can pose essential limitations to its holistic cytologic characterization. Thus, detectability is compromised if the lesion is (a) poorly exfoliative and of low cellularity; (b) affecting tissues that are difficult to access (eg, the central nervous system [CNS]) or comprised of sparse fluids (eg, cerebrospinal fluid [CSF]); (c) has atypical cells and pathogens that are poorly dense or scantily distributed; and (d) has cells that are highly vulnerable to shearing stress.

To detect changes in samples with low cellularity, multiple investigations should be carried out on the same slide rather than single investigations on multiple slides with variable cell numbers.

The simplest secondary procedures use conventional stains to highlight microorganisms, chemical compounds, matrix components, and subcellular structures with histochemistry after a destaining procedure. With the advancement of panoptic stains, special stains have mainly focused on the assessment of microbial and fungal organisms (eg, Ziehl-Neelsen, Fite-Faraco, Gram, Fontana-Masson), mucins and polysaccharides (eg, Alcian blue, Periodic acid-Schiff), iron pigments, and melanin (eg, Prussian blue reaction, Nile blue A, Fontana-Masson).² As cellular identification is rarely needed in these situations, ancillary staining often can be conducted on spare slides.² Other infectious diseases and tumor cell antigens, however, could require preselection and cytomorphologic characterization of the cells to be stained.^{2,3} This holds true, in particular, for advanced tumor diagnoses.^{3,4} Immunocytochemistry (ICC) on Romansky-stained (pre-stained) slides (poststaining ICC, PSICC) could help identify the histogenetic origin of tumors or cell types, characterize cells that cannot be identified with conventional stains, and obtain further prognostic and predictive information.^{3,5–8} For infectious diseases, PSICC is a promising tool for the intracellular detection of viral proteins. One of the most common situations is in the detection of feline coronavirus (FCoV) for the diagnosis of feline infectious peritonitis (FIP), in which the presence of intracellular viral antigens in macrophages must be demonstrated.^{9,10} This approach requires preservation of both the target antigen and host cell morphology.

Historically, PSICC methodology was tailored to individual cases. Therefore, systematic studies on the reproducibility, efficacy, and reliability of immunostaining are rare.^{1,11–24} Hence, the present study aimed to fill this gap by establishing reproducible guidelines for PSICC labeling of selected cellular and viral antigens in tissue

imprints, FNA, and cytocentrifuged fluids with the focus specifically on antigen preservation and retrieval. Target antigen selection was driven by our daily neurocytologic specimen caseload various mammalian species with possible inflammatory and infectious CNS diseases.

2 | MATERIALS AND METHODS

2.1 | Study design

This study investigated (a) the ability to apply ICC to prestained cytologic specimens, (b) whether coverslipping could be used to preserve antigenicity, and (c) whether microwave treatment (MWT) enhanced immunodetection in prestained smears. Therefore, ICC staining quality was evaluated on smears after prestaining with a modified Wright's stain (modWS), destaining with hydrochloric acid (HCl), and then comparing the now unstained samples with and without coverslipping and MWT. The effects were evaluated for a set of cellular antigens with a distinct subcellular distribution (study A) and intracellular FCoV proteins (study B). All procedures were carried out at the Institute of Veterinary Pathology, LMU Munich. The investigation enrolled surplus postmortem samples (studies A & B) and/or discarded specimens (study B) after the examination had been completed a diagnosis had been achieved. The procedures were exempt from Institutional Animal Care and Use Committee review as was decided by the Ethics Commission of the Centre for Veterinary Clinical Medicine of the LMU Munich.

2.2 | Study A—cellular antigens

We tested the impact of individual pretreatments on the immunostaining of nuclear, cytoplasmic, and membrane antigens. Therefore, this systematic evaluation employed distinct methodologic trials, as illustrated in Figure 1 and Table 1.

A series of 122 impression smears and 64 FNA preparations were taken from the brain and lymph nodes of a cat and a pig during postmortem examination (<1/2 hour after euthanasia) for reasons unrelated to the study's purpose. CNS cells were obtained from the postcruciate gyrus of the brain after extensive craniectomy, encephalotomy, and trimming, as described elsewhere.^{25,26} Lymphocyte-enriched samples were collected from the superficial cervical and para-aortic lymph nodes via FNA using a 22-gauge syringe. All preparations were air-dried immediately.

A set (30/186) of cytology smears (20 CNS; 10 FNAs) was stained for cytomorphologic examination (trial 1) using a Hematek Slide Stainer (Siemens Healthcare Diagnostic, Inc, Tarrytown, NY, USA). Another 24 slides (8 per antigen) were stained with a modified Wright's stain (modWS), coverslipped using a xylene-based mounting medium (Histokitt, Glaswarenfabrik Karl Hecht GmbH & Co. KG, Sondheim/Rhön, Germany), and underwent "hot mount" polymerization using MWT (2 minutes, 600 W, dry) prior to PSICC (Table 1). All slides were coverslipped for at least 5 days. The effects of the staining-destaining cycle (SDS, 24 slides) on immunodetection (trial

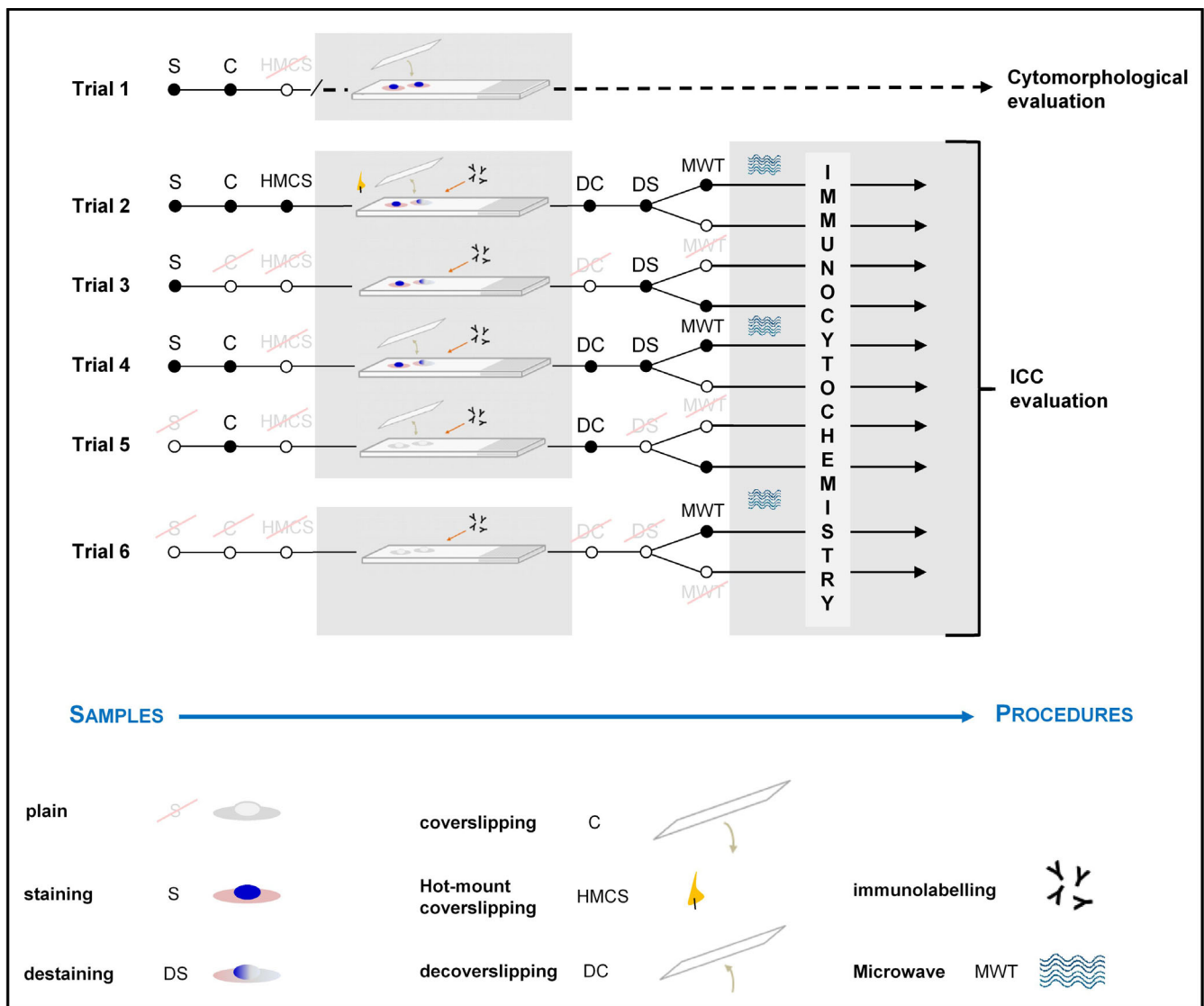


FIGURE 1 Schematic illustration of the staining trials. Trial 1: Slides were stained and coverslipped. These slides were used for cytomorphologic evaluations. Trial 2: The procedure included staining, coverslipping, and microwave treatments of the slides. After storage and directly before immunocytochemistry, these specimens were decoverslipped and destained, and half of the slides were microwave-treated again. Trial 3: Slides were only stained and stored before immunocytochemistry, at which time the slides were destained, and half were microwave treated. Trial 4: Slides were stained and coverslipped. After storage and directly before immunocytochemistry, they were decoverslipped and destained, and half of them were microwave treated. Trial 5: This procedure included only the coverslipping of the slides. Before immunocytochemistry, the slides were decoverslipped, and half were microwave treated. Trial 6: No pretreatment was carried out with these specimens, and they were stored frozen. Only half of the slides were pretreated in the microwave before immunocytochemistry. These unstained and untreated slides served as the gold standard for the study

3) plus the additive effects of additional coverslipping-decoverslipping cycles (SDS-CDC, 36 slides) (trial 4) were investigated with another 60 slides. These trials were compared to the 36 CDC-treated slides (trial 5) and to a series of 24 slides not subjected to any treatment, which served as the gold standard (trial 6) (Table 1). All samples were stored for up to 3 months.

All slides except those from trial 6 were subjected to the laboratory treatments mentioned above, which preceded ICC. Coverslipped samples from trials 2, 4, and 5 were immersed in xylene to achieve liquefaction of the mounting medium until the coverslips slipped off. Thereafter, the slides were put through a graded ethanol series

(2 × 100%, 1 × 96%, 1 × 70%; 5 minutes each) and immersed in distilled water.

Prestained and decoverslipped slides (trials 2 and 4) and those left uncovered after the modWS method (trial 3) were immersed in 1% HCl until the color had completely faded as identified with microscopy. Freshly destained slides (trials 2, 3, and 4) and non-stained decoverslipped slides from trial 5 were immersed in distilled water until ICC was performed (Figure 1, Table 1).

Before performing ICC, one set of slides from each trial (trials 2, 3, and 6: n = 12 each; trials 4 and 5: n = 18 each; Figure 1 and Table 1) was subjected to the MWT-based antigen retrieval. For this

TABLE 1 Different pretreatments applied before performing the immunocytochemistry trials (Trials 1-6)

	Total number of slides	Cat/pig	modWS	CS	HMCS	De-CS	Destaining	MWT ^a –	Number of slides for each primary AB (NeuN/GFAP/CD3)
Trial 1	30	15/15	+	–	–	–	–	0 30	–
Trial 2	24	12/12	+	+	+	+	+	12/24 12/24	4 4
Trial 3	24	12/12	+	–	–	–	+	12/24 12/24	4 4
Trial 4	36	18/18	+	+	–	+	+	18/36 18/36	6 6
Trial 5	36	18/18	–	+	–	+	–	18/36 18/36	6 6
Trial 6	24	12/12	–	–	–	–	–	12/24 12/24	4 4

Numbers without negative controls (n = 12).

modWS, modified Wright's stain; CS, coverslipping; HMCS, hot mount coverslipping; MWT, microwave treatment; AB, antibody; NeuN, neuronal nuclei; GFAP, glial fibrillary acidic protein.

^aNumber of slides treated with microwave (+) and without microwave (–) for cat and pig together.

TABLE 2 The primary antibodies used in studies A and B

Target antigen	Type/clone	Target	Subcellular localization	Manufacturer
CD3 (ε chain)	Polyclonal Rabbit, Catalogue no. A0452	T lymphocyte	Plasmalemma	DakoCytomation, Glostrup, Denmark
NeuN	Monoclonal Mouse Clone A60, MAB377	Neurons	Nucleus	Millipore, Chemicon, USA & Canada
GFAP	Polyclonal Rabbit, Z0334	Astrocytes	Cytoplasm	DakoCytomation, DK-2600 Glostrup, Denmark
Feline Coronavirus	Monoclonal Mouse Clone FIPV3-70, MAK2194	FIPV type 1 and 2	Nucleocapsid	Linaris GmbH, Dossenheim, Germany

NeuN, neuronal nuclear antigen; GFAP, glial fibrillary acidic protein; FIPV, feline infectious peritonitis virus.

procedure, the slides were transferred to a cuvette containing 0.01 mol/L of a citrate buffer solution (pH 6). Based on our immunohistochemical protocol, MWT was carried out for 5 minutes/800 W followed by 20 minutes/250 W. The slides were left in citrate buffer for 30 minutes to cool down to room temperature. All further steps except for the primary antibody (pAB) incubations were carried out at room temperature.

The MWT slides and those kept in distilled water (destained and unstained slides without MWT, Table 1) were bathed in 0.01 mol/L of phosphate-buffered saline (PBS; pH 7.2) for 20 minutes. Endogenous peroxidase was quenched for 35 minutes by adding hydrogen peroxide (H₂O₂) to the PBS. Thereafter, the slides were washed in fresh PBS, transferred to a humidified chamber, and incubated with normal goat serum (1:20; MP Biomedicals, LLC 3 Hutton Center Drive, Santa Ana, CA, USA) for 30 minutes.

Upon removal of the nonimmune serum, lymph node FNAs were incubated with an anti-CD3 antibody for detection of the corresponding T cell antigen. Other markers, specifically, NeuN and GFAP, were used on separate brain smears (Table 2). Each run contained site-matched slides in which a pAB was replaced by an antibody

diluent, serving as a negative control (altogether n = 12). Incubation was carried out for 18 hours at 4°C (39.2°F).

After repeated wash steps with PBS, the slides were mounted with biotinylated goat anti-rabbit/mouse IgG antibodies (both DAKO, Glostrup, Denmark) for 1 hour. Bound pAB was subsequently visualized using an ABC amplification kit (Vectastain; Vector Laboratory Inc, Burlingame, CA, USA) using diaminobenzidine tetrahydrochloride (DAB) as the chromagen. The enzyme reaction was blocked with PBS rinses. Then, the slides were counterstained with Mayer's hematoxylin (AppliChem GmbH, Darmstadt, Germany), underwent an ascending ethanol series, and were coverslipped as described above.

Cell yields and preservation were assessed with bright field microscopy by two different clinical pathologists. In separate sessions, these observers, who were blinded to the smear origins, the pretreatment types, and the pAB type, evaluated the ICC outcomes. ICC quality determinants were (a) cell type specificity, (b) intensity of cellular staining, (c) the presence/absence of acellular background activity, and (d) nonspecific staining. These parameters were semi-quantitatively scored by using a 4-point system (0-3). In the event of intraobserver disagreement, the slides were reviewed on a

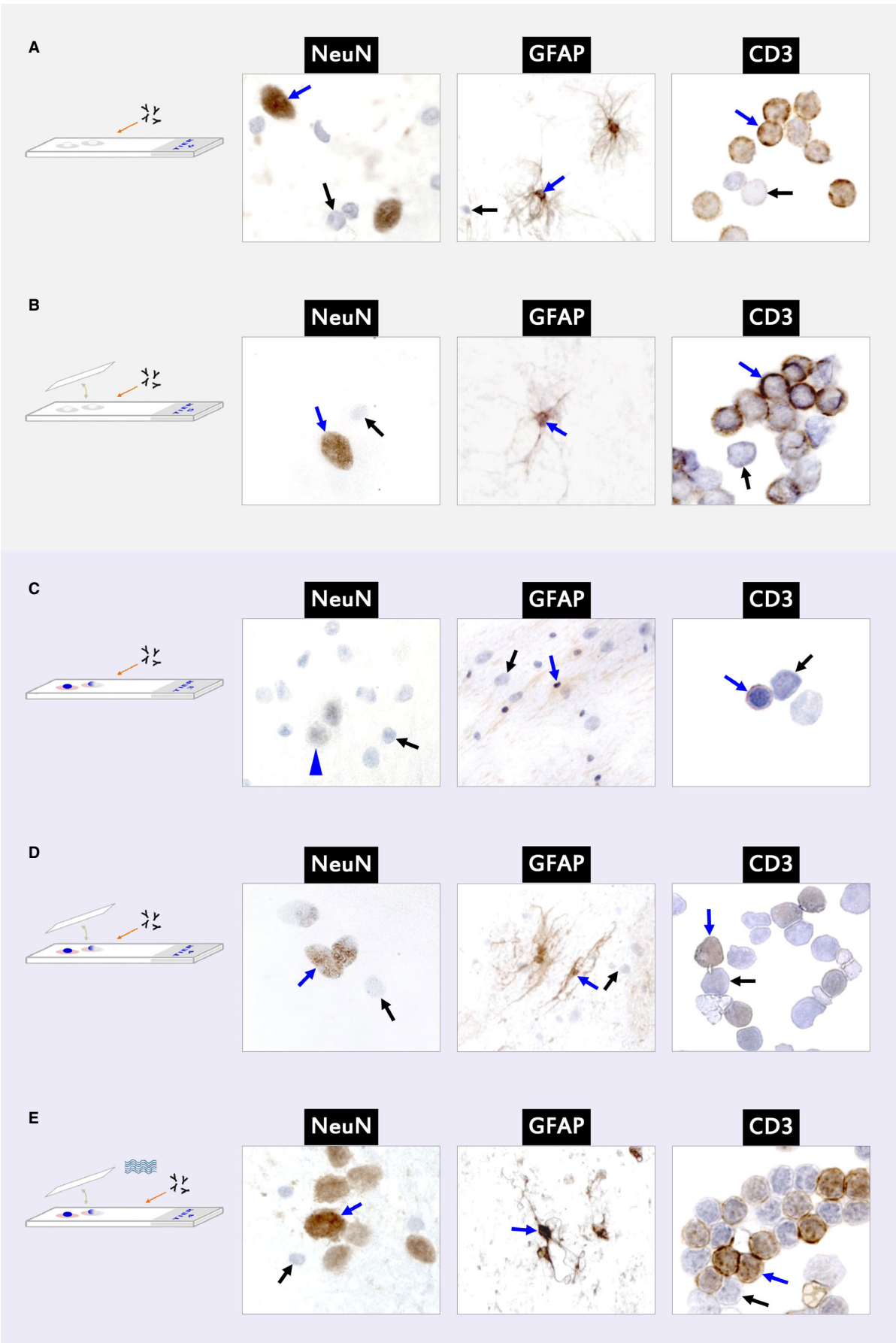


FIGURE 2 The outcome of immunocytochemical staining for cellular antigens (blue arrows: specific positive staining; black arrows: immunonegative cells). Counterstaining with Mayer's hematoxylin. A, Immunocytochemistry on unstained and untreated films served as the gold standard, and which illustrates optimal staining results. The CD3 signal was strongest in the periphery of the lymphocyte cytoplasm close to the membrane. NeuN immunoreactivity was restricted to neuronal nuclei, while GFAP diffusely stained the soma and fragmented processes of astrocytes (procedure depicted in trial 6 without microwave treatment). B, The impact of xylene-based coverslipping and decoverslipping appeared negligible. Hence, microwave treatment was not necessary (procedure depicted in trial 5 without microwave treatment). C, Prestaining with Wright's stain and then bleaching with hydrogen chloride abolished the specific immunostaining of all markers (blue arrow), if the slides were left uncoverslipped (procedure depicted in trial 3 without microwave treatment). D, Coverslipping after prestaining with a Wright's stain appeared superior in being able to preserve antigenicities and specific staining intensities (procedure depicted in trial 4 without microwave treatment). E, Microwave treatment completely rescued the compromising effects of staining/destaining and coverslipping/decoverslipping (procedure depicted in trial 4 with microwave treatment). NeuN = neuronal nuclei, GFAP = glial fibrillary acidic protein, CD3 = T cell marker. The wave image depicts microwave treatment, the upside down γ image depict antibody treatment, the coverslip indicates the coverslipping/decoverslipping technique

multiheaded microscope (Zeiss AxioPhot, Carl Zeiss AG, Oberkochen, Germany), and mean values were newly assigned.

For statistical evaluations, the final scores were compared between the different procedures using nonparametric statistical algorithms. A P of ≤ 0.05 indicated statistical significance.

2.3 | Study B—viral antigens

This study evaluated the impact of pretreatment on FCoV antigen immunolabeling.

Study B was conducted on pleural ($n = 6$) and abdominal ($n = 16$) effusions of FIP cases confirmed with histopathology and FCoV antigen-positive immunohistochemistry.⁹ These effusions were collected using conventional thoracentesis or abdominocentesis procedures.

Harvested fluids were mounted onto uncoated standard slides (Langenbrinck, Emmendingen, Germany) using a cytocentrifuge (Hettich Universal 16, Adelsried, Germany). According to our in-house protocol for effusions, centrifugation chambers were spun for 5 minutes at 250g, after which the supernatant was removed, and the coated slides were centrifuged for 1 minute at 416g. Then, the slides were air-dried and stored at -20°C (-4°F) until further processing.

To evaluate the preservation and antigenicity of viral antigens, the samples underwent trials 3, 4, 5, and 6 (with and without MWT), as described in study A. ICC was performed using a mouse monoclonal antibody directed against the coronavirus nucleocapsid (clone FIPV3-70; Table 2). Incubation and subsequent steps were identical to those applied for NeuN labeling (see above) using the ABC enhancer and DAB.

The ICC signal was re-evaluated by both observers concerning cellular and subcellular localization, intensity, specificity, and background, as described above.

3 | RESULTS

3.1 | Study A—cell-specific antigens

To evaluate cell preservation, the slides were microscopically assessed. ModWS-stained slides revealed a representative cell yield, with fewer than 5% of cells suffering crush artifact and fewer than

10% with ghost nuclei. Cell preservation was inversely related to cell size, as lymphocytes, glial cells, and small granule neurons were less vulnerable to the shearing forces than large neurons.

All samples were coverslipped for at least 5 days. The time needed for coverslip removal upon immersion in xylene corresponded to the duration since coverslipping. For slides coverslipped for fewer than 14 days, the coverslip was removed within 48 hours after incubation. Those slides coverslipped for more than 3 weeks needed 5 days to remove the coverslip without manipulation.

The effects of destaining with HCl were assessed microscopically. Thin FNA smears required 10 minutes to achieve complete decoloration. Thick brain smears required HCl treatment for 15–20 minutes until complete bleaching was observed.

Independent of blood content, endogenous peroxidase activity was completely removed when quenching the slides in 0.7% H_2O_2 for 35 minutes, as seen in controls subjected to direct DAB treatments.

Among unstained and noncoverslipped specimens (trial 6, $n = 24$), ICC for all markers provided good, reliable, and reproducible results with high intensity (median intensity score 2.0 ± 0 to 3.0 ± 0), high cell specificity (median cell specificity score [CSS] 3.0 ± 0) and absent (CD3, NeuN), and low background signals

TABLE 3 The median scores of trial 6 with and without microwave treatments

Antibody	Cell specificity	Intensity	Background	Nonspecific staining
Trial 6				
NeuN	3.0 ± 0.0^a	2.5 ± 0.58	0.0 ± 0.0	0.0 ± 0.0
GFAP	3.0 ± 0.0	2.0 ± 0.0^b	1.5 ± 0.58	0.0 ± 0.5
CD3	3.0 ± 0.0	3.0 ± 0.0	0.0 ± 0.0	0.0 ± 0.5
Trial 6 with MWT				
NeuN	3.0 ± 0.0	3.0 ± 0.0	0.5 ± 0.58	0.0 ± 0.5
GFAP	3.0 ± 0.0	3.0 ± 0.0	2.0 ± 0.82	1.0 ± 0.5
CD3	3.0 ± 0.0	3.0 ± 0.0	0.0 ± 0.0	0.0 ± 0.0

NeuN, neuronal nuclear antigen; GFAP, glial fibrillary acidic protein; MWT, microwave treatment.

^aStandard deviation.

^bSignificant difference between with MWT and without MWT.

TABLE 4 The median scores of trial 5 with and without microwave treatments

Antibody	Cell specificity	Intensity	Background	Nonspecific staining
Trial 5				
NeuN	2.0 ± 0.5 ^{a,b}	1.0 ± 0.5 ^b	1.0 ± 0.5 ^c	0.0 ± 0.0 ^c
GFAP	2.0 ± 0.0	2.0 ± 0.0 ^c	3.0 ± 0.0	0.5 ± 0.58 ^c
CD3	1.5 ± 0.58	1.5 ± 0.58	0.5 ± 0.58 ^c	0.0 ± 0.0 ^c
Trial 5 with MWT				
NeuN	3.0 ± 0.0 ^{b,c}	2.5 ± 0.58 ^{b,c}	0.0 ± 0.5 ^c	0.0 ± 0.5 ^c
GFAP	2.5 ± 0.58 ^c	2.5 ± 0.58 ^c	2.5 ± 0.58 ^c	0.0 ± 0.0 ^c
CD3	1.5 ± 0.58	1.5 ± 0.58	0.0 ± 0.0 ^c	0.0 ± 0.0 ^c

NeuN, neuronal nuclear antigen; GFAP, glial fibrillary acidic protein; MWT, microwave treatment.

^aStandard deviation.

^bSignificant difference between with MWT and without MWT.

^cNo significant difference compared to trial 6.

(GFAP: score 1.5 ± 0.58) (Figure 2A; Table 3). For GFAP only, a background with brownish, cloudy, sometimes flocculent low-intensity staining was evident in all specimens (4/4) (Table 3). However, this background did not interfere with the distinctive staining of astrocyte somata. Regarding the subcellular distribution of ICC on these plain slides, the CD3 signal was strongest in the periphery of the lymphocyte cytoplasm close to the membrane. NeuN immunoreactivity was restricted to neuronal nuclei, while GFAP diffusely stained the soma and fragmented processes of astrocytes.

Even after coverslipping and decoverslipping (CDC only, trial 5), ICC permitted the identification of all three cell types (Figure 2B). However, both the staining intensity and cell specificity of the CD3 and NeuN specimens were significantly lower than those observed in trial 6 ($P \leq 0.04$), while GFAP background staining was stronger ($P = 0.02$) (Tables 3 and 4).

The SDS (trial 3) did not interfere with immunolabeling if ICC was performed within a few days after the Romanowsky staining. However, a delay of 1-2 weeks abolished immunolabeling significantly (Figure 2C). Hence, the detectability of all markers was severely compromised (cell specificity: $P = 0.013$; intensity: $P \leq 0.019$) (Tables 3 and 5). Weak cellular staining was seen in isolated lymphocytes and astrocytes only, while the majority of cells in all specimens remained immunonegative.

Early coverslipping of modWS-stained specimens (trials 2 and 4) rescued the antigenicity of all three antigens compared with the pre-stained, noncoverslipped slides in trial 3 (intensity and cell specificity: $P < 0.001$) (Figure 2D; Tables 5 and 6). A specific signal was obtained on these slides, with a median signal intensity (SI) of 1.0-1.5 (Table 6). Nonspecific background staining was restricted mostly to GFAP slides (10/10) but remained distinct from cellular chromagen enrichment, as seen in Figure 2D (Table 6). Notably, SDS/CDC affected the subcellular distribution of immunostaining; the CD3 signal extended throughout the lymphocyte cytoplasm rather than accentuating the periphery, while GFAP staining in astrocytes leaked into the nucleus. NeuN staining was still mainly confined to neuronal

TABLE 5 The median scores of trial 3 with and without microwave treatments

Antibody	Cell specificity	Intensity	Background	Nonspecific staining
Trial 3				
NeuN	0.0 ± 0.0 ^a	0.0 ± 0.0	0.0 ± 0.0 ^b	0.0 ± 0.0 ^b
GFAP	0.0 ± 0.0	0.0 ± 0.0	2.5 ± 0.58 ^b	0.0 ± 1.0 ^b
CD3	0.0 ± 0.0	0.0 ± 0.0	0.5 ± 0.58 ^b	0.0 ± 0.0 ^b
Trial 3 with MWT				
NeuN	0.5 ± 0.58	0.5 ± 0.58	0.0 ± 0.5 ^b	0.0 ± 0.5 ^b
GFAP	0.0 ± 0.0	0.0 ± 0.0	2.0 ± 0.0 ^b	0.0 ± 0.5 ^b
CD3	1.0 ± 0.82	1.0 ± 0.5	0.5 ± 0.58 ^b	0.0 ± 0.5 ^b

NeuN, neuronal nuclear antigen; GFAP, glial fibrillary acidic protein; MWT, microwave treatment. There was no significant difference.

^aStandard deviation.

^bNo significant difference compared to trial 6.

TABLE 6 The median scores of trials 2/4 with and without microwave treatments

Antibody	Cell specificity	Intensity	Background	Nonspecific staining
Trial 2/4				
NeuN	1.0 ± 0.0 ^{a,b}	1.0 ± 0.0 ^b	0.0 ± 0.0 ^c	0.0 ± 0.35 ^c
GFAP	1.0 ± 1.03 ^b	1.5 ± 0.99 ^{b,c}	3.0 ± 0.46	0.0 ± 0.76 ^c
CD3	1.0 ± 0.46 ^b	1.0 ± 0.46 ^b	0.5 ± 0.53 ^{b,c}	0.0 ± 0.35 ^c
Trial 2/4 with MWT				
NeuN	3.0 ± 0.0 ^c	3.0 ± 0.46 ^c	0.0 ± 0.52 ^c	0.0 ± 0.0 ^c
GFAP	3.0 ± 0.0 ^c	3.0 ± 0.35	3.0 ± 0.0	1.0 ± 0.76 ^c
CD3	3.0 ± 0.46 ^c	2.0 ± 0.52 ^c	0.0 ± 0.0 ^c	0.0 ± 0.46 ^c

NeuN, neuronal nuclear antigen; GFAP, glial fibrillary acidic protein; MWT, microwave treatment.

^aStandard deviation.

^bSignificant difference between with MWT and without MWT.

^cNo significant difference compared to trial 6.

nuclei; however, the signal was patchy and did not encompass the entire nuclear area (Figure 2D).

“Hot mount” coverslipping did not have an impact on the ICC results ($P = \geq 0.47$), while MWT in citrate buffer significantly increased the SI and cell specificity of all markers ($P \leq 0.03$, Figure 2E) (Table 6). Therefore, the negative effects of SDS were exacerbated for all markers, and the GFAP immunostaining in trial 4 became even stronger than that on plain slides (CD3, SI, $P = 0.06$, CSS, $P = 0.4$; NeuN, SI, $P = 0.5$, CSS, $P = 1.0$; GFAP, SI, $P = 0.007$, CSS, $P = 1.0$).

The positive effect of MWT was restricted to coverslipped slides. The omission of coverslipping in trial 3 failed to rescue antigenicity.

3.2 | Study B—FCoV antigen

All types of chemical pretreatments (trials 3, 4, and 5) completely abolished immunostaining of the FCoV nucleocapsid (Figure 3A and B; Table 7). Therefore, in contrast to the immunodetection of cellular




FIGURE 3 Impact of pretreatments on immunocytochemistry (ICC) to detect feline coronavirus (FCoV) antigens. Counterstaining with Mayer's hematoxylin. A, Only direct ICC of unstained slides allowed reliable immunodetection (blue arrow). All other physicochemical maneuvers carried out on unstained slides completely abolished FCoV immunoreactivity. B, The same results were obtained with panoptic staining, bleaching, coverslipping, and decoverslipping. Even microwave treatment failed to rescue the antigenicity

TABLE 7 The median scores of with different pretreatments for feline coronavirus antigen detection

	Cell specificity	Intensity	Background	Nonspecific staining
Trial 6	3.0 ± 0.0 ^a	2.0 ± 1.0	0.0 ± 0.0	0.0 ± 0.0
Trial 6 with MWT	0.0 ± 1.73	0.0 ± 0.58	0.0 ± 0.0	0.0 ± 0.0
Trial 5	0.0 ± 0.0	0.0 ± 0.0	1.0 ± 0.58	0.0 ± 0.58
Trial 5 with MWT	0.0 ± 0.0	0.0 ± 0.0	1.0 ± 0.58	0.0 ± 1.15
Trial 4	0.0 ± 0.0	0.0 ± 0.0	0.0 ± 0.0	0.0 ± 0.0
Trial 4 with MWT	0.0 ± 0.0	0.0 ± 0.0	1.0 ± 0.58	0.0 ± 0.0
Trial 3	0.0 ± 0.0	0.0 ± 0.0	0.0 ± 0.0	0.0 ± 0.0
Trial 3 with MWT	0.0 ± 0.0	0.0 ± 0.0	0.0 ± 0.0	0.0 ± 0.0

MWT, microwave treatment.

^aStandard deviation.

antigens, coverslipping did not protect viral antigenicity on stained slides (Table 7). Likewise, MWT precluded immunostaining on plain slides from trial 6 and, hence, failed to rescue antigen labeling on the pretreated slides.

4 | DISCUSSION

According to the ROSE concept (Rapid On-Site Evaluation), cytologic examination is a valuable tool for establishing a definitive tissue diagnosis in practice and can complement histologic studies by revealing previously unrecognized features.^{1,26} There is, however, an enormous demand for more specific diagnoses to confirm or specify atypical and rare infections or undifferentiated neoplasia.^{2,4,27} Special stains are recommended to be performed in parallel with routine Romanowsky-stained smear evaluations using separate unstained smears.^{2,28} In clinical settings, however, exploitation of available tests is often limited by a paucity of slides, poor sample preservation, low cellularity, blood

contamination, and differences in yield and cell composition among consecutive samples.^{2,29,30} These limitations are most relevant in poorly accessible tissues (eg, CNS) and media (CSF, pericardial effusion), and with procedures that inflict high procedural morbidity (eg, involving the heart, lungs, CNS). The diagnostician often must cope with single-slide scenarios, in which sequential tests carried out on the same slides could provide subcellular, molecular, or metabolic details in the context of the sample type.²

Ideally, the best cytologic samples, exhibiting conspicuous changes, should be subjected to additional testing. In this way, the cytologic context is preserved, and the information is not obscured by concomitant, nonrelevant cells such as contaminating blood cells.

Previous studies and case reports have demonstrated the feasibility of subjecting cytologic, histologic, and histochemically stained slides, and immunocytochemistry and in situ hybridization procedures, to second analyses.^{1,11–13} These studies were mainly carried out after the removal of previous dyes by alcohol, bleaching with hydrogen chloride, or applying MWTs in citrate buffer and distilled water.^{2,14,31}

Only a few investigators have performed direct immunolabeling of nuclear, cytoplasmic, and membranous antigens in neoplastic tissue smears previously stained with Papanicolaou, May-Grünwald Giemsa, and Diff-Quick stains that were not subjected to stain removal procedures.^{1,11,13,15,16} Romanowsky stains bind to cell components by electrostatic forces without causing conformational changes in the target epitopes.^{1,32} Thus, May-Grünwald Giemsa/Pappenheim, Hemacolor, Diff-Quick and, as seen in this study, modified Wright stains, exhibit a low risk of interference with immunodetection methods.^{1,11,13,14,32,33} It appears, however, that the lag period between cytologic staining and immunolabeling is a critical determinant. Published PSICC studies have documented successful immunostaining after a time period of as much as 10 years. Notably, all of these slides were coverslipped between the cytologic staining and the ICC procedures.^{13,14} Even in the absence of cytologic staining, antigenicity, and therefore, immunoreactivity have been reported to decrease after 4 weeks without coverslipping.³⁴ If longer preservation is needed, it has been recommended to store the slides at -70°C .^{35,36}

Now, as seen in this study, even cytologic staining appears to accelerate the decay of immunoreactivity. After only 1 week, immunopositivity for cellular markers decreased significantly. Similar to the experiments mentioned above, immediate coverslipping shielded vulnerable stained films from detrimental environmental factors. In this study, we showed that the decay of antigenicity was directly associated with exposure to dye and not with the destaining procedure compared with unstained coverslipped slides.

Without coverslipping, ionic dye components appear to facilitate cellular biomolecule degradation by oxidative stress and other less known pathways.³⁷ If a slide was sealed under a lid using a xylene-based mounting medium, the decrease in antigenicity was significantly lower but still identifiable. However, initial immunoreactivity up to the levels of fresh plain slides could be reestablished if the previously stained slides underwent MWT in citrate buffer after decoverslipping, destaining, and rehydrating.

Traditionally, MWT is used in immunohistochemistry with formalin-fixed tissues for antigen recovery from the cross-linking of aldehyde bridges.^{37,38} Similarly, MWT has proven useful for antigen demasking in cytologic specimens after fixation with ethanol and formalin³⁷ and after cytologic staining.¹ However, MWT failed to recover viral antigen detectability in this study. Instead, MWT alone effectively abolished the immunolabeling of FCoV in untreated and unstained films; furthermore, it was not possible to reestablish immunostaining after antecedent cytologic staining and coverslipping. Thus, this FCoV epitope appears to be much more vulnerable to changes induced by physicochemical factors than the other cellular proteins investigated in this study.

Whether viral antigen preservation can be achieved by prior fixation of a smear, as described for other microbial antigens, such as Chlamydia,³⁹ is currently under investigation.

Other studies have proposed that fixation by formalin or ethanol can improve ICC results.^{1,11,13,14,26,36,37,39} Even though observations were made in a substancial number of samples in this study, our results provide evidence that viral antigen labeling in ICC can be more sensitive to interference with other laboratory procedures than cellular antigen labeling. Consequently, this liability has to be considered and tested if pathogen-specific ICC is to be carried out on sparse sample volumes.

In summary, PSICC is an easy, sensitive, reliable, and reproducible method for the immediate evaluation of selected markers in Romanowsky-stained cells. Cytologic staining, on the other hand, can rapidly decrease antigenicity if left uncoverslipped. Any further cellular antigen decay can be counteracted by performing MWTs prior to immunolabeling.

Viral epitopes, however, might require dedicated preservation techniques. In this study, all pretreatments abolished the ICC results for FCoV detection in air-dried prestained films.

ACKNOWLEDGEMENTS

We are grateful to the head technician of our Neuropathology & Cytology Lab, Mrs. Karin Stingl, for excellent technical assistance.

DISCLOSURE

The authors have indicated that they have no affiliations or financial involvement with any organization or entity with a financial interest in, or in financial competition with, the subject matter or materials discussed in this article.

REFERENCES

1. Beraki E, Olsen TK, Sauer T. Establishing a protocol for immunocytochemical staining and chromogenic in situ hybridization of Giemsa and Diff-Quick prestained cytological smears. *Cytojournal*. 2012;9:8.
2. Marcos R, Santos M, Santos N, et al. Use of destained cytology slides for the application of routine special stains. *Vet Clin Pathol*. 2009;38:94-102.

3. McKee PH. Immunocytochemistry and cutaneous neoplasia ('something will turn up', Micawber 1863). *Clin Exp Dermatol*. 1990;15:235-244.
4. Mandal PK, Mondal SK, Roy S, Adhikari A, Basu N, Sinha SK. Immunocytochemistry: It's role in diagnosis of undifferentiated neoplasms by fine needle aspiration cytology. *J Cytol*. 2013;30:121-124.
5. Dalquen P, Sauter G, Epper R, Kleiber B, Feichter G, Gudat F. Immunocytochemistry in diagnostic cytology. *Recent Results Cancer Res*. 1993;133:47-80.
6. Höinghaus R, Hewicker-Trautwein M, Mischke R. Immunocytochemical differentiation of neoplastic and hyperplastic canine epithelial lesions in cytologic imprint preparations. *Vet J*. 2007;173:79-90.
7. Mason DY, Gatter KC. The role of immunocytochemistry in diagnostic pathology. *J Clin Pathol*. 1987;40:1042-1054.
8. Ponce F, Magnol JP, Marchal T, et al. High-grade canine T-cell lymphoma/leukemia with plasmacytoid morphology: a clinical pathological study of nine cases. *J Vet Diagn Invest*. 2003;15:330-337.
9. Gründl S, Matiasek K, Matiasek L, et al. Diagnostic utility of cerebrospinal fluid immunocytochemistry for diagnosis of feline infectious peritonitis manifesting in the central nervous system. *J Feline Med Surg*. 2017;19:576-585.
10. Ives EJ, Vanhaesebrouck AE, Cian F. Immunocytochemical demonstration of feline infectious peritonitis virus within cerebrospinal fluid macrophages. *J Feline Med Surg*. 2013;15:1149-1153.
11. Corkill ME, Katz R. Immunocytochemical staining of c-erb B-2 oncogene in fine-needle aspirates of breast carcinoma: a comparison with tissue sections and other breast cancer prognostic factors. *Diagn Cytopathol*. 1994;11:250-254.
12. Iwa N, Yutani C, Ishibashi-Ueda H, Katayama Y. Immunocytochemical demonstration of glial fibrillary acidic protein in imprint smears of human brain tumors. *Diagn Cytopathol*. 1988;4:74-77.
13. Nordgård S, Bofin A, Hagmar B. Ki-67 antigen detection in unstained and destained cytological samples. *Ana Quant Cytol Histol*. 2002;24:198-204.
14. Shtilbans V, Szporn AH, Wu M, Burstein DE. p63 immunostaining in destained bronchoscopic cytological specimens. *Diagn Cytopathol*. 2005;32:198-203.
15. Choi US, Kim DY. Immunocytochemical detection of KI-67 in Diff-Quick-stained cytological smears of canine mammary gland tumours. *Cytopathology*. 2011;22:115-120.
16. Kirbis IS, Flezar MS, Krasovec MU. MIB-1 immunostaining on cytological samples: a protocol without antigen retrieval. *Cytopathology*. 2004;15:154-159.
17. Abendroth CS, Dabbs DJ. Immunocytochemical staining of unstained versus previously stained cytologic preparations. *Acta Cytol*. 1995;39:379-386.
18. Oza N, Sanghvi K, Shet T, et al. Mammary analogue secretory carcinoma of parotid: Is preoperative cytological diagnosis possible? *Diagn Cytopathol*. 2016;44:519-525.
19. Kim DH, Kwon MS. Role of fine needle aspiration cytology, cell block preparation and CD63, P63 and CD56 immunostaining in classifying the specific tumor type of the lung. *Acta Cytol*. 2010;54:55-59.
20. Cheng L, Reiter RE, Jin Y, et al. Immunocytochemical analysis of prostate stem cell antigen as adjunct marker for detection of urothelial transitional cell carcinoma in voided urine specimens. *J Urol*. 2003;169:2094-2100.
21. Darvishian F, Stier EA, Soslow RA, Lin O. Immunoreactivity of p16 in anal cytology specimens: histologic correlation. *Cancer*. 2006;108:66-71.
22. Zhang L, Krausz T, DeMay RM. A pilot study of Galectin-3, HBME-1, and p27 triple immunostaining pattern for diagnosis of indeterminate thyroid nodules in cytology with correlation to histology. *Appl Immunohistochem Mol Morphol*. 2015;23:481-490.
23. Cajulis RS, Szumel R, Frias-Hidvegi D, Combs SG, Radosevich JA. Monoclonal antibody 44-3A6 as an adjunct in cytodiagnosis of adenocarcinomas in body fluids. *Diagn Cytopathol*. 1993;9:179-183.
24. Dabbs DJ, Wang X. Immunocytochemistry on cytologic specimens of limited quantity. *Diagn Cytopathol*. 1998;18:166-169.
25. Matiasek K, Pumarola M, Rosati M, et al. International Veterinary Epilepsy Task Force recommendations for systematic sampling and processing of brains from epileptic dogs and cats. *BMC Vet Res*. 2015;28:216.
26. Wünsche S, Rosati M, Matiasek K. Diagnostic yield and accuracy of postmortem cytological sampling from the brain surface of animals with neurological abnormalities. *Vet J*. 2016;211:57-63.
27. Grahn B, Peiffer R, Cullen C, Haines D. Classification of feline intraocular neoplasms based on morphology, histochemical staining, and immunohistochemical labelling. *Vet Ophthalmol*. 2006;9:395-403.
28. Lumsden JH, Baker R. Cytopathology techniques and interpretation. In: Baker R, Lumsden JH, eds. *Color Atlas of Cytology of the Dog and Cat*, 1st edn. St. Louis, MO: Mosby; 2000:7-20.
29. Meinkoth JH, Cowell RL. Sample collection and preparation in cytology: increasing diagnostic yield. *Vet Clin North Am Small Anim Pract*. 2002;32:1187-1207.
30. Tyler RD, Cowell RL, Baldwin CJ, Morton RJ. Introduction. In: Cowell RL, Tyler RD, Meinkoth JH, eds. *Diagnostic Cytology and Hematology of the Dog and Cat*, 2nd edn. St. Louis, MO: Mosby; 1999:1-19.
31. Chen JT, Lane MA, Clark DP. Inhibitors of the polymerase chain reaction in Papanicolaou stain. Removal with a simple destaining procedure. *Acta Cytol*. 1996;40:873-877.
32. Jörundsson E, Lumsden JH, Jacobs RM. Rapid staining techniques in cytopathology: a review and comparison of modified protocols for hematoxylin and eosin, Papanicolaou and Romanowsky stains. *Vet Clin Pathol*. 1999;28:100-108.
33. Howat WJ, Wilson BA. Tissue fixation and the effect of molecular fixatives on downstream staining procedures. *Methods*. 2014;70:12-19.
34. Aoki J, Sasaki N, Hino N, Nanba K. A study on the appropriate fixation for the procedures for the better preservation of cellular antigenicity and morphology of the blood smear in immunocytochemistry: an improvement of the immunostain technique using alkaline-phosphatase (ALP) as a labeling enzyme. *Rinsho Ketsueki*. 1991;32:11-18.
35. Skoog L, Tani E. Immunocytochemistry: an indispensable technique in routine cytology. *Cytopathology*. 2011;22:215-229.
36. Suthipintawong C, Leong A, Vinyuvat S. Immunostaining of cell preparations: a comparative evaluation of common fixatives and protocols. *Diagn Cytopathol*. 1996;15:167-174.
37. Ramos-Vara JA, Miller MA. When tissue and antibodies get along: revisiting the technical aspects of immunohistochemistry – the red, brown, and blue technique. *Vet Pathol*. 2014;51:42-87.
38. Shi SR, Cote RJ, Taylor CR. Antigen retrieval techniques: current perspectives. *J Histochem Cytochem*. 2001;49:931-937.
39. Demirezen S, Kakudo K, Kawashima T, Katsuoka Y, Osamura RY. Immunocytochemical detection of Chlamydia trachomatis on cytological specimens. *Tokai J Exp Clin Med*. 1986;11:229-234.

How to cite this article: Dörfelt S, Matiasek LA, Felten S, Sangl L, Hartmann K, Matiasek K. Antigens under cover—The preservation and demasking of selected antigens for successful poststaining immunocytochemistry of effusion, brain smears, and lymph node aspirates. *Vet Clin Pathol*. 2019;48(Suppl. 1):98–107. <https://doi.org/10.1111/vcp.12702>