

CT imaging findings and endovascular management of isolated spontaneous dissecting aneurysm of celiac artery

Rama Krishnan RS, Murali K, Madan R, Francis G

Department of Radiology, MIOT Hospitals, Chennai, India

Correspondence: Dr. Rama Krishnan RS, Department of Radiology, MIOT Hospitals, Chennai - 69, India. E-mail: drramki27@gmail.com

Abstract

Isolated spontaneous dissecting aneurysm of celiac artery without concomitant involvement of aorta is a rare entity and only a few cases are reported in the literature. More cases are being detected recently with greater advancements in CT technology. Clinicians and emergency physicians should be aware of this condition and should include it in the differential diagnosis of patients who present with refractory postprandial epigastric pain, particularly in middle-aged men. We present a case of a 45-year-old male with isolated spontaneous dissecting celiac artery aneurysm, with special emphasis on CT findings and the role of endovascular management.

Key words: Aneurysm; celiac artery; dissection

Introduction

Symptomatic celiac artery dissection without concomitant involvement of aorta is an unusual event. This should be considered in the differential diagnosis of middle-aged men who present in the emergency room with refractory postprandial epigastric pain.^[1,2] Contrast-enhanced CT is the modality of choice because of its easy availability, quickness, less invasiveness, and reliability.^[3] The optimal treatment has not been established but may involve simple surveillance, medical treatment, and surgical or endovascular repair depending on the clinical features.^[4] We present a case of a 45-year-old male with isolated spontaneous dissecting aneurysm of celiac artery detected by CT scan taken during admission and successfully treated with endovascular embolization.

Case Report

A 45-year-old man presented to our emergency department with sudden onset of sharp epigastric pain. He gave history of hospital admission elsewhere, 6 months back for similar complaint. Upper gastrointestinal (GI) endoscopy performed at that time revealed peptic ulcer, and since then, he had been on antacids. His medical history was also remarkable except for uncontrolled hypertension. At presentation, his blood pressure was 180/100 mm Hg. Routine blood tests and basic metabolic profile including liver, cardiac enzymes, and serum amylase/lipase levels were normal. Emergency ultrasound performed on him did not reveal any significant abnormality. So, a biphasic contrast-enhanced CT of the abdomen was performed on a GE Light Speed Discovery 750 HD, 64-slice scanner, using oral contrast and 80 ml of non-ionic iodinated contrast material 350 mg I/ml, injected at the rate of 3 ml/s. Arterial phase images of the upper abdomen were obtained using smart prep technique followed by portal venous phase acquisition of whole abdomen at 50 s from the start of contrast injection.

The CT study revealed celiac artery aneurysm of 1.4 cm, approximately 0.8 cm from its origin with focal dissection as evidenced by true lumen and thrombosed false lumen. The caliber of the true lumen was severely

Access this article online

Quick Response Code:



Website:
www.ijri.org

DOI:
10.4103/0971-3026.120275

compromised [Figures 1 and 2]. Distal propagation of the dissection and mural thrombus into the ostia-proximal hepatic and splenic arteries was seen which were occluded. The left gastric artery was originating from the celiac axis, proximal to the dissecting aneurysm and was normal. Replaced left hepatic artery from left gastric artery was seen as a normal variant. Fat infiltration was seen surrounding the celiac axis and proximal hepatic and splenic arteries [Figure 2B]. This finding is a sign of dissection acuity and indicates predisposition toward progressive extension of dissection into adjacent vessels. The abdominal aorta and its other major branches were normal with no stenosis or aneurysm or dissection. There was no evidence of organ or bowel infarction. Subsequent Digital subtraction angiogram performed with therapeutic intent confirmed the CT findings [Figure 3]. Also, superior mesenteric artery injection showed retrograde filling of the hepatic and splenic arteries via the anterior, posterior

pancreaticoduodenal arcades and the gastroduodenal artery [Figure 4].

Severe abdominal pain present in spite of good collateral flow indicates dissection to be the cause of pain, rather than intestinal ischemia. Also, in view of peri-celiac fat infiltration on CT and the complicating aneurysm with inherent potential risk of rupture, it was decided to treat him either with endovascular stent grafting or coil embolization. Stent grafting can be done if there is good landing zone of 2 cm on either side of the aneurysm. In our case, stent graft would have compromised the flow through the left gastric artery originating just proximal to the aneurysm. Also, in view of the good collateral flow to the hepatic and splenic arteries from superior mesenteric artery, it was decided to occlude the aneurysm distal to left gastric origin to prevent rebleed. Transarterial embolization was performed and the aneurysm was packed with detachable micro coils (Covidien, Ireland). Post coil embolization angiogram [Figure 5] showed that the parent artery was obliterated except for its proximal portion with left gastric origin and that the intrahepatic branches were supplied through collateral pathways and the replaced left hepatic artery. His initial pain subsided gradually, and he was symptom free during discharge.

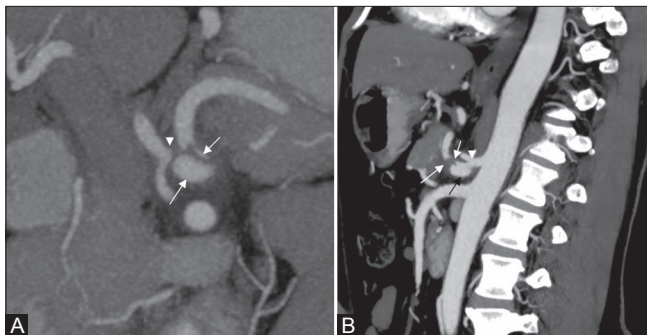


Figure 1 (A, B): Dissecting celiac artery aneurysm. (A) CT oblique coronal MIP image shows celiac aneurysm (large white arrow) with true lumen (small white arrow) and thrombosed false lumen (arrow head) occluding the proximal splenic, hepatic arteries. (B) Sagittal CT MIP image shows celiac aneurysm (black arrow) with compromised true lumen (small white arrow) and thrombosed false lumen (large white arrow). The left gastric origin (arrow head) is appreciated proximal to the aneurysm

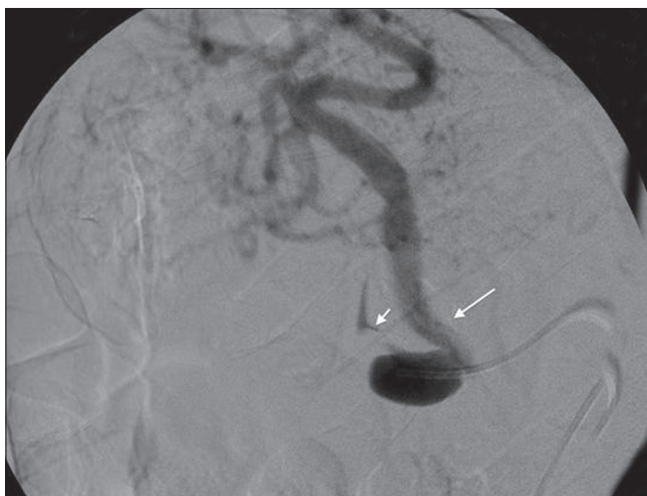

Figure 3: Dissecting celiac artery aneurysm. DSA image shows celiac aneurysm with compromised true lumen (small arrow). Left gastric artery (large arrow) is originating proximal to the dissecting aneurysm

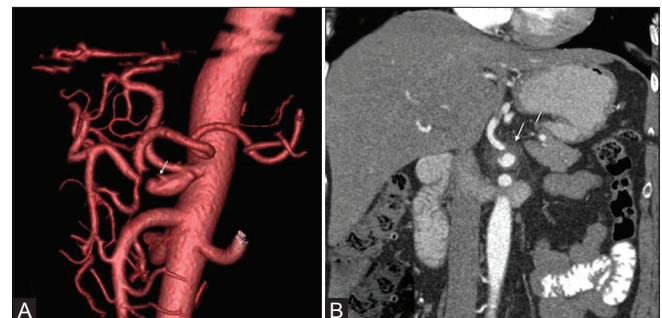


Figure 2 (A, B): Dissecting celiac artery aneurysm. (A) CT 3D VR image shows celiac aneurysm with true lumen (arrow) and occluded proximal splenic, hepatic arteries. (B) Coronal CT shows peri-celiac fat infiltration (arrow)

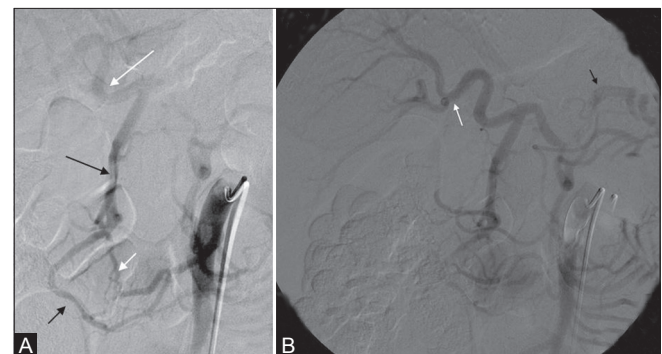


Figure 4 (A, B): (A) SMA injection shows retrograde filling of the right hepatic artery (large white arrow) via the anterior (small white arrow), posterior (small black arrow) pancreaticoduodenal arcades and the gastroduodenal artery (large black arrow). (B) DSA image shows good filling of the hepatic (white arrow) and splenic (black arrow) arteries by collateral pathway

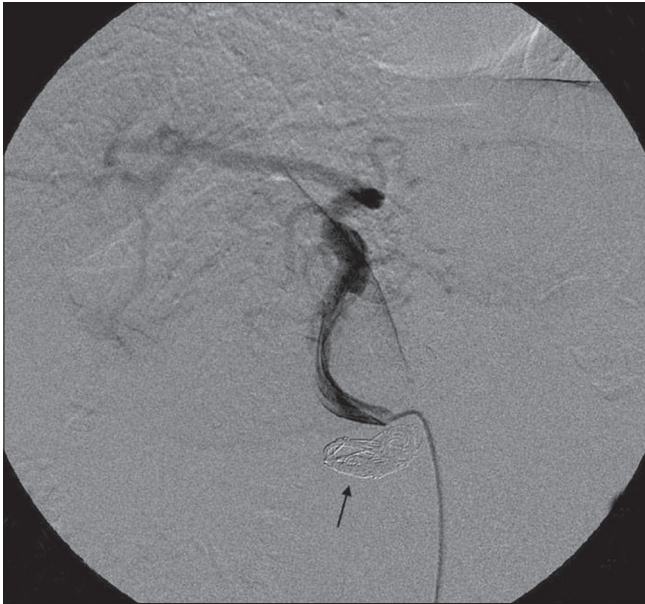

Figure 5: Post coil embolisation of the celiac artery aneurysm with preservation of flow in the left gastric artery

Discussion

Spontaneous dissecting celiac artery aneurysm without concomitant involvement of aorta is an uncommon event.^[1,2,5] A standard search made on Medline database reveals less than 25 cases of isolated celiac artery dissection with aneurysm.^[1,3,5-10] But with recent advancements in CT technology, more cases are being detected frequently.^[5]

Most patients with celiac artery dissection are asymptomatic, probably due to lack of small bowel involvement. Symptomatic patients, usually middle-aged men,^[5] commonly present in the emergency room with acute abdominal pain.^[1] Some patients have chronic dyspepsia, weight loss, and postprandial abdominal pain, likely due to intestinal angina.^[11] Patients with ruptured aneurysm can present acutely with bleeding and abdominal pain.^[4] The common risk factors include hypertension, cystic medial necrosis, abdominal aortic aneurysm, fibromuscular dysplasia, trauma, pregnancy, and connective tissue disorders. However, no underlying cause or risk factor may be identified in several cases.^[1,2]

CT angiography is the primary imaging modality of choice because of its easy availability, quickness, less invasiveness, and reliability. Magnetic resonance (MR) angiography, Doppler sonography, and conventional angiography are the other modalities that can be used.^[3] Visualization of intimal flap on CT is the pathognomonic finding. Sometimes, as in our case, eccentric mural thrombus may be the only finding which is suspicious for dissection.^[1] Presence of isolated eccentric mural thrombus without intimal flap can be wrongly interpreted as thromboembolic occlusion and may result in unnecessary pharmacologic thrombolysis.^[12]

CT can also show associated complications like aneurysm, hemorrhage, branch vessel involvement, and bowel/organ infarction. Fat infiltration surrounding the celiac axis, as seen in our case, is a sign of dissection acuity and is more common in symptomatic population.^[1,6] Also, this finding indicates predisposition toward extension of dissection into adjacent vessels.^[1]

The natural progression of spontaneous dissecting celiac artery aneurysm is unclear. Aneurysm rupture with intraperitoneal bleeding, distal propagation of dissection with branch vessel involvement, end-organ infarctions, and intestinal ischemia are some of the serious complications on follow-up.^[5]

Management of spontaneous dissecting celiac artery aneurysm should be a case-based approach. Conservative medical management, surgical and endovascular techniques are the treatment options available. The appropriate treatment option should be chosen based on the severity of the dissection, presence of associated complications, status of collateral pathways, patient's hemodynamic status, and the surgeon's expertise.^[13] Conservative medical management using anticoagulative, antiplatelet, and antihypertensive therapy may be advocated in some asymptomatic uncomplicated cases.^[5] Routine follow-up CT angiography should be performed in incidentally detected cases in which only medical management is planned.^[5,14] Surgery or endovascular interventions are recommended when a patient in hemodynamically unstable condition has persistent abdominal pain, when medical therapy fails to control blood pressure/symptoms, and when dissection is progressive.^[15] In view of having relatively fewer complications, endovascular treatment is fast replacing surgery as the preferred treatment option. However, there is no sufficient literature data to support this. Both stent grafting and endovascular coil embolization^[10,16,17] are described in literature. Surgery should be advocated for lesions that are inaccessible through an endovascular approach or for patients in whom angiography is contraindicated.^[5]

Conclusion

Isolated spontaneous celiac artery dissection, though rare, is now being detected frequently with major advancements in CT technology. Clinicians should be aware of this condition and should include it in the differential diagnosis of cases with refractory postprandial epigastric pain, particularly in middle-aged men.

References

1. D'Ambrosio N, Friedman B, Siegel D, Katz D, Newatia A, Hines J. Spontaneous isolated dissection of the celiac artery: CT findings in adults. *AJR Am J Roentgenol* 2007;188:W506-11.
2. Ozturk TC, Yaylaci S, Yesil O, Cevik SE, Guneysele O. Spontaneous isolated celiac artery dissection. *J Res Med Sci* 2011;16:699-702.

3. Takayama T, Miyata T, Shirakawa M, Nagawa H. Isolated spontaneous dissection of the splanchnic arteries. *J Vasc Surg* 2008;48:329-33.
4. Vaidya S, Dighe M. Spontaneous celiac artery dissection and its management. *J Radiol Case Rep* 2010;4:30-3.
5. Obon-Dent M, Shabaneh B, Dougherty KG, Strickman NE. Spontaneous celiac artery dissection Case report and literature review. *Tex Heart Inst J* 2012;39:703-6.
6. Jung SC, Lee W, Park EA, Jae HJ, Chung JW, Park JH. Spontaneous dissection of the splanchnic arteries: CT findings, treatment, and outcome. *AJR Am J Roentgenol* 2013;200:219-25.
7. Mousa AY, Coyle BW, Affuso J, Haser PB, Vogell TR, Graham AM. Nonoperative management of isolated celiac and superior mesenteric artery dissection: Case report and review of literature. *Vascular* 2009;17:359-64.
8. Glehen O, Feugier P, Aleksic Y, Delannoy P, Chevalier JM. Spontaneous dissection of the celiac artery. *Ann Vasc Surg* 2001;15:687-92.
9. Matsuo R, Ohta Y, Ohya Y, Kitazono T, Irie H, Shikata T *et al.* Isolated dissection of the celiac artery – a case report. *Angiology* 2000;51:603-7.
10. Batt M, Baque J. Successful percutaneous embolisation of a symptomatic celiac artery dissection with aneurysm dilation with detachable vascular plugs. *J Vasc Surg* 2011;54:1812-5.
11. Glehen O, Feugier P, Aleksic Y, Delannoy P, Chevalier JM. Spontaneous dissection of the celiac artery. *Ann Vasc Surg* 2001;15:687-92.
12. Kim JH, Roh BS, Lee YH, Choi SS, So BJ. Isolated spontaneous dissection of the superior mesenteric artery: Percutaneous stent placement in two patients. *Korean J Radiol* 2004;5:134-8.
13. Neychev V, Krol E, Dietzek A. Unusual presentation and treatment of spontaneous celiac artery dissection. *J Vasc Surg* 2013;58:491-5.
14. Takach TJ, Madjarov JM, Holleman JH, Robicsek F, Roush TS. Spontaneous splanchnic dissection: Application and timing of therapeutic options. *J Vasc Surg* 2009;50:557-63.
15. Fenoglio L, Allione A, Scalabrino E, Alberto G, Benedetti V, Pomero F, *et al.* Spontaneous dissection of the celiac artery: A pitfall in the diagnosis of acute abdominal pain. Presentation of two cases. *Dig Dis Sci* 2004;49:1223-7.
16. Abdullah MH-Wahbi. Giant celiac artery aneurysm: Treatment by transcatheter coil embolisation. *Int J Surg Case Rep* 2011;2:191-3.
17. Takeda H, Matsunaga N, Sakamoto I, Obata S, Nakamura S, Hayashi K. Spontaneous dissection of the celiac and hepatic artery treated by transcatheter embolisation. *AJR Am J Roentgenol* 1995;165:1288-9

Cite this article as: Rama Krishnan RS, Murali K, Madan R, Francis G. CT imaging findings and endovascular management of isolated spontaneous dissecting aneurysm of celiac artery. *Indian J Radiol Imaging* 2013;23:234-7.

Source of Support: Nil, **Conflict of Interest:** None declared.