



Case series

Noninvasive test for the diagnosis of ovarian hormone-secreting-neoplasm in postmenopausal women☆



Ilan Cohen^{a,*}, Dan Nabriski^b, Ami Fishman^a

^a Department of Obstetrics and Gynecology, Meir Medical Center, Kfar Saba, Israel, affiliated with Sackler Faculty of Medicine, Tel Aviv University, Israel

^b Institute of Endocrinology, Diabetes and Metabolism, Meir Medical Center, Kfar Saba, Israel, affiliated with Sackler Faculty of Medicine, Tel Aviv University, Israel

ARTICLE INFO

Article history:

Received 5 May 2015

Received in revised form 4 June 2015

Accepted 7 June 2015

Available online 10 June 2015

Keywords:

Diagnosis

Postmenopausal

Ovarian tumor

Hormone

ABSTRACT

Context: The diagnosis of ovarian hormone-secreting neoplasm in postmenopausal women is currently based on imaging modalities and selective venography. However, these diagnostic tests are not always accurate. In order to improve and simplify the diagnosis, we propose a noninvasive hormonal test.

Objective: To report our experience using noninvasive hormonal test for the diagnosis of ovarian hormone producing tumor in two postmenopausal women.

Design and intervention: Evaluation of androgen and estradiol serum levels following 1. Adrenal hormonal depression, 2. ovarian hormonal depression and 3. ovarian hormonal stimulation.

Setting: Tertiary care medical center.

Main outcome measures: Changes in androgen and estradiol levels.

Results: In the first case, total testosterone, free androgen index and estradiol serum levels decreased following ovarian depression by GnRH-antagonist (6.9 nmol/L, 67 nmol/L and <70 pmol/L, respectively) and subsequently increased after ovarian stimulation with LH (11.5 nmol/L, 117 nmol/L and 176 pmol/L, respectively). Histological evaluation revealed steroid cell tumor in one ovary. In the second case, estradiol serum levels decreased following ovarian depression by GnRH-antagonist (73 pmol/L) and subsequently increased following ovarian stimulation with FSH (118 pmol/L). Histological evaluation revealed granulosa cell tumor in one ovary.

Conclusions: To our knowledge, these are the first cases of ovarian hormone-producing tumors in postmenopausal women diagnosed by noninvasive hormonal test. The proposed test can be considered in postmenopausal women suspected of having androgen and/or estrogen producing tumors.

© 2015 The Authors. Published by Elsevier Inc. This is an open access article under the CC BY-NC-ND license (<http://creativecommons.org/licenses/by-nc-nd/4.0/>).

1. Introduction

Both functional and nonfunctional ovarian neoplasms are known to produce androgen. Androgen-secreting neoplasms of the ovary are a rare cause of androgen excess and, account for only 5% of all ovarian tumors. Most are Sertoli-Leydig cell, lipid cell, theca cell or hilus cell tumors (Lobo, 1991). Granulosa cell tumors of the ovary are rare neoplasm (Mancaux et al., 2013), estrogen-producing tumors (Geetha and Nair, 2010) and difficult to diagnose (Mancaux et al., 2013).

It is important to identify and remove these tumors. Although clinical history and baseline androgen levels may increase clinical suspicion,

localization of these tumors requires several diagnostic methods, including dynamic ovarian and adrenal assessment and diagnostic imaging (Taylor et al., 1986). However, sometimes they are very difficult to detect, and interpretation of test results can be difficult. Imaging modalities, such as magnetic resonance imaging (MRI), computerized tomography (CT) and ultrasound (US) might not identify ovarian lesions (Wang et al., 2001).

Selective venous catheterization has been recommended as an accurate method for the diagnosis and localization of androgen-secreting ovarian and adrenal tumors (Lobo, 1991; Cohen et al., 1993), especially as most ovarian androgen-producing tumors are small (Lobo, 1991) and thus, difficult to detect by imaging techniques (Sarfati et al., 2011). However, diagnostic specificity of this technique is often disappointing even in experienced hands (Sarfati et al., 2011). Moreover, in some cases, pre-operative venous sampling was attempted but not achieved, and thus venous sampling was done intra-operatively during diagnostic laparoscopy or explorative laparotomy (Kaltsas et al., 2003).

☆ Grants or fellowship supporting the writing of the paper: None

* Corresponding author at: Department of Obstetrics and Gynecology, Meir Medical Center, 50 Tschernihovsky St., Kfar Saba 44281 Israel.
E-mail address: cohen.ilan@clalit.org.il (I. Cohen).

In order to improve and simplify the diagnosis of postmenopausal hormone-producing ovarian tumors, we used a noninvasive hormonal test. In this paper, we report on our experience using this noninvasive hormonal test for the diagnosis of ovarian androgen and estrogen producing tumors in postmenopausal women.

2. Material and methods

2.1. Case 1

A 58-year-old, Caucasian, healthy, menopausal, married, gravida, 2 para 2 woman was referred to our clinic for evaluation of progressive facial hirsutism, which had appeared one year earlier. The patient did not take any medications that had androgenic side-effects and had no familial history of virilization.

On examination, her weight was 63 kg and height 160 cm. Blood pressure was normal. She had no striae or abnormal skin pigmentation. No alopecia or acne was noted. She presented with mild facial hirsutism. General physical and gynecological examinations were normal. Pelvic ultrasound revealed normal uterus, endometrial thickness was 3 mm, right ovary measured 29 * 33 mm and left ovary 20 * 22 mm, without evidence of tumor or cyst. There was no pelvic or abdominal mass. Adrenal ultrasound was normal. Computerized tomography disclosed bilateral adenoma of the adrenal glands.

Basal serum hormone levels are listed in Table 1.

A hormonal dynamic test was performed to determine the anatomical location of the suspected hormone producing tumor (Table 1, Fig. 1). The patient started daily oral dexamethasone (Rekah Pharmaceutical Industries Ltd., Holon, Israel) 1 mg per day. Seven days later, hormonal blood sample was taken at 8:00 A.M. Immediately after, the patient received one subcutaneous injection of GnRH antagonist (0.25 cetrorelix (Merck Serono S.A. Switzerland)). A day later, a second hormonal blood sample was performed at 8:00 A.M. Immediately after, the patient received one subcutaneous injection of 250 microgram chorionadotropin alpha (Merck Serono S.A. Switzerland). A day later (on day 9), a third hormonal blood sample was taken at 8:00 A.M., and dexamethasone was discontinued.

A flow chart of the dynamic hormonal changes was drawn and the anatomical location of the androgen overproduction was diagnosed (Table 1). Based on the hormonal results indicating the presence of ovarian androgen producing tumor, laparoscopic bilateral salpingo-oophorectomy was performed. Histological evaluation revealed steroid cell tumor in the right ovary. Left ovary and both fallopian tubes were unremarkable. Preoperative and postoperative hormonal values are listed in Table 1.

2.2. Case 2

A 58-year-old, Caucasian, menopausal, married, gravida 2, para 2 woman was referred to our clinic for evaluation of breast engorgement

and an episode of postmenopausal bleeding. Two years ago, the patient had coronary catheterization with insertion of coronary stents. The patient had hypertension and was treated with bisoprolol fumarate 2.5 mg per day, rosuvastatin 20 mg per day, clopidogrel 75 mg per day and valsartan hydrochloride 160/25 mg per day.

On vaginal ultrasound evaluation, the uterus had normal dimensions, and endometrial thickness was 9.5 mm. A right ovarian cyst 34 * 30 * 30 mm with small hypercogenic imprints was noted. Doppler blood flow was normal (RI = 0.34 and 0.4). The left ovary was normal. Endometrial biopsy revealed endometrial hyperplasia without atypia.

Adrenal ultrasound was normal. Carcinoma antigen 125 was within normal limits (13.78 U/ml). Hormonal evaluation revealed high estradiol levels, with no other hormonal abnormality (Table 2).

A hormonal dynamic test was then performed to determine the anatomic location of the suspected hormone producing tumor (Table 2, Fig. 2). The patient started daily oral dexamethasone (Rekah Pharmaceutical Industries Ltd., Holon, Israel) 1 mg per day. Seven days later, hormonal blood sample was taken at 8:00 A.M. Immediately after, the patient received one subcutaneous injection of GnRH – antagonist 0.25 cetrorelix (Merck Serono S.A. Switzerland). A day later, a second hormonal blood sample was performed at 8:00 A.M. Immediately after, the patient received one subcutaneous injection of 75 µg follitropin alpha (Merck Serono S.A. Switzerland). A day later (day 9), a third hormonal blood sample was taken at 8:00 A.M. and dexamethasone was discontinued.

A flow chart of the dynamic hormonal changes was drawn and the anatomical location of the estrogen overproduction was diagnosed (Table 2).

Based on the hormonal results, indicating the presence of ovarian estrogen producing tumor, laparoscopic bilateral salpingo-oophorectomy was performed. Histological evaluation revealed adult type granulosa cell tumor in the right ovary. The left ovary and both fallopian tubes were unremarkable. Preoperative and postoperative hormonal values are listed in Table 2.

3. Discussion

Detection of postmenopausal high androgen or estrogen production requires identification of the exact anatomic location of the hormone-producing tissue, before performing a surgical procedure to remove the pathological tissue. Although diagnostic imaging is recommended (Taylor et al., 1986), sometimes it is very difficult to detect and interpret test results. Imaging modalities, such as magnetic MRI, CT and US, might not identify ovarian lesions (Wang et al., 2001).

Selective venous catheterization has been recommended as an accurate method for the diagnosis and localization of hormone-secreting ovarian and adrenal tumors (Lobo, 1991; Cohen et al., 1993). However, diagnostic specificity of this technique is often disappointing even in experienced hands (Kaltsas et al., 2003), and in some cases pre-operative venous sampling was attempted but not achieved (Kaltsas et al., 2003).

Table 1

Basal hormone values, hormone levels throughout the 9-day dynamic hormonal test and postoperative hormonal values (patient 1)

Day	0	1–9	7	8	9	Post-operative
Medications and procedures	Basal hormone values	Dexa 1.0 mg daily	Blood test, GnRH-antagonist 250 µg	Blood test, LH 5000 IU	Blood test	
Hormone levels (normal range)						
SHBG (18–144 nmol/L)	49	–	38	35	34	
DHEAS (0.9–11.6 µmol/L)	2.71	–	1.25	1.1	1.38	2.1
Androstenedione (0.48–10.07 nmol/L)	5.21	–	1.6	0.52	0.7	4.76
Cortisol (nmol/L) (138–690)	314					
17 OHP (0.6–5.2 nmol/L)	2.31	–	0.8	0.6	1.5	1.55
Total testosterone (nmol/L) (0.9–2.6)	8.2	–	9.2	6.9	11.5	1.1
SHBG (nmol/L) (18–44)	49					
Free androgen index (0.2–12.0 nmol/L)	69	–	84	67	117	2.2
Estradiol (<70 pmol/L)	71	–	88	70>	176	

Dexa = dexamethasone; SHBG = sex hormone binding globulin; DHEAS = dehydroepiandrosterone sulfate; 17 OHP = 17 hydroxyprogesterone. Bold text indicates abnormal values.




Fig. 1. Algorithm of the 9-day dynamic LH hormonal test protocol (patient 1).

Moreover, this procedure is invasive and may cause complications. Therefore, we thought to perform a noninvasive diagnostic procedure, based on the physiological function of androgen or estrogen producing cells.

The rationale for this procedure is that there is no need to lateralize an ovarian tumor in postmenopausal patients (Sarfati et al., 2011). In case of hormone-producing ovarian tumor in menopause, both ovaries are removed.

The rationale for the hormonal diagnostic manipulation used for the diagnostic procedure is based on the presence of luteinizing hormone (LH) receptors on the theca cells. Theca cells are characterized by steroidogenic activity in response to LH, specifically resulting in androgen production (Hormone biosynthesis, 2011). Human chorionic gonadotropin (hCG) stimulates testosterone production in both healthy (Hormone biosynthesis, 2011) and hyperandrogenic women (Rosenfield et al., 1990).

It has been shown that gonadotropin releasing hormone (GnRH)-agonist suppresses LH dependent ovarian steroidogenesis and does not appear to affect adrenal androgen secretion (Lobo, 1991). Moreover, GnRH-agonist treatment may suppress testosterone to levels found in oophorectomized women (Chang et al., 1983).

We used oral steroids to induce adrenal hormonal depression. Decrease in androgens or estradiol might indicate the presence of an adrenal tumor due to elimination of direct adrenal production of androgens and/or subsequent conversion to estradiol by aromatase.

Once adrenal depression was achieved, we induced ovarian androgen hormonal depression by using GnRH-antagonist. Decrease in androgen levels may indicate potential ovarian androgen producing tumor, as it has been demonstrated that GnRH-agonist suppression of gonadotropins lowered serum testosterone levels in virilized women having basal increased serum testosterone and gonadotropin levels

(Lamberts et al., 1982). Therefore, it was suggested that androgen secretion by ovarian virilizing tumors, as well as hyperthecosis, is not autonomous, but apparently depends on continuous gonadotropin stimulation and thus, is gonadotropin dependent (Lamberts et al., 1982). Furthermore, in an in vitro study of androblastoma, Lamberts et al. demonstrated a suppressive effect of GnRH-agonist on androgen secretion by a direct effect on the ovarian tumor (Lamberts et al., 1982).

In a previous study, we demonstrated that three weeks after a subcutaneous injection of 3.75 mg GnRH-agonist, LH and testosterone levels decreased dramatically in a postmenopausal patient with ovarian Sertoli–Leydig cell tumor (Sarfati et al., 2011). Moreover, GnRH-agonist has been shown to suppress elevated androgen levels in patients with Leydig cell ovarian tumor (Kennedy et al., 1987), hyperthecosis (Lamberts et al., 1982), granulosa cell ovarian tumor (Martikainen et al., 1989), hilus cell ovarian tumor (Rosenfield et al., 1990), Sertoli–Leydig ovarian tumor and steroid-cell ovarian tumor (Brewer and Douglas, 1998).

Using GnRH-antagonist induces immediate ovarian hormonal depression, similar to the depressive, but delayed action of GnRH-agonist. Subsequent administration of LH may irritate the androgen tumor cells and consequently provoke higher androgen levels. We have previously shown during selective venous catheterization, that 15 min after administration of intravenous injection of hCG, testosterone and androstenedione levels increased 6.5- to 7-fold, while there were only mild elevations of basal levels of these two hormones in a postmenopausal patient with ovarian Leydig cell tumor (Cohen et al., 1993) and in a postmenopausal patient with ovarian hyperthecosis (Sarfati et al., 2011). In the first case, androgen levels decreased following GnRH-antagonist injection and subsequently increased significantly following LH injection. Moreover, histological evaluation revealed steroid cell tumor in the ovary.

Table 2
Basal hormone values, hormone levels during the 9-day dynamic hormonal test and postoperative hormonal values (patient 2)

Day	0	1–9	7	8	9	Post-operative
Medications and procedures	Basal hormone values	Dexa 1.0 mg daily	Blood test, GnRH-antagonist 250 µg	Blood test, FSH 75 IU	Blood test	
Hormone levels (normal range)						
SHBG (18–144 nmol/L)		–	24	25	23	
DHEAS (0.9–11.6 µmol/L)	1.37	–	0.54	0.54	0.54	1.21
Androstenedione (0.48–10.07 nmol/L)	3.73	–	0.58	0.5	0.58	3.37
Cortisol (138–690 nmol/L)	475					
17 OHP (0.6–5.2 nmol/L)	0.51	–	0.46	0.46	0.46	0.57
Total testosterone (0.9–2.6 nmol/L)	0.9	–	1.22	1.22	1.22	0.9
Free androgen index (0.2–12.0 nmol/L)	–	–	1.4	1.4	1.4	–
Estradiol (<70 pmol/L)	431	–	158	73	118	<70

Dexa = dexamethasone; SHBG = sex hormone binding globulin; DHEAS = dehydroepiandrosterone sulfate; 17 OHP = 17 hydroxyprogesterone. Bold text indicates abnormal values.

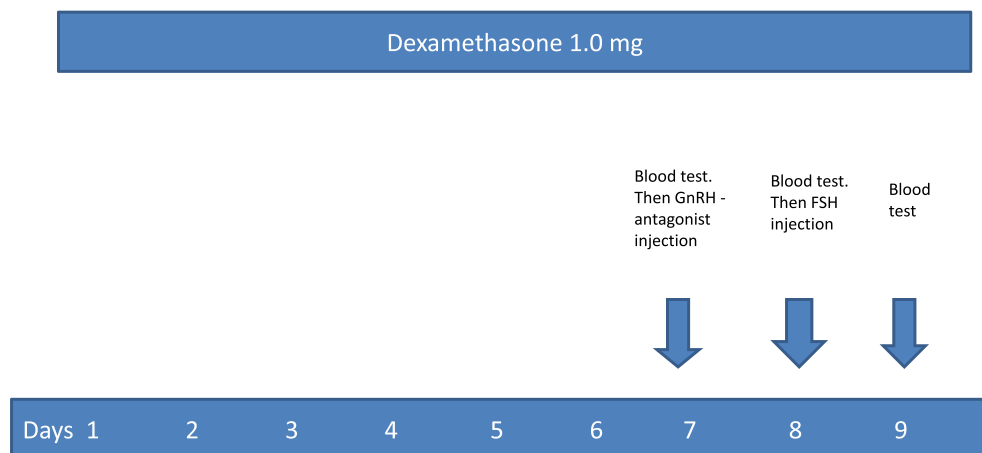


Fig. 2. Algorithm of the 9-day dynamic FSH hormonal test protocol (patient 2).

In a case of potential estrogen-producing tumor, we performed the same hormonal test. However, instead of subsequent administration of LH, we injected follicular-stimulating hormone (FSH), as it may irritate the estrogen producing cells and consequently provoke higher estrogen levels. It is well known that FSH receptors are present on the granulosa cells and FSH induces aromatization of androgens to estrogens in the granulosa cells (*Hormone biosynthesis, 2011*).

In the second case, estradiol level decreased following GnRH-antagonist injection and subsequently, increased significantly after FSH injection. Moreover, histological evaluation revealed granulosa cell tumor in the ovary. Neither patient experienced any side effects during the hormonal study.

To conclude, to the best of our knowledge, these are the first cases showing the efficacy of a noninvasive hormonal test for detecting postmenopausal hormone-producing ovarian tumors. The test is simple, safe and the patients did not experience side effects. The proposed hormonal test can be considered in postmenopausal women suspected of having androgen and/or estrogen producing tumors, especially in cases with no adnexal pathology on imaging studies/pelvic exam, as well as in cases with abnormalities present on imaging studies that are unlikely to prompt immediate surgical intervention. Due to the small number of patients, our results should be confirmed in larger studies.

Disclosure statement

The authors have nothing to disclose.

References

Brewer, C.A., Douglas, S., 1998. Encouraging response of an advanced steroid-cell tumor to GnRH agonist therapy. *Obstet. Gynecol.* 92, 661–663.

- Chang, R.J., Laufer, L.R., Meldrum, D.R., DeFazio, J., Lu, J.K., Vale, W.W., Rivier, J.E., Juded, H.L., 1983. Steroid secretion in polycystic ovarian disease after ovarian suppression by a long-acting gonadotropin-releasing hormone agonist. *J. Clin. Endocrinol. Metab.* 56, 897.
- Cohen, I., Shapira, M., Cuperman, S., Goldberger, S., Siegal, A., Altaras, M., Beyth, Y., 1993. Direct in-vivo detection of atypical hormonal expression of a Sertoli-Leydig cell tumour following stimulation with human chorionic gonadotrophin. *Clin. Endocrinol.* 39, 491–495.
- Geetha, P., Nair, M.K., 2010. Granulosa cell tumors of the ovary. *Aust. N. Z. Obstet. Gynecol.* 50, 216–220.
- Hormone biosynthesis, 2011. *Metabolism and mechanism of action*. In: Fritz, M.A., Speroff, L. (Eds.), *Clinical Gynecologic Endocrinology and Infertility*, 8th ed. Lippincott Williams & Wilkins, Philadelphia, pp. 41–42.
- Kaltsas, G.A., Mukherjee, J.J., Kola, B., Isidori, A.M., Hanson, J.A., Dacie, J.E., Reznick, R., Monson, J.P., Grossman, A.B., 2003. Is ovarian adrenal venous catheterization and sampling helpful in the investigation of hyperandrogenic women? *Clin. Endocrinol.* 59, 34–43.
- Kennedy, L., Traub, A., Atkinson, A.B., 1987. Short term administration of gonadotrophin releasing hormone analog to a patient with a testosterone secreting ovarian tumor. *J. Clin. Endocrinol. Metab.* 64, 1320–1322.
- Lamberts, S.W.J., Timmers, J.M., Oosterom, R., Verleun, T., Rommerts, F.G., 1982. deJong FH. Testosterone secretion by cultured arrhenoblastoma cells: suppression by luteinizing hormone releasing hormone agonist. *J. Clin. Endocrinol. Metab.* 54, 450–454.
- Lobo, R.A., 1991. Ovarian hyperandrogenism and androgen-producing tumors. *Endocrinol. Metab. Clin. N. Am.* 20, 773–805.
- Mancaux, A., Gardel Chambenoit, E., Gagner, O., Nasreddine, A., Gondry, J., Merviel, P., 2013. Granulosa cell tumor: difficulty of diagnosis and contribution of imaging. *Gynecol. Obstet. Fertil.* 41, 439–445.
- Martikainen, H., Penttinen, J., Huhtaniemi, I., Kauppila, A., 1989. Gonadotropin-releasing hormone agonist analog therapy effective in ovarian granulosa cell malignancy. *Gynecol. Oncol.* 35, 406–408.
- Rosenfield, R.L., Barnes, R.B., Cara, J.F., Lucky, A.W., 1990. Dysregulation of cytochrome P450c17 α as the cause of polycystic ovarian syndrome. *Fertil. Steril.* 53, 785.
- Sarfati, J., Bachelot, A., Coussieu, C., Meduri, G., Tourine, P., 2011. Impact of clinical, hormonal, radiological and immunohistochemical studies on the diagnosis of postmenopausal hyperandrogenism. *Eur. J. Endocrinol.* 165, 779–788.
- Taylor, L., Ayers, J.W., Gross, M.D., Peterson, E.P., Menon, K.M., 1986. Diagnostic considerations of virilization: iodomethyl-norcholesterol scanning in the localization of androgen secreting tumors. *Fertil. Steril.* 46, 1005–1010.
- Wang, P.-H., Chao, H.-T., Liu, R.-S., Cho, Y.-H., Ng, H.-T., Yoan, C.-C., 2001. Diagnosis and localization of testosterone-producing ovarian tumors: imaging or biochemical evaluation. *Gynecol. Oncol.* 83, 596–598.