

Received: 2013.02.23
Accepted: 2014.03.02
Published: 2014.04.01

Hemostasis in brain tumor surgery using the Aquamantys system

Authors' Contribution:
Study Design A
Data Collection B
Statistical Analysis C
Data Interpretation D
Manuscript Preparation E
Literature Search F
Funds Collection G

ABCDE 1 **Giovanni Grasso**
EF 2 **Filippo Giambartino**
AD 1 **Domenico G. Iacopino**

1 Section of Neurosurgery, Department of Experimental Biomedicine and Clinical Neurosciences (BIONE), University of Palermo, Palermo, Italy
2 Department of Anesthesiology, University of Palermo, Palermo, Italy

Corresponding Author: Giovanni Grasso, e-mail: giovanni.grasso@unipa.it
Source of support: Departmental sources

Background: Adequate hemostasis in cranial and spinal tumor surgery is of paramount importance in neurosurgical practice. Generalized ooze bleeding from the surgical walls cavity, coming from neoplastic vessels or nervous tissue, may be problematic. Recent technical advances have dramatically reduced intraoperative complications related to blood loss. Several techniques are usually employed to control hemostasis in tumor surgery, including preoperative embolization, intraoperative hypotension, electrical coagulation, and local application of fibrin sealants or hemostatic matrix, which influence coagulation.





Material/Methods: Our aim in this study was to evaluate the efficacy and the safety of the Aquamantys® system (Medtronic Advanced Energy, Portsmouth, NH, USA), a novel bipolar coagulation device that incorporates a new bipolar coagulation technique. This device has been used in 10 consecutive patients affected by cerebral tumor along with the standard microsurgical technique and well-known intraoperative tools. The technique is associated with simultaneous delivery of bipolar radio frequency energy and conductive fluid through its electrode tip. The volume of saline passing by the electrode tip prevents charring and maintains a clean tip. This cools the tissue as it raises the temperature sufficiently to shrink the collagen of veins and arteries.

Results: Effective hemostasis was achieved in all the cases. No complications or unwanted reactions associated with the device have been observed.

Conclusions: Our findings suggest that the Aquamantys® system may be a highly effective adjuvant tool in minimizing blood loss in a patient with brain tumor, as well as reducing time of surgery.

MeSH Keywords: **Blood Loss, Surgical • Brain Neoplasms • Meningioma**

Full-text PDF: <http://www.medscimonit.com/download/index/idArt/890583>

 1871  —  4  10

Background

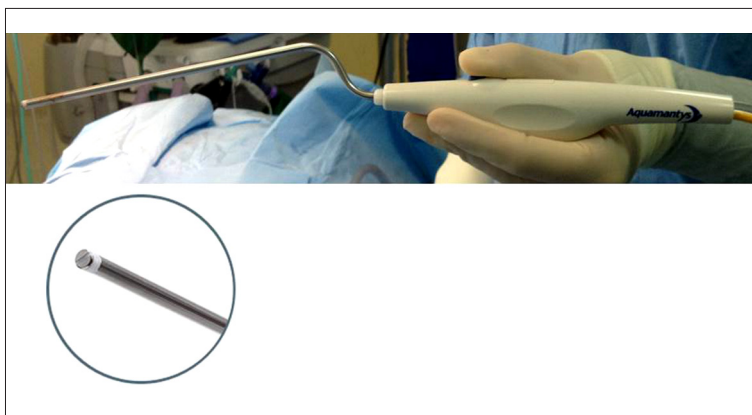Surgical treatment for intracranial tumor may be associated with blood loss. Several strategies are used to reduce blood loss, including preoperative embolization, intraoperative controlled hypotension, electrical coagulation, or local application of fibrin sealants or hemostatic matrix, which influence coagulation [1–3]. With usual contact methods involving electrocautery, such as monopolar knife and bipolar coagulator, removal of the probe from the adherent, desiccated eschar around the probe often detaches the eschar, causing greater bleeding than before the coagulation. In this scenario, the Aquamantys® system (Medtronic Advanced Energy, Portsmouth, NH, USA) incorporates a new bipolar coagulation technique [4] associated with simultaneous delivery of bipolar radio frequency energy and conductive fluid through its electrode tip. The volume of saline passing by the electrode tip prevents charring and maintains a clean tip. This cools the tissue as it raises the temperature sufficiently to shrink the collagen of veins and arteries. Power and saline flow are adjustable for different types of tissue to promote effective coagulation.

We report a series of brain tumor patients undergoing surgery using the Aquamantys® system, along with its epidural vein sealer (EVS), which revealed some practical advantages. Usefulness and limitations are discussed.

Material and Methods

Informed patient consent has been obtained.

The Aquamantys® system (Medtronic Advanced Energy, Portsmouth, NH, USA) is based on a new bipolar coagulation technique, the so-called transcollation technology, a proprietary combination of radiofrequency energy and saline [4]. The technique is associated with simultaneous delivery of bipolar radio frequency energy and conductive fluid through its electrode tip.



Briefly, the system works by combining a bipolar electro-surgical generator with a rotary peristaltic pump to provide simultaneous delivery of radiofrequency energy and saline when used with Aquamantys® handheld disposable devices. The saline cools the tissue as it is treated and evenly conducts the energy into the tissue to seal blood vessels. The thermal effect shrinks the collagen in the vessel walls of small arteries, and this results in the cessation of bleeding from these vessels. The saline used as a conductive fluid cools the tissue surface and prevents the surface temperature from getting too hot, thus avoiding charring.

The Aquamantys® device, when associated with the hand-piece EVS, has a shaft diameter of 4 mm, thus offering good visibility and less crowdedness in the surgical field (Figure 1).

The Aquamantys® system has been used in 10 consecutive patients with brain tumors (5 meningiomas, 3 glioblastomas, and 2 pituitary adenomas). In cases with pituitary adenomas, the device was used for hemostasis of the bleeding from the nasal mucosa and on the tumor capsule.

The coagulation setting, adjustable from 20 to 200 watts, was 20 watts and the saline flow (with settings for low, medium, and high), was set in “medium” position. External irrigation was also maintained as usual.

The device was used in the same way as standard electrocautery except that the bipolar sealer could be used not only in a localized manner to stop bleeding, but also in a spreading manner to stop diffuse bleeding.

Results

Effective hemostasis was achieved in all cases. No complications or unwanted reactions associated with the device were observed.

Figure 1. The Aquamantys® system consists of a proprietary radiofrequency generator that delivers transcollation technology to disposable Aquamantys bipolar sealers. The epidural vein sealer (EVS) handpiece has an out-of-body shaft length of 172.50 mm and a shaft diameter of 4 mm.

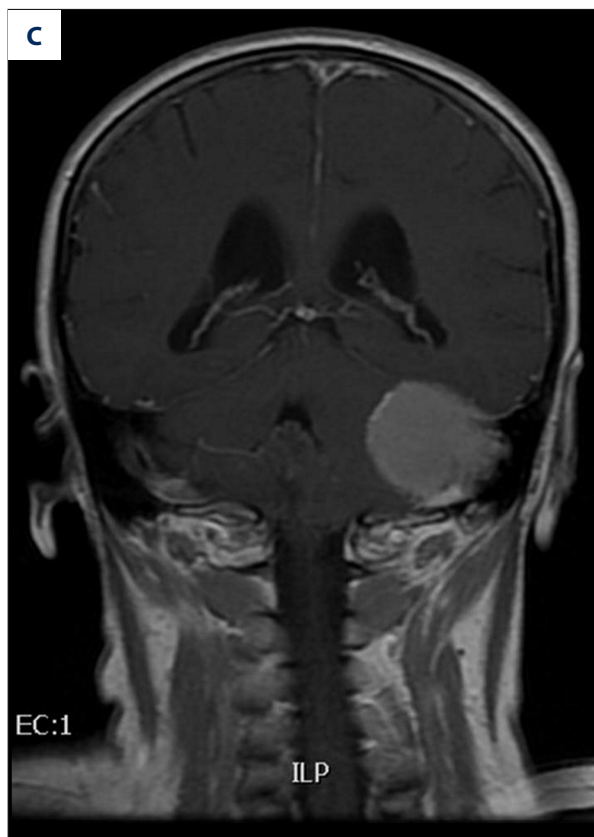
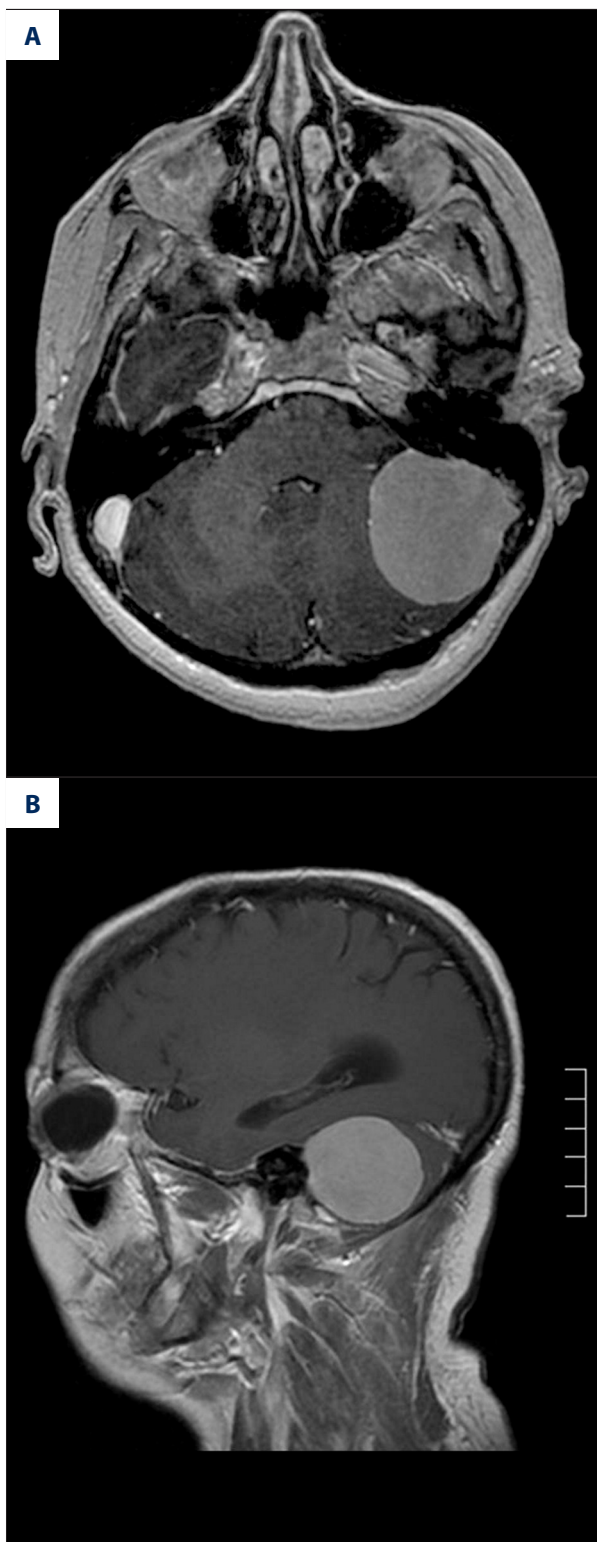


Figure 2. Preoperative axial (A), sagittal (B), and coronal (C) magnetic resonance imaging (MRI) scans with contrast showing a mass lesion in the left cerebellopontine angle entering the left sigmoid sinus.

Hemostasis on tumor removal

On the removal of meningioma, at first, the tumor capsule was coagulated by the Aquamantys® device. This technique not only

coagulated superficial blood vessels in the tumour capsule, but also produced shrinkage of the capsule due to the heating effect, facilitating the dissection of the tumor from the surrounding arachnoid planes with minimal manipulation of surrounding structures.

The Aquamantys® probe can be used with both the naked eye and under the surgical microscope. A thin and a relative flexible probe (tip diameter of 3.4 mm, distal bayonet shaft length of 139.45 mm) particularly increased the usefulness of the system for hemostasis under the microscope. Thus, the total amount of bleeding was reduced and the reduction of the tumor size due to shrinking made it very easy to handle the tumors.

In glioma surgery, the device, with its relatively wide hand-piece tip, allowed optimal tumor coagulation during dissection and stopped generalized ooze bleeding from the surrounding surgical wall cavity.

Hemostasis on skull base tumor removal

In brain tumors that have a large blood supply from feeding arteries penetrating the skull base, the Aquamantys® device

was extremely useful for the hemostasis of these bone-penetrating feeding arteries.

Hemostasis of the nasal mucosa

The Aquamantys® device was also useful for troublesome bleeding from the nasal mucosa with the endonasal approach for a pituitary adenoma. By using its long distal bayonet, it was possible to stop the bleeding from the sidewall of the nasal mucosa. Furthermore, the Aquamantys® device was very useful in coagulating the tumor capsule, leading to lesion shrinking.

Illustrative case

A 52-year-old woman was admitted with mild occasional headache and disequilibrium. Neurological examination on admission showed mild left hearing impairment and mild gait disturbance with ataxia. No other neurological findings (e.g., facial dysesthesia or facial palsy) were observed.

No familial history of neurofibromatosis was evident.

The patient underwent brain computed tomography (CT), which showed a lesion in the left cerebellopontine angle. Magnetic resonance imaging demonstrated a mass lesion in the left cerebellopontine angle. The mass was approximately 6 cm in diameter, appearing hypointense on T1-weighted imaging, and heterogeneously intense on T2-weighted imaging. The lesion had peritumoral edema apparent in the surrounding cerebellum on fluid-attenuated inversion recovery imaging. The mass had a solid lobular shape with heterogeneous enhancement after contrast administration. The tumor margins were clear and no contact with the internal auditory meatus was evident. Slight dural tail sign was evident on the left sigmoid sinus, which was infiltrated but not occluded by the lesion (Figure 2).

Left suboccipital retrosigmoid craniotomy exposed the tumor originating from the tentorium, and present mainly in the infratentorial epiarachnoid space, with a small attachment to the edge of the petrosal bone. The lesion was well demarcated from the surrounding cerebellum, but attachment to the petrosal vein was identified. The lesion was carefully dissected out by the surrounding cerebellum. The Aquamantys® device was used both for tumor capsule coagulation and meningioma shrinking (Figure 3). Bipolar coagulation and ultrasound suction were used to achieve tumor resection. A small piece of tumor was left inside the sigmoid sinus. Histological examination of the tumor demonstrated typical findings of meningothelial meningioma. Postoperatively, the patient showed no neurological deficit and recovered well. Two years later, brain MRI follow-up did not show development of the residual tumor inside the left sigmoid sinus (Figure 4).

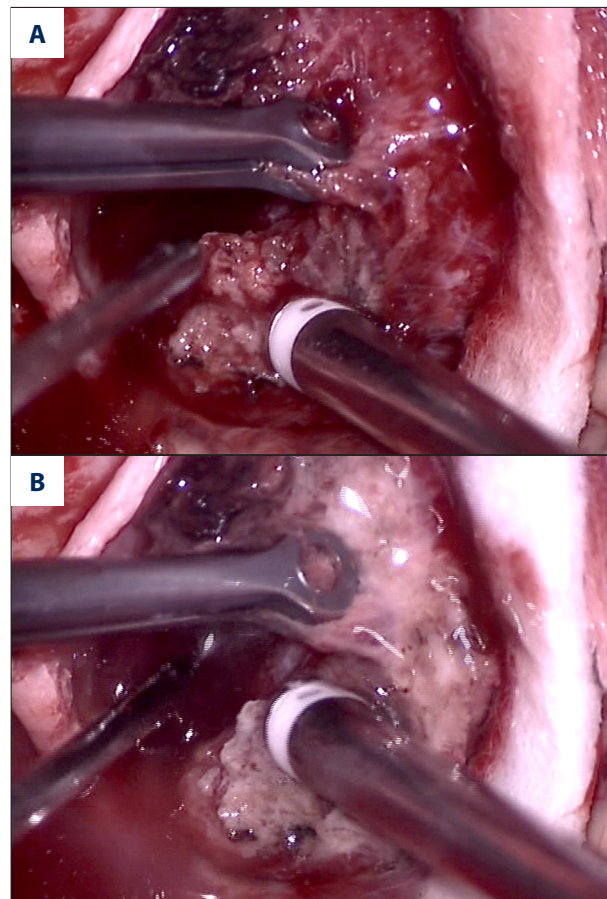


Figure 3. Intraoperative photographs showing the tumor in the left cerebellopontine angle. The Aquamantys® system is used to coagulate the tumor capsule (A). This allows a rapid devascularization, as shown by the progressive capsule discoloration (B).

Discussion

The development of bipolar coagulation began with the broad thermal-dispersion electrodes and has evolved to include highly accurate devices that deliver thermal energy via nonstick methods. Over time, the operative range of coagulation instruments has dramatically increased and improved. However, most of the contact methods of electrocautery have 2 shortcomings [5]. First, despite suction and irrigation, they work in the pooled blood. Coagulation in a bloody field only leads to boiling and then carbonization of the blood. Second, the coagulation of the pooled blood and not the bleeding vessel leads to the formation of a coating eschar around the probe. Removal of the probe from the adherent, desiccated eschar often detaches the eschar, causing greater bleeding than before the coagulation. In these contexts, a new electro-surgery modality, the Aquamantys® system, which has been used successfully in orthopedic [4,6,7], general and cardiac surgery [8], is gaining interest as an innovative method.

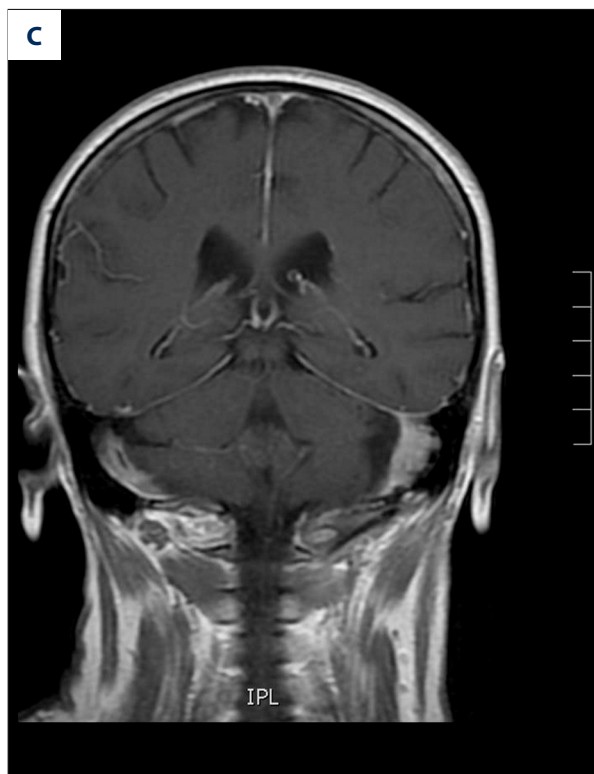
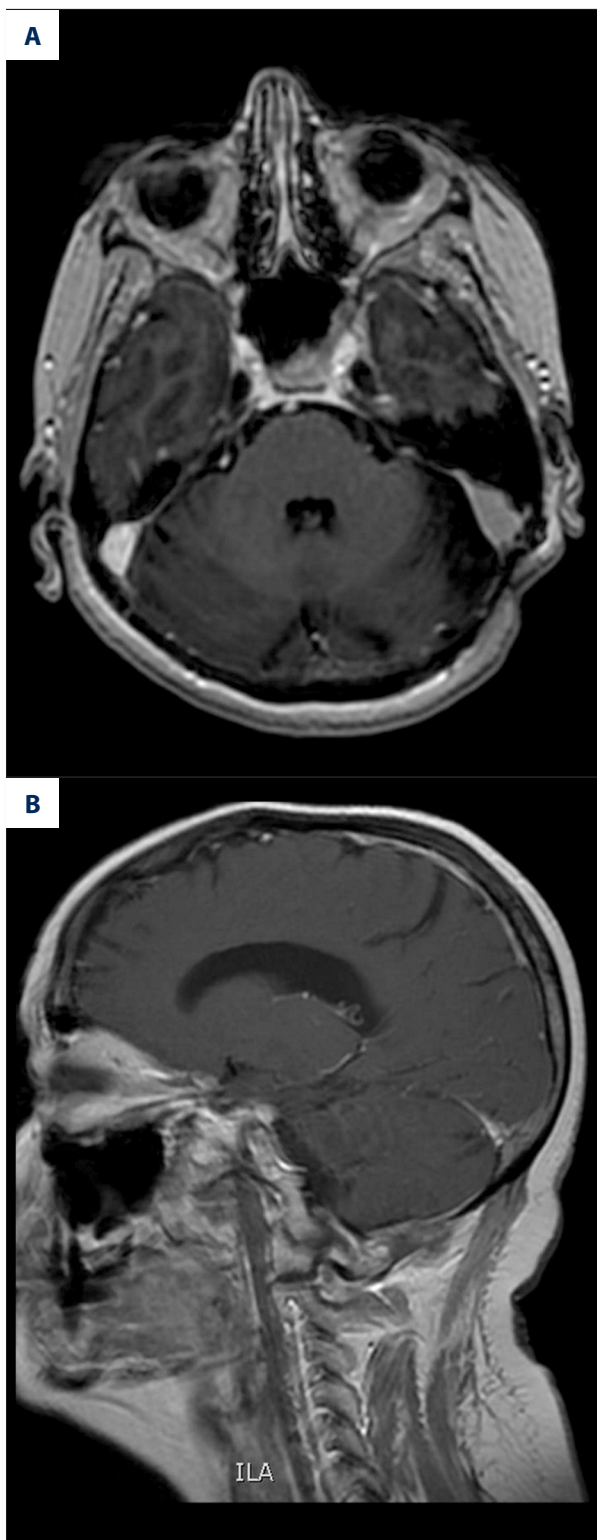


Figure 4. Postoperative axial (A), sagittal (B), and coronal (C) magnetic resonance imaging (MRI) scans with contrast showing no recurrence of the lesion at 2-year follow-up.

The Aquamantys® system and bipolar sealers feature innovative Transcollation® technology, a combination of radiofrequency (RF) energy and saline that provides hemostatic sealing of soft tissue and bone during surgery [4]. It consists of a generator

and disposable, single-use handpieces. The generator delivers transcollation technology, simultaneous RF power and saline delivery, to the disposable bipolar sealers. Power settings can vary from 20 to 200 watts and 3 different flow rates can be selected. Various handpieces are available that are adept for use in specific surgical procedures. The 6.0 Bipolar Sealer is mainly used in orthopedic surgery, where the system has been demonstrated to be useful in reducing blood loss during hip and knee replacement procedures and trauma surgery [4,9]. The EVS, with its out-of-body shaft length of 172 mm and shaft diameter of 4 mm, is recently used during spine surgery such as decompression procedures (e.g., discectomy and laminectomy) and all procedures requiring access to the epidural space [9].

In our surgical procedures, we used the EVS handpiece. The coagulation setting was 20 watts and saline flow was set at medium.

Compared with other high-frequency contact coagulation methods, the depth of necrosis, due to thermal injury, is extremely superficial and the continuous saline irrigation reduces the temperature in and around the treated area, which is crucially advantageous for neurosurgical operations. The use of standard electrocautery results in a high tissue surface temperature

and therefore leads to charring of the tissue and scar formation. Preventing this charring and searing of the tissue by using the Aquamantys® device should avoid the possible postoperative breakage or detachment of scar and clots produced by conventional electrocautery, which can lead to postoperative blood loss. Since the Aquamantys® system uses a round handpiece tip, the tissue surface that can be treated is larger than that usually coagulated by the classical bipolar forceps. This feature allows better control of capillary ooze, a well-known problem at the end of intracerebral tumor removal, and a wide coagulation area of the tumor and its capsule. In meningioma surgery, capsule coagulation leads to tumor devascularization; by increasing the power of the transcapsulation technology, tumor shrinking can be obtained. Furthermore, in skull base meningioma, when Simpson grade I cannot be achieved [10], the Aquamantys® tip device allows an efficacious coagulation of dural attachment.

Aquamantys® device can be applied in a brushwork fashion over large areas and it is particularly well-suited for treating diffuse bleeding and broad tumors, even when it is difficult to determine the bleeding point. Furthermore, since the device does not cause carbonization or vaporization and hence does not generate smoke, the surgeon's operative view is not disturbed. The relatively low initial cost and operating expenses are additional advantages of this technique.

The disadvantages of Aquamantys® should also be considered. In some instances, when the bleeding comes from a

well-recognized broken vein or artery, the bipolar forceps are more adequate and precise in controlling the bleeding than is the Aquamantys® system. Furthermore, the limited flexibility of the handpiece is a drawback, especially in case of a deep, narrow, and irregular operating channel. In such a case, however, the bipolar coagulation needs a wide enlargement of the working channel to provide complete control of the bleeding.

Conclusions

The Aquamantys® system is a novel coagulation technique with an innovative Transcapsulation® technology, a combination of radiofrequency (RF) energy and saline that provides hemostatic sealing of soft tissue and bone during surgery [4].

This technology can be considered as an adjuvant strategy for achieving hemostasis in brain tumor surgery. The Aquamantys® device is complementary to rather than competitive with bipolar coagulation and a conventional monopolar knife. The use of this device is certainly no substitute for a good microsurgical hemostasis technique. With the development of tailored and more flexible probes, the device might become a valuable surgical device.

Disclosure

The authors have no personal financial or institutional interest in the device described in this article.

References:

1. Thierry A, Foissac JC, Pelikan MC et al: [Controlled hypotension in neurosurgery excluding aneurysms]. *Neuro-Chirurgie*, 1978; 24(3): 193-95
2. Tudor KI, Tudor M, Buca A et al: [Electrosurgery, the cornerstone of current achievements of brain tumor surgery – on the occasion of 80th anniversary]. *Acta Med Croatica*, 2008; 62(1): 33-40
3. Cappabianca P, Esposito F, Esposito I et al: Use of a thrombin-gelatin haemostatic matrix in endoscopic endonasal extended approaches: technical note. *Acta Neurochirurgica*, 2009; 151(1): 69-77
4. Zeh A, Messer J, Davis J et al: The Aquamantys system – an alternative to reduce blood loss in primary total hip arthroplasty? *J Arthroplasty*, 2010; 25(7): 1072-77
5. Chehrizi B, Collins WF Jr: A comparison of effects of bipolar and monopolar electrocoagulation in brain. *J Neurosurgery*, 1981; 54(2): 197-203
6. Morris MJ, Barrett M, Lombardi Jr AV et al: Randomized Blinded Study Comparing a Bipolar Sealer and Standard Electrocautery in Reducing Transfusion Requirements in Anterior Supine Intermuscular Total Hip Arthroplasty. *J Arthroplasty*, 2013; 28(9): 1614-17
7. Barsoum WK, Klika AK, Murray TG et al: Prospective randomized evaluation of the need for blood transfusion during primary total hip arthroplasty with use of a bipolar sealer. *J Bone Joint Surgery Am*, 2011; 93(6): 513-18
8. Hammond S, Muirhead W, Zaitoun AM et al: Comparison of liver parenchymal ablation and tissue necrosis in a cadaveric bovine model using the Harmonic Scalpel, the LigaSure, the Cavitron Ultrasonic Surgical Aspirator and the Aquamantys devices. *HPB*, 2012; 14(12): 828-32
9. Mankin KP, Moore CA, Miller LE, Block JE: Hemostasis with a bipolar sealer during surgical correction of adolescent idiopathic scoliosis. *J Spinal Disord Techn*, 2012; 25(5): 259-63
10. Simpson D: The recurrence of intracranial meningiomas after surgical treatment. *J Neurol Neurosurg Psychiatry*, 1957; 20(1): 22-39