

Combination of serum phosphorylated neurofilament heavy subunit and hyperintensity of intramedullary T2W on magnetic resonance imaging provides better prognostic value of canine thoracolumbar intervertebral disc herniation

Tadahisa MASHITA^{1,2)*}, Hiroaki KAMISHINA^{2,4)}, Yuya NAKAMOTO³⁾, Yosuke AKAGI¹⁾, Ataru NAKANISHI¹⁾, Yusuke HARASAKI¹⁾, Tsuyoshi OZAWA³⁾, Takashi UEMURA³⁾, Yui KOBATAKE^{2,4)}, Shunsuke SHIMAMURA^{2,6)}, Naoki KITAMURA⁷⁾, Sadatoshi MAEDA^{2,4)}, Yuji UZUKA^{2,6)}, Gerry SHAW⁵⁾ and Jun YASUDA^{2,6)}

¹⁾Maizuru Animal Medical Center, 8–22 Hamamachi, Maizuru, Kyoto 625-0037, Japan

²⁾Department of Clinical Veterinary Science, The United Graduate School of Veterinary Science, Gifu University, 1–1 Yanagito, Gifu 509-1193, Japan

³⁾Kyoto Animal Referral Center, 208–4 Taishinarami, Kyoto 613-0036, Japan

⁴⁾Department of Veterinary Medicine, Faculty of Applied Biological Sciences, Gifu University, 1–1 Yanagito, Gifu 509-1193, Japan

⁵⁾Department of Neuroscience, University of Florida, College of Medicine, Gainesville, FL 32611, U.S.A.

⁶⁾Cooperative Department of Veterinary Medicine, Faculty of Agriculture, Iwate University, 3–18–8 Ueda, Morioka, Iwate 020-8550, Japan

⁷⁾Laboratory of Veterinary Physiology, Joint Department of Veterinary Medicine, Faculty of Agriculture, Tottori University, 4–101 Koyamacho Minami, Tottori 680-8553, Japan

(Received 4 November 2014/Accepted 7 December 2014/Published online in J-STAGE 19 December 2014)

ABSTRACT. The aim of this study was to evaluate the prognostic value of concurrent measurement of serum phosphorylated neurofilament heavy subunit (pNF-H) concentration and intramedullary T2W hyperintensity in paraplegic to paraplegic dogs. Our hypothesis was that concurrent measurement of these would provide a more accurate prediction of functional outcome in dogs with thoracolumbar intervertebral disc herniation (IVDH). A prospective case-control clinical study was designed using 94 dogs with acute onset of thoracolumbar IVDH. The association of serum pNF-H concentration, T2W hyperintensity on sagittal MRI (T2H/L2), deep pain perception and surgical outcome were evaluated with logistic regression analysis after three months for all 94 surgically treated dogs. Sensitivity to predict non-ambulatory outcome was compared among pNF-H and T2H/L2 and combination of both. Logistic regression analysis indicated that serum pNF-H concentration and T2H/L2 were significantly correlated with surgical outcome ($P<0.05$); however, deep pain perception was not ($P=0.41$). The results of logistic regression analysis indicated that the odds ratios of unsuccessful long-term outcome were 2.6 for serum pNF-H concentration, 1.9 for T2H/L2 and 2.3 for deep pain sensation. The sensitivity and specificity to predict non-ambulatory outcome for using serum parameter pNF-H >2.6 ng/ml, using T2H/L2 value of >0.84 and using both serum pNF-H and T2H/L2, were 95% and 75.7%, 65% and 86.5%, and 90.0% and 97.5%, respectively. Therefore, combined measurements of serum pNF-H and T2H/L2 might be useful for predicting long-term outcome in dogs with thoracolumbar IVDH.

KEY WORDS: canine, intervertebral disc herniation, MRI, neurofilament heavy subunit, T2W hyperintensity

doi: 10.1292/jvms.14-0582; *J. Vet. Med. Sci.* 77(4): 433–438, 2015

Thoracolumbar intervertebral disk herniation (IVDH) is the most common cause of spinal cord injury in dogs. Chondrodystrophic breed dogs show early onset of disk degeneration, which results in rupture of annulus fibrosus and nuclear extrusion [5, 11]. Thoracolumbar IVDH may cause various clinical signs that can range in severity from paraspinal hyperesthesia to paralysis with loss of pelvic limb deep pain perception. Traditionally, neurological dysfunction, such as absence of deep pain perception, is thought to be strongly associated with functional outcome in dogs with thoracolumbar IVDH [7, 21]. Although the prognosis of

dogs with intact deep pain perception in the hind limb is easily predicted, functional outcome in dogs without deep pain perception is difficult to determine. Previous studies have reported a wide range of functional recovery rates (30–56%) in these dogs [21, 25].

Some studies examined other prospective prognostic indicators. Intramedullary hyperintensity of the spinal cord identified on preoperative T2 weighted (T2W) images has provided a prognosis of poor functional recovery, regardless of deep pain perception [13]. In these studies, all dogs without T2W hyperintensity regained ambulation, whereas only 55% of dogs with T2W hyperintensity became ambulatory [13]. Another study had similar results, reporting a 93% recovery rate for dogs without T2W hyperintensity compared to only 76% in dogs who had hyperintensity [15].

In addition to these neurological signs and MRI findings, biomarkers in cerebrospinal fluid and urine have been used to evaluate canine IVDH [16, 17]. For example, urine 15F-2t-isoprostane-to-creatinine ratio was correlated with

*CORRESPONDENCE TO: MASHITA, T., Maizuru Animal Medical Center, 8–22 Hamamachi, Maizuru, Kyoto 625-0037, Japan.
e-mail: mashitad@gaia.eonet.ne.jp

©2015 The Japanese Society of Veterinary Science

This is an open-access article distributed under the terms of the Creative Commons Attribution Non-Commercial No Derivatives (by-nc-nd) License <<http://creativecommons.org/licenses/by-nc-nd/3.0/>>.

neurologic score in IVDH dogs [17]. Low myelin basic protein concentration in cerebrospinal fluid was associated with better long-term outcome [16]. Serum phosphorylated neurofilament heavy subunit (pNF-H) increased in non-ambulatory dogs compared with ambulatory dogs [19]. pNF-H is only found in large amounts inside neurons, and detection of this protein indicates neuronal damage [22, 26]. Previous studies have reported elevated serum pNF-H in experimental rodent spinal cord injury models as well as in traumatic brain injury models [23]. Furthermore, it is reported that pNF-H can be detected in patients with acute cervical spinal cord injury [12] and in patients with amyotrophic lateral sclerosis during disease progression [4]. Axonal injury may affect the structural integrity of cytoskeletal components, and the eventual detachment of pNF-H. Once pNF-H is released from damaged axons, pNF-H can enter blood circulation directly or through cerebrospinal fluid [28].

Deep pain perception, T2W hyperintensity and serum pNF-H concentration are useful factors to predict functional outcome of canine spinal cord injury, but these parameters had only been studied separately. The purpose of this study was to evaluate the prognostic values of combinatory measurements of serum pNF-H and intramedullary T2W intensity in dogs with acute onset of thoracolumbar IVDH. We supposed that serum pNF-H concentration and T2W hyperintensity would reflect different histopathological events, and thus, concurrent measurement of these would provide more accurate prediction of functional outcome in dogs with thoracolumbar IVDH compared with previously reported single factors, such as deep pain sensation, T2W hyperintensity or serum pNF-H concentration.

MATERIALS AND METHODS

Animals: This study used client-owned 96 dogs that met the following criteria: suffering from spinal cord compression located between T3 and L3 vertebral articulation for duration of more than 6 hr and less than 4 days of neurologic dysfunction prior to MRI and disk extrusion confirmed by MRI and/or decompressive surgery. All dogs with thoracolumbar Hansen Type I IVDH were admitted to Kyoto Animal Referral Medical Center (Kyoto AR) between November 2010 and August 2012. Age, sex, breed, duration of clinical signs and treatment history before admission were recorded for all dogs. Neurological dysfunction was classified into five categories at admission as previously reported with some modifications [24]: Grade I, spinal hyperesthesia only; Grade II, ambulatory paraparesis; Grade III, non-ambulatory paraparesis; Grade IV, paralysis of the hind limb with intact deep pain sensation; Grade V, paralysis of the hind limb without deep pain sensation.

Serum sample collection; pNF-H measurement: Approximately 1 ml of serum samples were obtained prior to anesthesia for each MRI. Peripheral blood was collected into a microsample tube (Fuji plain tube, Fujifilm Medical Co., Ltd., Tokyo, Japan) and centrifuged at room temperature immediately after blood clotting. The serum was collected and stored at -80°C until pNF-H analysis. pNF-H was measured

using a commercial ELISA kit (ELISA kit for Neurofilament subunit NF-H ver 2.1, EnCor Biotechnology Inc., Gainesville, FL, U.S.A.) for human pNF-H. pNF-H is reported to have extensive cross-species immunoreactivity [14]; previous data proved that this kit could detect canine pNF-H using the mouse anti-pNF-H antibody [14].

MRI: MRI scans were performed using 0.3 T permanent magnetic equipment (Airis Vento, Hitachi Medical Systems, Tokyo, Japan). T1W spin-echo images and T2W fast spin-echo images were obtained in the sagittal and transverse planes, respectively. T1W transverse (TR 450, TE 21–25, slice thickness 3.0 mm), T1W sagittal (TR 400, TE 25, slice thickness 3.0 mm), T2W transverse (TR 3000, TE 100, slice thickness 3.0 mm) and T2W sagittal (TR 3000, TE 100, slice thickness 3.0 mm) images were acquired. Using commercial software (AZE Win, AZE Ltd., Tokyo, Japan), T2W sagittal and transverse images were analyzed to determine the presence of spinal cord T2W hyperintensity. Image analysis was performed individually by two investigators (Y.N. and T.U.), who were blinded to clinical information. When both investigators agreed that T2W hyperintensity was present on the sagittal MRI, the length of the hyperintensity was measured and divided by the length of the 2nd lumbar vertebra to calculate a standardized ratio (T2H/L2) as described previously [13].

Surgical procedures: All dogs received hemilaminectomy on the same day or a day after MRI at Kyoto AR or at one of seven other referral veterinary hospitals. IVDH was confirmed at the surgery. The length of the decompression was determined by the extent of the dispersed disc material. Post-operative care included opioid analgesics, bladder management, passive range of motion and physical rehabilitation. These were performed for all dogs as needed until discharge. Postoperative rehabilitation was instructed to the owners after discharge and continued as needed. Administrations of corticosteroids and/or nonsteroidal anti-inflammatory drugs (NSAIDs) before, at admission and during perioperative periods were recorded.

Long-term follow-up: All surviving dogs with thoracolumbar IVDH were assessed for voluntary ambulation 12 weeks after the first admission to this study. Ambulatory status was determined by in-hospital examination or through a questionnaire sent to referring veterinarians, which consisted of inquiries about the motor function of the affected limb and the dog's ability to ambulate with or without assistance. Functional outcome was considered successful, if the dog regained the ability to walk with conscious proprioception without assistance. Dogs that regained motor function of the hind limbs but were unable to walk without assistance were considered to have an unsuccessful outcome. Dogs that did not regain ambulation during the follow-up period or that were died because of progressive myelomalacia were also classified as unsuccessful outcomes.

Statistical analysis: Linear regression was used to assess the associations of serum pNF-H concentration and T2H/L2 value. Receiver-operating characteristics (ROC) curve analysis was performed to estimate the effectiveness of serum pNF-H concentration or T2H/L2 to predict the surgical

Table 1. Serum pNF-H concentration and sagittal length of T2W hyperintensity within initial neurologic grade and surgical outcome

Neurologic grade	N	Serum pNF-H (ng/ml)		T2H/L2			Surgical Outcome		
		Mean	(SD)	Mean	(SD)	N#	Success	Unsuccess	PM
II	12	1.9	(1.1)	0.10	(0.34)	1	12	0	0
III	20	2.9	(4.5)	0.11	(0.49)	1	20	0	0
IV	38	2.6	(3.3)	0.43	(0.85)	14	34	4	0
V	24	7.1	(6.2)	1.93	(2.05)	18	8	10	6
Total	94	3.5	(4.3)	0.71	(1.38)	34	74	14	6

Neurologic grade means neurologic grade at presentation. PM, Progressive Myelomalacia. T2H/L2, Sagittal length of T2W hyperintensity (mm) divided by 2nd Lumbar vertebral body length (mm). N# means cases with T2W hyperintensity. Mean and SD was calculated in all dogs in each grade.

outcome. The optimal cutoff value was selected to maximize the Youden index (sensitivity + specificity - 1). To evaluate prediction efficacy of concurrent examination of serum pNF-H concentration, T2H/L2 value and deep pain sensation for unsuccessful surgical outcome, logistic regression was performed. Sensitivity and specificity were calculated by a cross table made from the results of logistic regression analysis. Data were expressed as mean \pm SD. All analyses were performed using commercially available software (JMP, SAS Institute Japan Ltd., Tokyo, Japan) and evaluated at 5% significance level.

RESULTS

A total of 96 dogs met the inclusion criteria. Since two dogs were excluded because of loss of follow-up, 94 dogs with thoracolumbar IVDH was examined in this study. Six dogs died due to progressive myelomalacia; functional outcome of these dogs was considered unsuccessful and included in the statistical analyses. None of the dogs were euthanized during the study period. Median age of dogs was 7 years (range, 2–12 years). There were 25 sexually intact females, 12 spayed females, 44 sexually intact males and 13 castrated males. Breeds included Miniature Dachshund (81), French Bulldog (3), Pekingese (3), Papillon (2), Welsh Corgi (2), Toy Poodle (1), Beagle (1) and mixed breed (1). The median duration of neurological signs before admission was 2 days (range, 1–4 days). The median neurological grade at admission was 4 (range, 2–5). After long-term follow-up, the functional outcomes of 74 dogs were considered successful. All the dogs with non-ambulatory outcome were in Grade IV or V. Of the 20 dogs with non-ambulatory outcomes, 6 dogs (all were in Grade V) died because of progressive myelomalacia, and 14 dogs (4 in Grade IV and 10 in Grade V) did not regain ambulation (Table 1). Compressive lesions were seen at 109 articulations; T11-12 (10), T12-13 (19), T13-L1 (30), L1-2 (28) and L2-3 (22). The number of compressive lesions was observed at one (80), two (13) or three intervertebral disc spaces (1). The long-term outcome was investigated at 12 weeks after the first admission at Kyoto AR (18/94) and through questionnaires to veterinarians (76/94). Sixty-five dogs were administered corticosteroids, 12 were given NSAIDs, 2 were given both corticosteroids and NSAIDs,

and 19 received neither.

The mean serum pNF-H concentration in all dogs was 3.5 ± 4.3 ng/ml. Serum pNF-H concentration and T2H/L2 value for each grade at the initial neurological examination are listed in Table 1. Intramedullary T2W hyperintensity was identified in 34 dogs. Mean T2H/L2 value was 0.71 ± 1.38 in all dogs.

Correlation analysis between serum pNF-H concentration and T2H/L2 value exhibited no linear relationship ($R^2=0.046$, Fig. 1). All the dogs with serum pNF-H higher than 5.9 ng/ml or T2H/L2 value higher than 3.9 had unsuccessful outcome; with only one exception, all dogs with serum pNF-H lower than 2.4 ng/ml had successful outcome.

The ROC curve analysis suggested that optimal serum pNF-H cutoff concentration was 2.6 ng/ml. The sensitivity and specificity for predicting unsuccessful outcome at this value were 95% (95% CI; 90.6–99.4%) and 75.7% (95% CI; 67.0–84.4), respectively. The area under the ROC curve was 0.91 (95% CI; 0.84–0.98), and the overall ability of serum pNF-H concentration to predict unsuccessful long-term outcome was significant ($P=0.010$, Fig. 2a). On the other hand, the sensitivity and specificity of T2H/L2 were 65% (95% CI; 55.4–74.6%) and 86.5% (95% CI; 79.6–93.4%), respectively. The cut-off value of T2H/L2 was 0.84 based on the ROC analysis. The area under the ROC curve was 0.78 (95% CI; 0.66–0.90), and the overall ability of T2H/L2 to predict unsuccessful long-term outcome was also significant ($P=0.043$, Fig. 2b).

An increase in serum pNF-H concentration, T2H/L2 and deep pain sensation by one unit conferred an increase in the odds ratio (OR) of unsuccessful outcome at long-term follow-up (OR: 2.6, 95% CI: 1.3–5.2, OR: 1.9, 95% CI: 1.1–3.6 and OR: 2.3, 95% CI: 0.3–15.5, respectively). In addition, serum pNF-H concentration and T2H/L2 value were significantly correlated to long-term surgical outcome ($P=0.009$ and 0.032, respectively); however, deep pain sensation was not ($P=0.41$). Cross table based on logistic regression analysis indicated that the combination of serum pNF-H concentration and T2H/L2 value revealed a sensitivity of 90% and a specificity of 97.5% in predicting an overall long-term unsuccessful outcome.

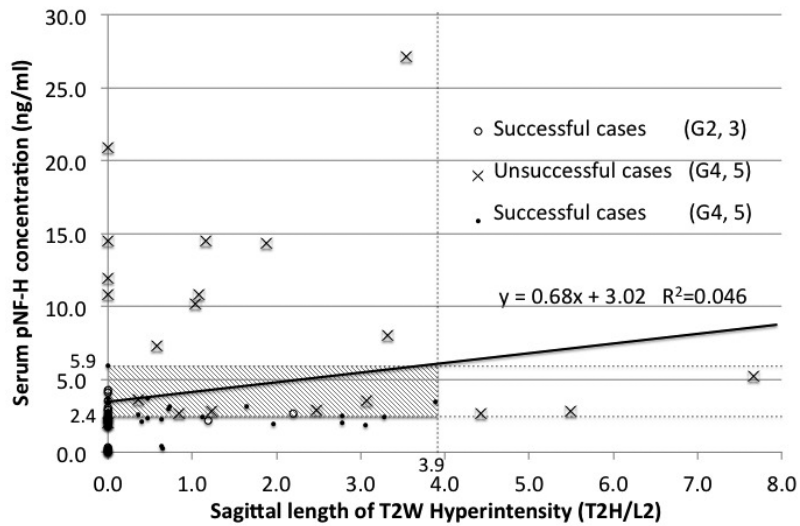


Fig. 1. Correlation between serum pNF-H concentration and sagittal length of intramedullary T2W hyperintensity (T2H/L2). All dogs with serum pNF-H > 5.9 ng/ml or T2H/L2 value > 3.9 had unsuccessful outcome. Dogs with serum pNF-H < 2.4 ng/ml had successful outcome, except for one case. Falsely diagnosed cases were in the area (shadows), when serum pNF-H was used for detection of intervertebral disc herniation alone. Linear relationship was not observed between T2H/L2 value and serum pNF-H concentration ($R^2=0.046$).

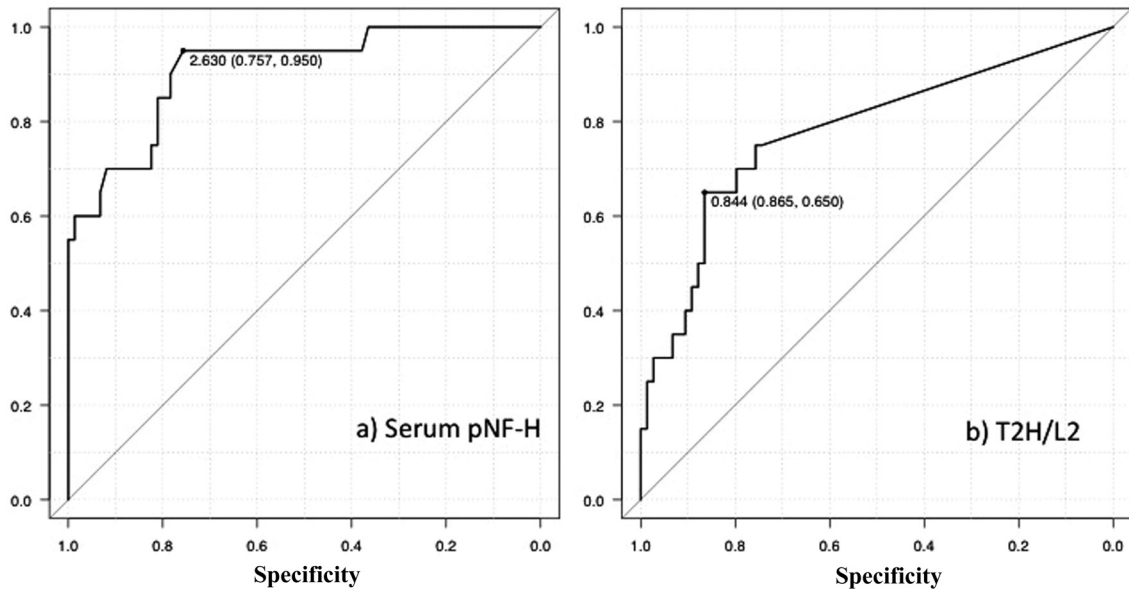


Fig. 2. Receiver-operating characteristic (ROC) curve to predict unsuccessful outcome by serum pNF-H concentration (a) and T2H/L2 value (b). a) Sensitivity and specificity of serum pNF-H concentration at 2.6 ng/ml were 95% and 75.7%, respectively. Area under the ROC curve was 0.91, and the overall ability of serum pNF-H concentration in this analysis to predict unsuccessful long-term outcome was significant ($P=0.010$). b) Sensitivity and specificity of T2H/L2 value at 0.84 were 65% and 86.5%, respectively. Area under the ROC curve was 0.78, and the overall ability to predict unsuccessful long-term outcome was significant ($P=0.043$). The sensitivity of serum pNF-H was higher than those of T2H/L2, although the specificity of T2H/L2 was higher than that of pNF-H.

DISCUSSION

The results of this study exhibited that the sensitivity and specificity for predicting long-term outcome by combination of serum pNF-H concentration and T2H/L2 value were 90% and 97.5%, respectively. These were sufficiently reliable and showed an improvement in specificity, compared to using each parameter separately. The sensitivity to predict unsuccessful surgical outcome of serum pNF-H concentration was superior to other conventional factors, such as T2W hyperintensity alone or deep pain sensation. However, the specificity of T2H/L2 was superior compared with those of serum pNF-H concentration. This implies that prediction with serum pNF-H alone would lead to inaccurate prognosis as was seen in a case with serum pNF-H concentration of 2.0 ng/ml revealed unsuccessful outcome. Furthermore, T2H/L2 showed higher specificity with lower sensitivity. Deep pain sensation had been used as the standard marker to predict functional outcome, though it was not significantly associated with unsuccessful outcome in this study based on the result of logistic regression analysis ($P=0.41$). However, dogs without deep pain sensation had increased risk of non-ambulatory outcome (OR: 2.3, 95% CI: 0.3–15.5).

The sensitivity to predict unsuccessful surgical outcome by serum pNF-H concentration was sufficient enough, although a wide range of serum pNF-H levels, (more than 2.4 and lower than 5.9 ng/ml) were obtained in this study. There has been no report about blood pNF-H level in patients with spinal cord injury, although increased serum pNF-H in dogs with thoracolumbar IVDH in Grades IV and V has been reported within 3 days after the onset of clinical signs [19]. pNF-H is thought to be released from damaged axons and then enters blood circulation directly or through damaged barrier [28]. pNF-H had an initial peak of expression at 16 hr, and the second peak at 3 days in experimentally induced spinal cord injury in rats [26]. Thereafter, pNF-H levels returned to the baseline over the following few days [26]. Since serum samples were collected 1 to 4 days after the onset of the clinical signs, pNF-H was released into blood circulation at a significantly high level. Decreased serum pNF-H in unsuccessful dogs might be due to proteolysis, because proteolysis of neurofilament in ischemic tissue has been reported [1].

In this study, sagittal length of intramedullary T2W hyperintensity was also associated with unsuccessful outcome. Although T2W hyperintensity is easily examined, additional parameters are required for accurate prediction of outcomes, because of relatively low sensitivity of T2W for predicting poor functional outcome. Length of T2W hyperintensity has been associated with poor functional outcome with cervical spinal cord injury in human patients [8, 18] and dogs with thoracolumbar IVDH [13, 15]. The usefulness of such signal characteristics on MRI might be limited without histopathological information. T2W hyperintensity includes various pathological changes, such as edema, inflammation or hemorrhage [2, 9, 10, 20]. Intraparenchymal hemorrhage has been of greater prognostic value in human patients with spinal cord injury compared to those without hemorrhage [3,

18, 19, 27, 30]. In veterinary medicine, detection of intraparenchymal hemorrhage by MRI has a limitation due to the body size of the patients and relatively lower-field magnetic strength of equipment. T2 star weighted image is used to depict intraparenchymal hemorrhage in various tissues and lesions [6]; however, T2 star weighted images had difficulty detecting spinal cord intraparenchymal hemorrhage in dogs. Thus, T2W is the sole imaging parameter for detecting spinal cord intraparenchymal hemorrhage in dogs at present.

The supposition was that serum pNF-H concentration and T2W hyperintensity would reflect spinal cord injury independently, since each of them represents different histopathological events. Our findings revealed that correlation between these two parameters was significantly low; however, histopathological events of dogs with increased serum pNF-H concentration and higher T2H/L2 value might occur concurrently. The spinal cord is injured by a combination of primary and secondary mechanisms. Primary injury produces intraparenchymal hemorrhage and edema, which results in expression of pNF-H [26]. Secondary demyelination including swelling and degeneration of myelin sheath results in continuous, and higher expression of pNF-H [26]. This secondary demyelination was reported to occur in canine IVDH-associated injury [29]. In our present study, 0.3T low-field strength MRI was used, and T2W imaging might have not completely detected lesions associated with demyelination. The sensitivities of 3T and 1T instruments in detecting T2W spinal cord hyperintensity were not significantly different from a previous study [15]. However, the results of our study may not directly apply to all imaging studies, especially those obtained using higher magnetic field units. Though serum pNF-H was measured as a prognostic biomarker in this study, human pNF-H in cerebrospinal fluid had been studied previously [4]. pNF-H in cerebrospinal fluid could also be applied. A serum biomarker may provide quick and simple clinical diagnosis/prognosis in animals with spinal injuries, if this assay becomes commercially available. In addition, repeated measurements of a serum biomarker allow monitoring of disease progression without anesthesia. Further studies using higher field strength of MRI equipment and consecutive examination of pNF-H in dogs with spinal cord injury are needed in order to apply these combinatory measurements for accurate prognosis.

From the study reported here, a combinatory analysis of serum pNF-H concentrations and T2W hyperintensity seems to have a prognostic value. Especially, serum pNF-H concentration of >2.6 ng/ml and T2H/L2 value of >0.84 can be associated with unsuccessful long-term outcome.

REFERENCES

1. Aronowski, J., Cho, K. H., Strong, R. and Grotta, J. C. 1999. Neurofilament proteolysis after focal ischemia; when do cells die after experimental stroke? *J. Cereb. Blood Flow Metab.* **19**: 652–660. [Medline] [CrossRef]
2. Berens, S. A., Colvin, D. C., Yu, C. G., Yeziarski, R. P. and Mareci, T. H. 2005. Evaluation of the pathologic characteristics of excitotoxic spinal cord injury with MR imaging. *AJNR Am. J. Neuroradiol.* **26**: 1612–1622. [Medline]

3. Boldin, C., Raith, J., Fankhauser, F., Haunschmid, C., Schwantzer, G. and Schweighofer, F. 2006. Predicting neurologic recovery in cervical spinal cord injury with postoperative MR imaging. *Spine* **31**: 554–559. [Medline] [CrossRef]
4. Boylan, K. B., Glass, J. D., Crook, J. E., Yang, C., Thomas, C. S., Desaro, P., Johnston, A., Overstreet, K., Kelly, C., Polak, M. and Shaw, G. 2013. Phosphorylated neurofilament heavy subunit (pNF-H) in peripheral blood and CSF as a potential prognostic biomarker in amyotrophic lateral sclerosis. *J. Neurol. Neurosurg. Psychiatry* **84**: 467–472. [Medline] [CrossRef]
5. Cappello, R., Bird, J. L., Pfeiffer, D., Bayliss, M. T. and Dudhia, J. 2006. Notochordal cell produce and assemble extracellular matrix in a distinct manner, which may be responsible for the maintenance of healthy nucleus pulposus. *Spine* **31**: 873–882, discussion 883. [Medline] [CrossRef]
6. Chavhan, G. B., Babyn, P. S., Thomas, B., Shroff, M. M. and Haacke, E. M. 2009. Principles, techniques, and applications of T2*-based MR imaging and its special applications. *Radiographics* **29**: 1433–1449. [Medline] [CrossRef]
7. Duval, J., Dewey, C., Roberts, R. and Aron, D. 1996. Spinal cord swelling as a myelographic indicator of prognosis: a retrospective study in dogs with intervertebral disc disease and loss of deep pain perception. *Vet. Surg.* **25**: 6–12. [Medline] [CrossRef]
8. Flanders, A. E., Spettell, C. M., Tartaglino, L. M., Friedman, D. P. and Herbison, G. J. 1996. Forecasting motor recovery after cervical spinal cord injury: value of MR imaging. *Radiology* **201**: 649–655. [Medline] [CrossRef]
9. Fukuoka, M., Matsui, N., Otsuka, T., Murakami, M. and Seo, Y. 1998. Magnetic resonance imaging of experimental subacute spinal cord compression. *Spine* **23**: 1540–1549. [Medline] [CrossRef]
10. Hackney, D. B., Finkelstein, S. D., Hand, C. M., Markowitz, R. S. and Black, P. 1994. Postmortem magnetic resonance imaging of experimental spinal cord injury: magnetic resonance findings versus *in vivo* functional deficit. *Neurosurgery* **35**: 1104–1111. [Medline] [CrossRef]
11. Hansen, H. J. 1952. A pathologic-anatomical study on disc degeneration in dog, with special reference to the so-called endochondrosis intervertebralis. *Acta Orthop. Scand. Suppl.* **11**: 1–117. [Medline] [CrossRef]
12. Hayakawa, K., Okazaki, R., Ishii, K., Ueno, T., Izawa, N., Tanaka, Y., Toyooka, S., Matsuoka, N., Morioka, K., Otori, Y., Nakamura, K., Akai, M., Tobimatsu, Y., Hamabe, Y. and Ogata, T. 2012. Phosphorylated neurofilament subunit NF-H as a biomarker for evaluating the severity of spinal cord injury patients, a pilot study. *Spinal Cord* **50**: 493–496. [Medline] [CrossRef]
13. Ito, D., Matsunaga, S., Jeffery, N. D., Sasaki, N., Nishimura, R., Mochizuki, M., Kasahara, M., Fujiwara, R. and Ogawa, H. 2005. Prognostic value of magnetic resonance imaging in dogs with paraplegia caused by thoracolumbar intervertebral disk extrusion: 77 cases (2000–2003). *J. Am. Vet. Med. Assoc.* **227**: 1454–1460. [Medline] [CrossRef]
14. Lee, V. M., Carden, M. J. and Schlaepfer, W. W. 1986. Structural similarities and differences between neurofilament proteins from five different species as revealed using monoclonal antibodies. *J. Neurosci.* **6**: 2179–2186. [Medline]
15. Levine, J. M., Fosgate, G. T., Chen, A. V., Rushing, R., Nghiem, P. P., Platt, S. R., Bagley, R. S., Kent, M., Hicks, D. G., Young, B. D. and Schatzberg, S. J. 2009. Magnetic resonance imaging in dogs with neurologic impairment due to acute thoracic and lumbar intervertebral disk herniation. *J. Vet. Intern. Med.* **23**: 1220–1226. [Medline] [CrossRef]
16. Levine, G. J., Levine, J. M., Witsberger, T. H., Kerwin, S. C., Russell, K. E., Suchodolski, J., Steiner, J. and Fosgate, G. T. 2010. Cerebrospinal fluid myelin basic protein as a prognostic biomarker in dogs with thoracolumbar intervertebral disk herniation. *J. Vet. Intern. Med.* **24**: 890–896. [Medline] [CrossRef]
17. McMichael, M. A., Ruaux, C. G., Baltzer, W. I., Kerwin, S. C., Hosgood, G. L., Steiner, J. M. and Williams, D. A. 2006. Concentrations of 15F2t isoprostane in urine of dogs with intervertebral disk disease. *Am. J. Vet. Res.* **67**: 1226–1231. [Medline] [CrossRef]
18. Miranda, P., Gomez, P. and Alday, R. 2008. Acute traumatic central cord syndrome: analysis of clinical and radiological correlations. *J. Neurosurg. Sci.* **52**: 107–112, discussion 112. [Medline]
19. Nishida, H., Nakayama, M., Tanaka, H., Kamishina, H., Izawa, T., Hatoya, S., Sugiura, K., Suzuki, Y., Ide, C. and Inaba, T. 2014. Evaluation of serum phosphorylated neurofilament subunit NF-H as a prognostic biomarker in dogs with thoracolumbar intervertebral disc herniation. *Vet. Surg.* **43**: 289–293. [Medline] [CrossRef]
20. Ohshio, I., Hatayama, A., Kaneda, K., Takahara, M. and Nagashima, K. 1993. Correlation between histopathologic features and magnetic resonance images of spinal cord lesions. *Spine* **18**: 1140–1149. [Medline] [CrossRef]
21. Olby, N., Levine, J., Harris, T., Muñana, K., Skeen, T. and Sharp, N. 2003. Long-term functional outcome of dogs with severe injuries of the thoracolumbar spinal cord: 87 cases (1996–2001). *J. Am. Vet. Med. Assoc.* **222**: 762–769. [Medline] [CrossRef]
22. Petzold, A. 2005. Neurofilament phosphoforms: surrogate markers for axonal injury, degeneration and loss. *J. Neurol. Sci.* **233**: 183–198. [Medline] [CrossRef]
23. Rostami, E., Davidsson, J., Ng, K. C., Lu, J., Gyorgy, A., Walker, J., Wingo, D., Plantman, S., Bellander, B. M., Agoston, D. V. and Risling, M. 2012. A model for mild traumatic brain injury that induces limited transient memory impairment and increased levels of axon related serum biomarkers. *Front Neurol* **3**: 115. [Medline] [CrossRef]
24. Scott, H. W. 1997. Hemilaminectomy for the treatment of thoracolumbar disc disease in the dog: a follow-up study of 40 cases. *J. Small Anim. Pract.* **38**: 488–494. [Medline] [CrossRef]
25. Scott, H. W. and McKee, W. M. 1999. Laminectomy for 34 dogs with thoracolumbar intervertebral disc disease and loss of deep pain perception. *J. Small Anim. Pract.* **40**: 417–422. [Medline] [CrossRef]
26. Shaw, G., Yang, C., Ellis, R., Anderson, K., Parker Mickle, J., Scheff, S., Pike, B., Anderson, D. K. and Howland, D. R. 2005. Hyperphosphorylated neurofilament NF-H is a serum biomarker of axonal injury. *Biochem. Biophys. Res. Commun.* **336**: 1268–1277. [Medline] [CrossRef]
27. Shimada, K. and Tokioka, T. 1999. Sequential MR studies of cervical cord injury: correlation with neurological damage and clinical outcome. *Spinal Cord* **37**: 410–415. [Medline] [CrossRef]
28. Singh, P., Yan, J., Hull, R., Read, S., O’Sullivan, J., Henderson, R. D., Rose, S., Greer, J. M. and McCombe, P. A. 2011. Levels of phosphorylated axonal neurofilament subunit H (pNF-H) are increased in acute ischemic stroke. *J. Neurol. Sci.* **304**: 117–121. [Medline] [CrossRef]
29. Smith, P. M. and Jeffery, N. D. 2006. Histological and ultrastructural analysis of white matter damage after naturally-occurring spinal cord injury. *Brain Pathol.* **16**: 99–109. [Medline] [CrossRef]
30. Tewari, M. K., Gifti, D. S., Singh, P., Khosla, V. K., Mathuriya, S. N., Gupta, S. K. and Pathak, A. 2005. Diagnosis and prognostication of adult spinal cord injury without radiographic abnormality using magnetic resonance imaging: analysis of 40 patients. *Surg. Neurol.* **63**: 204–209, discussion 209. [Medline] [CrossRef]