

## Exceptional Case

# Secondary amyloidosis in a patient carrying mutations in the familial Mediterranean fever (FMF) and tumour necrosis factor receptor-1 syndrome (TRAPS) genes

Anna Clementi<sup>1</sup>, Dinna N. Cruz<sup>2</sup>, Antonio Granata<sup>1</sup>, Grazia Maria Virzi<sup>3,4</sup> and Giorgio Battaglia<sup>5</sup>

<sup>1</sup>Department of Nephrology and Dialysis, San Giovanni Di Dio Hospital, Agrigento, Italy, <sup>2</sup>Division of Nephrology-Hypertension, Department of Medicine, University of California, San Diego, CA, USA, <sup>3</sup>Department of Nephrology Dialysis and Transplantation, San Bortolo Hospital, Vicenza, Italy, <sup>4</sup>International Renal Research Institute (IRRI), Vicenza, Italy and <sup>5</sup>Department of Nephrology and Dialysis, Santa Marta e Santa Venera, Acireale, Catania, Italy

Correspondence and offprint requests to: Dinna N. Cruz; E-mail: dinnacruzmd@yahoo.com

### Abstract

Secondary amyloidosis (AA) is characterized by the extracellular tissue deposition of fibrils composed of fragments of an acute-phase reactant protein, serum amyloid A (SAA), due to chronic inflammatory diseases, infections and several neoplasms. AA amyloidosis may also complicate several hereditary diseases, where genetic factors play a pivotal role in the expression of amyloidosis. Familial Mediterranean fever (FMF) and tumour necrosis factor receptor-1 syndrome (TRAPS) are the most frequently involved. We describe a case of a 21-year-old Romanian woman who presented at the 35th week of gestation with acute abdominal pain, nausea and vomiting. The laboratory workup performed after delivery showed proteinuria in the nephrotic range and increased SAA protein. Kidney amyloid deposits were detected and genetic testing for secondary amyloidosis was performed identifying two mutations, one involving the gene of FMF (MEFV), and the other involving the tumour necrosis factor receptor-1 gene (TNFRSF1A). To our knowledge, this is the first case in the literature where secondary amyloidosis develops in a patient carrying mutations involving the genes of both FMF and TRAPS.

**Keywords:** familial Mediterranean fever; secondary amyloidosis; TRAPS syndrome

## Introduction

Secondary amyloidosis (AA) is characterized by the extracellular tissue deposition of fibrils composed of fragments of an acute-phase reactant protein, serum amyloid A (SAA), due to chronic inflammatory diseases, infections and various neoplasms [1]. AA amyloidosis may also complicate several hereditary diseases, such as periodic fever syndromes, where genetic factors play a pivotal role in the expression of amyloidosis. Familial Mediterranean fever (FMF) and tumour necrosis factor receptor-1 syndrome (TRAPS) are the most frequently involved, while the development of amyloidosis in the setting of hyperimmunoglobulinaemia IgD is less often observed [2]. The prevalence of specific mutations correlates positively with the incidence and severity of AA amyloidosis. Nevertheless, variability in the expression of the same mutation between different populations, and even within families, suggests a significant effect for environment and other genetic factors [3].

## Case report

A 21-year-old Romanian woman at the 35th week of gestation was admitted due to acute left upper quadrant

abdominal pain for 3 days, associated with nausea and vomiting.

She had been healthy until the age of 20 when she underwent appendectomy for acute appendicitis and contracted hepatitis C virus infection. During pregnancy, blood pressure was normal and total weight gain was 6 kg. Mild oedema in the lower limbs was present before pregnancy, but it worsened during the first trimester. Due to her socioeconomic status, the patient did not receive any prenatal care.

Upon admission, blood pressure was 100/60 mmHg, pulse rate 90 beats/min and respiratory rate 28/min. There was no fever. Physical examination revealed mild abdominal distention and hypoactive bowel sounds. Moderate pitting oedema was present in the lower limbs. Lung, heart and neurological examinations were within normal limits. She was placed on parenteral nutrition and bowel rest, but her clinical condition worsened and the patient developed an inability to pass flatus. A Caesarean delivery was immediately performed and a premature child was delivered. A few days after delivery, abdominal pain, nausea and vomiting resolved spontaneously.

Table 1 summarizes the laboratory examination performed after delivery. Proteinuria 3.6 g/24 h was noted, serum creatinine was 53 µmol/L (0.6 mg/dL) and urea 7.1

**Table 1.** Laboratory examination performed after delivery

Haemoglobin	78 g/L (7.8 g/dL)
Haematocrit	23.7%
White blood cells	$20 \times 10^9/L$ (19.700/ $\mu$ L)
Neutrophils	94%
Lymphocytes	3.8%
Monocytes	1.2%
Eosinophils	0.1%
Platelets	$738 \times 10^9/L$ (738 000/ $\mu$ L)
Glucose	3.9 mmol/L (70 mg/dL)
Urea	7.1 mmol/L (20 mg/dL)
Creatinine	53 $\mu$ mol/L (0.6 mg/dL)
Sodium	145 mmol/L (145 mEq/l)
Potassium	4.4 mmol/L (4.4 mEq/l)
Total calcium	1.7 mmol/L (7.9 mg/dL)
CRP	28.3 mg/dL
ESR	90 mm/h
SAA	591.28 ng/mL
Fibrinogen	12 $\mu$ mol/L (407 mg/dL)
Serum proteins	33 g/L (3.3 g/dL)
Albumin	16 g/L (1.6 g/dL)
Total cholesterol	7.65 mmol/L (296 mg/dL)
Aspartate aminotransferase	8 U/L (8 U/l)
Alanine aminotransferase	8 U/L (8 U/l)
Gamma glutamyl transferase	19 U/L (19 U/l)
24 h proteinuria	3.3 g/24 h
TSH	3 mIU/L (3 $\mu$ IU/mI)
p-ANCA	0.8 U/mL
c-ANCA	1.2 U/mL
ANA	1:40
HBsAg	Negative
HCV core	Positive (+)

ANA, antinuclear antibodies; HbsAg, hepatitis B surface antigen; HCV, hepatitis C virus; p-ANCA, perinuclear antineutrophil cytoplasmic antibodies; TSH, thyroid-stimulating hormone.

mmol/L (20 mg/dL). Haemoglobin was 78 g/L (7.8 g/dL), white blood cells  $20 \times 10^9/L$  (19.700/ $\mu$ L) with 94% of neutrophils and platelets  $738 \times 10^9/L$  (738.000/ $\mu$ L). C-reactive protein (CRP) and erythrocyte sedimentation rate (ESR) were 150 mg/L and 90 mm/h, respectively; fibrinogen was normal. Serum protein was 33 g/L (3.3 gr/dL) and albumin 16 g/L (1.6 g/dL). No monoclonal band was present in serum protein electrophoresis. Autoimmune and coagulation parameters were normal, as well as thyroid and liver function tests. Hepatitis B virus infection markers were negative, and apart from a slight increase in hepatitis C virus antibody titre, no signs of active hepatitis were detected. The SAA protein level was high (591.28 ng/mL). Abdominal ultrasonography showed hyperechogenic cortex. Echocardiography revealed only mild mitral regurgitation. Electromyography detected initial signs of lower-limb sensory neuropathy. While abdominal fat pad aspirate was negative for amyloidosis, kidney biopsy revealed a diffuse glomerular deposition of amorphous hyaline material that stained weakly with periodic acid Schiff's and bound Congo red and thioflavine T (Figure 1). Vascular and tubular deposits were also present. Rectal biopsy was performed as well, showing the presence of A protein and the absence of immunoglobulin light chains. Molecular genetic screening tests for secondary (AA) amyloidosis were performed. A blood sample was obtained from the patient after her informed consent and genomic DNA was extracted from peripheral blood lymphocytes. The entire coding regions and intron-exon junctions, which are important in order to identify variants affecting mRNA splicing, were amplified and screened for mutation in Apo A-I, TNFRS1A and MEFV genes by the Sanger sequencing method to identify the causing mutation. Reference sequences were obtained from NCBI RefSeq and all sequences were compared with these sequences. The standard nomenclature

recommended by HGVS was used to number nucleotides and name mutations or variants. Two different mutations were identified by sequencing analysis. The first involved a copy of the gene of the FMF (MEFV) and it was c2082G>A, p.M694I on the short arm of chromosome 16. The second involved a copy of the tumour necrosis factor receptor-1 gene (TNFRSF1A), and it was c.362G>A, p.R92Q on the short arm of chromosome 12 (Figure 2). The diagnosis of AA amyloidosis was then confirmed. The Apo A-I gene did not present any mutations.

## Discussion

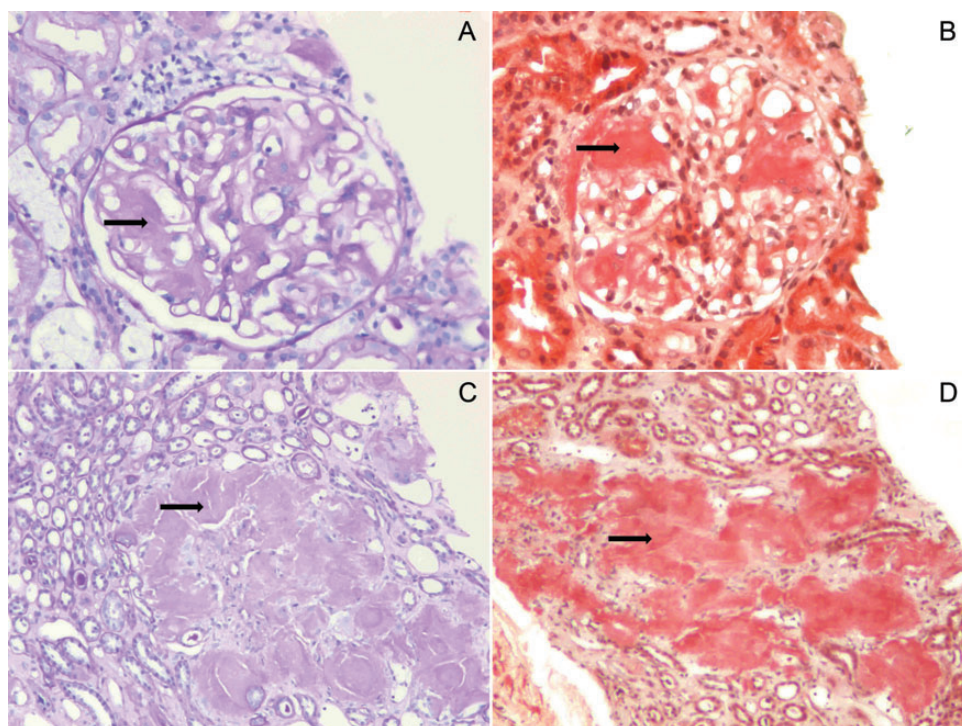
To our knowledge, this is the first case in the literature of secondary amyloidosis where mutations involving the gene of the FMF and the gene of the tumour necrosis factor receptor-1 co-exist.

In the case we reported, the diagnosis of renal amyloidosis was suggested by the presence of proteinuria in the nephrotic range and the initial signs of peripheral neuropathy, and was then confirmed by the detection of amyloid deposits in the kidneys. The high levels of SAA protein, the detection of AA protein in the rectal biopsy and the absence of kidney light chain deposits supported the diagnosis of secondary amyloidosis. As other causes of AA amyloidosis, such as autoimmune and infectious diseases, were excluded, we considered the possibility of hereditary syndromes that may be complicated by this type of amyloidosis. Two mutations involving the MEFV (c.2082G>A) and TNFR-1 (c.362G>A) genes were identified.

Since a heterozygous mutation both in MEFV and TNFRSF1A genes seems implied in the disease phenotype in this patient, a segregation analysis would be necessary to determine from which parent(s) they were inherited. Unfortunately, DNA samples from family members were not available. Therefore, familial segregation analysis could not be performed, and we could not distinguish the parental origin of the mutations in these two genes.

The FMF and the TRAPS are hereditary syndromes often complicated by amyloidosis [2]. FMF is characterized by sporadic, paroxysmal attacks of fever, serosal inflammation and arthritis, typically lasting 2–4 days, resolving spontaneously. This disorder has been described primarily in several ethnic groups originating in the Mediterranean littoral: Jews, Armenians, Turks, North Africans, Arabs, Greeks and Italians. Patients may experience painful attacks localized to the abdomen. Rebound tenderness, rigidity and adynamic ileus are often present. Patients may also develop amyloidosis, which usually presents as nephropathy. FMF can be transmitted as an autosomal-recessive disease, but several cases of compound heterozygous and heterozygote individuals with a milder disease of later onset have been described [4].

The responsible molecule is a 781 amino acid protein denoted as pyrin, encoded by a single gene on chromosome 16p (MEFV), with an important role in the regulation of apoptosis and inflammation [5]. To date, >90 mutations have been identified in the MEFV gene [6], but five mutations, M680I, M694V, M694I, V726A on exon 10 and E148Q on exon 2, account for >85% of cases. Nearly all of the disease-associated mutations are missense substitutions and most of them are clustered in the C-terminal domain. Furthermore, the genotype-phenotype correlation suggests that mutations located within the mutational hotspots in codons 680 and 694 are associated with severe



**Fig. 1.** Kidney biopsy. Diffuse glomerular deposition of amorphous hyaline material, which stained weakly with periodic acid Schiff's (PAS) and bit Congo red (A and B). Interstitial amyloid deposits (C and D). See black arrows.

disease, early onset and frequent occurrence of amyloidosis in untreated case [7]. Two specific mutations, M694V and E148Q-V726A double mutation, seem to correlate positively with the severity of the disease and the development of AA amyloid in some populations of patients [3]. Some reports suggest, indeed, that M694V/M694V homozygous patients appear to be more likely to have arthritis, renal amyloidosis, higher fever and more frequent attacks [8, 9]. Moreover, these patients require higher doses of colchicine to prevent attacks than those with other genotypes. Among Arab patients, homozygosity for the M694V allele results in more severe disease than homozygous individual for M694I [10]. The M694V mutation affects the majority of North African Jews with FMF, which are known to have more severe attacks and a higher frequency of amyloidosis [11]. On the other hand, Ashkenazi Jews, Druze and Armenians, who have a low frequency of this mutation, tend to have a milder versions of FMF with a lower incidence of amyloidosis. The mildest and least penetrant genotype is associated with the E148Q mutation [12]. Nevertheless, variability in the expression of the same mutation among different populations, and even between families, suggests significant environmental effects [3].

TRAPS is a rare syndrome, originally described among the Irish population and then reported in many other ethnic groups. It is inherited as an autosomal dominant disorder with incomplete penetrance [13, 14]. The genetic mutation involves the gene on chromosome 12 encoding the 55-kDa tumour necrosis factor  $\alpha$  receptor 1, TNFR1, and this results in enhanced susceptibility to TNF [15] and impaired TNF-driven apoptosis [16].

The median age of the disease onset is 3 years old, but cases of later onset have also been described. TRAPS is characterized by recurrent fevers which commonly last at least 5 days and often continue for more than 2 weeks, in the absence of viral or bacterial infections [17]. Febrile

episodes can be triggered by physical or emotional stress. Patients may also present focal myalgias, sometimes migratory, conjunctivitis, periorbital oedema, abdominal pain, monoarticular arthritis and rash. A minority of them, ~15% in the USA, may develop clinical manifestations of secondary amyloidosis, which primarily involves the kidney [2].

Over 80 distinct mutations of the TNFR-1 gene have been identified, and some of them are functional polymorphisms [18]. Mutations affecting cysteine residues are accompanied by a higher risk for amyloidosis than non-cysteine mutations [2]. The majority of TRAPS-related mutations are missense mutations, resulting in single amino acid substitutions in the cysteine-rich domains (CRDs), CRD1, CRD2 or CRD3, of the ectodomain of the mature TNFR1 protein [19, 20]. These CRDs are involved in disulphide bond formation and in the folding of the extracellular portion of the protein. Hence, mutations resulting in cysteine substitutions demonstrate a higher penetrance, usually being associated with a more aggressive phenotype and an increased probability of developing renal amyloidosis compared with mutations not involving the CRD [21].

The medical history of our patient was negative for fever and abdominal pain in childhood. Even though both the periodic fever syndromes described previously usually manifest in early childhood, some patients may experience a later onset of the disease. Triggering events for the attacks, which are usually less frequent during the third trimester of pregnancy, are vigorous exercise, exposure to cold and emotional stress, all of which were difficult to document in our patient. She experienced abdominal pain without fever, but presented leucocytosis with a predominance of neutrophils, increased levels of ESR, CRP and SAA. These laboratory findings are typical features of both FMF and TRAPS syndromes. The development of small bowel obstruction may indicate the presence of serositis, a more

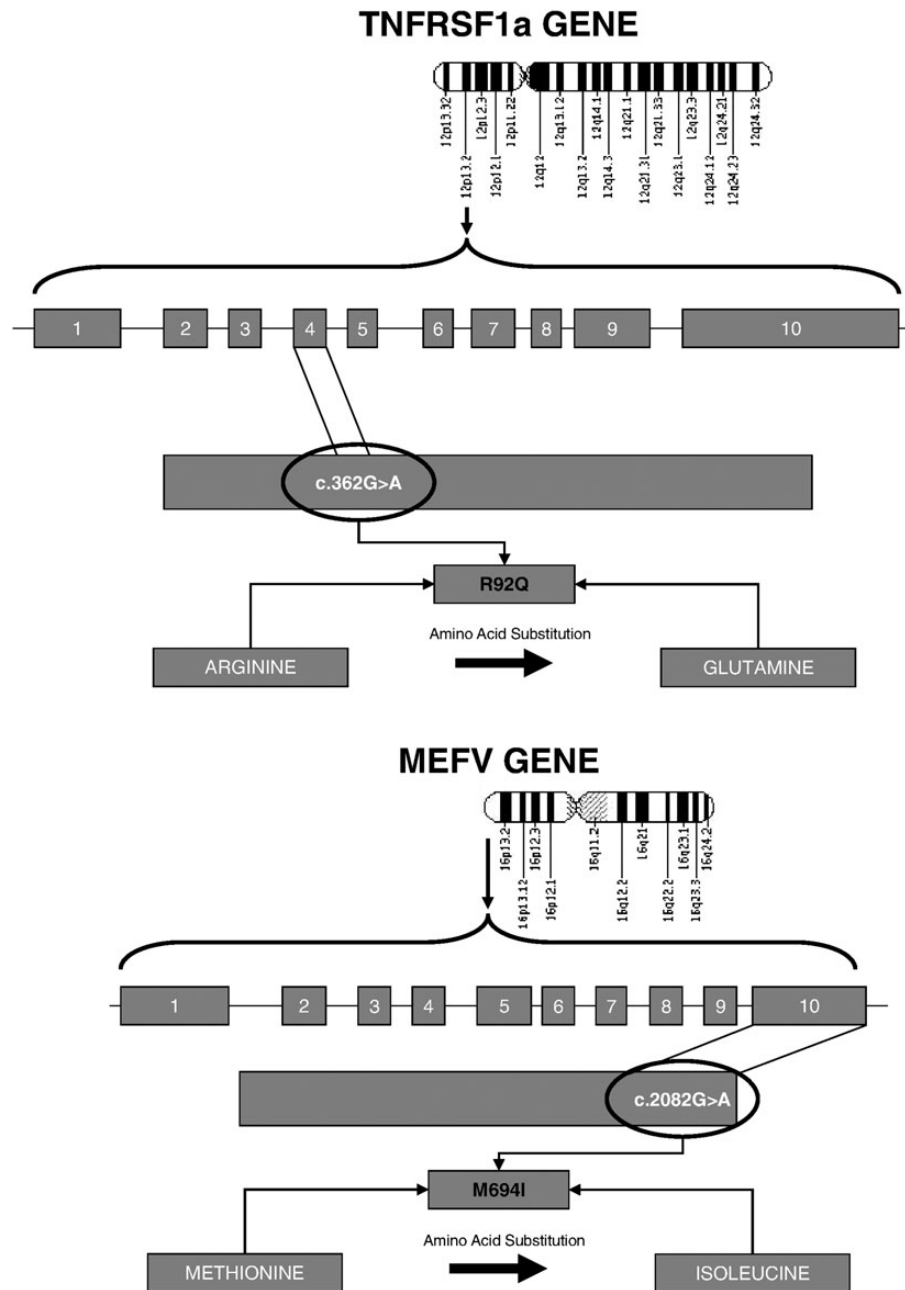


Fig. 2. Genetic mutations in both the TNFRSF1a and MEFV genes.

common finding in the setting of FMF rather than in TRAPS. These diseases may also present as what has been termed 'phenotype 2', in which renal amyloid is found without any indication of periodic fever [22]. In a large database of patients with AA amyloidosis evaluated in the UK, 9% were associated with known autoinflammatory disease and 6% were found to have 'idiopathic' AA, occurring in the absence of any apparent underlying inflammatory disease [1], as in our patient.

In summary, we describe the case of a pregnant woman of Mediterranean origin who presented with symptoms of abdominal serositis, heavy proteinuria and elevated SAA protein. Kidney and rectal biopsy were diagnostic of AA amyloidosis. Genetic testing revealed mutations in both the FMF and TRAPS genes. Although the

two mutations identified in our patient are not usually associated with amyloidosis, the presence of both together might have been determinant for the development of the disease.

*Conflict of interest statement.* None declared.

## References

1. Lachmann HJ, Goodman HJ, Gilbertson JA et al. Natural history and outcome in systemic AA amyloidosis. *N Engl J Med* 2007; 356: 2361–2371
2. van der Hilst JC, Simon A, Drenth JP. Hereditary periodic fever and reactive amyloidosis. *Clin Exp Med* 2005; 5: 87–98

3. Pras M. Amyloidosis of familial Mediterranean fever and the MEFV gene. *Amyloid* 2000; 7: 289–293
4. Marek-Yagel D, Berkun Y, Padeh S et al. Clinical disease among patients heterozygous for familial Mediterranean fever. *Arthritis Rheum* 2009; 60: 1862–1866
5. Masters SL, Simon A, Aksentijevich I et al. Horror autoinflammatory: the molecular pathophysiology of autoinflammatory disease (\*). *Annu Rev Immunol* 2009; 27: 621–668
6. Yesilada E, Taskapan H, Gulbay G. Prevalence of known mutations and novel missense mutation (M694K) in the MEFV gene in a population from the Eastern Anatolia Region of Turkey. *Gene* 2012; 511: 371–374
7. Etem E, Deveci SC, Erol D et al. Familial Mediterranean fever: a retrospective clinical and molecular study in the east of Anatolia Region of Turkey. *Open Rheumatol J* 2010; 4: 1–6
8. Koné Paut I, Dubuc M, Sportouch J et al. Phenotype-genotype correlation in 91 patients with familial Mediterranean fever reveals a high frequency of cutaneous features. *Rheumatology (Oxford)* 2000; 39: 1275–1279
9. Shinar Y, Livneh A, Langevitz P et al. Genotype-phenotype assessment of common genotypes among patients with familial Mediterranean fever. *J Rheumatol* 2000; 27: 1703–1707
10. Majeed HA, El-Shanti H, Al-Khateeb MS et al. Genotype/phenotype correlations in Arab patients with familial Mediterranean fever. *Semin Arthritis Rheum* 2002; 31: 371–376
11. Centola M, Kastner D, the International FMF Consortium. Cloning of MEFV: Implications for the pathophysiology of familial Mediterranean fever. In: Sohar E, Gafni J, Pras M (eds). *Familial Mediterranean Fever*. London: Freund Publishing House, 1997
12. Touitou I. The spectrum of Familial Mediterranean Fever (FMF) mutations. *Eur J Hum Genet* 2001; 9: 473–483
13. Simon A, van der Meer JW, Vesely R et al. International HIDS Study Group. Approach to genetic analysis in the diagnosis of hereditary autoinflammatory syndromes. *Rheumatology (Oxford)* 2006; 45: 269–273
14. Williamson LM, Hull D, Mehta R et al. Familial Hibernian fever. *Q J Med* 1982; 51: 469–480
15. Nedjai B, Hitman GA, Yousaf N et al. Abnormal tumor necrosis factor receptor I cell surface expression and NF-kappaB activation in tumor necrosis factor receptor-associated periodic syndrome. *Arthritis Rheum* 2008; 58: 273–283
16. D'Osualdo A, Ferlito F, Prigione I et al. Neutrophils from patients with TNFRSF1A mutations display resistance to tumor necrosis factor-induced apoptosis: pathogenetic and clinical implications. *Arthritis Rheum* 2006; 54: 998–1008
17. Dodé C, André M, Bienvenu T et al. French Hereditary Recurrent Inflammatory Disorder Study Group. The enlarging clinical, genetic, and population spectrum of tumor necrosis factor receptor-associated periodic syndrome. *Arthritis Rheum* 2002; 46: 2181–2188
18. Cantarini L, Lucherini OM, Muscari I et al. Tumor necrosis factor receptor-associated periodic syndrome (TRAPS): state of the art and future perspectives. *Autoimmun Rev* 2012; 12: 38–43
19. Aksentijevich I, Galon J, Soares M et al. The tumor-necrosis-factor receptor-associated periodic syndrome: new mutations in TNFRSF1A, ancestral origins, genotype-phenotype studies, and evidence for further genetic heterogeneity of periodic fevers. *Am J Hum Genet* 2001; 69: 301–314
20. Aganna E, Hammond L, Hawkins PN et al. Heterogeneity among patients with tumor necrosis factor receptor-associated periodic syndrome phenotypes. *Arthritis Rheum* 2003; 48: 2632–2644
21. Federici S, Caorsi R, Gattorno M. The autoinflammatory diseases. *Swiss Med Wkly* 2012; 142: w13602
22. Tunca M, Akar S, Onen F et al. Turkish FMF Study Group. Familial Mediterranean fever (FMF) in Turkey: results of a nationwide multicenter study. *Medicine (Baltimore)* 2005; 84: 1–11

Received for publication: 18.6.13; Accepted in revised form: 19.8.13