

Received: 2017.10.19
Accepted: 2018.02.05
Published: 2018.04.27

e-ISSN 1941-5923
© Am J Case Rep, 2018; 19: 494-499
DOI: 10.12659/AJCR.907638

Endometrial Metastasis from Ductal Breast Carcinoma: A Case Report with Literature Review

Authors' Contribution:
Study Design A
Data Collection B
Statistical Analysis C
Data Interpretation D
Manuscript Preparation E
Literature Search F
Funds Collection G

ABCDG 1 **Maryam Rahmani**
ABCD 2 **Fatemeh Nili**
BCEF 1 **Elnaz Tabibian**

1 Department of Radiology, Advanced Diagnostic and Interventional Radiology Research Center (ADIR), Imam Khomeini Hospital Complex (IKHC), Tehran University of Medical Sciences (TUMS), Tehran, I.R. Iran
2 Department of Pathology, Imam Khomeini Hospital Complex (IKHC), Tehran University of Medical Sciences (TUMS), Tehran, I.R. Iran

Corresponding Author: Elnaz Tabibian, e-mail: elnaz.tabibian@gmail.com
Conflict of interest: None declared

Patient: Female, 51
Final Diagnosis: Endometrial metastasis from ductal breast carcinoma
Symptoms: Abnormal uterine bleeding • menorrhagia
Medication: —
Clinical Procedure: Dilatation and curettage (D&C) • tissue diagnosis of the endometrium
Specialty: Obstetrics and Gynecology

Objective: Unusual clinical course


Background: There are few reports of breast cancer cases with uterine metastases; among them, myometrium is more frequently involved than endometrium. The majority of breast cancer metastases to endometrium are lobular type, and there have been only 5 reported cases of ductal type since 1984. Here, we describe a new case of invasive ductal carcinoma with metastases to endometrium and isolated presentation of abnormal uterine bleeding, in addition to reviewing the existing literature on other similar cases.

Case Report: The patient was a 51-year-old Persian woman with no remarkable past medical or family history of cancer, who presented with a 6-month complaint of menorrhagia to our gynecology clinic. Diagnostic studies including trans-vaginal ultrasonography, pathological examination of endometrial curettage specimen, immunohistochemistry findings, and X-plane and magnetic resonance mammography, and breast core-needle biopsy revealed invasive ductal breast carcinoma as the origin of the endometrial metastasis.

Conclusions: Abnormal uterine bleeding in a premenopausal patient should alert clinicians to the possibility of secondary as well as primary neoplasms. It is necessary to differentiate a metastatic tumor from a primary one, since the treatment and prognosis are completely different.

MeSH Keywords: Carcinoma, Ductal, Breast • Case Reports • Endometrium • Menorrhagia • Neoplasm Metastasis

Full-text PDF: <https://www.amjcaserep.com/abstract/index/idArt/907638>




1403



1



3



17



Background

The most prevalent organs to which breast cancer metastases often migrate are the liver, bone, and lungs [1,2]. Uterine metastasis more frequently originates from genital sites other than extra-genital tumors [3]. On the other hand, among breast metastases to gynecologic organs, the uterus is involved in only 3.8% of cases [4]. When uterine metastasis occurs, myometrium is more frequently involved than endometrium [1]. Almost 80% of genital metastases from breast origin are invasive lobular carcinoma (ILC), whereas invasive ductal carcinoma (IDC) is very rare [5]. There have been only 5 reported cases of IDC metastases to endometrium from 1985 to 2017 [4–8]. Here, we describe a unique case of IDC with no prior history of known breast cancer and who presented with an isolated complaint of abnormal uterine bleeding (AUB).

Case Report

A 51-year-old Persian premenopausal woman with no remarkable past medical or family history of cancer was referred to a gynecologic clinic with a 6-month complaint of AUB as menorrhagia. She had undergone only 2 non-scheduled sessions of screening mammography and 1 Pap smear since she turned 40 years old, and no data were accessible. In our center, by means of trans-vaginal ultrasonography (TVS), the endometrial thickness assessed at 18 mm with heterogeneous echogenicity but no evidence of focal thickening, and myometrium and adnexa were unremarkable. Therefore, she underwent a dilatation and curettage (D&C) biopsy for tissue diagnosis of the endometrium.

Microscopic examination revealed isolated or sheets of neoplastic epithelial cells infiltrated within endometrial stroma. Occasional normal endometrial glands were identified (Figure 1A). The impression was of a metastatic adenocarcinoma with suspicious gastrointestinal (GI) tract or breast cancer origin.

In light of the regional epidemiology and high prevalence of GI cancers in Iran, upper and lower GI endoscopy was performed, which showed gastric mucosa involvement by neoplastic tissue with histopathologic features identical to the endometrial curettage specimen (Figure 1A).

For better differentiation and according to the pathologist's recommendation, immunohistochemistry staining (IHC) was performed and both gastric and endometrial specimens were positive for GCDFP-15, CK₇, ER, PR, mammaglobin, and E-Cadherin antigen and negative for Her-2/neu, CK₂₀, and CDX₂. Also, Ki67 proliferative index showed 15–20% activity (Figure 1B). All the

data suggested the breast as the origin, so the next step was its diagnostic imaging.

On an X-plane mammogram, a focal asymmetry in the left breast upper outer quadrant (UOQ), a small focal asymmetry in right breast UOQ, and prominent dense axillary lymph nodes (Figure 2) were detected. On magnetic resonance mammography (MRM), bilateral multiple small enhancing masses of different sizes with different kinetic curves (including type-III) were seen, in addition to multiple prominent axillary lymph nodes (Figure 3A).

On breast US, the most prominent finding was tissue distortion, but several indistinct hypoechoic small masses with similar appearance were detected bilaterally, dominantly on the left UOQ (BIRADS: IVc) (Figure 3B), and a core-needle biopsy was obtained from one.

The pathology and positive reaction for E-Cadherin on IHC (Figure 1A) totally confirmed the invasive ductal breast adenocarcinoma; imaging and patterns supported the diagnosis of bilateral and multi-centric breast cancer. Tissue sampling from highly suspicious axillary lymph nodes showed positive involvement, as predicted.

On patient's metastasis workup before treatment, brain magnetic resonance imaging (MRI), and chest computed tomography (CT) scan were unremarkable, but whole-body bone scan and pelvic MRI demonstrated bone and ovary as suspected sites of metastasis.

Then, she started the chemotherapy regimen and fortunately completed the first 8 sessions with no plan for surgery. She is still alive and under observation, with no further involvement at 8 months after diagnosis.

Discussion

Extra-genital metastases to the female genital organs are uncommon and usually originate from gastrointestinal tract (37%) and breast (34%) malignancies [1,5]. As the most common gynecologic organ, the ovaries are affected in about 75% of such cases, followed by the vagina and cervix. Uterine corpus metastasis occurs in only 4.7% of cases. In almost two-thirds of patients, uterine involvement occurs due to retrograde lymphatic spreading of the tumor from the previously affected ovaries, but isolated uterine metastases are very rare and probably occur through hematogenous spreading [1,5,6]. Imaging modalities for evaluating uterine metastasis can be helpful by showing a myometrial nodule or a hypertrophied endometrium, which mimics a primary tumor [9].

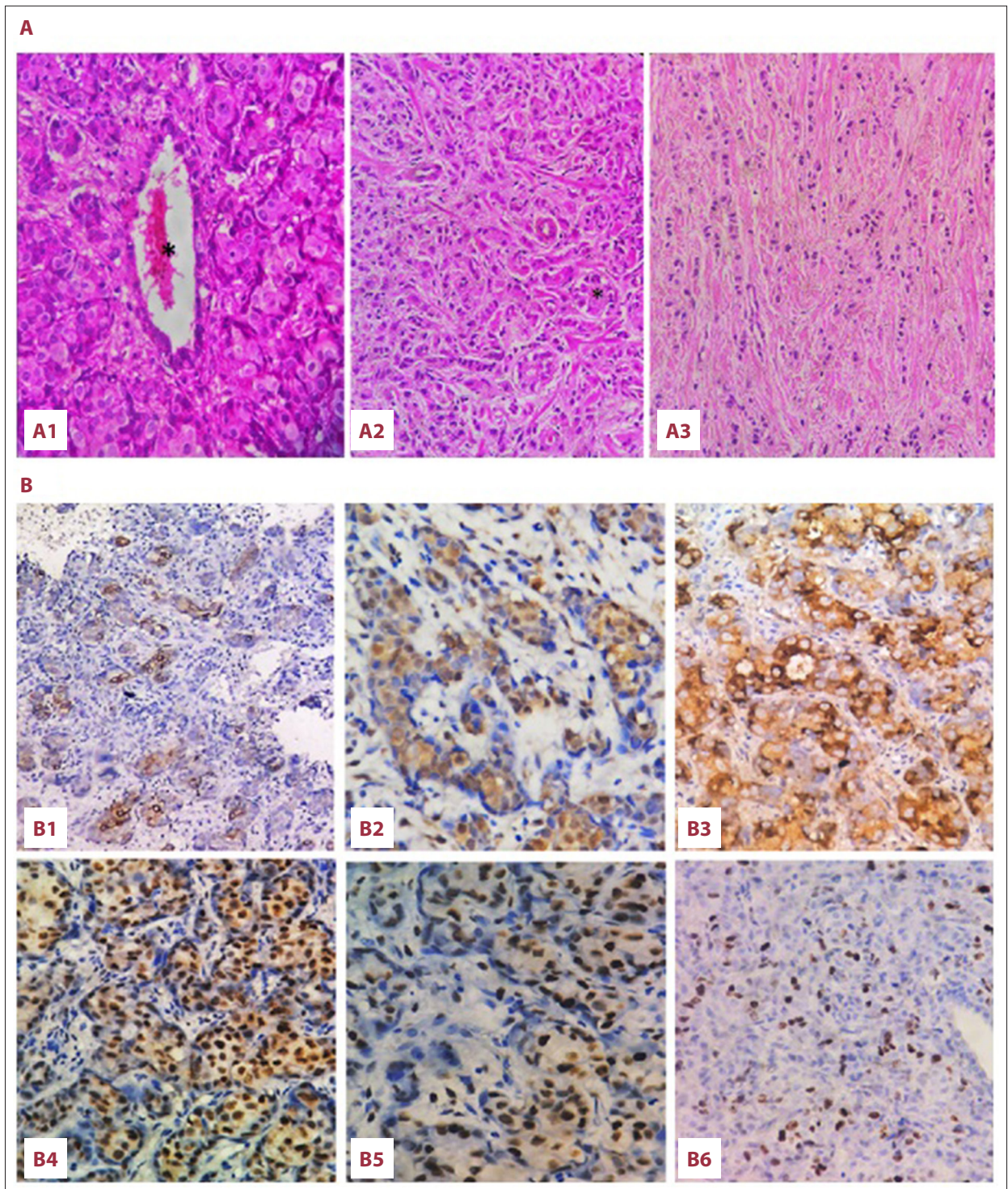


Figure 1. (A) H&E-stained sections (400×) of endometrial curettage specimen (A1), gastric mucosa (A2), and breast mass biopsies (A3) showing infiltration of small neoplastic cells with mild pleomorphism in single file, isolated cells, or small tubular structures. Occasional normal endometrial (*) and gastric glands (*) are also seen. (B) IHC study of an endometrial specimen showed positive immune reaction with CK7 (B1), mammaglobin (B2), GCDFP-15 (B3), ER (B4) and PR (B5). Ki67 proliferative marker (B6) was about 15–20%.

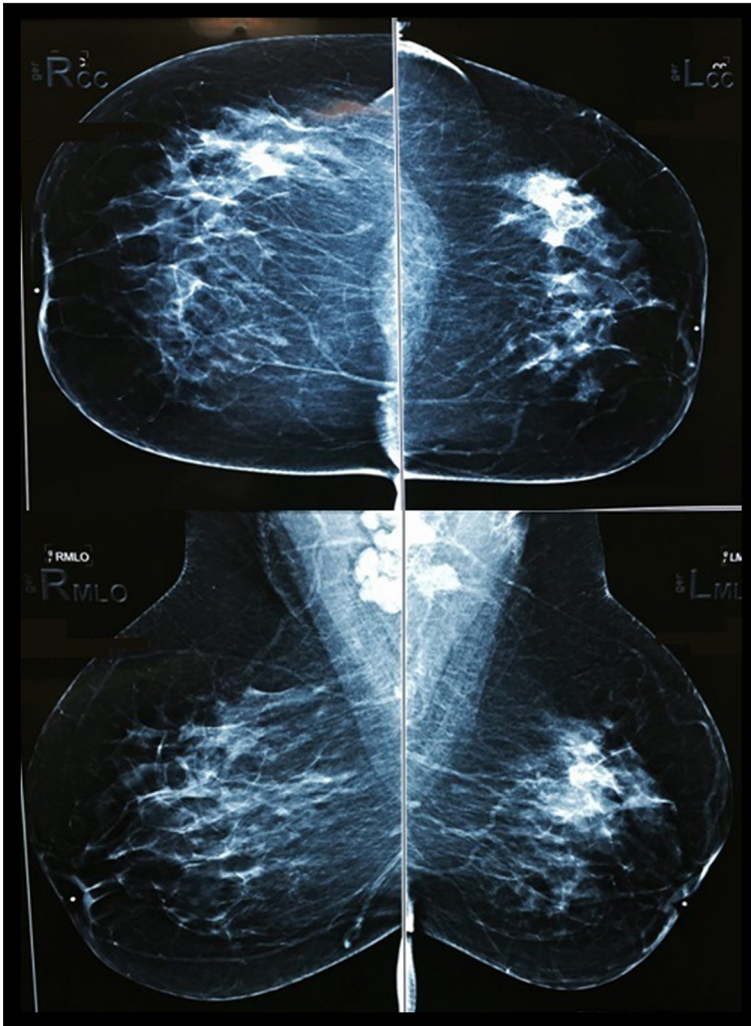


Figure 2. X-plane mammogram: a focal asymmetry in left breast upper outer quadrant (UOQ), a small focal asymmetry in right breast UOQ, and bilateral prominent dense axillary lymph nodes are seen.

Endometrial metastases usually present with AUB as the first symptom [10]. There are many diagnostic problems in confirming endometrial metastasis. Some criteria that must be met are: (1) Histopathologic features of the metastatic tumor should be identical to the original neoplasm, with no detection of coexisting primary neoplastic changes in the destination organ (uterus) [5,6,11,12]; (2) In known breast cancer patients, a hormone-induced (tamoxifen) endometrial neoplasm should be excluded; and (3) A consistent IHC is necessary to determine the original tumor (e.g., GCDP15 and mammaglobin are specific and differentiating markers in favor of breast origin rather than primary endometrial carcinoma). GI malignancies usually express CK20 and CDx2 whereas endometrial and breast carcinoma are CK7-positive and CK20-negative. In breast cancers, those with tubule formation and positive reaction with E-Cadherin are ductal type [6,12]. Our patient's IHC results were completely compatible with the prototype pattern of IDC.

Few studies have discussed breast metastases to the uterus. A case series in 1982 identified 63 uterine metastases from extra-genital origins, of which 43% were breast malignancies. Researchers demonstrated that when uterine metastases occur, myometrium is more often (96%) involved than endometrium (42%) [1]. In 1984, Mazur et al. reviewed 52 cases of metastatic breast cancer to the gynecologic organs during a 32-year period; endometrium was the metastatic site in only 2 patients, whereas 46 cases were metastases to ovary [4]. A comprehensive literature review performed by Huo et al. identified 13 cases of breast metastasis to the endometrium between 1984 and 2015, demonstrating that ER/PR-positive tumors, especially from lobular type (ILC), were more likely to result in endometrial metastasis in comparison to IDC [5,6]. Most of these uterine metastases were detected in known cases of breast cancer patients during their follow-up and hormone therapy period, and in 2016 Cift et al. reported a known case of ductal breast carcinoma under tamoxifen therapy who had myometrial metastasis [1,6–8,11,13,14]; there was only 1 patient in Delhi who had no prior history of cancer [15] such as

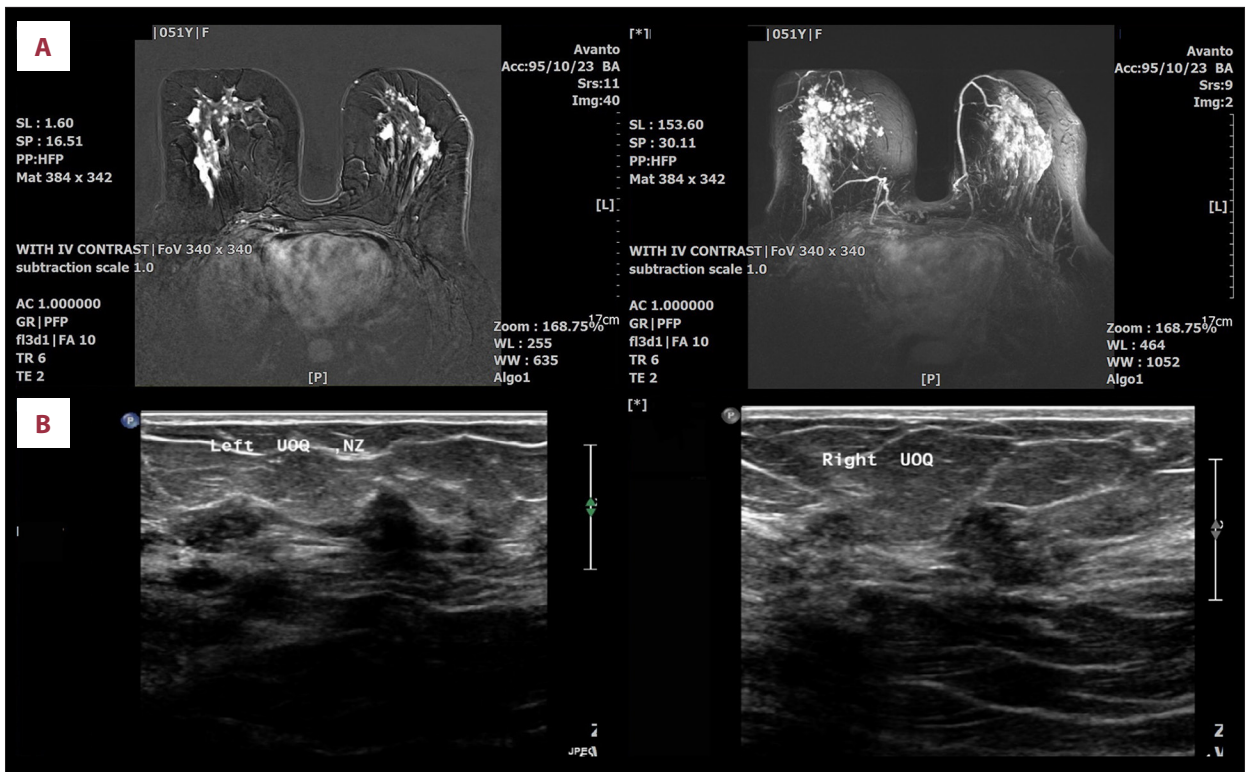


Figure 3. (A) Magnetic resonance mammography (MRM): bilateral multiple small enhancing masses of different sizes are seen. (B) Breast ultrasound: bilateral tissue distortion and indistinct hypochoic small masses are shown (BIRADS: IVC).

Table 1. Cases of endometrial metastases from invasive ductal breast carcinoma.

Author	Year	Age	Tumor Type	Metastases Sites	Recurrence interval	ER	PR	HER-2	TNM stage	Outcome
Kennebeck CH [8]	1998	71	Ductal	Endometrium, cervix	2.5 years	-	-	-	T1N1M0	Alive 10 months
Meydanli M [13]	2002	45	Ductal	Endometrium	6 years	+	NM	NM	T2N1M0	Alive 4 months
Karvouni E [7]	2008	51	Ductal	Endometrium, liver, bone	3 years	+	-	-	TxN1M0	Died in 4 months
Arslan D [5]	2013	57	Ductal	Endometrium, myometrium	2 years	+	+	-	T1bN3aM0	Alive (up to Mar 2013)
Hou Z [6]	2015	66	Ductal	Endometrium	11 years	-	-	-	T2N0M0	Alive (up to Jul 2015)
Rahmani M (our case)	2017	51	Ductal	Endometrium, gastric mucosa, bone, ovary	New case	+	+	-	T2N3M1	Alive up to 8 months

ER – estrogen receptor; PR – progesterone receptor; HER-2 – human epidermal growth factor receptor 2; TNM – tumor-node-metastasis, NM – not mentioned.

ours, which might be due to poor compliance of cancer screening programs in both countries (India and Iran).

According to the literature review through English articles published up to August 2017, there have been only 5 reported

cases of endometrial metastases with IDC origin. Among them, 1 case was ER/PR-positive (like ours) [5], 2 cases were only ER-positive [7,13] and the other 2 were ER/PR-negative [6,8]. All 4 Her-2/neu receptors were negative (as in our case) [5–8] and the other study did not provide this information [13]. Four

patients were over 50 years old. The mean time of recurrence was about 5 years; only 1 patient had recurrence after more than 10 years [6]. Our patient was unique in that she had no prior known history of breast cancer and her first presentation was isolated AUB. Also, she had simultaneous gastric involvement. Complete data are provided in Table 1.

This case report and literature review emphasizes the importance of complete workup and exact diagnosis in patients with AUB, particularly in the presence of prior breast cancer history. It should be noted that breast cancer patients under hormonal regimens like aromatase inhibitors or tamoxifen may have primary endometrial cancer as well as uterine metastases [16].

It is necessary to differentiate a metastatic breast tumor from a primary genital neoplasm, since the treatments and prognoses are completely different [6]; a primary uterine neoplasm can be surgically resected, while in uterine metastases surgical intervention does not appear to be indicated and systemic chemotherapy would be probably better [6,14]. However, based

on Kaplan-Meier survival analysis it is still not clear if hysterectomy enhances survival [17]. On the other hand, because of the limited number of case reports, there is not enough data about the prognosis. Although the majority of studies considered uterine metastasis as a poor prognostic pre-terminal event, more studies are needed to improve our knowledge about the best treatment and precise prognosis [7].

Conclusions

Endometrial metastasis can present as an isolated complaint of AUB. Therefore, abnormal menses of a premenopausal woman should alert clinicians to consider the possibility of secondary as well as primary neoplasms, especially in known cancer cases, regardless of hormonal therapy [7,16].

Conflict of interests

None.

References:

1. Kumar NB, Hart WR: Metastases to the uterine corpus from extra genital cancers. A clinic pathologic study of 63 cases. *Cancer*, 1982; 50(10): 2163–69
2. Hara F, Kiyoto S, Takabatake D et al: Endometrial metastases from breast cancer during adjuvant endocrine therapy. *Case Rep Oncol*, 2010; 3(2): 137–41
3. Razia S, Nakayama K, Tsukao M et al: Metastasis of breast cancer to an endometrial polyp, the cervix and a leiomyoma: A case report and review of the literature. *Oncol Lett*, 2017; 14(4): 4585–92
4. Mazur MT, Hsueh S, Gersell DJ: Metastases to the female genital tract: Analysis of 325 cases. *Cancer*, 1984; 53(9): 1978–84
5. Arslan D, Tural D, Tatli AM et al: Isolated uterine metastasis of invasive ductal carcinoma. *Case Rep Oncol Med*, 2013; 2013: 793418
6. Huo Z, Gao Y, Zuo W et al: Metastases of basal-like breast invasive ductal carcinoma to the endometrium: A case report and review of the literature. *Thorac Cancer*, 2015; 6(4): 548–52
7. Karvouni E, Papakonstantinou K, Dimopoulou C et al: Abnormal uterine bleeding as a presentation of metastatic breast disease in a patient with advanced breast cancer. *Arch Gynecol Obstet*, 2009; 279(2): 199–201
8. Kennebeck CH, Alagoz T: Signet ring breast carcinoma metastases limited to the endometrium and cervix. *Gynecol Oncol*, 1998; 71(3): 461–64
9. Toguchi M, Matsuki M, Numoto I, Tsurusaki M: Imaging of metastases from breast cancer to uncommon sites: A pictorial review. *Jpn J Radiol*, 2016; 34(6): 400–8
10. Kumar A, Schneider V: Metastases to the uterus from extrapelvic primary tumors. *Int J Gynecol Pathol*, 1983; 2(2): 134–40
11. Scopa CD, Aletra C, Lifschitz-Mercer B, Czernobilsky B: Metastases of breast carcinoma to the uterus. Report of two cases, one harboring a primary endometrioid carcinoma, with review of the literature. *Gynecol Oncol*, 2005; 96(2): 543–47
12. Aksahin A, Colak D, Gureli M: Endometrial metastases in breast cancer: A rare event. *Arch Gynecol Obstet*, 2013; 287(6): 1273–75
13. Meydanli MM, Karadag N, Ataoglu O, Kafkasli A: Uterine metastases from infiltrating ductal carcinoma of breast in a patient receiving tamoxifen. *Breast*, 2002; 11(4): 353–56
14. Cift T, Aslan B, Bulut B, Ilvan S: Unusual uterine metastasis of invasive ductal carcinoma: A case report. *Turk J Obstet Gynecol*, 2016; 13(3): 164–66
15. D'souza MM, Sharma R, Tripathi M et al: Cervical and uterine metastasis from carcinoma of breast diagnosed by PET-CT: An unusual presentation. *Clin Nucl Med*, 2010; 35(10): 820–23
16. Groß S, deWaal J, Neteler J, Debus G: Uterocervical metastasis of an invasive ductal breast carcinoma: A case report. *Geburtsh Frauenheilk*, 2011; 71(2): 144–46
17. Rodrigues F, Carneiro F, Lopes C: Uterine metastasis from breast cancer – retrospective analysis of 15 cases. *Acta Obstet Ginecol Port*, 2015; 9(1): 27–33