



## Original Research

# Can Unilateral Therapeutic Central Lymph Node Dissection Be Performed in Papillary Thyroid Cancer with Lateral Neck Metastasis?

Isik Cetinoglu, Nurcihan Aygun, Ceylan Yanar, Ozan Caliskan, Mehmet Kostek, Mehmet Taner Unlu, Mehmet Uludag

Department of General Surgery, University of Health Sciences Türkiye, Sisli Hamidiye Etfal Training and Research Hospital, Istanbul, Türkiye

### Abstract

**Objectives:** Unilateral or bilateral prophylactic central neck dissection (CND) in papillary thyroid cancer (PTC) is still controversial. We aimed to evaluate the risk factors for contralateral paratracheal lymph node metastasis and whether CND might be performed unilaterally.

**Methods:** Prospectively collected data of patients who underwent bilateral CND and lateral neck dissection (LND) with thyroidectomy due to PTC with lateral metastases, between January 2012 and November 2019, were evaluated retrospectively. The patients were divided into two groups according to the presence (Group 1) and absence (Group 2) of metastasis in the contralateral paratracheal region.

A total of 42 patients (46 ±15.7 years) were operated. In the contralateral paratracheal region, Group 1 (35.7%) had metastases, while Group 2 (64.3%) had no metastases. In groups 1 and 2, metastasis rates were 100% vs 77.8% (p=0.073), 46.7% vs 18.5% (p=0.078), and 80% vs 40.7% (p=0.023) for the ipsilateral paratracheal, prelaryngeal and pretracheal lymph nodes, respectively.

The number of metastatic lymph nodes in the central region was significantly higher in Group 1 compared to Group 2 as; 10.7±8.4 vs. 2.6±2.4 (p=0.001) in bilateral central region material; 8.3±7.4 vs. 2.9±2.7 (p=0.001) in lateral metastasis with ipsilateral unilateral central region; 3.8±3.4 vs. 1.9±1.9 (p=0.023) in ipsilateral paratracheal area; and 3.7±4.6 vs. 0.6±0.9 (p=0.001) in pretracheal region, respectively. However, no significant difference was found regarding the prelaryngeal region material (0.9±1.8 vs. 0.2±0.4 (p=0.71)).

**Results:** >2 metastatic central lymph nodes in unilateral CND material (AUC: 0.814, p<0.001, J=0.563) can estimate contralateral paratracheal metastasis with 93% sensitivity, 63% specificity, while >2 pretracheal metastatic lymph nodes (AUC: 0.795, p<0.001, J: 0.563) can estimate contralateral paratracheal metastasis with 60% sensitivity and 96.3% specificity.

**Conclusion:** In patients with lateral metastases, the rate of ipsilateral paratracheal metastasis is 85%, while the rate of contralateral paratracheal metastasis is 35.7%. The number of ipsilateral central region or pretracheal lymph node metastases may be helpful in predicting contralateral paratracheal lymph node metastases. Notably, unilateral CND may be performed in the presence of ≤ 2 metastases in the ipsilateral central region.

**Keywords:** Central neck dissection, lateral neck metastasis, papillary thyroid cancer

Please cite this article as "Cetinoglu I, Aygun N, Yanar C, Caliskan O, Kostek M, Unlu MT, et al. Can Unilateral Therapeutic Central Lymph Node Dissection Be Performed in Papillary Thyroid Cancer with Lateral Neck Metastasis? Med Bull Sisli Etfal Hosp 2023;57(4):458–465".

**Address for correspondence:** Isik Cetinoglu, MD. Department of General Surgery, University of Health Sciences Türkiye, Sisli Hamidiye Etfal Training and Research Hospital, Istanbul, Türkiye

**Phone:** +90 537 334 80 38 **E-mail:** isikcetinoglu@gmail.com

**Submitted Date:** December 13, 2023 **Accepted Date:** December 26, 2023 **Available Online Date:** December 29, 2023

©Copyright 2023 by The Medical Bulletin of Sisli Etfal Hospital - Available online at [www.sislietfaltip.org](http://www.sislietfaltip.org)

**OPEN ACCESS** This is an open access article under the CC BY-NC license (<http://creativecommons.org/licenses/by-nc/4.0/>).



Thyroid cancers are among the most common endocrine malignancies, with over 90% of these malignancies originating from thyroid follicular cells and classified as differentiated thyroid cancers (DTC).<sup>[1,2]</sup> Papillary thyroid cancers account for approximately 85% of DTC cases.<sup>[2]</sup> Other prevalent forms of DTC include Hurthle cell carcinoma (HTC) and follicular thyroid carcinoma (FTC).<sup>[1]</sup>

Cervical lymph node metastasis is a common occurrence in DTC, with clinical metastasis rates ranging from 20% to 50%. However, the micrometastasis rate (less than 2 mm) increases to 90%, although its clinical significance is lower than that of macrometastasis.<sup>[3]</sup> The typical pattern of lymph node metastasis starts with ipsilateral paratracheal lymph nodes in the central region, followed by contralateral paratracheal lymph nodes, and then extends to the lateral neck. After affecting the central compartment, further spread is predominantly observed in Levels IIA, III, IV, VB, and occasionally in Levels IIB and VA.<sup>[4]</sup> Skip metastasis to the lateral region without involvement of the central area occurs in 3.5-21.8% of cases and is more common in tumors of the upper pole.<sup>[5-8]</sup>

The standard treatment approach for DTC patients with clinically affected central lymph nodes involves therapeutic central neck dissection (tCND). However, there has been an ongoing debate regarding the extent of tCND.<sup>[2,5,9-11]</sup> Recent guidelines generally recommend prophylactic central neck dissection for patients with lateral metastases (N1b), even in the absence of clinical central metastasis (cN0), particularly for cases with advanced primary tumors (T3 or T4). This recommendation is based on the observed pattern of lymph node metastasis, which starts centrally and then spreads to the lateral region.<sup>[4]</sup> Nevertheless, there remains controversy regarding the extent of neck dissection, whether for therapeutic or prophylactic CNDs. Analysis of the literature reveals varying recommendations from different guidelines. According to the British Thyroid Association guidelines, both bilateral prophylactic central neck dissection (pCND) and tCND are recommended to ensure comprehensive staging.<sup>[9]</sup> The American Thyroid Association (ATA) guideline suggests that pCND can be performed unilaterally or bilaterally depending on individual patient characteristics, but bilateral tCND is recommended when there is preoperative evidence of central metastasis.<sup>[12]</sup> The NCCN Guideline indicates that both bilateral and unilateral tCND procedures are acceptable.<sup>[13]</sup> Additionally, the European Society of Endocrine Surgeons and the American Head and Neck Society suggest that unilateral pCND and tCND may be considered to minimize potential complications.<sup>[5, 10]</sup>

Studies have reported a notably high prevalence of occult contralateral paratracheal metastases in patients with lat-

eral metastases (34.5%), albeit lower than the rate of ipsilateral paratracheal metastasis (82.9%).<sup>[14]</sup> Given the high rate of occult metastases and the limited sensitivity of imaging tests in detecting contralateral central compartment involvement, Keum et al.<sup>[15]</sup> recommended bilateral central neck dissection in cases of therapeutic lateral neck dissection (LND). In a recent study, patients with ipsilateral central metastases who underwent routine bilateral central dissection, regardless of the presence of contralateral paratracheal metastases, were evaluated. These patients were followed up for a median of 83.2 months. While the overall recurrence rate was 11.5% in cases with contralateral central neck metastasis, it was 6% in cases without metastasis ( $p=0.064$ ). Contralateral recurrence rates were 1.2% vs. 0.8%, respectively ( $p=1.000$ ). Ultimately, it was concluded that contralateral central metastasis was not a significant factor in increasing the risk of recurrence.<sup>[16]</sup>

A major complication associated with bilateral central neck dissection is transient or permanent hypoparathyroidism. Therefore, the decision to perform bilateral dissection should be made cautiously. It is suggested that if lymph node metastasis is detected in the intraoperative frozen section pathology, central neck dissection should be performed. This strategy limits surgical treatment of bilateral CND to patients with intraoperative pathological evidence of lymph node metastases.<sup>[17,18]</sup> Despite the various risks associated with bilateral pCND, the manageable rates of contralateral central metastasis and recurrence make unilateral pCND a reasonable treatment option.<sup>[4]</sup> Currently, the application of pCND is gradually decreasing. Despite limited studies on this topic, recent research suggests that central dissection may not be necessary for patients with clinical lateral metastases, further adding to the controversy.<sup>[19-21]</sup>

Until very recently, routine bilateral therapeutic or prophylactic CND was performed in PTC patients with lateral metastases. In this study, we aim to assess the risk factors for contralateral paratracheal lymph node metastasis and explore the possibility of performing unilateral central dissection.

## Methods

### Patient Selection

Retrospective evaluation of prospectively recorded data from patients operated on for Papillary Thyroid Cancer (PTC) with lateral neck metastases at our clinic between 2012 and 2019 was conducted. This study adhered to the principles of the Helsinki Declaration and received approval from the local Ethics Committee (Decision No: 2950, Date: 25/07/2020). Patients who underwent bilateral lateral neck dissection (LND), those with prior central or lateral neck dis-

section, and those with inaccessible data were excluded. The study included patients diagnosed with PTC who underwent therapeutic or prophylactic Bilateral Central Neck Dissection (BCND) and therapeutic selective LND in addition to total thyroidectomy. We defined Central Neck Dissection (CND) in accordance with the American Thyroid Association Surgery Working Group definitions: therapeutic if nodal metastasis was clinically or radiologically detected in the central region preoperatively or intraoperatively, and prophylactic (elective) if no nodal metastasis was present in the central region.<sup>[12]</sup>

### Preoperative Evaluation

High-resolution ultrasonography (USG) was performed for thyroid and neck lymph node assessment in all patients. Preoperative lymph node sampling was conducted in patients with suspected lateral neck metastasis based on clinical and USG findings. Patients with confirmed lateral metastasis through fine-needle aspiration biopsy (FNAB) and/or thyroglobulin washout underwent therapeutic lateral neck dissection. Magnetic resonance imaging or computed tomography scans were performed in cases with locally advanced tumors, conglomerate lymph nodes, or suspicion of local invasion into adjacent organs.

### Surgical Procedures

Central neck compartment comprises lymph nodes in levels VI and VII, defined vertically between the hyoid bone and sternal notch and bilaterally between the carotid arteries. Level VII encompasses superior mediastinal lymph nodes, with the inferior boundary at the lowest part of CND as per ATA guidelines. The central region includes prelaryngeal (Delphian), pretracheal, right, and left paratracheal lymph node subcompartments, dissected independently during CND for PTC. Unilateral or bilateral CND is determined by the extent of paratracheal dissection.<sup>[5,12,22,23]</sup> Compartmental selective LND included at least level III and IV or level II, III, IV. Level V dissection was added for patients with clinical and USG-suspected metastasis at this level. All operations were guided by intraoperative nerve monitoring. Surgical samples were separated according to anatomical compartment boundaries, and central region dissection material was subdivided into subcompartmental sections and submitted for pathology evaluation.

### Patient Categorization

Patients were categorized into two groups based on pathological findings: those with contralateral paratracheal lateral metastasis (Group 1) and those without (Group 2). Demographic features, tumor histopathology, tumor diameter, TNM stage, thyroid capsule invasion, extrathyroidal

extension, lymphovascular invasion, multifocality, bilaterality, central metastasis, pretracheal metastasis, prelaryngeal metastasis, presence of unilateral lateral metastasis, and ipsilateral paratracheal metastasis were analyzed between the two groups. The relationship between clinicopathological factors and lymph node metastases to the contralateral central neck compartment was examined. Multifocality was defined when more than one tumor focus was present in a single lobe, while multicentricity (bilaterality) indicated tumoral tissue in both lobes.<sup>[24]</sup>

### Statistical Analysis

Statistical analysis was performed using SPSS software (version 21, SPSS Inc., Chicago, USA). Descriptive statistics including mean, standard deviation, frequency, percentage, minimum, and maximum were used to summarize study data. Non-normally distributed quantitative variables between the two groups were compared using the Mann-Whitney U test. Qualitative data were compared using Fisher's exact test and the Pearson Chi-square test. A significance level of  $p < 0.05$  was set for statistical significance. Multinomial logistic regression analysis was applied to identify risk factors for predicting contralateral paratracheal metastases in two appropriate models. Receiver Operating Characteristics (ROC) curves were used to determine sensitivity and specificity for pretracheal metastasis, unilateral central metastasis, ipsilateral paratracheal metastasis compared to lateral metastasis, prelaryngeal metastasis, and ipsilateral paratracheal metastasis. The Youden index was utilized to calculate appropriate cutoff values, with a Youden index above 0.5 indicating appropriateness.

### Results

Unilateral compartmental selective LND was performed in 42 patients (18 males, 24 females) with a mean age of  $46 \pm 15.7$  years due to Papillary Thyroid Cancer (PTC) with lateral metastases. The surgical procedures included Level III and IV selective LND in 1 patient, Level II, III, IV selective LND in 25 patients, and Level II, III, IV, V selective LND in 16 patients. Among these patients, contralateral paratracheal metastasis was detected in 15 patients (35.7%) (Group 1), while 27 patients (64.3%) showed no metastasis (Group 2). Ipsilateral paratracheal metastasis was observed in 36 patients (85.7%), prelaryngeal metastasis in 12 patients (28.6%), pretracheal metastasis in 23 patients (54.8%), and skip metastasis to the lateral region without central region tumor involvement in 4 patients (9.5%). There were no significant differences between the two groups in terms of age, gender, tumor diameter, T stage, thyroid capsule invasion, extrathyroidal extension, multifocality, multicentricity, and lymphovascular invasion (Table 1).

**Table 1.** Comparison of Demographic Data and Tumor Histopathological Features Among Groups.

Features	Grup 1 (contralateral paratracheal metastasis (+) (n=15)	Grup 2 (contralateral paratracheal metastasis (-) (n=27)	p
Gender, n (%)			
Male	6 (40%)	12 (44.4%)	0.780
Female	9 (60%)	15 (55.6%)	
Age (year) (Mean±SD) (Min-Max)	44.7±13.7 (21-75)	46.7±16.9 (19 - 81)	0.713
Tumor size (cm) (Mean±SD) (min-max)	2.49±17.20 (1.0-7.0)	1.97±1.68 (0.5-6.0)	0.127
T Stage, (n) (%)			0.338
T1	9 (60%)	19 (70.4%)	
T2	4 (26.7%)	2 (7.4%)	
T3	2 (13.3%)	5 (18.5%)	
T4	0	1 (3.7%)	
ETE (+), n (%)	7 (46.7%)	14 (51.9%)	0.747
Thyroid Capsule Invasion (+), n (%)	8 (53.3%)	11 (40.7%)	0.432
Lymphovascular Invasion, n (%)	12 (80%)	19 (70.4%)	0.717
Multifocality, n (%)	10 (66.7%)	19 (70.4%)	0.804
Bilaterality, n (%)	9 (60%)	13 (48.1%)	0.461
Central LNM, (n) (Mean±SD) (Min-Max)	10.7±8.4 (3-28)	2.6±2.4 (0-9)	0.001
Categorical Central LNM (n)			0.000
0	0	4 (14.8%)	
1-5	3 (20%)	19 (70.4%)	
6-10	8 (53.3%)	4 (14.8%)	
>10	4 (26.7%)	0	
Unilateral (+) Central LNM (n) (Mean±SD) (Min-Max)	8.3±7.4 (2-27)	2.9±2.7 (0-9)	0.001
Prelaryngeal LNM (+), n (%)	7 (46.7%)	5 (18.5%)	0.078
Prelaryngeal (+) LNM (n) (Mean ±SD) (Min-Max)	0.9±1.8 (0-7)	0.2±0.4 (0-1)	0.071
Pretracheal metastasis +, n (%)	12 (80%)	11 (40.7%)	0.023
Pretracheal (+) LNM (n) (Mean±SD) (Min-Max)	3.7±4.6 (0-18)	0.6±0.9 (0-3)	0.001
Ipsilateral paratracheal LNM (+), n (%)	15 (100%)	21 (77.8%)	0.073
Ipsilateral Paratracheal LNM (n)	3.8±3.4 (1-12)	1.9±1.9 (0-8)	0.023
Lateral (+) LNM (n)	6.1±3.7 (2-15)	4.2±3.6 (1-15)	0.420

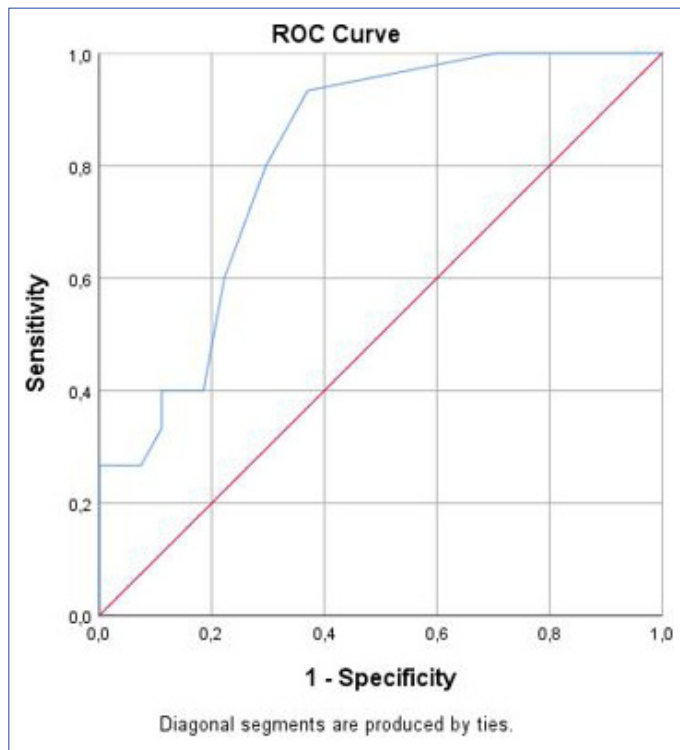
LNM: Lymph Node Metastasis; ETE: Extrathyroidal Extension.

The rates of pretracheal metastasis were significantly higher in Group 1 compared to Group 2 (80% vs. 40.7%,  $p=0.023$ ). Although the rates were higher in Group 1 for prelaryngeal metastasis (46.7% vs. 18.5%,  $p=0.078$ ) and ipsilateral paratracheal metastasis (100% vs. 77.8%,  $p=0.073$ ), the differences were not statistically significant. Two different multivariate models, including ipsilateral paratracheal metastasis, prelaryngeal metastasis, pretracheal metastasis, and bilateral tumor presence, or ipsilateral paratracheal metastasis, prelaryngeal metastasis, pretracheal metastasis, and multifocal tumor presence, were suitable for multivariate evaluation ( $p=0.021$ ,  $p=0.019$ , respectively). However, no independent risk factor was found in predict-

ing contralateral paratracheal metastasis in these two multivariate analyses.

The number of metastatic lymph nodes in the central region was significantly higher in Group 1 compared to Group 2, with values of  $10.7\pm 8.4$  vs.  $2.6\pm 2.4$  ( $p=0.001$ ) in bilateral central region material,  $8.3\pm 7.4$  vs.  $2.9\pm 2.7$  ( $p=0.001$ ) in lateral metastasis with ipsilateral unilateral central region,  $3.8\pm 3.4$  vs.  $1.9\pm 1.9$  ( $p=0.023$ ) in the ipsilateral paratracheal area, and  $3.7\pm 4.6$  vs.  $0.6\pm 0.9$  ( $p=0.001$ ) in the pretracheal region, respectively. However, no significant difference was found between the two groups regarding the prelaryngeal region material ( $0.9\pm 1.8$  vs.  $0.2\pm 0.4$ ,  $p=0.71$ ).

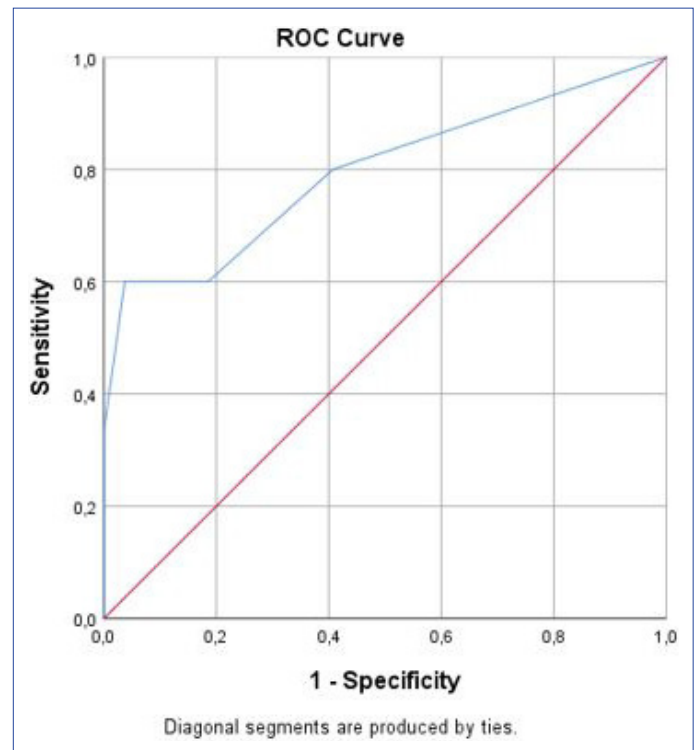
Optimal cutoff values obtained using ROC Curve analysis and the Youden index (J) led to two conclusions: >2 metastatic central lymph nodes in unilateral Central Neck Dissection (CND) material (AUC: 0.814,  $p < 0.001$ ,  $J = 0.563$ ) can estimate contralateral paratracheal metastasis with 93% sensitivity and 63% specificity (Fig. 1), while >2 pretracheal metastatic lymph nodes (AUC=0.795,  $p < 0.001$ ,  $J = 0.563$ ) can estimate contralateral paratracheal metastasis with 60% sensitivity and 96.3% specificity (Fig. 2) (Table 2).



**Figure 1.** KROC Curve for predicting contralateral paratracheal metastasis based on the number of metastatic lymph nodes in unilateral central dissection on the lateral metastasis side.

## Discussion

One of the most contentious issues in the management of Papillary Thyroid Cancer (PTC) is whether central neck dissection should be performed and, if so, to what extent. This debate also extends to patients with clinical lateral metastases. While many guidelines recommend prophylactic Central Neck Dissection (pCND) in certain cases, the latest version of the NCCN guideline suggests therapeutic Central Neck Dissection (tCND) only for clinically positive and/or biopsy-proven central nodal metastases in PTC. Al-



**Figure 2.** The ROC Curve for predicting contralateral paratracheal metastasis based on the number of pretracheal metastatic lymph nodes.

**Table 2.** To determine the optimal cutoff value for predicting contralateral paratracheal metastasis according to unilateral central metastasis, ipsilateral paratracheal metastasis with lateral metastasis, and pretracheal and prelaryngeal metastatic lymph node counts using Receiver Operating Characteristic (ROC) curve and Youden index analyses.

	Unilateral central metastasis	Ipsilateral Paratracheal metastasis	Pretracheal metastasis	Prelaryngeal metastasis
Area under the curve	0.814	0.710	0.795	0.637
Standard error	0.065	0.079	0.078	0.080
p	<0.001	0.008	<0.001	0.085
95% Confidence Interval	0.663-0.917	0.549-0.839	0.642-0.904	0.474-0.780
Youden index (J)	0.563	0.289	0.563	0.244
Number of Positive Lymph Nodes as a Criterion	>2	>1	>2	>0
Sensitivity	93.3%	73.3%	60%	46.7%
Specificity	63%	56.6%	96.3%	77.8%



though pCND is not recommended, it is emphasized that ipsilateral CND is necessary on the side where Lateral Neck Dissection (LND) will be performed in most patients with lateral metastases.<sup>[13]</sup> Currently, it is generally accepted to perform CND in the presence of lateral region metastases. The debate about the extent of dissection persists, especially when there is no clinical metastasis in the contralateral paratracheal area.<sup>[2,5,10]</sup>

In this study, we assessed the prevalence of metastases in different compartments of the central neck region and factors predictive of central metastasis extent in patients with lateral metastases. Skip metastasis may sometimes occur in patients with lateral metastases. It has been reported that being in the central part of the thyroid lobe and having fewer than 4 lateral metastases are independent protective risk factors for the development of a central neck tumor. The absence of central metastasis is a positive prognostic factor.<sup>[25]</sup>

In our study, the rate of ipsilateral paratracheal metastasis in cases with lateral metastasis was 85.7%. The rate of contralateral paratracheal metastasis was 35.7%, with a skip metastasis ratio of 9.5%. These results are consistent with a limited number of other studies in the literature.<sup>[14,26]</sup>

The pretracheal metastasis rate was significantly higher in the group with contralateral paratracheal metastasis than in the group without contralateral paratracheal metastasis (80% vs. 40.7%, respectively;  $p=0.023$ ). Although prelaryngeal (46.7% vs. 18.5%, respectively;  $p=0.078$ ) and ipsilateral paratracheal (100% vs. 77.8%, respectively;  $p=0.073$ ) metastasis rates were higher in Group 1, the differences were not statistically significant. In Group 1, compared to Group 2, the number of metastatic lymph nodes in the unilateral central region material ( $8.3\pm 7.4$  vs.  $2.9\pm 2.7$ ;  $p=0.001$ ) was higher. Additionally, the number of ipsilateral paratracheal metastatic lymph nodes ( $3.8\pm 3.4$  vs.  $1.9\pm 1.9$ ;  $p=0.023$ ) and pretracheal metastatic lymph nodes ( $3.7\pm 4.6$  vs.  $0.6\pm 0.9$ ;  $p=0.001$ ) was significantly higher. No significant difference was found between the two groups regarding the number of metastatic lymph nodes in the prelaryngeal region material ( $0.9\pm 1.8$  vs.  $0.2\pm 0.4$ ;  $p=0.71$ ).

ROC curve analysis identified two factors predicting contralateral paratracheal metastasis. These risk factors are the presence of  $>2$  metastatic central lymph nodes in unilateral Central Neck Dissection (CND) material (AUC=0.814,  $p<0.001$ ,  $J=0.563$ ) (with 93% sensitivity and 63% specificity) or  $>2$  metastatic pretracheal lymph nodes (AUC=0.795,  $p<0.001$ ,  $J=0.563$ ) (with 60% sensitivity and 96.3% specificity).

When one or two metastatic lymph nodes are present in the pretracheal region, we can predict the absence of metastasis in the contralateral paratracheal region with a sensitivity of 96.3%. Furthermore, in cases with two or fewer

pretracheal metastases, the sensitivity is only 60% when evaluating only the pretracheal region. When considering unilateral CND with fewer than 3 metastases (including prelaryngeal and ipsilateral pretracheal lymph nodes), the sensitivity for contralateral paratracheal metastases increases to 93%. Our findings suggest that evaluating unilateral central region subcompartments separately can yield high sensitivity and specificity rates. Particularly, the high rates of ipsilateral paratracheal, pretracheal, and contralateral paratracheal metastases (85.7%, 54.8%, and 35.7%, respectively) support the notion that the lymph node metastasis pattern is from the ipsilateral paratracheal region to the contralateral paratracheal region via the pretracheal region.

Intraoperative assessment of the central region is crucial when deciding on the extent of CND in patients with lateral metastases. Even experienced surgeons have poor sensitivity and specificity in evaluating and detecting central region metastases through intraoperative inspection and palpation. Scherl et al.<sup>[27]</sup> reported a false negative rate of 26% in patients with central metastases classified as false negatives by the senior surgeon. They detected five or more lymph node metastases in 42% of the false-negative group and extranodal extension in 25%. In another study, the sensitivity, specificity, positive predictive value, and negative predictive value of the surgeon's detection of metastatic central lymph nodes intraoperatively in clinically node-negative patients were 35.7%, 72.5%, 0.5%, and 68.2%, respectively. This suggests that the surgeon's judgment is a limited guide for detecting lymph node metastasis.<sup>[28]</sup>

Intraoperative frozen examination can help determine whether there is lymph node metastasis. This examination especially gives us an idea of how to distinguish lymph nodes from parathyroid tissue.<sup>[29]</sup> Importantly, frozen examination of a unilateral CND can appropriately check the status of neck lymph node metastasis. Routine ipsilateral CND combined with a frozen section of the ipsilateral nodes may be an appealing alternative to prophylactic bilateral CND.<sup>[30,31]</sup>

The susceptibility of ipsilateral metastasis for developing central lymph node metastasis is high, with sensitivity reported as 81–92% and specificity as 99–100%.<sup>[31,32]</sup>

In patients with lateral metastases, frozen examination of the ipsilateral central dissection may be an appropriate evaluation in terms of the extent of the dissection.

In our study, using the ROC curve, although we indicated that the number of ipsilateral central metastases or pretracheal metastases affected predicting paratracheal metastasis, there was no independent risk factor found for reveal-

ing the contralateral paratracheal metastasis. Furthermore, in another study, for patients with ipsilateral lateral metastases, several parameters were mentioned as risk factors. Male gender (adjusted OR=2.46,  $p=0.002$ ), bilaterality (adjusted OR=2.58,  $p=0.004$ ), the number of ipsilateral central lymph node metastases (adjusted OR=1.15,  $p=0.002$ ), the number of lateral metastatic lymph nodes (adjusted OR=1.48,  $p<0.001$ ), and the presence of metastatic lymph nodes in 3 lateral neck compartments (adjusted OR=2.46,  $p=0.012$ ) were determined to be independent risk factors for paratracheal metastasis. Similarly, in another study, multifocality of the primary tumor (OR=5.120,  $p=0.010$ ) and the presence of metastases in all lateral compartments (Level II, III, IV) (OR=5.130,  $p=0.017$ ) were determined as independent risk factors for contralateral paratracheal lymph node metastasis.<sup>[14]</sup>

Recently, it has been discussed if pCND should be performed in patients with lateral metastases when there is no clinical metastasis in the central region. In four meta-analyses of the literature regarding this subject, it was concluded that pCND has no advantage in preventing locoregional recurrence and increases the rates of total surgical complications and permanent hypoparathyroidism. On the contrary, the researchers stated that the available evidence is limited. They also emphasized that more evidence from multicenter, prospective, randomized, controlled clinical trials is needed to further clarify the true role of pCND in PTC patients with cN1b.<sup>[33]</sup>

The first main limitation of this study is that it is retrospective. Additionally, the number of cases is limited, and the central neck dissection is not categorized as prophylactic or therapeutic in patients with lateral neck metastases. On the other hand, it is a study that might contribute to the literature, especially since the situation of the compartments in the central region is evaluated separately, and the number of studies on this subject is limited.

## Conclusion

All things considered, in patients with lateral metastases, the rates of ipsilateral paratracheal metastasis and contralateral paratracheal metastasis are 85% and 35.7%, respectively. Especially, the number of metastatic pretracheal lymph nodes can help predict the contralateral paratracheal lymph node metastasis. Unilateral CND can be performed, especially in the presence of two or fewer metastases in the ipsilateral central region.

## Disclosures

**Ethics Committee Approval:** This study adhered to the principles of the Helsinki Declaration and received approval from the local Ethics Committee (Decision No: 2950, Date: 25/07/2020).

**Peer-review:** Externally peer-reviewed.

**Conflict of Interest:** None declared.

**Authorship Contributions:** Concept – M.U., N.A., I.C.; Design – M.U., N.A., I.C.; Supervision – M.U., N.A., I.C.; Materials – M.K., O.Z.C., C.Y., I.C.; Data collection &/or processing – M.T.U., M.K., O.Z.C., C.Y., I.C.; Analysis and/or interpretation – N.A., M.T.U., I.C.; Literature search – M.U., N.A., I.C.; Writing – M.U., N.A., I.C.; Critical review – M.U., N.A., M.T.U.

## References

- Houten PV, Netea-Maier RT, Smit JW. Differentiated thyroid carcinoma: an update. *Best Pract Res Clin Endocrinol Metab* 2023;37:101687. [\[CrossRef\]](#)
- Haugen BR, Alexander EK, Bible KC, Doherty GM, Mandel SJ, Nikiforov YE, et al. 2015 American Thyroid Association Management guidelines for adult patients with thyroid nodules and differentiated thyroid cancer: the American Thyroid Association Guidelines Task Force on Thyroid Nodules and Differentiated Thyroid Cancer. *Thyroid* 2016;26:1–133. [\[CrossRef\]](#)
- Khokhar M, Milas M. Management of nodal disease in thyroid cancer. *Surg Clin N Am* 2019;99:611–32. [\[CrossRef\]](#)
- Aygun N, Kostek M, Isgor A, Uludag M. Role and extent of neck dissection for neck lymph node metastases in differentiated thyroid cancers. *Sisli Etfal Hastan Tip Bul* 2021;55:438–49. [\[CrossRef\]](#)
- Agrawal N, Evasovich MR, Kandil E, Noureldine SI, Felger EA, Tufano RP, et al. Indications and extent of central neck dissection for papillary thyroid cancer: an American Head and Neck Society Consensus Statement. *Head Neck* 2017;39:1269–79. [\[CrossRef\]](#)
- Yang Z, Heng Y, Zhao Q, Cao Z, Tao L, Qiu W, et al. A specific predicting model for screening skip metastasis from patients with negative central lymph nodes metastasis in papillary thyroid cancer. *Front Endocrinol (Lausanne)* 2021;12:743900. [\[CrossRef\]](#)
- Hu D, Lin H, Zeng X, Wang T, Deng J, Su X. Risk factors for and prediction model of skip metastasis to lateral lymph nodes in papillary thyroid carcinoma. *World J Surg* 2020;44:1498–505. [\[CrossRef\]](#)
- Park JH, Lee YS, Kim BW, Chang HS, Park CS. Skip lateral neck node metastases in papillary thyroid carcinoma. *World J Surg* 2012;36:743–7. [\[CrossRef\]](#)
- Perros P, Boelaert K, Colley S, Evans C, Evans RM, Gerrard Ba G, et al; British Thyroid Association. Guidelines for the management of thyroid cancer. *Clin Endocrinol (Oxf)* 2014;81 Suppl 1:1–122.
- Sancho JJ, Lennard TW, Paunovic I, Triponez F, Sitges-Serra A. Prophylactic central neck dissection in papillary thyroid cancer: a consensus report of the European Society of Endocrine Surgeons (ESES). *Langenbecks Arch Surg.* 2014;399:155–63. [\[CrossRef\]](#)
- Ito Y, Onoda N, Okamoto T. The revised clinical practice guidelines on the management of thyroid tumors by the Japan Associations of Endocrine Surgeons: core questions and recommendations for treatments of thyroid cancer. *Endocr J* 2020;67:669–717. [\[CrossRef\]](#)
- Carty SE, Cooper DS, Doherty GM, Duh QY, Kloos RT, Mandel SJ, et al; American Thyroid Association Surgery Working Group;

- American Association of Endocrine Surgeons; American Academy of Otolaryngology-Head and Neck Surgery; American Head and Neck Society. Consensus statement on the terminology and classification of central neck dissection for thyroid cancer. *Thyroid* 2009;19:1153–8. [CrossRef]
13. National Comprehensive Cancer Network (NCCN). NCCN Guidelines. Thyroid Carcinoma. Version 4.2023. Available at: <https://www.nccn.org/guidelines/guidelines-detail?category=1&id=1470>. Accessed Aug 16, 2023.
  14. Koo BS, Choi EC, Park YH, Kim EH, Lim YC. Occult contralateral central lymph node metastases in papillary thyroid carcinoma with unilateral lymph node metastasis in the lateral neck. *J Am Coll Surg* 2010;210:895–900. [CrossRef]
  15. Keum HS, Ji YB, Kim JM, Jeong JH, Choi WH, Ahn YH, et al. Optimal surgical extent of lateral and central neck dissection for papillary thyroid carcinoma located in one lobe with clinical lateral lymph node metastasis. *World J Surg Oncol* 2012;10:221. [CrossRef]
  16. Back K, Choe JH, Kim JS, Kim JH. Occult contralateral central neck metastasis in papillary thyroid carcinoma with preoperatively documented ipsilateral lateral neck metastasis. *Eur J Surg Oncol* 2021;47:1339–45. [CrossRef]
  17. Giordano D, Valcavi R, Thompson GB, Pedroni C, Renna L, Gradoni P, et al. Complications of central neck dissection in patients with papillary thyroid carcinoma: results of a study on 1087 patients and review of the literature. *Thyroid* 2012;22:911–7. [CrossRef]
  18. Rosati D, Bononi M, Ruscito P, Radici M, Cavaliere C, Minni A. Bilateral and ipsilateral central neck dissection in total thyroidectomy: a long term comparison of complications. *Indian J Otolaryngol Head Neck Surg* 2022;74 Suppl 3:6206–12. [CrossRef]
  19. Carmel-Neiderman NN, Duek I, Amsterdam D, Wengier A, Kuzmenko B, Ringel B, et al. Total thyroidectomy with therapeutic level II-IV neck dissection for papillary thyroid carcinoma: level VI recurrence patterns. *Eur Arch Otorhinolaryngol* 2020;277:3449–55. [CrossRef]
  20. Carmel-Neiderman NN, Mizrahi A, Yaniv D, Vainer I, Muhanna N, Abergel A, et al. Prophylactic central neck dissection has no advantage in patients with metastatic papillary thyroid cancer to the lateral neck. *J Surg Oncol* 2021;123:456–61. [CrossRef]
  21. Harries V, McGill M, Wang LY, Tuttle RM, Wong RJ, Shaha AR, et al. Is a prophylactic central compartment neck dissection required in papillary thyroid carcinoma patients with clinically involved lateral compartment lymph nodes? *Ann Surg Oncol* 2021;28:512–8.
  22. Stack BC Jr, Ferris RL, Goldenberg D, Haymart M, Shaha A, Sheth S, et al; American Thyroid Association Surgical Affairs Committee. American Thyroid Association consensus review and statement regarding the anatomy, terminology, and rationale for lateral neck dissection in differentiated thyroid cancer. *Thyroid* 2012;22:501–8. [CrossRef]
  23. Uludağ M, Tanal M, İşgör A. Standards and definitions in neck dissections of differentiated thyroid cancer. *Sisli Etfal Hastan Tip Bul.* 2018;52:149–63. [CrossRef]
  24. Iscan Y, Sormaz IC, Tunca F, Giles Senyurek Y. Multicentricity is more common in thyroid papillary microcancer with a preoperative diagnosis compared to incidental microcancer. *Eur Thyroid J* 2019;8:256–61. [CrossRef]
  25. Graceffa G, Orlando G, Cacoruslo G, Mazzola S, Vitale I, Proclama MP, et al. Predictors of central compartment involvement in patients with positive lateral cervical lymph nodes according to clinical and/or ultrasound evaluation. *J Clin Med* 2021;10:3407.
  26. Khaff A, Ben-Yosef R, Abergel A, Kesler A, Landsberg R, Fliss DM. Elective paratracheal neck dissection for lateral metastases from papillary carcinoma of the thyroid: is it indicated? *Head Neck* 2008;30:306–10. [CrossRef]
  27. Scherl S, Mehra S, Clain J, Dos Reis LL, Persky M, Turk A, et al. The effect of surgeon experience on the detection of metastatic lymph nodes in the central compartment and the pathologic features of clinically unapparent metastatic lymph nodes: what are we missing when we don't perform a prophylactic dissection of central compartment lymph nodes in papillary thyroid cancer? *Thyroid* 2014;24:1282–8. [CrossRef]
  28. Ji YB, Lee DW, Song CM, Kim KR, Park CW, Tae K. Accuracy of intraoperative determination of central node metastasis by the surgeon in papillary thyroid carcinoma. *Otolaryngol Head Neck Surg* 2014;150:542–7. [CrossRef]
  29. Patel KN, Yip L, Lubitz CC, Grubbs EG, Miller BB, Shen W, et al. The American Association of Endocrine Surgeons guidelines for the definitive surgical management of thyroid disease in adults. *Ann Surg* 2020;271:e21–93. [CrossRef]
  30. Raffaelli M, De Crea C, Sessa L, Fadda G, Bellantone C, Lombardi CP, et al. Ipsilateral central neck dissection plus frozen section examination versus prophylactic bilateral central neck dissection in cN0 papillary thyroid carcinoma. *Ann Surg Oncol* 2015;22:2302–8. [CrossRef]
  31. Lim YS, Choi SW, Lee YS, Lee JC, Lee BJ, Wang SG, et al. Frozen biopsy of central compartment in papillary thyroid cancer: quantitative nodal analysis. *Head Neck* 2013;35:1319–22. [CrossRef]
  32. Raffaelli M, De Crea C, Sessa L, Giustacchini P, Bellantone R, Lombardi CP. Can intraoperative frozen section influence the extension of central neck dissection in cN0 papillary thyroid carcinoma? *Langenbecks Arch Surg* 2013;398:383–8. [CrossRef]
  33. Yan XQ, Zhang ZZ, Yu WJ, Ma ZS, Chen ML, Xie BJ. Prophylactic central neck dissection for cN1b papillary thyroid carcinoma: a systematic review and meta-analysis. *Front Oncol* 2022;11:803986.