

Unusual lymphocele following radical cystectomy with orthotopic neobladder

Senthil Kallappan*, Ramalingam Manickam, Sivasankaran Nachimuthu, Thilak Ganesapandi

Department of Urology, Urology Clinic, Gowtham Annexe, Coimbatore, Tamil Nadu, India

*E-mail: senthilsatya@hotmail.com

ABSTRACT

A 65-year-old male patient, a known case of carcinoma bladder, underwent radical cystectomy with ileal neobladder in 2016. Eleven lymph nodes were identified in the specimen. Histopathology revealed reactive lymphadenitis with sinus histiocytosis. The patient presented with a swelling in the right thigh, associated with dull pain, about 6 months after the procedure. Ultrasound of the right thigh and computed tomography of the region showed an isolated, large, loculated, cystic collection measuring 15 cm × 6 cm with internal septation in the pectineus and adductor longus muscles. Complete aspiration of fluid from the right thigh was done with ultrasound guidance and sent for analysis. The fluid appeared to be lymph, and the lesion turned out to be a lymphocele. There was no recurrence or infection following the aspiration till last follow-up visit. We report this rare lymphocele presentation (in the thigh without any extension from pelvis or groin) after 6 months, following radical cystectomy with neobladder, which was treated by one-time aspiration.

CASE REPORT

A 65-year-old male patient, a known case of carcinoma bladder, underwent radical cystectomy with ileal neobladder in 2016. Heparin was used for 72 h following surgery for deep vein thrombosis prophylaxis till the patient was ambulant. Eleven lymph nodes were identified in the specimen. Histopathology revealed reactive lymphadenitis with sinus histiocytosis. The patient presented with a swelling in the right thigh, associated with dull pain, about 6 months after the procedure.

The general and systemic examination did not reveal any abnormality. Examination of the right thigh revealed a diffuse nontender swelling in the medial aspect of the thigh. Complete blood count, electrolytes, and creatinine were within normal limits. Ultrasound of the right thigh revealed a large cystic lesion measuring 15 cm × 6 cm with internal echoes in

the medial aspect of the right thigh, below the femoral vein, extending just below the origin of superficial femoral vessels to mid thigh [Figure 1a]. Computed tomography showed a large loculated cystic collection measuring 15 cm × 6 cm with internal septation in the pectineus and adductor longus muscles [Figure 1b]. There were no significant pelvic lymph nodes. Complete aspiration of fluid from the right thigh was done with ultrasound guidance using multiple punctures and sent for analysis. The fluid appeared to be lymph and the lesion turned out to be a lymphocele. There was no recurrence or infection following the aspiration at latest follow-up after 6 months.

DISCUSSION

A lymphocele is defined as a lymphatic fluid collection without the presence of a distinct epithelial lining and occurs either due to surgical transection causing severe injury to the lymphatic vessels or inadequate ligation of lymphatic

Access this article online	
Quick Response Code:	Website: www.indianjurol.com
	DOI: 10.4103/iju.IJU_284_18

This is an open access journal, and articles are distributed under the terms of the Creative Commons Attribution-NonCommercial-ShareAlike 4.0 License, which allows others to remix, tweak, and build upon the work non-commercially, as long as appropriate credit is given and the new creations are licensed under the identical terms.

For reprints contact: reprints@medknow.com

Received: 03.09.2018, **Accepted:** 09.02.2019

Financial support and sponsorship: Nil.

Conflicts of interest: There are no conflicts of interest.

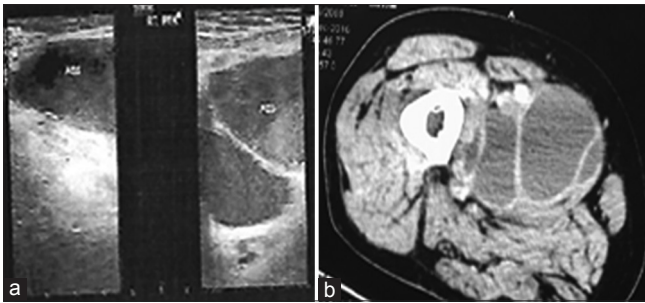


Figure 1: (a) Ultrasound images of the right thigh revealed a large cystic space of 15 cm × 6 cm with internal echoes in medial aspect of the right thigh below the femoral vein extending just below the origin of superficial femoral vessel to mid thigh and (b) computed tomography images of the right thigh revealed a large loculated cystic collection of size 15 cm × 6 cm with internal septation

vessels. It occurs most commonly as a postoperative complication related to pelvic lymphadenectomy.^[1] Presentation of lymphocele is highly variable. Patients may be asymptomatic or can present with swelling, pain, fever, genital or lower extremity edema, or urinary and gastrointestinal symptoms following mass effect on adjacent organs. Many factors can increase the chance of occurrence of lymphocele following pelvic lymph node dissection (PLND). Surgical technique can affect the chance of lymphocele formation; for example, through the excessive use of diathermy.^[2] Other surgical factors are large iliac lymph node metastasis or following extended PLND or disruption of the lymphatics overlying the external iliac artery. Lymphocele risk increases with history of prior radiation therapy and subcutaneous heparin.^[3] Sogani *et al.*,^[3] in 1981, reported a 4.7% lymphocele rate in a group of 187 patients who underwent PLND for either prostate or bladder cancer. Lymphoceles can occur sometimes as soon as few weeks following a surgery; however, late occurrences up to 2 years after surgery have been reported.^[4] In lymphocele, symptoms occur due to the compression of adjacent anatomic structures, such as compression of ureter resulting in hydronephrosis, venous compression resulting in lower extremity edema, rectosigmoid compression resulting in constipation, compression of pelvic nerves resulting in pain, and bladder compression resulting in urinary frequency. Common location of lymphocele is in pelvis or groin. Pelvic lymphoceles can be large and can extend to retroperitoneum. In our case, it was isolated in the right mid thigh, which is very rare and not reported in literature. Ultrasound is the investigation of choice for the diagnosis of lymphocele. Lymphoceles appear as anechoic cystic structures.^[5] In computed tomography, the lymphoceles will appear like a thin-walled, hypodense lesion with a negative Hounsfield unit (as low as -18 HU) values. There are various options in the management of lymphocele. Asymptomatic lymphocele does not require treatment and

disappears spontaneously. Persistent lymphocele can lead to various late complications.^[6] Studies reported that for asymptomatic small lymphocele, the absorption occurs over time with bed rest and antibiotics.^[7] Other option is simple aspiration, but there is a chance of fluid reaccumulation and risk of infection.^[3] Sclerotherapy using various chemical agents such as povidone-iodine, diatrizoate-meglumine, and doxycycline have also been described. The surgical option is marsupialization into the peritoneal cavity if the lymphocele is in the pelvis with or without extension into groin. Surgery can be performed either by an open or laparoscopic approach. In our case, lymphocele was isolated to the thigh, so marsupialization does not apply to our clinical scenario, hence, simple aspiration under ultrasound guidance was performed. To our knowledge, this is the first report on an unusual lymphocele presentation (in the thigh without any extension from pelvis or groin) after 6 months, following radical cystectomy with neobladder, which was treated by a single aspiration.

Declaration of patient consent

The authors certify that they have obtained all appropriate patient consent forms. In the form the patient(s) has/have given his/her/their consent for his/her/their images and other clinical information to be reported in the journal. The patients understand that their names and initials will not be published and due efforts will be made to conceal their identity, but anonymity cannot be guaranteed.

REFERENCES

1. Patel A. Complications of Urologic Surgery – Prevention and Management. 3rd ed. Philadelphia: Saunders; 2001. p. 370-85.
2. Abou-Elela A, Reyad I, Torkey M, Meshref A, Morsi A. Laparoscopic marsupialization of postrenal transplantation lymphoceles. *J Endourol* 2006;20:904-9.
3. Sogani PC, Watson RC, Whitmore WF Jr. Lymphocele after pelvic lymphadenectomy for urologic cancer. *Urology* 1981;17:39-43.
4. Greenberg BM, Perloff LJ, Grossman RA, Naji A, Barker CF. Treatment of lymphocele in renal allograft recipients. *Arch Surg* 1985;120:501-4.
5. vanSonnenberg E, Wittich GR, Casola G, Wing VW, Halasz NA, Lee AS, *et al.* Lymphoceles: Imaging characteristics and percutaneous management. *Radiology* 1986;161:593-6.
6. Braun WE, Banowsky LH, Straffon RA, Nakamoto S, Kiser WS, Popowniak KL, *et al.* Lymphocytes associated with renal transplantation. Report of 15 cases and review of the literature. *Am J Med* 1974;57:714-29.
7. Spring DB, Schroeder D, Babu S, Agee R, Gooding GA. Ultrasonic evaluation of lymphocele formation after staging lymphadenectomy for prostatic carcinoma. *Radiology* 1981;141:479-83.

How to cite this article: Kallappan S, Manickam R, Nachimuthu S, Ganesapandi T. Unusual lymphocele following radical cystectomy with orthotopic neobladder. *Indian J Urol* 2019;35:168-9.