

➤ **Case Report** ◀

Successful Hybrid Treatment of Stent-Graft Migration Caused by Type B Aortic Dissection after Endovascular Aortic Aneurysm Repair: A Case Report

Tsunehiro Shintani, MD, PhD, Kouji Atsuta, MD, and Takaaki Saito, MD

Herein, we report a rare case of type B aortic dissection that occurred after endovascular aortic aneurysm repair (EVAR). A 66-year-old man underwent successful EVAR for an abdominal aortic aneurysm (AAA). Computed tomography (CT) 2 years after EVAR showed a type B aortic dissection with stent-graft migration and AAA expansion. Juxtarenal aortic expansion precluded simple stent-graft placement. He underwent hepato-spleno-renal bypass followed by stent-graft placement just below the superior mesenteric artery. Postoperative CT showed no endoleaks. This case reconfirms the importance of regular follow-up after EVAR and illustrates the usefulness of a hybrid approach.

Keywords: type B aortic dissection, endovascular aortic aneurysm repair

Introduction

Endovascular aortic aneurysm repair (EVAR) for abdominal aortic aneurysm (AAA) is an established treatment for patients with favorable anatomy who are unfit for open surgery.¹⁾ However, the main concern regarding EVAR is its long-term durability.²⁾ The potential adverse events of EVAR, such as stent-graft migration and endoleak, require lifelong surveillance. Type B aortic dissection after EVAR is rare but may cause catastrophic events, including rupture, malperfusion, and expansion of the aneurysm.³⁾

Herein, we report a case of stent-graft migration caused by a type B aortic dissection 2 years after EVAR in a patient with favorable anatomy. He was treated using a hybrid approach involving hepato-spleno-renal bypass followed by stent-graft placement.

Department of Vascular Surgery, Shizuoka Red Cross Hospital, Shizuoka, Japan

Received: May 11, 2017; Accepted: June 30, 2017
Corresponding author: Tsunehiro Shintani, MD, PhD. Department of Vascular Surgery, Shizuoka Red Cross Hospital, 8-2 Ottemachi, Aoi-ku, Shizuoka, Shizuoka 420-0853, Japan
Tel: +81-54-254-4311, Fax: +81-54-252-8816
E-mail: tshintani@yb4.so-net.ne.jp

Case Report

A 66-year-old man presented for evaluation of a 60-mm AAA that had been incidentally detected during the investigation of left renal cell carcinoma (RCC) with pleural dissemination. The advanced cancer precluded open surgery for the AAA. The infrarenal aortic neck was 30 mm in length, 24 mm in diameter proximally, and 27 mm in diameter distally, without angulation. Both common iliac arteries were 14 mm in diameter with adequate landing zones. His aortic anatomy was favorable for EVAR. An Endurant II Stent (32-16-166 mm, 16-16-124 mm, 16-16-82 mm; Medtronic Inc., Santa Rosa, CA, USA) was implanted using a standard procedure. The patient's postoperative course was uneventful. Contrast-enhanced computed tomography (CT) before discharge on day 6 showed complete exclusion of the AAA without endoleaks and a normal thoracic aorta (Figs. 1A and 1C; Figs. 2A, 2C–2F). After EVAR, the patient began chemotherapy for the RCC. Regular follow-up CT every 6 months showed no AAA abnormalities, and he had no symptoms to suggest aortic dissection, such as back pain.

At the regular 2-year follow-up, contrast-enhanced CT showed a type B aortic dissection extending from the origin of the left subclavian artery to the infrarenal aortic neck, expansion of the entire descending aorta, migration of the stent-graft, a type I endoleak, and AAA expansion from 60 to 65 mm in diameter (Figs. 1B and 1D; Figs. 2B, 2G–2J). The CT also showed expansion of both the common iliac arteries from 14 to 20 mm in diameter. The expansion of the right common iliac artery caused a type Ib endoleak. Because the RCC was in partial remission and his general condition was good, including his renal function (estimated glomerular filtration rate, 52.6 ml/min/1.73 m²), he consented to undergo treatment for the AAA expansion.

Expansion of the juxtarenal aorta precluded simple placement of the stent-graft below the renal artery. Both the renal arteries were 4 mm in diameter, which was too small for endovascular reconstruction; therefore, we chose a hybrid procedure. Under a midline laparotomy,



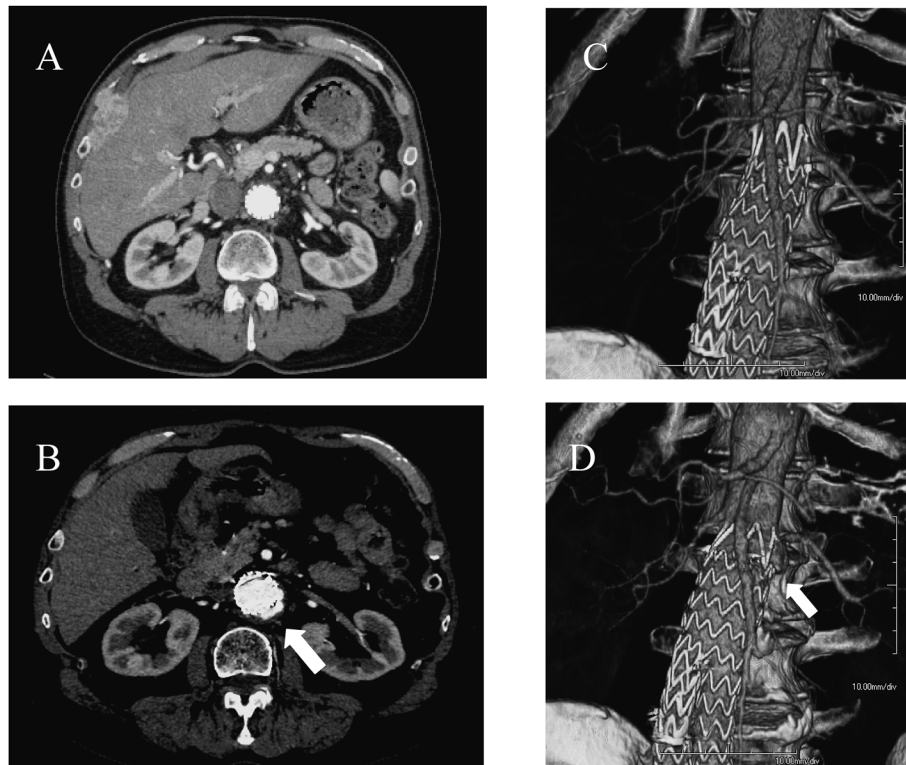


Fig. 1 Contrast-enhanced computed tomography after endovascular aortic aneurysm repair (EVAR). (A) Axial plane showing the aorta 15mm below the left renal artery 6 days after EVAR. (B) Axial plane showing the aorta 15mm below the left renal artery 2 years after EVAR. White arrow shows the type I endoleak. The aorta expanded from 26 to 40 mm. (C) Three-dimensional volume-rendering reconstruction showing the juxtarenal aorta 6 days after EVAR. (D) Three-dimensional volume-rendering reconstruction showing the juxtarenal aorta 2 years after EVAR. White arrow shows the migration of the stent-graft.

we performed a hepato-spleno-renal bypass. Because of pleural dissemination, we did not perform left nephrectomy for the RCC at this time. A hepato-renal bypass was performed from the common hepatic artery to the right renal artery using a reversed saphenous vein graft. A spleno-renal bypass was performed after mobilization of the splenic artery followed by end-to-side anastomosis to the left renal artery. Next, we placed a Gore Excluder aortic cuff (W.L. Gore & Associates Inc., Flagstaff, AZ, USA) below the origin of the superior mesenteric artery (SMA). We also extended the iliac limb of the Gore Excluder to the right external iliac artery, with coil embolization of the right hypogastric artery. Completion angiography showed no type I endoleaks.

The postoperative course was uneventful. Postoperative CT showed a patent bypass and complete exclusion of the AAA without endoleaks (Fig. 3). Chemotherapy was restarted for the RCC. Six months after the reoperation, CT showed shrinkage of the AAA from 65 to 50 mm in diameter and no further expansion of the thoracic aorta. Additionally, renal function was almost normal (estimated

glomerular filtration rate, 40.8 ml/min/1.73 m²).

Discussion

Although retrograde aortic dissection after thoracic EVAR is a well-known complication and has been reported in up to 2.4% of cases,⁴⁾ type B aortic dissection after EVAR has only been reported sporadically.³⁾ According to a report from a single institution, the incidence of this complication is postulated to be approximately 0.5%.⁵⁾

Although the exact etiology of this complication has not been determined in most cases, iatrogenic dissection or spontaneous type B dissection are suspected etiologies. When the dissection occurs in the early postoperative period, iatrogenic dissection should be considered. Factors causing iatrogenic dissection are classified as procedure related and device related. Balloon dilation, wire manipulation, and oversizing of the stent-graft have been implicated as procedure-related factors. A hostile aortic neck, including calcification of the aorta or an irregularly shaped or highly angulated infrarenal aortic neck, is close-

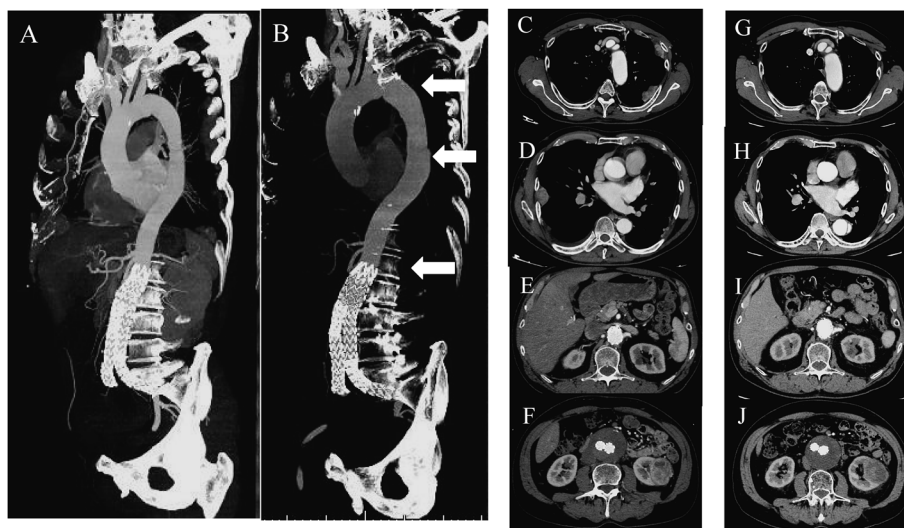


Fig. 2 Contrast-enhanced computed tomography after endovascular aortic aneurysm repair (EVAR). Multiplanar reconstruction showing the aorta (A) 6 days after EVAR and (B) 2 years after EVAR. (C–F) Axial plane showing the aorta 6 days after EVAR and (G–J) 2 years after EVAR at different levels of the aorta. The upper white arrow in B shows the aorta at the left subclavian artery level. (C, G) The diameter of the aorta expanded from 27 to 33mm. The middle white arrow in B shows the dissected aorta at the pulmonary artery level. (D, H) The diameter of the aorta expanded from 27 to 36mm. The lower white arrow in B shows the aorta at the left renal artery level. (E, I) The diameter of the aorta expanded from 25 to 30 mm. (F, J) The diameter of the aneurysm expanded from 60 to 65 mm.

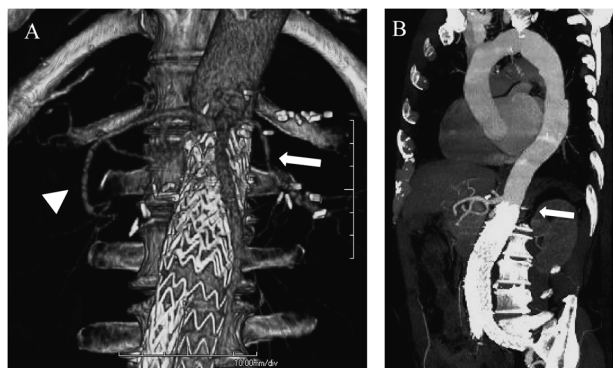


Fig. 3 Postoperative contrast-enhanced computed tomography. (A) Three-dimensional volume-rendering reconstruction showing the patent bypass (white arrowhead: hepato-renal bypass; white arrow: spleno-renal bypass). (B) Multiplanar reconstruction showing the successful placement of the stent-graft below the superior mesenteric artery (white arrow).

ly associated with these procedure-related factors.^{3,5)} In the present case, the infrarenal aortic neck had a favorable anatomy, and the stent-graft was implanted without difficulty. Therefore, a procedure-related cause was unlikely.

Device-related factors should also be considered because proximal bare stents with anchoring barbs were used in 9 of the 12 previously reported cases.³⁾ Proximal anchoring barbs may cause intimal injury, which leads to

aortic dissection. Because we used a device with a proximal anchoring barb, we cannot eliminate the possibility that this device-related factor contributed to the patient's dissection. However, the delay between the initial operation and the presentation was approximately 2 years, and the enhanced CT scan performed before discharge revealed no thoracic aorta abnormality. Thus, the possibility of an iatrogenic cause is low, and spontaneous type B dissection was the most probable cause.

The treatment for type B aortic dissection after EVAR depends on its presentation. Most cases of type B dissection are uncomplicated and can be managed by medical therapy⁶⁾; this was true for the present case. Five previously reported cases were managed by medical therapy alone.^{3,5)} However, some cases of type B dissection after EVAR lead to complicated presentations, such as malperfusion, aneurysm expansion, and aneurysm rupture, requiring surgical or endovascular interventions. In our case, a type B aortic dissection caused expansion of the juxtarenal aorta, which led to the migration of the stent-graft, a type I endoleak, and AAA expansion. The combination of these abnormalities was difficult to treat by medical therapy.

Aortic dissection in the present case led to the expansion of the juxtarenal aorta; this precluded simple placement of the stent-graft below the renal artery because of the absence of a suitable length of the aortic neck. Although a fenestrated endograft or snorkel/chimney tech-

nique using a covered stent may be an alternative option, these devices were not yet approved in Japan at the time of this writing.^{7,8)} Additionally, the patient's small renal arteries were unfit for the covered stent that is used for such techniques. Another potential option was surgical removal of the stent-graft and reconstruction of both renal arteries. However, stent-graft removal requires suprarenal aortic cross-clamping, resulting in renal dysfunction.⁹⁾ Our patient needed to restart chemotherapy for his RCC after the surgery. Therefore, to protect postoperative renal function, we chose to perform a hepato-spleno-renal bypass followed by stent-graft placement below the origin of the SMA. Hepato-renal, spleno-renal, and ileo-renal bypasses have been reported to facilitate EVAR for the treatment of juxtarenal aortic aneurysms.⁷⁾ Because both the renal arteries were small, we considered that an ileo-renal bypass using prosthetic grafts was inappropriate in this case. According to the literature, a hepato-spleno-renal bypass has been used to salvage unintentionally occluded renal arteries after EVAR.^{9,10)} We modified this procedure to facilitate EVAR for the juxtarenal aortic aneurysm. We used the aorta below the origin of the SMA as the proximal landing zone of the stent-graft. Because this aorta was the dissected aorta, we cannot eliminate the future possibility of dissection or expansion of the thoracic aorta around the proximal landing zone.

Conclusion

In summary, we have reported a rare case of stent-graft migration caused by a type B aortic dissection after EVAR in a patient with a favorable anatomy, illustrating the importance of regular follow-up after EVAR. We treated this complication with a hybrid approach involving hepato-spleno-renal bypass. This approach can avoid the need for suprarenal aortic cross-clamping and reduce the possibility of renal dysfunction. The possibility of postoperative complications associated with the future expansion of the dissected thoracic aorta necessitates careful postoperative surveillance of the aneurysm.

Disclosure Statement

All authors declare no conflict of interest.

Author Contributions

Study conception: TS

Data collection: TS

Writing: TS

Critical review and revision: all authors

Final approval of the article: all authors

Accountability for all aspects of the work: all authors

References

- 1) Moll FL, Powell JT, Fraedrich G, et al.; European Society for Vascular Surgery. Management of abdominal aortic aneurysms clinical practice guidelines of the European Society for Vascular Surgery. *Eur J Vasc Endovasc Surg* 2011; **41** Suppl 1: S1-58.
- 2) Paravastu SCV, Jayarajasingam R, Cottam R, et al. Endovascular repair of abdominal aortic aneurysm. *Cochrane Database Syst Rev* 2014; CD004178.
- 3) Sirignano P, Pranteda C, Capoccia L, et al. Retrograde type B aortic dissection as a complication of standard endovascular aortic repair. *Ann Vasc Surg* 2015; **29**: 127.e5-9.
- 4) Kpodonu J, Preventza O, Ramaiah VG, et al. Retrograde type A dissection after endovascular stenting of the descending thoracic aorta. Is the risk real? *Eur J Cardiothorac Surg* 2008; **33**: 1014-8.
- 5) Khanbhai M, Ghosh J, Ashleigh R, et al. Type B aortic dissection after standard endovascular repair of abdominal aortic aneurysm. *BMJ Case Rep* 2013; **2013**: bcr2012007209. DOI: 10.1136/bcr-2012-007209
- 6) Durham CA, Cambria RP, Wang LJ, et al. The natural history of medically managed acute type B aortic dissection. *J Vasc Surg* 2015; **61**: 1192-9.
- 7) Chaudhry T, Hobbs SD, Pinkney T, et al. Spleno-renal bypass facilitating endovascular stenting of a juxta-renal aortic aneurysm in a high risk patient. *Eur J Vasc Endovasc Surg* 2008; **35**: 452-4.
- 8) Donas KP, Lee JT, Lachat M, et al.; PERICLES investigators. Collected world experience about the performance of the snorkel/chimney endovascular technique in the treatment of complex aortic pathologies: the PERICLES registry. *Ann Surg* 2015; **262**: 546-53; discussion, 552-3.
- 9) Adu J, Cheshire NJ, Riga CV, et al. Strategies to tackle unrecognized bilateral renal artery occlusion after endovascular aneurysm repair. *Ann Vasc Surg* 2012; **26**: 1127.e1-7.
- 10) Hamish M, Geroulakos G, Hughes DA, et al. Delayed hepato-spleno-renal bypass for renal salvage following malposition of an infrarenal aortic stent-grafts. *J Endovasc Ther* 2010; **17**: 326-31.