

Case report: Dobutamine stress intracoronary physiology and imaging to examine the functional and dynamic properties of an apparent malignant intra-arterial right coronary artery

B. vanGorsel^{1*}, M. Voskuil ², A.J.J. Ijsselmuiden¹, and M. Meuwissen¹

¹Department of Cardiology, Amphia Hospital, Room NWO-003, Molengracht 21, 4818 CK, Breda, The Netherlands and ; and ²Department of cardiology, Universitair Medisch Centrum Utrecht, Heidelberglaan 100, 3584 CX Utrecht, The Netherlands

Received 16 March 2021; first decision 3 May 2021; accepted 5 July 2021; online publish-ahead-of-print 28 July 2021

Background

We present a case concerning a 64-year-old female with complaints of palpitations, chest pain, and an anomalous right coronary artery (RCA) from the opposite sinus (R-ACAOS) with a suspected malignant trajectory on computed tomography. She was referred to our clinic for a second opinion to re-assess the suggested treatment of coronary surgery.

Case summary

A coronary angiogram was performed demonstrating a RCA with a tapered ostium typical for an inter-arterial course. Dobutamine and adenosine stress test during simultaneous intracoronary flow, pressure, and ultrasound assessment, was performed to determine the functional significance. After 120 mcg adenosine, intracoronary baseline flow velocity increased from 14 cm/s to a peak flow velocity of 37 cm/s, demonstrating a sufficient coronary flow velocity reserve (CFVR) of 2.6. No intracoronary pressure drop during maximal hyperaemia was found. After maximum dobutamine stress, CFVR was measured 2.5. Fractional flow reserve measured 0.99. Cross-sectional area measurement through intravascular ultrasound demonstrated a diameter reduction from 14.6 mm² to 8.5 mm². Therefore, we concluded this aberrant trajectory was not of any functional relevance and should be considered non-malignant.

Discussion

There are several anatomic coronary anomalies which may contribute to coronary compression during exercise and are therefore correlated with sudden cardiac death. Right coronary artery from the opposite sinus is correlated with a low mortality rate of 0.2% in comparison to left-ACAOS at 6.3% over 20 years in participants of competitive sport. Therefore, strong evidence of ischaemia must be present before opting for surgery. Our pragmatic approach provided in our opinion enough evidence for a conservative treatment strategy.

Keywords

Case report • Intravascular ultrasound (IVUS) • Dobutamine stress • Anomalous right coronary artery from the opposite sinus (R-ACAOS) • Fractional flow reserve (FFR) • Coronary flow reserve • Sudden cardiac death (SCD)

* Corresponding author. Tel: 0031 76 595 4105, Email: [bvvangorsel@amphia.nl](mailto:bvangorsel@amphia.nl)

Handling Editor: Aref Bin Abdulhak

Peer-reviewers: Ivan Ilic; Antonios Karanasos

Compliance Editor: Reshma Amin

Supplementary Material Editor: Katharine Kott

© The Author(s) 2021. Published by Oxford University Press on behalf of the European Society of Cardiology.

This is an Open Access article distributed under the terms of the Creative Commons Attribution-NonCommercial License (<https://creativecommons.org/licenses/by-nc/4.0/>), which permits non-commercial re-use, distribution, and reproduction in any medium, provided the original work is properly cited. For commercial re-use, please contact journals.permissions@oup.com

Learning points

- (1) The combination of dobutamine stress testing in combination with intravascular ultrasound and fractional flow reserve/coronary flow reserve is a practical way to prove or disprove a malignant trajectory of a coronary anomaly.
- (2) Careful evaluation of haemodynamic significance in coronary artery anomalies is essential for setting out a treatment strategy.

Introduction

Currently, there is no gold standard for the assessment of the hemodynamic significance of an anomalous coronary artery.¹ In this case report, we describe the use of stenosis-specific intracoronary hemodynamic parameters; coronary flow velocity reserve (CFVR), fractional flow reserve (FFR), and intravascular imaging, to unravel the potential pathophysiological mechanism of an apparent malignant intra-arterial right coronary artery (RCA).

Timeline

Furthermore, there were no signs of obstructive atherosclerotic coronary artery disease. Coronary artery bypass grafting was advised in a multidisciplinary team meeting with cardiothoracic surgeons in the referring hospital. She was referred to our heart team for a second opinion at the patient's request. A dobutamine and adenosine stress test, during simultaneously intracoronary flow, pressure, and ultrasound assessment, was proposed to determine its functional significance.

Cardiac catheterization was performed following standard procedure through the radial approach. Coronary angiogram showed a slit like and tapered proximal course. After a bolus of nitroglycerine (200 mcg), intracoronary pressure and flow velocity were assessed during baseline and maximum hyperaemia induced by a bolus of

Date	Location	Intervention/examination
January 2019	Regional hospital	General practitioner refers patient to cardiologist on outpatient basis with symptoms of palpitations and chest pain. Echocardiography, computed tomography, and coronary angiography are performed demonstrating an anomalous right coronary artery from the opposite sinus.
March 2019	Regional hospital	Heart-team advice for coronary surgery.
July 2019	Regional hospital	Referred to our clinic for a second opinion
July 2019	Our clinic	Second opinion heart-team meeting. Advice for dobutamine stress examination in combination with fractional flow reserve, coronary flow velocity reserve and intravascular ultrasound.
August 2019	Our clinic	Clinical examination by interventional cardiologist
September 2019	Our clinic	Invasive coronary angiography with flow measurements.

Case presentation

A 64-year-old female was referred to our clinic for a second opinion to re-assess the suggested treatment of an anomalous RCA from the opposite sinus (R-ACAOS). Her medical history included asthma, hypertension, hypercholesterolaemia, and nicotine use. Relevant medication included amlodipine for hypertension treatment. She consulted her local cardiologist on an outpatient basis with complaints of palpitations and chest pain for which she was effectively treated with metoprolol. Clinical examination, in particular cardiovascular examination, was normal. Holter monitoring demonstrated 6% premature ventricular contractions. Echocardiography demonstrated a mildly dilated left ventricle with a good left ventricular ejection fraction, dilated atria without significant valvular dysfunctions. Computed tomography (CT) focused on the coronary arteries demonstrated a possible malignant path of the RCA between the aorta and the pulmonary trunk (*Figure 1A*).

Coronary angiography demonstrated an aberrant RCA with a tapered ostium typical for an inter-arterial course (*Figure 1B*).

120 mcg adenosine intracoronary (iC). Baseline flow velocity increased from 14 cm/s to a maximum peak flow velocity of 37 cm/s. Moreover, normal flow waveforms were preserved during both diastole and systole. A sufficient coronary flow velocity reserve (CFVR) of 2.6 was observed, which was above the cut-off value of 2.0 for myocardial ischemia.² There was no intracoronary pressure drop during maximal hyperaemia. *Figure 2* demonstrates a coronary angiography of the RCA from a left anterior oblique view. The arrow indicates the tip of a 'flipped' Combwire (ComboWire XT, Volcano/Philips Corporation, San Diego, CA, USA) stabilizing itself against the RCA intima to obtain stable retrograde Doppler flow velocity signal during dobutamine stress tests.

Thereafter, a dobutamine-atropine stress protocol was followed starting dobutamine 10 µg/kg/min continuous intravenous infusion of 3 min intervals before increasing the dose by 10 µg/kg/min. After a stepwise dosage increase up to 40 µg/kg/min 0.5 mg atropine was administered. Normal diastolic and systolic flow patterns were observed. CFVR after maximum dobutamine stress measured 2.5. *Figure 3* demonstrates the flow measurements. The derived

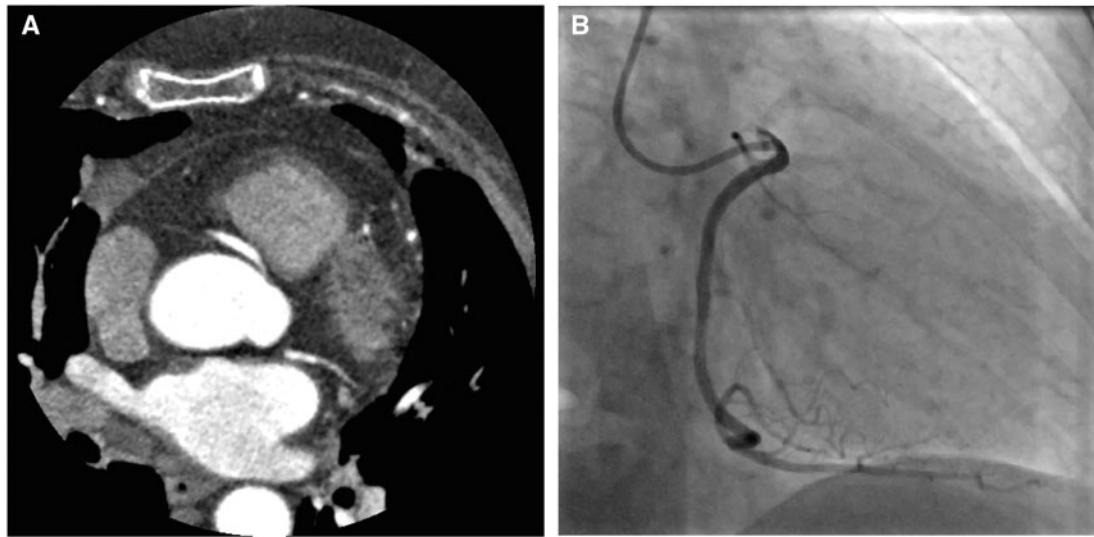


Figure 1 (A) Computed tomography (CT) the path of the right coronary artery between the pulmonary trunk and the aorta. (B) The slit-like same anomaly from the right anterior oblique (RAO) view.

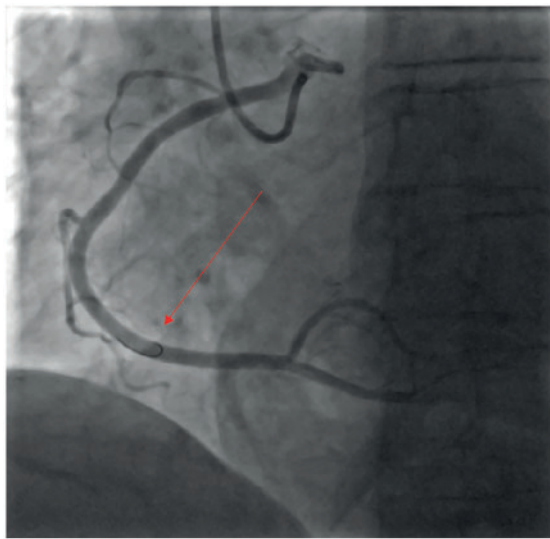


Figure 2 This figure demonstrates coronary angiography of the right coronary artery from a left anterior oblique view. Arrow indicates a Combwire which was 'flipped' to obtain a stable retrograde doppler flow velocity signal during dobutamine stress test.

fractional flow reserve (FFR) and CFVR were within their normal values used for discriminating for myocardial ischaemia; ie FFR was 0.99 (normal >0.80) and CFVR was 2.5 (normal >2.0). Cross-sectional area (CSA) measurement through intravascular ultrasound (IVUS) (Eagle eye, Volcano/Philips Corporation, San Diego, CA, USA) on the suspected malignant area showed a CSA of 14.6 mm^2 (Figure 4A). Cross-sectional area decreased to 8.5 mm^2 during maximum

dobutamine stress (Figure 4B). During the test, the patient experienced no symptoms of angina. Fractional flow reserve, CFVR, and CSA remained within normal ranges, even after chemically induced myocardial stress using dobutamine. Therefore, we concluded this aberrant trajectory of the RCA was not of any functional relevance and should be considered as non-malignant. Cardiac surgery was waived and our patient was without complaints or adverse events after 1 year of follow-up.

Discussion

Single coronary artery anomaly is a rare condition with an estimated prevalence of less than 0.2% (left sided 0.03% and right sided 0.23%)³ in the general population.^{4,5} Usually, patients remain asymptomatic and its discovery will be incidental. However, some patients present with chest pain, syncope, or arrhythmic complaints like our patient.

It's hypothesized that compression of a coronary artery in between surrounding bigger arteries correlates with sudden cardiac death (SCD), mainly during strenuous sports. Other pathophysiological mechanisms may include compression of a slit-like orifice due to aortic distension during exercise, the coexistence of an ostial ridge, acute angulation of the aberrant coronary causing a kink during exercise, spasm due to mechanical stress, hypoplasia leading to lumen narrowing, or a combination of all.⁶ The calculated absolute risk of sudden cardiac death (SCD) in this adult, the non-athletic population is still low. A mortality rate of 6.3% over a period of 20 years was reported in patients with left-sided coronary anomalies which participated in competitive sport. However, a mortality rate of 0.2% was found in another case series of R-ACAOS.⁷ Left-ACAOS are reported to have a 20 times higher risk of SCD.⁶ Therefore, different treatment strategies are generally being followed for left-sided

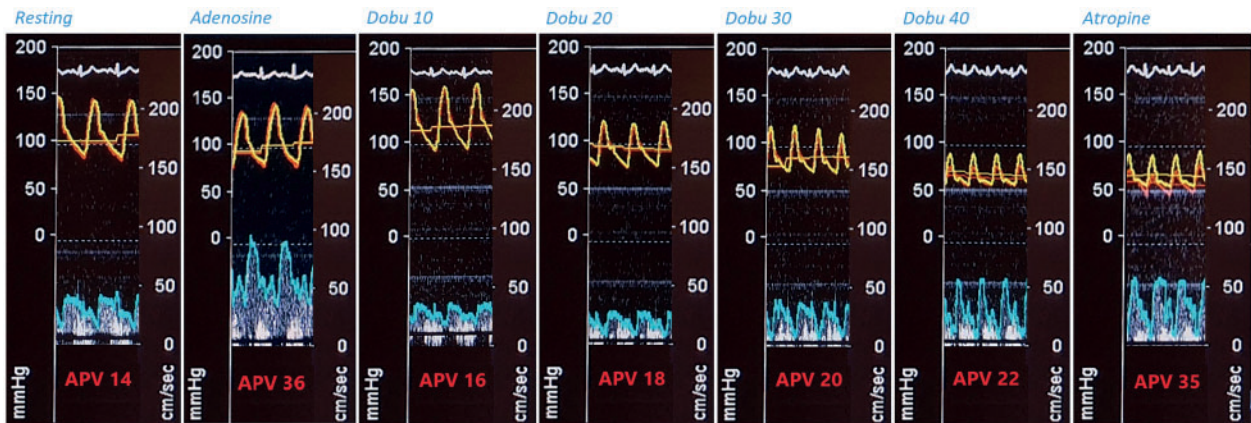


Figure 3 Resting: Measurements at rest. Adenosine: 120 mcg bolus. Dobu 10: dobutamine 10 $\mu\text{g}/\text{kg}/\text{min}$. Dobu 20: dobutamine 20 $\mu\text{g}/\text{kg}/\text{min}$. Dobu 30: dobutamine 30 $\mu\text{g}/\text{kg}/\text{min}$. Dobu 40: dobutamine 40 $\mu\text{g}/\text{kg}/\text{min}$. Atropine: 0.5 mg bolus. APV, average peak velocity.

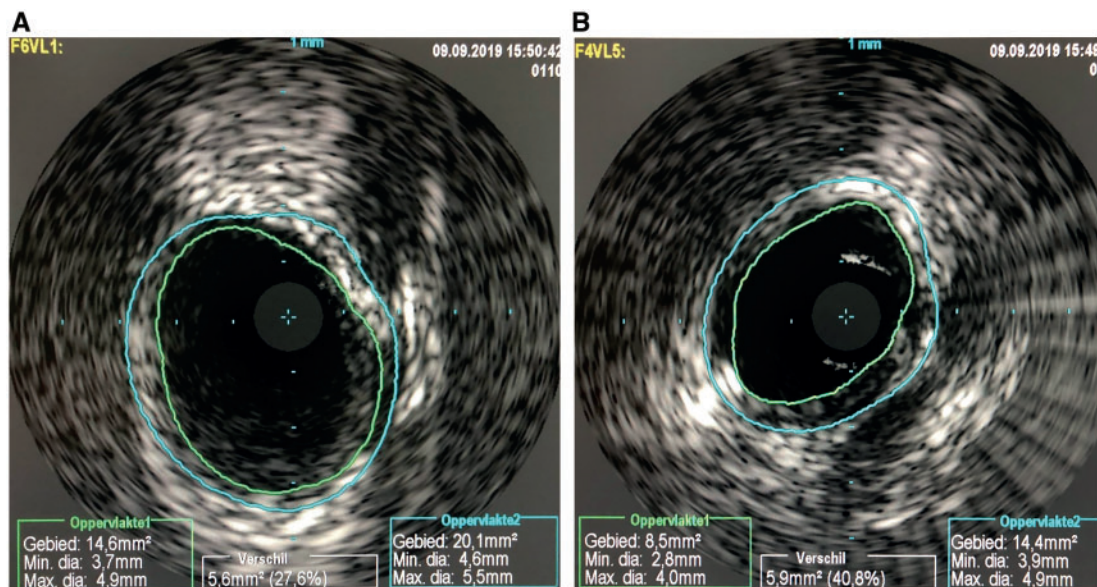


Figure 4 (A) An intravascular ultrasound image on the suspected malignant area measuring a luminal area of 14.6 mm^2 . (B) An intravascular ultrasound image on the same area during maximum dobutamine stress. The luminal area decreased to 8.5 mm^2 .

anomalies. A conservative approach in right-sided anomalies is mainly followed in the absence of myocardial ischaemia.⁸

Coronary surgery using the 'unroofing' technique is the general and accepted interventional treatment. In this 'unroofing' technique the outer part of the wall of between the aorta and the anomalous coronary will be removed. However, randomized trials to prove the superiority of any surgical methods is absent.

An earlier study used dobutamine stress perfusion CT to assess possible haemodynamic significant coronary obstruction.⁹ They used a similar dobutamine stress protocol while performing CT perfusion measurements to assess the functional risk of a

suspected malignant left coronary artery trajectory. Another study also added volume infusion to improve real-life exercise conditions.¹⁰ The impact of cardiac stress on both the inter-arterial route of the RCA and myocardial ischaemia was examined by using dobutamine stress IVUS, FFR, and CFVR. Intravascular ultrasound has already proven to be highly sensitive to measure cross-sectional area of a stenosis. In our patient, the intravascular area decreased from 14.6 mm^2 to 8.5 mm^2 showing a dobutamine-induced dynamic coronary vessel diameter. However, all functional measurements (FFR/CFVR) were indicative of the absence of myocardial ischaemia.

Conclusion and recommendation

To the best of our knowledge, this is the first report of a case assessing both intracoronary physiology as well as imaging during resting conditions and during a dobutamine stress test to assess the functional properties of a potential malignant intra-arterial coronary artery. Earlier research has already proven the use of IVUS and FFR in risk stratification.⁶ We suggest the addition of simultaneous dobutamine stress and IVUS/FFR (and CFVR) might help in the decision-making in patients with coronary anomalies.

Lead author biography



Bart van Gorsel received his medical degree from the University of Utrecht, The Netherlands in 2019. Currently, he is working as a clinician at the cardiology department from the Amphia hospital Breda, in his endeavour to obtain a cardiology residency.

Supplementary material

Supplementary material is available at *European Heart Journal - Case Reports* online.

Slide sets: A fully edited slide set detailing these cases and suitable for local presentation is available online as [Supplementary data](#).

Consent

The author/s confirm that written consent for submission and publication of this case report including image(s) and associated text has been obtained from the patient in line with COPE guidance.

Conflict of interest: none declared.

Funding: none declared.

References

- Baumgartner H, De Backer J, Babu-Narayan S, Budts W, Chessa M, Diller GP, et al.; ESC Scientific Document Group. 2020 ESC Guidelines for the management of adult congenital heart disease. *Eur Heart J* 2021;**42**:563–645.
- Kern MJ, Lerman A, Bech JW, de Bruyne B, Eeckhout E, Fearon WF, et al.; American Heart Association Committee on Diagnostic and Interventional Cardiac Catheterization, Council on Clinical Cardiology. Physiological assessment of coronary artery disease in the cardiac catheterization laboratory: a scientific statement from the American Heart Association Committee on diagnostic and interventional cardiac catheterization, council on clinical cardiology. *Circulation* 2006;**114**:1321–1341.
- Cheezeum MK, Libberthson RR, Shah NR, Villines TC, O’Gara PT, Landzberg MJ et al. Anomalous aortic origin of a coronary artery from the inappropriate sinus of valsalva. *J Am Coll Cardiol* 2017;**69**:1592–1608. doi:10.1016/j.jacc.2017.01.031.
- Napp LC, Schatka I, Kempf T, Bavendiek U, Bengel FM, Bauersachs J. Single coronary artery anomaly with interarterial left main: caught inbetween. *Eur Heart J* 2015;**36**:762.
- Satija B, Sanyal K, Katyayni K. Malignant anomalous right coronary artery detected by multidetector row computed tomography coronary angiography. *J Cardiovasc Dis Res* 2012;**3**:40–42.
- Driesen BW, Warmerdam EG, Sieswerda GT, Schoof PH, Meijboom FJ, Haas F et al. Anomalous coronary artery originating from the opposite sinus of Valsalva (ACAOS), fractional flow reserve- and intravascular ultrasound-guided management in adult patients. *Catheter Cardiovasc Interv* 2018;**92**:68–75.
- Gräni C, Kaufmann PA, Windecker S, Buechel RR. Coronary diagnosis and management of anomalous coronary. *Interv Cardiol* 2019;**14**:83–88.
- Lee SE, Yu CW, Park K, Park KW, Suh JW, Cho YS et al. Physiological and clinical relevance of anomalous right coronary artery originating from left sinus of Valsalva in adults. *Heart* 2016;**102**:114–119.
- Linsen PVM, Kofflard MJM, Lam SW, Kock MCJM. Images in CAD. *Coron Artery Dis* 2018;**29**:607–608.
- Bigler MR, Ashraf A, Seiler C, Praz F, Ueki Y, Windecker S et al. Hemodynamic relevance of anomalous coronary arteries originating from the opposite sinus of valsalva-in search of the evidence. *Front Cardiovasc Med* 2021;**7**:1–15. doi:10.3389/fcvm.2020.591326.