



Mesocaval Shunt Creation for Jejunal Variceal Bleeding with Chronic Portal Vein Thrombosis

Ja Kyung Yoon¹, Man-Deuk Kim¹, Do Yun Lee¹, and Seok Joo Han²

¹Department of Radiology, Severance Hospital, Research Institute of Radiological Science, Yonsei University College of Medicine, Seoul;

²Department of Pediatric Surgery, Severance Children's Hospital, Yonsei University College of Medicine, Seoul, Korea.

The creation of transjugular intrahepatic portosystemic shunt (TIPS) is a widely performed technique to relieve portal hypertension, and to manage recurrent variceal bleeding and refractory ascites in patients where medical and/or endoscopic treatments have failed. However, portosystemic shunt creation can be challenging in the presence of chronic portal vein occlusion. In this case report, we describe a minimally invasive endovascular mesocaval shunt creation with transsplenic approach for the management of recurrent variceal bleeding in a portal hypertension patient with intra- and extrahepatic portal vein occlusion.

Key Words: Portal hypertension, gastrointestinal hemorrhage, thrombosis, transjugular intrahepatic portosystemic shunt (TIPS), mesocaval, shunt

INTRODUCTION

Over the years, developments in the management of portal hypertension and variceal bleeding have led to a significant reduction in mortality.¹ Pharmacologic and endoscopic therapies remain the first-line treatment for prevention and treatment of variceal bleeding. In cases of first-line treatment failure, secondary options may be considered: surgical shunt creation, liver transplantation, and percutaneous treatments.

Transjugular intrahepatic portosystemic shunt (TIPS) is a well-described and widely performed technique to create a shunt between systemic and portal circulations, generally hepatic vein and portal vein, thereby bypassing the congested hepatic system. Unfortunately, portal vein thrombosis (PVT) occurs frequently in cirrhosis patients,² and have been reported to lower TIPS success rates to 40–75%.³ While surgical shunt is

a viable option, patients who do not meet surgical indications are left with very limited options. In this case report, we describe an endovascular mesocaval shunt creation with transsplenic approach to successfully manage variceal bleeding in a patient with total portal vein occlusion.

CASE REPORT

A 16-year-old female patient with portal hypertension and chronic portal vein occlusion was admitted for persistent melena and severe anemia. Patient history included duodenum-preserving resection of pancreatic head and Roux-en-Y pancreaticojejunostomy due to choledochal cyst at early childhood. Capsule endoscopy confirmed active bleeding with a large amount of blood clot at proximal jejunum (Fig. 1B). However, contrast-enhanced CT demonstrated total intra- and extrahepatic portal vein obliteration with intrahepatic collaterals and splenomegaly, rendering TIPS unfeasible (Fig. 1A). Alternatively, mesocaval shunt formation was decided under informed consent. Under US-guidance, a direct puncture of the splenic vein was done using a 21-G Chiba needle (Cook Medical, Bloomington, IN, USA) and a 7-Fr Flexor Check-Flo Ansel modification sheath (Cook Medical). Angiography showed total obliteration of superior mesenteric vein (SMV) with cavernous transformation and collateral vessels (Fig. 1C). An 11-mm Arrow balloon catheter (Teleflex, Dublin, Ireland) was placed at the SMV-

Received: January 25, 2017 **Revised:** July 21, 2017

Accepted: July 26, 2017

Corresponding author: Dr. Man-Deuk Kim, Department of Radiology, Severance Hospital, Research Institute of Radiological Science, Yonsei University College of Medicine, 50-1 Yonsei-ro, Seodaemun-gu, Seoul 03722, Korea.
Tel: 82-2-2228-7400, Fax: 82-2-393-3035, E-mail: mdkim@yuhs.ac

•The authors have no financial conflicts of interest.

© Copyright: Yonsei University College of Medicine 2018

This is an Open Access article distributed under the terms of the Creative Commons Attribution Non-Commercial License (<http://creativecommons.org/licenses/by-nc/4.0>) which permits unrestricted non-commercial use, distribution, and reproduction in any medium, provided the original work is properly cited.

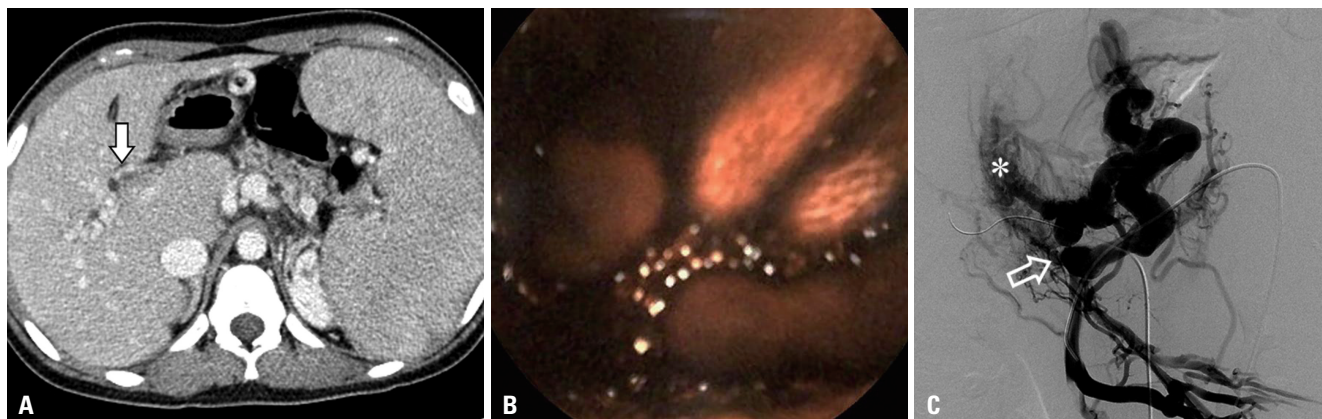


Fig. 1. Portal phase of preoperative contrast-enhanced CT image (A) shows total occlusion of portal vein due to extensive thrombosis (arrow) and cavernous malformation of intrahepatic portal veins with splenomegaly. Capsule endoscopy (B) revealed active bleeding and a large amount of blood clots at proximal jejunum. SMV angiography (C) shows cavernous transformation of intrahepatic portal vein (asterisk), and collateral vessels are seen. Total obliteration of SMV (open arrow) is noted. SMV, superior mesenteric vein.

splenic vein confluence as a fluoroscopic target. A 16-G Colapinto needle and a 9-Fr Teflon sheath (Transjugular Liver Access Set, Cook) were coaxially loaded over a guidewire via US-guided puncture of right internal jugular vein. Sheath tip was placed at the inferior vena cava (IVC), with a 0.035-inch guidewire placed at nearby common hepatic artery, due to concerns for vascular injury. Under fluoroscopic guidance, the Colapinto needle was advanced towards the target balloon, traversing the caudate lobe (Fig. 2A and D). After successful puncture of SMV, predilation of the extrahepatic tract was performed with 5-mm Mustang balloon catheter (Boston Scientific, Marlborough, MA, USA). An 8-mm×7-cm stent-graft (S&G Biotech, Seongnam, Korea) was placed, followed by stent dilatation using an 8-mm FoxCross balloon catheter (Abbott Laboratories, Abbott Park, IL, USA). Another 7-mm×23-mm Palmas Blue stent (Cordis, Miami, FL, USA) was placed at splenic vein to prevent shunt wasting. Final angiography revealed patent flow between the SMV to IVC with an inverted “Y”-stent configuration (Fig. 2B, C, and D) with decreased gastric varices. Portal vein pressure decreased immediately from 26-mmHg to 6-mmHg. Transsplenic tract embolization was done using histoacryl glue. No immediate complications occurred. At 9 month follow-up, mild gastrointestinal (GI) bleeding symptom recurred despite the disappearance of esophageal varices at endoscopy. Mild stenosis of the proximal stent was observed and treated with balloon dilatation. Shunt patency was maintained up to 24-month follow-up, with intermittent balloon dilatation of proximal stent stenosis.

DISCUSSION

Initially described by Nyman, et al.,⁴ a total of eight cases of mesocaval shunt creation in the presence of chronic portal occlusion⁴⁻⁸ have been reported in English publications (Table 1). While mesocaval shunt creation may be offered to patients

who are not surgical and/or TIPS candidates, certain anatomic requirements must be met. Preoperative contrast-enhanced CT should be performed to evaluate anatomic feasibilities, since potential complications may vary depending on the patient's anatomy.⁹ Injuries may occur at adjacent vasculatures, pancreas, duodenum, and any other structures. One case reported mesocaval shunt creation through the pancreatic uncinate process without complications.⁵ However, transpancreatic approach involves theoretical complications of pancreas bissection leading to pancreatic hemorrhage or inflammation⁷ and should be avoided if possible.

While most of the reported cases created entirely extrahepatic mesocaval shunts, we created a partially intrahepatic shunt by traversing the caudate lobe. A potential advantage for partially intrahepatic shunt is the prevention of shunt migration. Because a completely extrahepatic shunt lacks suitable anchoring structures, acute or delayed shunt migration has been suggested as a potential complication.⁵ It should be noted that, in the presented case, mild stenosis without thrombotic occlusion of the stent graft required repeated balloon dilatation. Whether the surrounding hepatic parenchyme contributed to intrahepatic stent graft stenosis is unclear.

To our best knowledge, this is only the second case of endovascular mesocaval shunt creation, with a unique use of transsplenic approach. Transcolonic,⁴ transgastric,⁸ or transabdominal^{6,7,9} routes have been utilized, but there are concerns for increased risks of peritonitis, sepsis and hemorrhage.^{5,6,8,9} Alternatively, a direct puncture of the splenic vein under US-guidance was adopted. Although not widely advocated, transsplenic approach has been shown to be safe and feasible for portal vein intervention with preventable complications.¹⁰⁻¹³ Moreover, transsplenic endovascular process can bypass direct puncture of the abdominal wall, intestines, and major vessels with a single needle, reducing the risk of infection. In addition, the risk of hemorrhage may be reduced since only one wall of the SMV is punctured.⁵

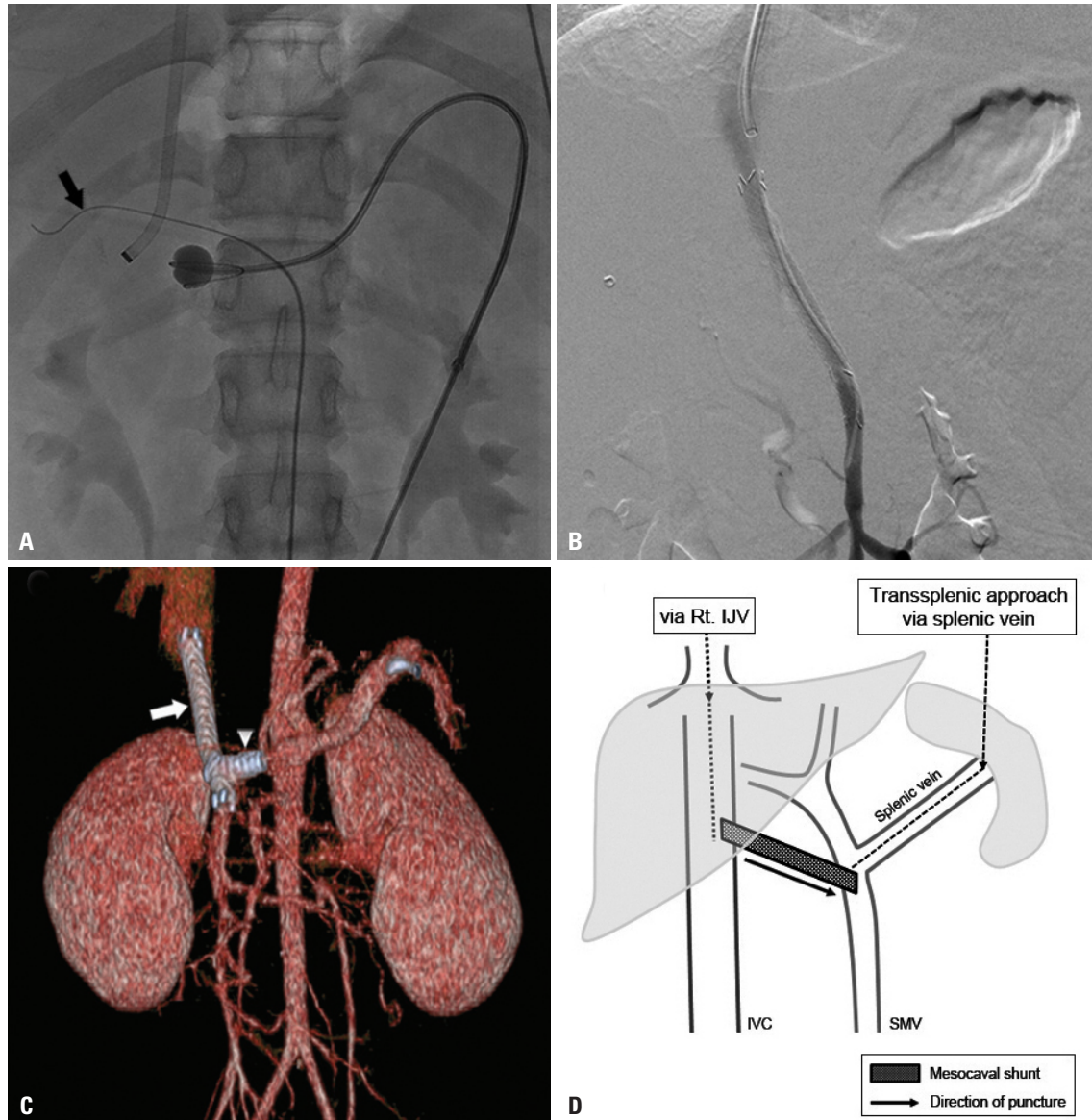


Fig. 2. Mesocaval shunt creation. (A) A 16-G Colapinto needle and a 9-Fr Teflon sheath were coaxially loaded over a guidewire via US-guided puncture of right IJV. Via US-guided puncture of the splenic vein, an 11-mm balloon catheter was placed at the SMV-splenic vein confluence. The inflated balloon was used as a fluoroscopic target. A 0.035-inch guidewire (black arrow) was placed in the dilated hepatic artery to avoid puncture of the target. (B) Final angiography shows patent mesocaval shunt between IVC and SMV. (C) CT-rendered three-dimensional image reveals patent stent graft (white arrow) with partial intrahepatic portion at the proximal end. Additional stent at distal splenic vein (arrowhead) to prevent shunt wasting resulted in an inverted “Y” configuration of stents. (D) Simplified diagram of transsplenic mesocaval shunt technique. Linear arrow represents the direction of puncture (splenic vein stent is not shown). IJV, internal jugular vein; SMV, superior mesenteric vein; IVC, inferior vena cava.

Despite the lack of long-term mortality analysis, mesocaval shunt offers an effective alternative treatment in patients with limited options due to PVT. Previous reports indicate that patients did not have recurrent thrombosis or variceal bleeding for as long as 18 months. Although our patient developed recurrent GI bleeding at 9 months, mesocaval shunt remained patent up to 24 months, which is the longest follow-up period up to date. Therefore, mesocaval shunt offers an alternative treatment in cases where TIPS cannot be applied. To determine its utility in clinical settings, further research on long-term durability of mesocaval shunt is warranted.

In conclusion, intrahepatic and extrahepatic PVT or occlusion poses a great challenge in creating percutaneous portosystemic shunts in portal hypertension patients. We present a successful fluoroscopy-guided, endovascular mesocaval shunt creation technique that can relieve portal hypertension and variceal bleeding in patients with total portal vein occlusion.

ORCID

Ja Kyung Yoon <https://orcid.org/0000-0002-3783-977X>
 Man-Deuk Kim <https://orcid.org/0000-0002-3575-5847>

Table 1. Summary of Previous Case Reports of Mesocaval Shunt Creation

Age/ sex	Clinical history	Imaging guidance	Technical approach	Clinical outcome	References
37/M	Idiopathic chronic PVT Recurrent massive variceal bleeding Failed prior surgical shunt attempts	CT and fluoroscopy	Transcolonic	Thrombosis (+)* Recurrent variceal bleeding (-) Follow-up period: 14 months	Nyman, et al. ⁴
57/M	Metastatic CRC with multiple metastastectomies Extrahepatic PVT Failed TIPS attempt	CT and fluoroscopy	Transgastric	Thrombosis (+) [†] Recurrent variceal bleeding (+) [†] Follow-up period: 3 months	Moriarty, et al. ⁸
16/F	Chronic PVT Recurrent GI bleeding Failed previous splenorenal shunt	Fluoroscopy and IVUS	Endovascular Side-firing IVUS probe	Thrombosis (-) Recurrent variceal bleeding (-) Follow-up period: 11 months	Hong, et al. ⁵
60/F	HCC with PV obliteration due to tumor thrombi Failed variceal banding	Fluoroscopy and IVUS	Endovascular Side-firing IVUS probe [‡]	Thrombosis (-) Recurrent variceal bleeding (-) Follow-up period: 10 months	Hong, et al. ⁵
55/M	Pancreatic teratoma S/P Whipple OP Segmental occlusion of SMV Failed endoscopic clipping	Fluoroscopy and IVUS	Endovascular Side-firing IVUS probe	Thrombosis (-) Recurrent variceal bleeding (-) Follow-up period: 3 months	Hong, et al. ⁵
13/M	Extrahepatic portal vein occlusion Failed surgical shunt attempt Retroperitoneal rhabdomyosarcoma S/P surgical resection and RT	CT	Transabdominal	Thrombosis (-) Recurrent variceal bleeding (-) Follow-up period: 18 months	Burke, et al. ⁶
58/F	C-viral cirrhosis with recurrent ascites Portal vein and SMV thrombosis Failed previous splenorenal shunt and TIPS attempt	Fluoroscopy	Transabdominal	Thrombosis (-) Recurrent variceal bleeding (-) Follow-up period: 3 months	Bercu, et al. ⁷
N/A	Cirrhosis PVT (+)	CT and fluoroscopy	Transabdominal	N/A	Davis, et al. ⁹
16/F	Chronic PVT Choledochal cyst S/P surgical resection	Fluoroscopy	Transsplenic	Thrombosis (-) Recurrent variceal bleeding (+) [§] Follow-up period: 24 months	Present case

N/A, not available; PVT, portal vein thrombosis; CRC, colorectal cancer; TIPS, transjugular intrahepatic portosystemic shunt; GI, gastrointestinal; HCC, hepatocellular carcinoma; PV, portal vein; OP, operation; SMV, superior mesenteric vein; RT, radiation therapy; S/P, status post; POD, post-operative day; IVUS, intravascular ultrasound.

*Thrombosis occurred at POD #1, which was fully recanalized by balloon embolectomy. 12-month follow-up angiography revealed thrombotic occlusion of the second mesocaval shunt, but patient did not have recurrent symptoms and no further intervention was performed, [†]Angiography at 24-hours was performed due to recurrent GI bleeding revealing total thrombotic occlusion of the mesocaval shunt. Failure of recanalization led to a second mesocaval shunt creation, [‡]Uncinate process of pancreas was traversed without significant complications, [§]Minor lower GI bleeding recurred at 9 months follow-up, but shunt patency was confirmed for 24 months.

REFERENCES

- Garcia-Tsao G, Sanyal AJ, Grace ND, Carey W; Practice Guidelines Committee of the American Association for the Study of Liver Diseases; Practice Parameters Committee of the American College of Gastroenterology. Prevention and management of gastroesophageal varices and variceal hemorrhage in cirrhosis. *Hepatology* 2007;46:922-38.
- Stine JG, Shah NL, Argo CK, Pelletier SJ, Caldwell SH, Northup PG. Increased risk of portal vein thrombosis in patients with cirrhosis due to nonalcoholic steatohepatitis. *Liver Transpl* 2015;21:1016-21.
- Wils A, van der Linden E, van Hoek B, Pattynama PM. Transjugular intrahepatic portosystemic shunt in patients with chronic portal vein occlusion and cavernous transformation. *J Clin Gastroenterol* 2009;43:982-4.
- Nyman UR, Semba CP, Chang H, Hoffman C, Dake MD. Percutaneous creation of a mesocaval shunt. *J Vasc Interv Radiol* 1996;7:769-73.
- Hong R, Dhanani RS, Louie JD, Sze DY. Intravascular ultrasound-guided mesocaval shunt creation in patients with portal or mesenteric venous occlusion. *J Vasc Interv Radiol* 2012;23:136-41.
- Burke C, Taylor AG, Ring EJ, Kerlan RK Jr. Creation of a percutaneous mesocaval shunt to control variceal bleeding in a child. *Pediatr Radiol* 2013;43:1218-20.
- Bercu ZL, Sheth SB, Noor A, Lookstein RA, Fischman AM, Nowakowski FS, et al. Percutaneous mesocaval shunt creation in a patient with chronic portal and superior mesenteric vein thrombosis. *Cardiovasc Intervent Radiol* 2015;38:1316-9.
- Moriarty JM, Kokabi N, Kee ST. Transvenous creation of a mesocaval shunt: report of use in the management of extrahepatic portal vein occlusion. *J Vasc Interv Radiol* 2012;23:565-7.
- Davis J, Chun AK, Borum ML. Could there be light at the end of the tunnel? Mesocaval shunting for refractory esophageal varices in patients with contraindications to transjugular intrahepatic portosystemic shunt. *World J Hepatol* 2016;8:790-5.

10. Chu HH, Kim HC, Jae HJ, Yi NJ, Lee KW, Suh KS, et al. Percutaneous transsplenic access to the portal vein for management of vascular complication in patients with chronic liver disease. *Cardiovasc Intervent Radiol* 2012;35:1388-95.
11. Bertram H, Pfister ED, Becker T, Schoof S. Transsplenic endovascular therapy of portal vein stenosis and subsequent complete portal vein thrombosis in a 2-year-old child. *J Vasc Interv Radiol* 2010;21:1760-4.
12. Tuite DJ, Rehman J, Davies MH, Patel JV, Nicholson AA, Kessel DO. Percutaneous transsplenic access in the management of bleeding varices from chronic portal vein thrombosis. *J Vasc Interv Radiol* 2007;18:1571-5.
13. Lee JY, Song SY, Kim J, Koh BH, Kim Y, Jeong WK, et al. Percutaneous transsplenic embolization of jejunal varices in a patient with liver cirrhosis: a case report. *Abdom Imaging* 2013;38:52-5.