

IgG4-Related disease simulating paraneoplastic syndrome: Role of ¹⁸F¹⁸FDG PET/CT imaging

Madhuri S Mahajan, Sudeshna Maitra, Natasha Singh, Melvika Pereira

Department of Nuclear Medicine and PET-CT, P.D. Hinduja National Hospital and MRC, Mumbai, Maharashtra, India

Correspondence: Dr. Madhuri S. Mahajan, Department of Nuclear Medicine and PET-CT, P.D. Hinduja National Hospital and MRC, Mumbai - 400 016, Maharashtra, India. E-mail: docmadhurim@gmail.com

Abstract

Immunoglobulin G4 (IgG4)-related systemic disease (IgG4-RSD) is a new systemic entity associated with autoimmune pancreatitis (AIP). Other organ involvements take the form of sclerosing cholangitis, sclerosing cholecystitis, sclerosing sialadenitis, retroperitoneal fibrosis, and interstitial nephritis. Recently, lung diseases related to IgG4 have been described to occur with or without other organ involvement. These diseases include interstitial lung disease (ILD), pulmonary inflammatory pseudotumor, and lymphomatoid granulomatosis. Most of these cases occur in combination with AIP, which also appears to have a general preponderance for males. The true incidence of IgG4-related ILD and the incidence of AIP are unknown. Here, we describe a case of a 53-year-old gentleman who presented with weight loss, fever, loose motions, altered sensorium, and persistent low hemoglobin, for which he was referred for 18-fluorodeoxyglucose positron emission tomography/computed tomography scan to diagnose probable underlying occult malignancy/paraneoplastic syndrome. It revealed features suggestive of IgG4 disease involving the pancreas and lungs, which was confirmed subsequently.

Key words: ¹⁸F¹⁸FDG PET/CT scan; Ig4 related disease; interstitial lung disease; paraneoplastic syndrome

Introduction

Autoimmune pancreatitis (AIP) is a distinct type of chronic pancreatitis and is characterized by abundant infiltration of Immunoglobulin G4 (IgG4)-positive plasma cells and associated fibrosis that lead to organ dysfunction. Patients with AIP typically present with jaundice or abdominal discomfort, severe abdominal pain, or acute pancreatitis. Current evidence, such as reversible improvement with corticosteroid therapy, strongly suggests an autoimmune cause for AIP; however, its exact pathophysiology remains speculative. IgG4 disease is characterized by involvement of other organs such as the lungs, kidneys, and salivary

glands in addition to pancreas. Hence, it is important to diagnose, determine the extent, guide biopsy, and to monitor the therapy of these patients. Here, we describe the case of a 53-year-old gentleman who presented with atypical clinical symptoms for IG4 disease and was referred for whole body 18-fluorodeoxyglucose positron emission tomography/computed tomography (¹⁸F¹⁸FDG PET/CT) scan.

Case Report

A 53-year-old gentleman presenting with weight loss, fever, loose motions, and altered sensorium was diagnosed with acute renal failure secondary to acute gastroenteritis

This is an open access article distributed under the terms of the Creative Commons Attribution-NonCommercial-ShareAlike 3.0 License, which allows others to remix, tweak, and build upon the work non-commercially, as long as the author is credited and the new creations are licensed under the identical terms.

For reprints contact: reprints@medknow.com

Cite this article as: Mahajan MS, Maitra S, Singh N, Pereira M. IgG4-Related disease simulating paraneoplastic syndrome: Role of ¹⁸F¹⁸FDG PET/CT imaging. Indian J Radiol Imaging 2017;27:249-53.

Access this article online

Quick Response Code:



Website:
www.ijri.org

DOI:
10.4103/ijri.IJRI_135_16

along with severe dehydration. His CT scan and magnetic resonance imaging (MRI) of the brain revealed multiple lacunar areas of nonhemorrhagic infarcts in the bilateral frontoparietal white matter and corona radiata with narrowing of right common and internal carotid artery. His serum creatinine was 2.9 mg%, Hb 7 g/dl, red blood cell count 2.23×10^{12} , white blood cell count 12.12×10^9 l, platelets 325×10^3 , K^+ 2.6 mEq/l, Na^+ 136 mEq/l, and Cl^- was 114 mEq/l. His urine sample was positive for Bence Jones protein, and serum electrophoresis showed raised kappa (112.6), raised λ (82.2), k/λ was 1.37, raised IgM (5.61), IgG (17.7), and normal IgA (4.53). Cerebrospinal fluid adenosine deaminase activity (CSF:ADA) was normal (1.6 u/l). Ultrasonography of the abdomen pelvis only revealed increased renal cortical echogenicity. His Weil Felix test for rickettsia was also positive. Considering nonspecific symptomatology and overlapping clinical, laboratory, and anatomical imaging investigations, ¹⁸F-FDG PET/CT scan was requested.

The ¹⁸F-FDG PET/CT scan was performed with the patient in the fasting state. Prior to intravenous injection of 370 MBq FDG, the patient's blood glucose level was measured to be 120 mg/dl. Following ingestion of 750 ml of 5% iodine-based oral contrast and after an uptake time of 60 min, imaging from head to mid-thigh was performed on a PET/CT scanner. There was diffuse-to-heterogeneous-moderate-grade increased ¹⁸F-FDG uptake seen in the entire pancreas (SUV max 6.6), which appeared relatively bulky and showed subtle peripancreatic fat stranding with blunting and truncation of the distal body and tail on CT images [Figures 1 and 2]. In addition, there was heterogeneous patchy uptake predominantly along the subpleural posterior and posterobasal regions in both the lungs with reticular inter and intralobular septal thickening with traction bronchiolectatic changes on CT images (SUV max 17.2 on the left) and peripheral subpleural ground glass opacities (SUV 4.5). Low-grade uptake was also seen in few small subcentimeter mediastinal lymph nodes in the

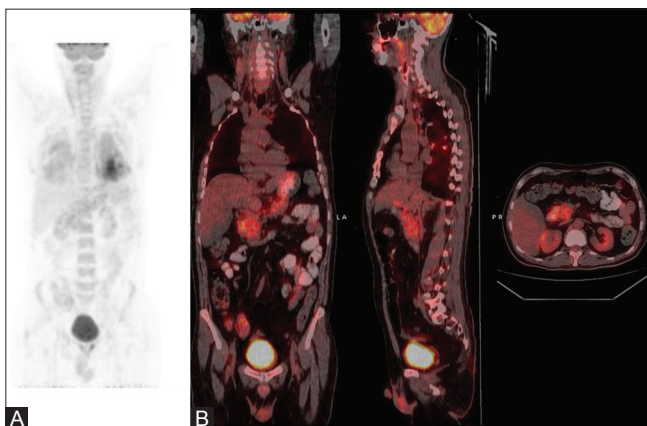


Figure 1 (A and B): (A) Whole body ¹⁸F-FDG PET/CT MIP and (B) fused PET/CT images: Abnormal diffuse to heterogeneous ¹⁸F-FDG uptake in the lungs, upper abdomen, bone marrow, and spleen

prevascular, right paratracheal, aortopulmonary window, precarinal, subcarinal, and right hilar regions (SUV max 3.5). There was diffuse uptake in marrow (SUV max 5.8) and spleen (SUV max 5) [Figure 1]. Overall scan findings were suspicious for IgG4-related involvement of the lung and pancreas.

Subsequently Serum Ig4 was tested and was found to be raised (>140 mg/dL); pancreatic biopsy performed was positive for pancreatitis, which showed diffuse lymphoplasmacytic infiltration, accompanied by obliterative phlebitis and interstitial fibrosis with predominance of CD8⁺ and CD4⁺ T lymphocytes in immunohistochemical typing. Bone marrow biopsy showed normocellular trilinear hematopoiesis. He was subsequently treated with injection solumedrol (250 mg) for 3 days, tablet creon (2500 mg) 1 OD for few days, and tablet wysolone, which was tapered later on. He showed tremendous improvement after first dose of injection solumedrol. After a 1-year follow-up period, the patient is stable and doing well.

Discussion

The exact pathophysiology of AIP remains speculative. It is an important mimic of pancreatic carcinoma, and 3–9% of the patients who undergo resection for a presumed carcinoma have AIP.^[1] Inadequate understanding may cause misdiagnosis of the disease as malignancies. Such misunderstanding can cause high psychological pressure in the patients, excessive examinations, and even unnecessary surgical intervention when the condition can actually be cured by corticosteroid-based treatment.

There are three recognized patterns of AIP – diffuse, focal, and multifocal [Figure 3]. Diffuse disease is the most common type, with a diffusely enlarged sausage-like pancreas and a sharp margin, loss of the lobular contour, and absence of pancreatic clefts seen on imaging.^[2,3] Multifocal involvement also may be present. It is diagnosed on the basis of the diagnostic criteria proposed by Kim *et al.*,^[4,5] which included a combination of the following radiologic, laboratory, clinical, and histologic findings; (a) enlargement of the pancreas and irregular segmental narrowing of the main pancreatic duct at imaging; (b) abnormally elevated serum IgG or IgG4 levels or the presence of autoantibodies; (c) characteristic histopathology features; and (d) response to corticosteroid therapy. The extrapancreatic organs that may be involved include the bile ducts, gallbladder, kidneys, retroperitoneum, mesentery, thyroid, lacrimal glands and orbits, salivary glands, lymph nodes, lungs, gastrointestinal tract, and blood vessels.^[6]

IgG4-related pulmonary disease has been reported in as many as 13% patients with AIP.^[7] The predominant radiographic patterns associated with IgG4-related lung

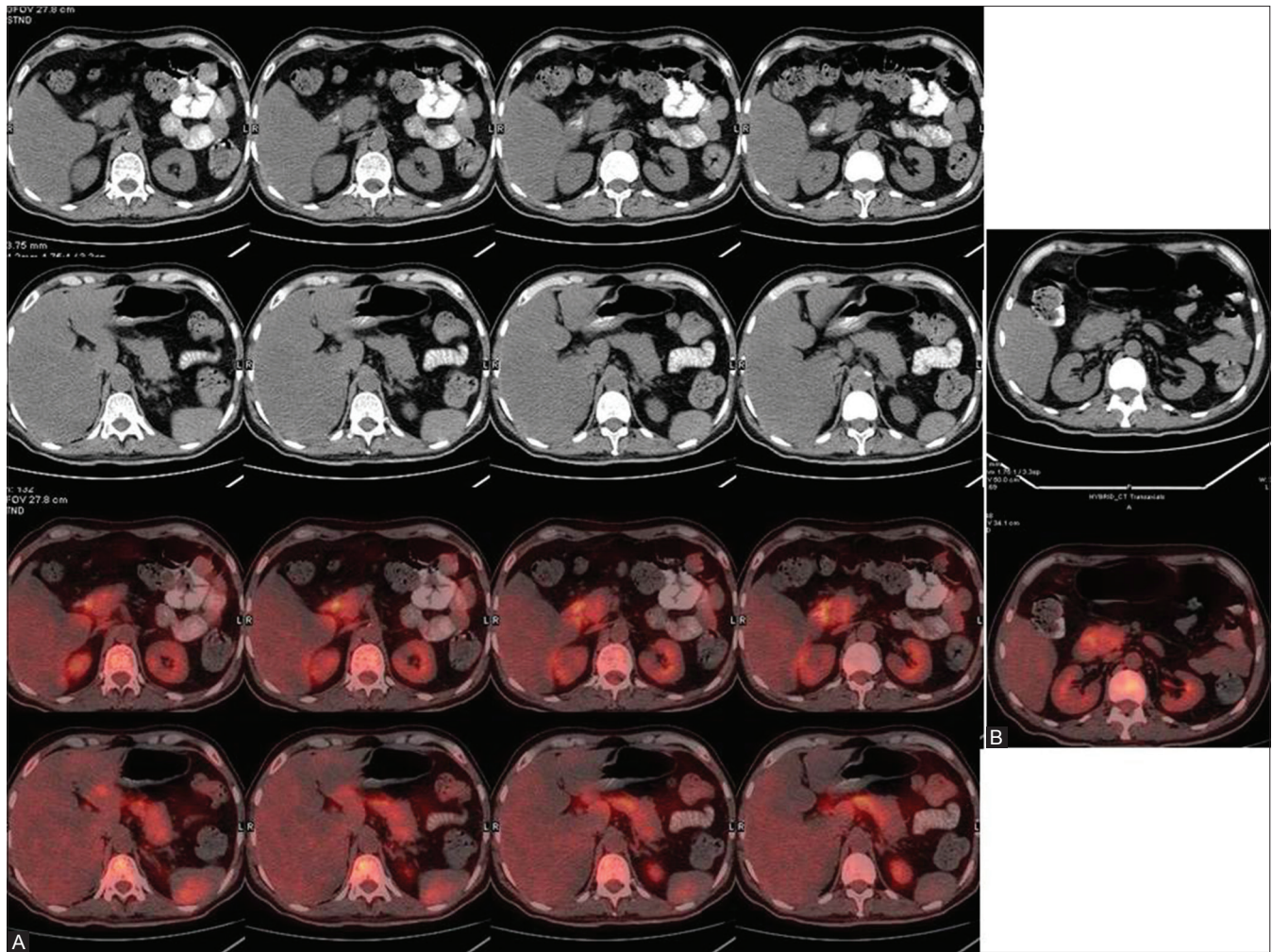


Figure 2 (A and B): (A) CT and axial fused ¹⁸F-FDG PET/CT images of the upper abdomen: Diffuse to heterogeneous moderate grade ¹⁸F-FDG uptake in entire pancreas, which appears relatively bulky with subtle peripancreatic fat stranding. (B) Delayed fused CT and axial fused ¹⁸F-FDG PET/CT images: persistent tracer retention in pancreas

disease are interstitial lung disease patterns including alveolar interstitial type with honeycombing, bronchiectasis, and diffuse ground glass opacity, as well as thickened bronchovascular bundles and interlobular septa. Other patterns such as solid nodules or mass-like lesions and round-shaped ground-glass opacities were also observed. Enlargement of hilar or mediastinal lymph node is also common. The prognosis of the disease still remains to be elucidated. However, because of the relative effectiveness of corticosteroids, though the data is limited, IgG4-related ILD appears to have a favorable clinical course. Recurrences have been reported, especially when the dose of steroid is tapered, and therefore, close monitoring would be imperative. Differential diagnosis may include idiopathic interstitial pneumonitis, sarcoidosis, and lymphoproliferative disorders.

A study was conducted by Lee^[8] among 94 clinically suspected patients who had tissue IgG4 staining ($n = 85$) or serum IgG4 greater than 135 mg/dL ($n = 9$) and who

underwent FDG PET/CT within 40 days. He found the final diagnosis of IgG4-RD in 28 patients with lower maximum standardized uptake value (SUVmax) of FDG uptake in lesions (4.6 ± 1.7 vs 7.1 ± 5.0) and higher submandibular gland SUVmax (2.8 ± 1.0 vs 2.3 ± 0.6), and were having diffuse/heterogeneous uptake pattern (78.6% vs 54.8%). With optimum criteria, ¹⁸F-FDG PET/CT had a sensitivity of 85.7% and specificity of 66.1% for diagnosing IgG4-RD. He concluded that ¹⁸F-FDG PET/CT has the capacity to potentially differentiate IgG4-RD from other diseases in clinically suspected patients.

Zhang^[9] conducted a study among 35 patients diagnosed with IgG4-RD according to the consensus criteria whose baseline 18F-FDG PET/CT scan was done. Among them, 29 patients underwent a second 18F-FDG PET/CT scan after 2–4 weeks of steroid-based therapy. He classified the most important characteristics into four categories. The first category was diffusely elevated 18F-FDG uptake in the exocrine organ, such as salivary glands,

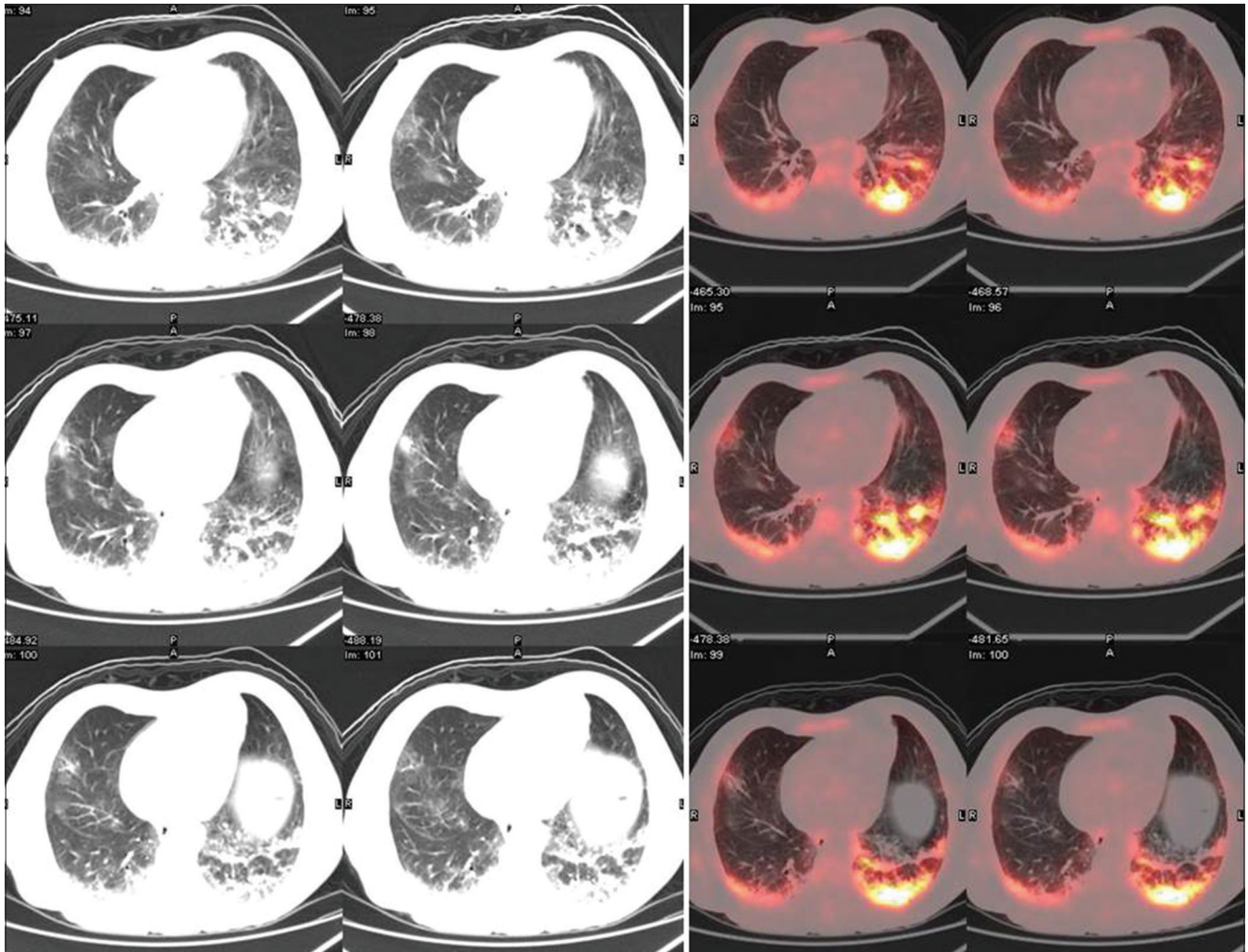


Figure 3: CT and axial fused ^{18}F -FDG PET/CT images of the lungs: Heterogeneous ^{18}F -FDG uptake predominantly along subpleural posterior and posterobasal regions in both lungs with peripheral subpleural ground glass opacities with reticular inter and intralobular septal thickening with traction bronchiolectatic changes

pancreas, and prostate gland. The second was patchy ^{18}F -FDG-avid hypermetabolic lesions, mainly involving the retroperitoneal region, vascular wall, bile duct, lungs, liver, and kidneys. The third was extensive distribution of multiple lesions that could not be interpreted as common metastasis of malignancies. The last was rapid and significant response to steroid-based treatment. Although none of these characteristics alone is specific enough for diagnosis of IgG4-RD, coexistence of several characteristics simultaneously may strongly indicate the disease. Another possible contribution of ^{18}F -FDG PET/CT in the diagnosis of IgG4-RD is its value in helping the selection of a minimal and adequate biopsy site, especially in cases with a negative result using conventional imaging methods, or those with multiple lesions but without functional preference. He concluded that whole body ^{18}F -FDG PET/CT can provide a comprehensive view of the organs/tissues involved in IgG4-RD and can detect a larger number of lesions than conventional imaging methods such as ultrasonography and CT. The image

characteristics or pattern of IgG4-RD observed on ^{18}F -FDG PET/CT may be used for the indication or diagnosis of IgG4-RD, aid in the selection of biopsy site, and guide the recanalization of ureteral obstruction, which is valuable for early response monitoring to achieve personalized treatment of the disease.

In our patient, ^{18}F -FDG-PET/CT scan was found to be useful in detecting AIP and associated extrapancreatic autoimmune disease involving the lungs, even though ultrasonography did not reveal any abnormality except only in the kidneys. By providing an adequate diagnosis of IgG4-RSD, the immediate introduction of steroids leads to better recovery and outcome of this patient. We conclude that ^{18}F -FDG-PET/CT scan enables the acquisition of whole-body images and provides functional information about disease activity and detection, and has a valuable role in staging the extent of the disease. It can also be useful for monitoring the disease activity. It may be a useful tool for differentiating AIP from pancreatic cancer when the findings of anatomical

imaging are equivocal. Moreover, it can be very valuable adjunct towards guiding the most accurate and adequate biopsy site also accomplishing minimally invasive biopsy.

Financial support and sponsorship

Nil.

Conflicts of interest

There are no conflicts of interest.

References

1. Abraham SC, Wilentz RE, Yeo CJ, Sohn TA, Cameron JL, Boitnott JK, *et al.* Pancreaticoduodenectomy (Whipple resections) in patients without malignancy: Are they all 'chronic pancreatitis'? *Am J Surg Pathol* 2003;27:110-20.
2. Sahani DV, Kalva SP, Farrell J, Maher MM, Saini S, Mueller PR, *et al.* Autoimmune pancreatitis: Imaging features. *Radiology* 2004;233:345-52.
3. Yang DH, Kim KW, Kim TK, Park SH, Kim SH, Kim MH, *et al.* Autoimmune pancreatitis: Radiologic findings in 20 patients. *Abdomen Imaging* 2006;31:94-102.
4. Kim KP, Kim MH, Kim JC, Lee SS, Seo DW, Lee SK. Diagnostic criteria for autoimmune chronic pancreatitis revisited. *World J Gastroenterol* 2006;12:2487-96.
5. Nakatani K, Nakamoto Y, Togashi K. Utility of FDG PET/CT in IgG4-related systemic disease. *Clin Radiol* 2012;67:297-305.
6. Kamisawa T, Egawa N, Nakajima H, Tsuruta K, Okamoto A, Hayashi Y, *et al.* Gastrointestinal findings in patients with autoimmune pancreatitis. *Endoscopy* 2005;37:1127-30.
7. Hirano K, Kawabe T, Komatsu Y, Matsubara S, Togawa O, Arizumi T, *et al.* High-rate pulmonary involvement in autoimmune pancreatitis. *Intern Med J* 2006;36:58-61.
8. Lee JI, Hyun SH, Kim S. Utility of FDG PET/CT for Differential Diagnosis of Patients Clinically Suspected of IgG4-Related Disease. *Clin Nucl Med* 2016;41:e237-43.
9. Zhang J, Chen H, Ma Y, Xiao Y, Niu N, Lin W, *et al.* Characterizing IgG4-related disease with ¹⁸F-FDG PET/CT: A prospective cohort study. *Eur J Nucl Med Mol Imaging* 2014;41:1624-34.