



Published in final edited form as:

*Infect Dis Res.* 2022 ; 3(1): . doi:10.53388/idr20220117003.

## Osteomyelitis of the spine: treatments and future directions

Yusuf Mehkri<sup>1</sup>, Patrick Felisma<sup>1</sup>, Eric Panther<sup>1</sup>, Brandon Lucke-Wold<sup>1,\*</sup>

<sup>1</sup>Department of Neurosurgery, University of Florida, Gainesville, Florida, the USA.

### Abstract

**Background:** Osteomyelitis of the spine is a serious condition that has been increasing with the intravenous drug pandemic and aging population. Multiple different organisms can cause osteomyelitis and mainstay of treatment is early recognition and antibiotics. The course can sometimes be indolent leading to delayed presentations. Once suspected, comprehensive workup and initiation of management should be employed. In rare circumstances, surgical evacuation or deformity correction is indicated. Continued antibiotic treatment should be considered post-operatively.

**Methods:** Emerging treatment solutions are being developed to help target osteomyelitis in a more effective manner. In this review, we highlight the epidemiology and pathophysiology of spinal osteomyelitis. We overview the diagnostic workup and treatment options. Finally, we present new options that are currently being investigated and are on the near horizon.

**Conclusion:** This review offers a user friendly resource for clinicians and researchers regarding osteomyelitis of the spine and will serve as a catalyst for further discovery.

### Keywords

osteomyelitis of spine; surgical treatment; medical management; emerging solutions

### Introduction

Vertebral osteomyelitis is a condition caused by bacterial infection of vertebral bodies and is often accompanied by infection of the adjacent intervertebral discs (discitis) [1]. Vertebral osteomyelitis and discitis frequently occur together, but also can occur independently. If both the vertebral bodies and discs are affected, the condition is termed spondylodiscitis [1]. 55-80% of vertebral osteomyelitis cases are caused by the bacterium *Staphylococcus aureus* [2]. The most common cause of infection is hematogenous spread from a distant site due to the impressive blood supply to the vertebral bodies [3]. Distant infections can be from previous spinal surgery, instrumentation such as spinal fixation devices, or epidural injections for pain management [4]. Patients most at risk for vertebral osteomyelitis are male patients aged >50 years old, intravenous drug users, patients with diabetes mellitus,

This is an open access article under the CC-BY license. (<http://creativecommons.org/licenses/by/4.0/>)

\***Corresponding to:** Brandon Lucke-Wold. Department of Neurosurgery, University of Florida, Gainesville, Florida, the USA. [bwold@mix.wvu.edu](mailto:bwold@mix.wvu.edu).

Competing interests

The authors declare no conflicts of interest.

long-term corticosteroid users, and/or patients who have undergone previous spinal surgery and instrumentation [4]. The incidence of spondylodiscitis has increased in recent decades to 4.8-7.4 cases per 100,000 [5]. This trend has been attributed to the higher prevalence of obesity, longer life expectancy of chronic disease patients, and increased usage of spinal surgery and instrumentation. Patients typically present with new and worsening neck or back pain, elevated inflammatory cytokines, and c-reactive protein, and fever [6]. Upon physical exam, tenderness to palpation over spinous and transverse processes raises suspicion of vertebral osteomyelitis. Most patients begin treatment conservatively with antibiotics since the surgical instrumentation is associated with bacterial infection. However, if patients do not respond well to antibiotics, surgery is required to prevent sepsis, spinal instability, and/or abscess formation.

The following review of the literature detailing the pathophysiology, current and future management of vertebral osteomyelitis was conducted in accordance with the Preferred Reporting Items for Systematic Reviews and Meta-Analyses (PRISMA) guidelines. In January 2022, the US National Library of Medicine (PubMed/MEDLINE) was systematically searched by two authors (YM and PF) to identify relevant studies published in the last five years (January 2017-January 2022). The search terms used were: ["vertebral osteomyelitis" OR "spinal osteomyelitis"]. Only full-text articles were included. A full-text screen followed a title screen to determine relevance. Low quality articles such as opinion pieces and case reports were excluded. The selection process is summarized in Figure 1.

## Pathophysiology

Vertebral osteomyelitis (also termed spinal osteomyelitis, septic discitis, disk-space infection, or spondylodiscitis) is inflammation or swelling, normally due to infection, of any of the osseous or soft tissue extradural segments of the spine [4]. These include the neural arch, epidural space, and paravertebral soft tissues [7]. Despite this extensive definition, the infection typically involves both the vertebrae and the intervertebral disc, although it's possible for the infection to be limited to one or the other depending on the vascular supply of the individual's intervertebral disc [8]. In adults, the disc is avascular and involvement in infection is secondary to direct spread from adjacent structures such as the vertebral body or soft tissue by direct implantation. In children, the disc has vascular channels crossing the cartilaginous growth plate and ending in the avascular nucleus pulposus, so it's infection can come about by direct hematogenous spread [9]. When starting in the vertebrae, infection usually first affects the anterior subchondral region (osseous endplate) of the vertebral body [7]. Only 5% of cases of VO involve posterior structures of the spine and this is largely because of the superior blood supply of the anteriorly located vertebral bodies [3]. Posterior vertebral involvement is commonly seen in the cases of actinomycosis, coccidioidomycosis, and neoplasms [10]. VO is generally an indolent and slow growing disease with nonspecific clinical presentation [11]. The most common sites of involvement are the lumbar spine, which is greater than thoracic spine, and then followed by the cervical spine. This rule holds true for the general population [9].

The two subsets of vertebral osteomyelitis (VO) are native vertebral osteomyelitis and post-operative vertebral osteomyelitis occurring after spinal surgery. Post-operative vertebral

osteomyelitis seems to result in poorer outcomes than native vertebral osteomyelitis, but studies comparing the two are scarce [12]. The etiology of VO can be pyogenic (bacterial), granulomatous (tuberculous, brucellar, fungal), or parasitic infections [8]. Non-infective causes include the related conditions of chronic recurrent multifocal osteomyelitis and SAPHO (synovitis, acne, pustulosis, hyperostosis, and osteitis) syndrome [7]. When due to infective causes, VO may be acute, subacute, or chronic. Symptoms lasting for greater than 3 weeks are acute, and those greater than 3 months are classified as chronic [4]. VO normally presents as a monomicrobial infection. Polymicrobial infection is rarer and typically ordinarily due to a contiguous spread that includes participation of anaerobes as a general rule [10]. This presents with differences in presentation and clinical outcomes from monomicrobial vertebral osteomyelitis [13].

The mechanisms of infection by which VO originates in the patient are either by hematogenous seeding, contiguous spread from an adjacent soft-tissue infection, or direct inoculation, which we will discuss next [4]. This direct inoculation can be the result of trauma or iatrogenic infection from percutaneous or open spinal surgeries and procedures (eg, epidural steroid injections, discography, chemonucleolysis) [9]. Hematogenous spread is the most common route and may present with important differences depending on the etiology of the infection [4]. In a study of 253 patients, it was reported that the primary foci of infection were the urinary tract, skin, soft tissue, a site of vascular access, endocarditis, bursitis, or septic arthritis [4].

Hematogenous seeding has two major theories regarding its spread in pyogenic vertebral osteomyelitis (PVO), the venous theory and the arteriolar theory. The venous theory assumes retrograde seeding of venous blood from the pelvic venous plexus to the paravertebral venous plexus (also termed the Batson venous plexus) by means of valveless meningeorrhachidian veins. However, there are mixed views on this theory. In the arteriolar theory, it's suggested that bacteria can become fixed in the end-arteriolar network near the vertebral end plate [3]. While much rarer, the infection can also spread from the retropharyngeal space to vertebral bodies in the cervical spine when the patient has a large enough prevertebral pharyngeal venous plexus to act as a pipeline for the spread of bacteria [9].

Local dissemination occurs after the infection has been established next to the vertebral body end plate, and can increase the severity of VO by direct seeding in specific compartments of the spine causing epidural, paravertebral, or psoas abscesses [4]. As soon as an infection is formed adjacent to the end plate of one vertebral body, it can break through said structure and infect the adjoining intervertebral disc. Because the disc is generally avascular, it is quickly consumed by bacterial enzymes and the infection can go on to spread to the next vertebral body. The damage to the vertebral bodies and intervertebral discs can lead to instability and collapse. This collapse can lead to retropulsion of infected bone or granulation tissue into the spinal canal, which would lead to neural compression or vascular occlusion. In the cervical spine, the infection can potentially break through the prevertebral fascia and spread to the mediastinum or the supraclavicular fossa. In an infection of the lumbar spine, abscess formation can course along the psoas muscle, into the piriformis fossa (buttock), perianal region, the groin, and possibly the popliteal fossa [9]. Local spread

into the spinal canal can cause epidural abscesses and potentially bacterial meningitis, although it's important to note that the opposite can be true in that concomitant VO can result as a complication of bacterial meningitis [14]. Further spread from the vertebral column involving paraspinal tissues, nerve roots, and even the intradural space will cause inflammation, abscesses, soft tissue and osseous destruction [3].

The aforementioned consequences of local dissemination can cause neurologic degeneration leading to neural deficit. Epidural abscesses caused by spread into the spinal canal can compress neural elements or infarct local blood supply to the spinal cord. Kyphosis caused by destruction of portions of the vertebral column may also cause neural impingement [9]. Other sequelae include motor weakness or paralysis, which are particularly high in those patients with VO of the cervical spine or frank sepsis [4]. The most common site of infection for pyogenic VO is the lumbar spine [15].

The pathophysiology of granulomatous vertebral osteomyelitis differs from that of pyogenic vertebral osteomyelitis. Causative organisms can include a plethora of bacteria, fungi, or parasites, but the most common organism causing granulomatous VO is *Mycobacterium tuberculosis* (Pott's Disease), which most often infects by the hematogenous route from a pulmonary origin. After seeding near the vertebral end plate, the host immune system starts the process of granuloma and caseous abscess formation. This begins by local migration of polymorphonuclear leukocytes to the infection site. Phagocytosis of the causative organism by macrophages subsequently turns the macrophages into epithelioid cells, and when numerous epithelioid cells come together, they create giant cells which is typical for this type of infection. Roughly one week after the start of the infection, lymphocytes migrate to wall off the infected tissue. Generally, coagulation necrosis will occur in the center of the lesion, liquifying the center and creating a caseating granuloma. This is caused by the protein fraction of *Mycobacterium tuberculosis*. But if the infection is caused by an atypical organism (eg. *Brucella*), coagulation necrosis may not occur [16].

In granulomatous VO, three patterns of vertebral involvement have been reported: peridiscal, central, and anterior. Of the three, peridiscal is the most common [9]. In the peridiscal pattern, the infection spreads peripherally from vertebral end plate to the adjacent intervertebral disc. Contiguous spread to adjacent vertebra happens deep to the anterior longitudinal ligament. Because *Mycobacterium Tuberculosis* does not create proteolytic enzymes, the intervertebral disc isn't as affected as it is in pyogenic VO [16]. This early sparing of the intervertebral disc that happens in granulomatous VO prevents the process of autofusion, which is a common occurrence in pyogenic VO [16]. The central pattern of granulomatous VO starts with abscess formation in the middle of the vertebral body which can cause vertebral body collapse, and then, spinal deformity. The anterior pattern starts with a nidus of infection anterior to the vertebral body and posterior to the anterior longitudinal ligament. This then spreads underneath the anterior longitudinal ligament and scallops on the anterior aspect of multiple vertebral bodies. This can cause an abscess that stretches over multiple vertebral bodies [16]. The most common site of infection for granulomatous VO is the thoracic spine [15].

## Common Organisms

Microbiology will vary depending on the host's risk factors (i.e. diabetes, coronary heart disease, immunosuppressive disorders, intravenous drug use) and local epidemiology [17]. The most common organism causing pyogenic VO is *Staphylococcus aureus*, especially the setting of hematogenous dissemination [3]. VO caused by *Staphylococcus aureus* is followed by *Escherichia coli*, *Streptococcus pyogenes*, and *Pseudomonas aeruginosa* [18]. Coagulase-negative staphylococci and *Propionibacterium acnes* are microorganisms that are generally implicated in cases of exogenous VO after spinal surgery, especially with the use of spinal fixation devices [4]. In cases of prolonged bacteremia, hematogenous VO due to low-virulence microorganisms has also been documented [4]. Other potential organisms include streptococci species, enterobacteriaceae, and enterococci [11]. *Proteus Mirabilis*, a rare cause of vertebral osteomyelitis, should be considered in the setting of recent urinary tract infection or urological surgery. Proteus organisms frequently infect the urinary tract and less commonly other locations such as surgical wounds [18]. While *Staphylococcus aureus* remain far and above the most common cause, there are many potential causative organisms (Table 1, Table 2).

Vertebral Osteomyelitis with alternate pathogens may present in endemic regions and immunocompromised patients [3]. *Mycobacterium Tuberculosis* is a common cause of granulomatous VO in developing countries [11]. Other atypical organisms causing granulomatous VO include bacteria, fungal, and parasitic organisms. Bacterial organisms include Brucella, Actinomyces, and Nocardia. Fungal VO is rare, but may involve causative organisms like candidiasis, histoplasmosis, aspergillosis, coccidioidomycosis, blastomycosis, and cryptococcosis. Parasitic organisms include Echinococcus and *Taenia solium* [16].

VO caused by non-tuberculous mycobacterial (NBTM) organisms is rare, becoming more common. NBTM VO osteomyelitis is generally associated with patients in immunocompromised states but can occur in healthy individuals [19]. *Mycobacterium Avium* is reported to be the most common causative agent. *Mycobacterium abscessus* is an extremely rare case with only eight cases reported in the literature. *Mycobacterium abscessus* is a rapidly growing pathogen that can be found in soil, plants, and aqueous environments and normally implicated in pulmonary infections and as a cause of post-traumatic infections in skin, soft tissue, and long bones [20].

## Diagnosis

Vertebral osteomyelitis (VO) presents as a challenging diagnosis for many clinicians because of its indolent and slow progression coupled with various nonspecific symptoms ranging from neck/back pain, malaise, night sweats, anemia, weight loss, fatigue, fever, spine deformity painful dorsal flexion, and contingently, neurological deficit that can become permanent [11]. An initial workup should include MRI and CT of the spine, erythrocyte sedimentation rate (ESR) and c-reactive protein (CRP), blood cultures, and an infectious disease workup. Often the infectious disease workup will involve an interventional radiology guided biopsy. An average delay of 2 to 6 months between first symptoms and diagnosis

has been reported [21]. VO can also be misdiagnosed and mismanaged as a degenerative process. In the setting of delayed and misdiagnosis, patients are frequently developed destructive lesions or neurological complications [22]. Delays in diagnosis and treatment are connected to considerable morbidity and mortality [11]. Late diagnosis can lead to general multiple organ failure and epidural abscesses [23]. Early diagnosis has improved VO clearance and clinical outcomes but is also held back by the fact that 30-70% of patients with VO show no signs of prior infection [13]. As a result, diagnosis should be supported by a combination of history and physical examination, laboratory data, clinical findings, and proper imaging, as to allow the clinician to reach a reasonable index of suspicion [21]. As such, a multidisciplinary approach is essential, and the diagnosis and management of VO is managed best by an interprofessional team that includes a radiologist, infectious disease expert, orthopedic surgeon, internist, pathologist, nurses, and pharmacists [3]. Diagnosis confirmation will rely on MRI and microbiological documentation by blood cultures and/or image-guided percutaneous vertebral biopsy as mentioned above [24]. Unless the patient is septic or exhibits neurologic compromise, empirical antimicrobial therapy should generally be withheld, until a microbiologic diagnosis is confirmed [25].

## Laboratory data

VO is normally diagnosed in the setting of unmanageable protracted back pain unresponsive to conservative measures and elevated inflammatory markers with or without fever [25]. Several clinical routine markers are appropriate for diagnosis of VO and evaluating treatment response. Of these markers CRP is the most sensitive for bacterial infection as it is elevated in more than 90% of cases of acute VO [22]. It is also considered the most specific marker for treatment response because it returns to normal levels quickly after successful treatment. ESR is also a sensitive marker but has a low specificity. As a result, ESR can't be used as effectively as CRP to monitor therapeutic outcome, because it remains elevated in 50% of patients with good clinical outcomes [21]. In patients with nonspecific back pain, elevated ESR and CRP tests have a sensitivity ranging from 94% to 100%, and are useful when ruling out the presence of an infection or malignancy [22]. CRP is normally elevated alongside ESR, but CRP is more sensitive and specific due to its shorter half-life. These inflammatory markers should be followed closely during the treatment of VO, because ESR > 55 mm/h and CRP > 2.75 after 4 weeks of antibiotic treatment is associated with treatment failure (odds ratio 5.15). It is, however, important to note that granulomatous VO caused by *Mycobacterium Tuberculosis* is less frequently associated with elevated inflammatory markers compared to pyogenic PO [26].

The white blood cell (WBC) count is less useful than ESR and CRP because a normal WBC doesn't rule out a diagnosis of spinal infection [21]. Up to 40% of patients with native VO retain a normal WBC [25]. Procalcitonin (PCT) is a favorable marker that can be used to distinguish between bacterial and nonbacterial infection. PCT is less sensitive than CRP in patients with VO, but the sensitivity increases with multiple infected sites. As follows, patients with elevated PCT levels should be considered as suffering from a combined infection, and adequate antibiotic treatment is necessary [21].

When VO is suspected, and the patient is stable (nonseptic and without signs of neurologic impairment) collecting blood and urine cultures before beginning antibiotic therapy is the standard of care as empiric treatment has been connected to lower diagnostic yield. If tuberculosis is suspected, acid fast bacilli (AFB) and cultures should also be collected [26]. 59% of positive blood cultures (BC) identify the etiological organism in monomicrobial pyogenic VO and can drive antibiotic selection as well as predict poor outcomes of nonoperative treatment [26]. If BC is negative and microbiological diagnosis hasn't been established, but imaging findings support VO, Computed Tomography (CT)-guided aspiration or biopsy of a disc space or vertebral end plate sample submitted for microbiologic examination is recommended for patients with suspected VO [22]. CT guidance will offer continuous assessment of the sampling needle position in relation to the anatomic target. An MRI or nuclear medicine study will assist in site selection for said CT-guided aspiration or biopsy [3]. If percutaneous culture still cannot be collected successfully, then open biopsy should be considered [26]. The concomitant presence of *Staphylococcus Aureus* bloodstream infection in the preceding 3 months and compatible spine MRI changes may preclude the need for aspiration in most patients [24].

## Imaging

Contrast-enhanced magnetic resonance imaging (MRI) is the gold standard when diagnosing VO due to a high sensitivity (96%), high specificity (94%), and its ability to provide detailed data on paraspinal soft tissues and the epidural space. The typical MRI findings in patients suffering from VO are hypointense discs and vertebral bodies in T1-weighted and hyperintense signals of those same structures in T2-weighted images with corresponding enhancement on postcontrast imaging [21]. The infected disc space will present with decreased T1-weighted signal along with increased T2 signal with contrast enhancement [3]. These early MRI findings are highly sensitive (70-100%) MRI can also help distinguish between tubercular VO and pyogenic VO through the identification of large, well-defined paraspinal abscesses with thin rim enhancement and smooth margins, thoracic spine involvement, subligamentous extension to adjacent vertebra with preserved disc height, as well as multi-level involvement with skip lesion [26].

Some patients may have MRI contraindication, and as such, require a different imaging modality. Nuclear medicine has proven to be an acceptable alternative. Gallium-67 single photon emission computed tomography (SPECT) has a sensitivity similar to MRI. Bone scintigraphy with technetium 99m and Indium-111 have been shown to be less sensitive. 18F-Fluorodeoxyglucose (18F-FDG) positron emission tomography (PET) is also a comparable alternative. 18-FDG will accrue at sites of infection and inflammation. However, PET lacks specificity because this radionucleotide uptake can take place in various inflammatory and neoplastic processes. As a result, clinicians must look at PET results in the framework of previous clinical and imaging findings [3].

Plain and flexion/extension X-rays should be performed in every baseline evaluation, but a plain radiograph of the spine is not sensitive enough for the early diagnosis of VO [25]. Plain radiographs are generally normal during the early phases of VO. Some irregular findings, such as narrow disc space and destruction of endplates may be apparent in

pyogenic VO, but osseous destruction may not be present for weeks. Tuberculous VO will spare the disc space entirely early on and show vertebral involvement. As such plain radiography is primarily useful in chronic pyogenic and tuberculous VO and should be used primarily for surgical planning to assess for kyphotic deformity [26].

## Medical management

Treatment of VO includes both antibiotic treatment as well as surgical management [11]. While some guidelines are available, treatment for VO is not standardized and usually based on individual preferences. In general, the goal of treatment should be eradication of the infection by treating the causative systemic disease and removing its septic focus, restoring and preserving the structure and function of the spine, and alleviating pain [1]. First line treatment should be based on a conservative attempt, which is reasonable in the setting of early-stage VO with no, or minor, neural deficits as well as in patients with comorbidities that may limit surgical options. In the case of empiric antibiotic therapy, Clindamycin + Ciprofloxacin or Cefotaxime Flucloxacillin should be given to cover a wide range of potential pathogens. Some newer agents used include linezolid, daptomycin, tigecycline, and telavancin. These newer agents aren't licensed for use in osteomyelitis, but are all active against Gram-positive bacteria including MRSA [8]. Empirical treatment should always cover *Staphylococcus Aureus* as the most common cause, as well Gram-negative organisms, but should otherwise be dictated by the patient's risk factors and local epidemiology, taking into account the likelihood of colonization with resistant organisms. Fungal VO may be treated conservatively with antifungal agents such as amphotericin B [27]. Definitive therapy must be adapted to the results of culture and in vitro susceptibility testing [25]. As such, the appropriate antibiotics should be applied intravenously for 2-4 weeks or until the patients CRP levels have normalized. Oral antibiotic treatment should be administered after this for a total of 6 to 12 weeks. This is recommended by most published guidance. However, the 2015 IDSA guidance shortened treatment to 6 weeks and emphasizes that the selected oral agents should have high bioavailability [28]. Some possible options include fluoroquinolones, clindamycin, rifampicin, and fusidic acid. In recent years there has been a move towards early oral antibiotic therapy and/or outpatient parenteral antibiotic therapy due to patient choice and pressure on hospital beds. However early conversion should be avoided until endocarditis has been excluded [8]. Depending on pain upon mobilization, conservative treatment should also include bed rest and/or orthosis for at least 6 weeks [21]. The patient's response to treatment is generally assessed through the clinical picture, monitoring CRP and ESR, and MRI imaging [8]. Most patients are cured within a 6-week course of antimicrobials, but may need surgical debridement and/or spinal stabilization during the term of therapy. Courses of antimicrobial therapy longer than 6 weeks are not more efficacious for typical cases. However, even after treatment, recovery after VO is normally prolonged [29]. Patients should be educated about prognosis for VO as well as the importance of adhering to medication and the consequences of inadequate treatment. They should also be urged to seek immediate care if symptoms worsen during treatment [3].

If treatment fails, management options are best determined by trending clinical, laboratory, and imaging data. Surgery should only be considered when medical options have failed or in the event of complex cases, but the end result in both conservative and surgical treatment



is always bony fusion. If imaging fails to identify a surgical target, then it's appropriate to repeat blood cultures and take atypical pathogens into consideration [21].

## Surgical management

Surgical treatment of vertebral osteomyelitis is rare, but is indicated when there is neurologic compromise, significant disc space and vertebral osteolysis leading to instability, developing kyphosis, epidural or psoas abscess formation, or failure of conservative antibiotic treatment [25]. There is, however, mixed data on the effectiveness of surgical intervention in treating vertebral osteomyelitis. Dimar et al. performed a study on 42 patients with vertebral osteomyelitis who underwent a two-stage anterior debridement surgery followed by posterior fusion [30]. 40 patients had complete resolution of infection and 2 patients died. In contrast, Valancius et al. reports 117 vertebral osteomyelitis patients who underwent various procedures to remove the infected bone with little success [31]. Among these patients, 24/117 (20%) required re-operation, 7/117 (6%) died within a year of follow-up, and 27/117 (23%) reported residual post-operative back pain. Below, are the most common surgical techniques, their indications, and post-operative outcomes.

### Anterior minimally invasive retroperitoneal debridement with pedicle screw instrumentation

The anterior retroperitoneal debridement approach, also known as the oblique retroperitoneal approach (ORA), is primarily indicated in patients with lumbar vertebral osteomyelitis and/or a psoas abscess [32]. In this procedure, the patient is in the lateral decubitus position, and the affected vertebral body is identified through imaging. The vertebral body is accessed through a 4 cm incision, passing through the external abdominal oblique, internal abdominal oblique, and transverse abdominis muscles. The vertebral body and neighboring discs are removed and replaced with a synthetic titanium or polyetheretherketone (PEEK) cage filled with bone graft to reestablish normal spinal curvature. Patients then undergo pedicle screw fixation. The average operating time is 162.9-375 minutes, average blood loss is 1152-1470 mL, the average corrected lordotic angle is  $6.1 \pm 10.3^\circ$ , and the average stay in the spine unit is 30 days [33]. Many patients experience immediate relief of pain and reduction of fever, and the anterior approach minimizes the damage done to the paraspinal muscles and bones [34]. However, 10% have infection recurrence, 6.3% require revision surgery, and 14.6% of patients die [33].

### Anterior minimally invasive retropleural debridement approach

The anterior minimally invasive retropleural approach can be used in treating patients with thoracic vertebral osteomyelitis [35]. In this procedure, the patient is in the lateral decubitus position, and an 8 cm incision is made at the appropriate rib level. The lung is retracted anteriorly, revealing the affected vertebral body. The vertebral body and neighboring discs are removed and replaced with an implantable titanium or PEEK cage. One of the main advantages of this procedure is the ability to restore the normal curvature of the spine and access the vertebral body without spinal cord manipulation [36]. However, a notable complication of the surgery is increased risk of the development of a pneumothorax [37].

### **Single-Stage posterior debridement approach**

The posterior debridement approach involves a posterior, linear midline incision followed by placement of pedicle screws. This procedure is most often used when the thoracic spine is involved and/or an epidural abscess is present [38]. The spinal process and laminae are removed, followed by the removal of the diseased vertebrae [34]. A PEEK bone graft cage is then placed. The kyphotic deformity is then corrected using a screw and rod fixation [39]. The average operating time is 123 min, average corrected lordotic angle is  $4.3^\circ \pm 8.4^\circ$ , and the average blood loss is 679 mL [40]. The posterior approach enables rigid fixation through the placement of pedicle screws [34].

### **Single-Stage combined anterior-posterior approach**

The combined anterior-posterior approach is used when there is significant destruction/erosion of vertebral endplates and when the effected vertebral body cannot be adequately exposed through a posterior-only approach [41]. The patient is operated on in the lateral decubitus position for the anterior procedure and in the prone position for the posterior procedure. First, stabilizing transpedicle screws are placed through a posterior midline incision. This is followed by the anterior/retroperitoneal removal of the diseased vertebrae. A titanium mesh cage with bone graft is then placed for stabilization [41]. The average operating time is 270-300 minutes, the average blood loss is 700-1420mL, the average corrected lordotic angle is  $3.5^\circ \pm 11.2^\circ$ , and the average stay in the spine unit is 38 days [40]. Patients improve in neurological condition and experience immediate pain relief. Additionally, the combined approach allows the direct removal of the infected vertebral body, short spinal fixation associated with improved range of motion, and better sagittal deformity correction [34].

## **Novel treatments**

Although the medical and surgical management of osteomyelitis of the spine is sufficient for most cases, severe cases of infection especially in high-risk patients require novel treatments to improve drug delivery and overcome drug resistance. Several treatment strategies have been identified and few have entered clinical studies. These primarily include improved drug delivery vehicles and combination therapies.

### **Delivery vehicles**

Hydrogels are versatile drug vehicles that are water based and composed of select synthetic or natural hydrophilic polymers including chitosan, silk, gelatin, polyethylene glycol, among others [42]. Modification of the hydrogel composition can allow for alteration of the drug elution rate [43]. They typically biodegrade within weeks and can slowly release low concentrations of the drug over this duration [44]. Hydrogels have been shown to be therapeutically effective by reducing bacterial load and supporting healing when used as carriers for not only antibiotics, but also bacteriophages, proteins and nanoparticles containing therapeutics [45].

Novel formulations of drug-eluting bone cement are also under investigation. Traditional drug-carrying bone cements proved to be counter-productive as they released subtherapeutic

levels of antibiotics following an initial burst and therefore contributed to resistance [46]. Modified polymethylmethacrylate (PMMA) bone cement has shown great promise with two studies showing significant continuous release of antibiotics while maintaining proper strength for joint fixation and space maintenance [47]. A major limitation associated with the use of modified bone cements, especially those that may not provide proper joint fixation, is the high risk for either re-infection or need for subsequent surgical intervention [48].

Nanoparticles, similar to hydrogels, can also vary in composition and carry a variety of antimicrobial therapeutics. They can improve delivery due to their high affinity for bacteria and ability to protect their drug from degradation, thereby increasing the half-life and bioavailability of the drug [49]. In addition, nanoparticles can also be designed to target specific internal stimuli such as infectious environments, allowing for targeted therapy [50]. Nanoparticle delivery is especially unique in that it can target infected host cells for intracellular infections that are common causes of recurrent osteomyelitis [51]. This is another way in which nanoparticles can be designed to enhance cellular uptake and increase intracellular bioactivity. Multiple studies have demonstrated efficacy for the use of modified nanoparticles to eradicate infection following extended release of high-dose antibiotics [52].

### Combination therapies

Combination antibiotics, although not novel, should be preferred over monotherapy to avoid resistance, especially when dealing with small colony variants and biofilms that are already innately resistant to antimicrobial therapeutics due to their overall decreased metabolic activity [42]. Vergidis and colleagues showed not only increased antimicrobial activity, but also decreased resistance when using combination therapy (linezolid and rifampin) relative to monotherapy in an animal model of osteomyelitis [53]. These results were replicated by numerous other animal models [54]. Monotherapy should largely be avoided to prevent recurrence and future surgical management.

Antibiotics can also be combined with bacteriophages for more targeted therapy, especially in patients with antibiotic-resistant infections. Bacteriophages are unique in that they proliferate and generate larger effects when interacting with their host bacteria [55]. These properties make them ideal for treating vertebral osteomyelitis, specifically when combined with a broad-spectrum antibiotic. Several large clinical trials have already demonstrated the potential benefits and efficacy of bacteriophage therapeutics for treating multiple pathologies including chronic otitis, urinary tract infections and ventricular assist device infection [56]. One potential limitation is the specificity bacteriophages have for a single bacterium. Therefore, they need to be combined with either a broad-spectrum antibiotic or multiple strains of bacteriophages for clinical efficacy [57].

Antimicrobial proteins (AMPs) and enzymes can also be combined with antibiotics to rapidly reduce bacterial load and avoid resistance or recurrence.  $\beta$ -defensins are AMPs that have been shown to activate the innate immune system within bone and can therefore be used both for treatment and prophylactic purposes [58]. Unlike bacteriophages,  $\beta$ -defensins are broad-spectrum and have been shown to be effective against multiple multi-drug resistant bacteria [59]. Interestingly, they have also been shown to inhibit biofilm formation, a major

form of treatment resistance in vertebral osteomyelitis [60]. When compared to vancomycin,  $\beta$ -defensins demonstrated similar bactericidal activity [61]. A major limitation of AMPs, such as  $\beta$ -defensins, is low stability and bioavailability, and therefore requires a proper delivery vehicle. Like AMPs, enzymes have also been shown to be active against biofilms and resistant bacteria [62]. For example, endolysins are capable of rapid bacterial lysis via cell wall digestion [63]. Given that they're produced by bacteriophages, they overcome the limitations associated with whole phage usage. Chimeric endolysins have been developed and demonstrated efficacy against multiple strains of bacteria typically involved in vertebral osteomyelitis [64]. Another promising enzyme that functions similarly and can function synergistically with other antimicrobial therapeutics is lysostaphin [65]. However, a major limitation with use of this enzyme is its specificity for *S. aureus* [66].

## Conclusion

Osteomyelitis of the spine is an important disease of increasing incidence with a complex pathophysiology and challenging diagnosis. When a patient has intractable back pain and elevated inflammatory markers, suspicion should be high. Treatment is primarily medical, with surgical management in select cases such as kyphotic deformity or neurologic deficits. There are no universal guidelines for treatment and treatment failures are not uncommon. Therefore, these patients should be followed by medicine, surgical, and infectious disease teams. Due to the lack of treatment efficacy, delivery vehicles for targeted drug therapy and novel therapeutics are beginning to be explored. These may be combined with interventional or surgical approaches to improve outcomes for patients.

## Abbreviations

<b>PRISMA</b>	Preferred Reporting Items for Systematic Reviews and Meta-Analyses
<b>VO</b>	vertebral osteomyelitis
<b>PVO</b>	pyogenic vertebral osteomyelitis
<b>NBTM</b>	non-tuberculous mycobacterial
<b>ESR</b>	erythrocyte sedimentation rate
<b>CRP</b>	c-reactive protein
<b>WBC</b>	the white blood cell
<b>PCT</b>	Procalcitonin
<b>AFB</b>	acid fast bacilli
<b>BC</b>	blood cultures
<b>CT</b>	Computed Tomography
<b>MRI</b>	magnetic resonance imaging

<b>SPECT</b>	single photon emission computed tomography
<b>18F-FDG</b>	18F-Fluorodeoxyglucose
<b>PET</b>	positron emission tomography
<b>ORA</b>	oblique retroperitoneal approach
<b>PEEK</b>	polyetheretherketone
<b>PMMA</b>	polymethylmethacrylate
<b>AMPs</b>	Antimicrobial proteins

## References

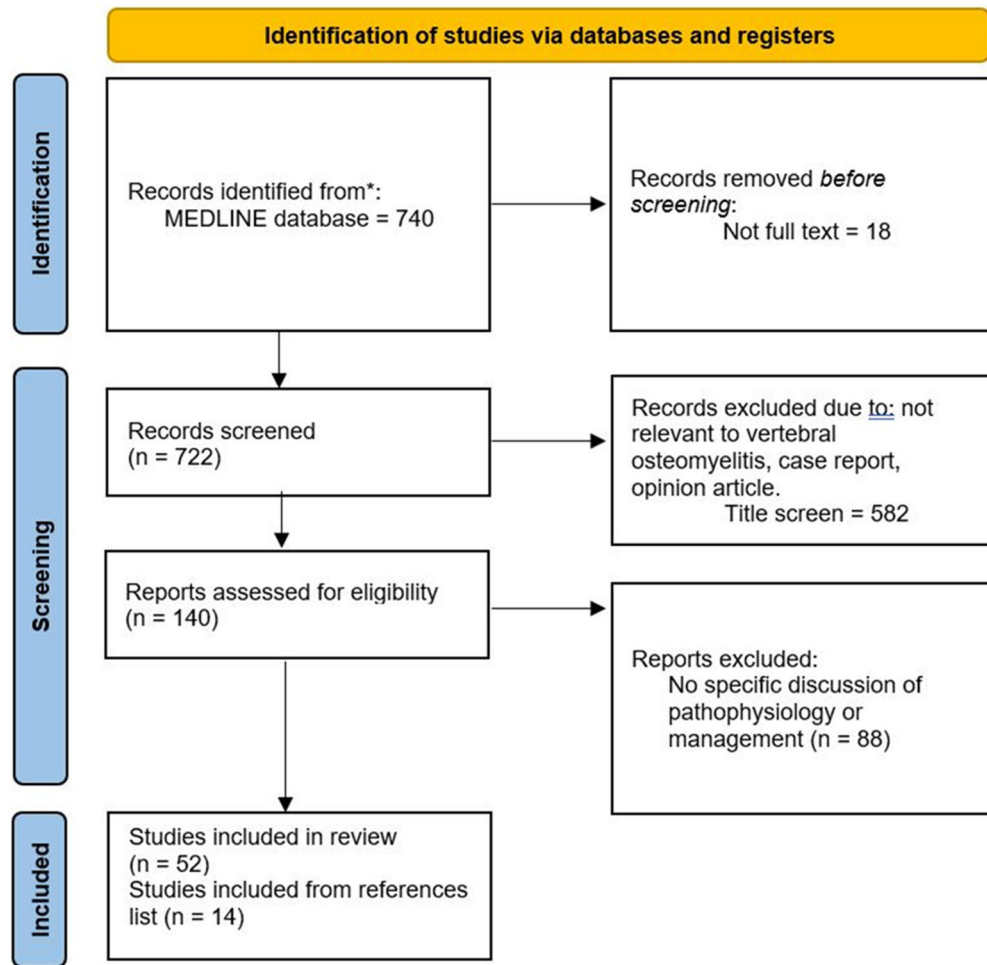
- Gouliouris T, Aliyu SH, Brown NM. Spondylodiscitis: update on diagnosis and management. *J Antimicrob Chemother.* 2010;65 Suppl 3:iii11–24. [PubMed: 20876624]
- Muller EJ, Russe OJ, Muhr G. [Osteomyelitis of the spine]. *Orthopade.* 2004;33(3):305–15. [PubMed: 15007555]
- Graeber A, Cecava ND. Vertebral Osteomyelitis. *StatPearls.* Treasure Island (FL): StatPearls Publishing; 2022.
- Zimmerli W. Clinical practice. Vertebral osteomyelitis. *N Engl J Med.* 2010;362(11):1022–9. [PubMed: 20237348]
- Schoof B, Stangenberg M, Mende KC, Thiesen DM, Ntalos D, Dreimann M. Obesity in spontaneous spondylodiscitis: a relevant risk factor for severe disease courses. *Sci Rep.* 2020;10(1):21919. [PubMed: 33318604]
- Momodu II, Savaliya V. Osteomyelitis. *StatPearls.* Treasure Island (FL): StatPearls Publishing; 2021.
- Kayani I, Syed I, Saifuddin A, Green R, MacSweeney F. Vertebral osteomyelitis without disc involvement. *Clin Radiol.* 2004;59(10):881–91. [PubMed: 15451346]
- Nickerson EK, Sinha R. Vertebral osteomyelitis in adults: an update. *Br Med Bull.* 2016;117(1):121–38. [PubMed: 26872859]
- Tay BK, Deckey J, Hu SS. Spinal infections. *J Am Acad Orthop Surg.* 2002;10(3):188–97. [PubMed: 12041940]
- Sapico FL, Montgomerie JZ. Vertebral osteomyelitis. In *fect Dis Clin North Am.* 1990;4(3):539–50.
- Moral MZ, Desai K, Arain AR, O'Leary RE, Haddad SF, Lawrence JP. Mycobacterium abscessus-associated vertebral osteomyelitis in an immunocompetent patient: a rare case report and literature review. *Spinal Cord Ser Cases.* 2019;5:53.
- Kim UJ, Bae JY, Kim SE, et al. Comparison of pyogenic postoperative and native vertebral osteomyelitis. *Spine J.* 2019;19(5):880–7. [PubMed: 30500465]
- Issa K, Pourtaheri S, Stewart T, et al. Clinical Differences Between Monomicrobial and Polymicrobial Vertebral Osteomyelitis. *Orthopedics.* 2017;40(2):e370–e3. [PubMed: 27841926]
- Sheybani F, Figueiredo AHA, Brouwer MC, van de Beek D. Vertebral osteomyelitis in bacterial meningitis patients. *Int J Infect Dis.* 2021;111:354–9. [PubMed: 34487853]
- Gasbarrini AL, Bertoldi E, Mazzetti M, et al. Clinical features, diagnostic and therapeutic approaches to haematogenous vertebral osteomyelitis. *Eur Rev Med Pharmacol Sci.* 2005;9(1):53–66. [PubMed: 15852519]
- Murray MR, Schroeder GD, Hsu WK. Granulomatous Vertebral Osteomyelitis: An Update. *J Am Acad Orthop Surg.* 2015;23(9):529–38. [PubMed: 26306806]
- Roth A, Chuard C. [Vertebral osteomyelitis in adults]. *Rev Med Suisse.* 2019;15(666):1818–22. [PubMed: 31599523]

18. Yong TY, Li JY. Proteus vertebral osteomyelitis. *Int J Rheum Dis.* 2009;12(2):155–7. [PubMed: 20374334]
19. Garcia DC, Sandoval-Sus J, Razzaq K, Young L. Vertebral osteomyelitis caused by Mycobacterium abscessus. *BMJ Case Rep.* 2013;2013:bcr2013009597.
20. Petitjean G, Fluckiger U, Scharen S, Laifer G. Vertebral osteomyelitis caused by non-tuberculous mycobacteria. *Clin Microbiol Infect.* 2004;10(11):951–3. [PubMed: 15521995]
21. Lener S, Hartmann S, Barbagallo GMV, Certo F, Thome C, Tschugg A. Management of spinal infection: a review of the literature. *Acta Neurochir (Wien).* 2018;160(3):487–96. [PubMed: 29356895]
22. Russo A, Graziano E, Carnelutti A, et al. Management of vertebral osteomyelitis over an eight-year period: The UDIPROVE (UDIne PROtocol on VERtebral osteomyelitis). *Int J Infect Dis.* 2019;89:116–21. [PubMed: 31629078]
23. Zadrán S, Pedersen PH, Eiskjaer S. Vertebral Osteomyelitis: A Mortality Analysis Comparing Surgical and Conservative Management. *Global Spine J.* 2020;10(4):456–63. [PubMed: 32435567]
24. Buzele R, Lemaignan A, Gras G, Bernard L. [Vertebral osteomyelitis: to suspect ahead any inflammatory spinal pain]. *Rev Prat.* 2016;66(8):893–8. [PubMed: 30512545]
25. Berbari EF, Kanj SS, Kowalski TJ, et al. 2015 Infectious Diseases Society of America (IDSA) Clinical Practice Guidelines for the Diagnosis and Treatment of Native Vertebral Osteomyelitis in Adults. *Clin Infect Dis.* 2015;61(6):e26–46. [PubMed: 26229122]
26. Boody BS, Tarazona DA, Vaccaro AR. Evaluation and Management of Pyogenic and Tubercular Spine Infections. *Curr Rev Musculoskelet Med.* 2018;11(4):643–52. [PubMed: 30280287]
27. O Guinn DJ, Serletis D, Kazemi N. Fungal osteomyelitis with vertebral re-ossification. *Int J Surg Case Rep.* 2016;19:1–3. [PubMed: 26692163]
28. Saeed K, Esposito S, Ascione T, et al. Hot topics on vertebral osteomyelitis from the International Society of Antimicrobial Chemotherapy. *Int J Antimicrob Agents.* 2019;54(2):125–33. [PubMed: 31202920]
29. Huang CY, Hsieh RW, Yen HT, et al. Short- versus long-course antibiotics in osteomyelitis: A systematic review and meta-analysis. *Int J Antimicrob Agents.* 2019;53(3):246–60. [PubMed: 30639627]
30. Dimar JR, Carreon LY, Glassman SD, Campbell MJ, Hartman MJ, Johnson JR. Treatment of pyogenic vertebral osteomyelitis with anterior debridement and fusion followed by delayed posterior spinal fusion. *Spine (Phila Pa 1976).* 2004;29(3):326–32. [PubMed: 14752357]
31. Valancius K, Hansen ES, Hoy K, Helmig P, Niedermann B, Bunger C. Failure modes in conservative and surgical management of infectious spondylodiscitis. *Eur Spine J.* 2013;22(8):1837–44. [PubMed: 23247861]
32. Luo W, Ou YS, Du X, Wang B. Anterior oblique retroperitoneal approach vs posterior transpedicular approach for the treatment of one- or two-level lumbar vertebral osteomyelitis: a retrospective cohort study. *Int Orthop.* 2020;44(11):2349–56. [PubMed: 32500308]
33. Dai LY, Chen WH, Jiang LS. Anterior instrumentation for the treatment of pyogenic vertebral osteomyelitis of thoracic and lumbar spine. *Eur Spine J.* 2008;17(8):1027–34. [PubMed: 18575900]
34. Guo W, Wang M, Chen G, et al. Early surgery with antibiotic medication was effective and efficient in treating pyogenic spondylodiscitis. *BMC Musculoskelet Disord.* 2021;22(1):288. [PubMed: 33736624]
35. Noureldine MHA, Pressman E, Krafft PR, Smith DA, Greenberg MS, Alikhani P. Minimally Invasive Lateral Retropleural and Retroperitoneal Approaches in Patients with Thoracic and Lumbar Osteomyelitis: Description of the Techniques and a Series of 14 Patients. *World Neurosurg.* 2020;139:e166–e181. [PubMed: 32272270]
36. Wewel JT, Uribe JS. Retropleural Thoracic Approach. *Neurosurg Clin N Am.* 2020;31(1):43–8. [PubMed: 31739928]
37. Wong AYF, Foo CH, Wong CC, Ohn KM. Experiences of early air travel with pneumothorax after anterior spinal surgery. *BMJ Case Rep.* 2021;14(8):e243771.

38. Lemaignen A, Ghout I, Dinh A, et al. Characteristics of and risk factors for severe neurological deficit in patients with pyogenic vertebral osteomyelitis: A case-control study. *Medicine (Baltimore)*. 2017;96(21):e6387. [PubMed: 28538361]
39. Zhu Y, Wu P, Luo W, Zhao ZH, Ou YS. Single-Stage Posterior Instrumentation and Unilateral Transpedicular Debridement for the Treatment of Thoracolumbar Tuberculosis: Three Years of Follow-Up. *World Neurosurg*. 2019;121:e230–e236. [PubMed: 30261383]
40. Poutoglidou F, Metaxiotis D, Saloupis P, Mpeletsiotis A. Operative Treatment of Adult Pyogenic Spondylodiscitis: A Retrospective Study of 32 Cases. *Cureus*. 2021;13(5):e14820. [PubMed: 34094774]
41. Korovessis P, Petsinis G, Koureas G, Iliopoulos P, Zacharatos S. One-stage combined surgery with mesh cages for treatment of septic spondylitis. *Clin Orthop Relat Res*. 2006;444:51–9. [PubMed: 16523127]
42. Cobb LH, McCabe EM, Priddy LB. Therapeutics and delivery vehicles for local treatment of osteomyelitis. *J Orthop Res*. 2020;38(10):2091–103. [PubMed: 32285973]
43. Changez M, Burugapalli K, Koul V, Choudhary V. The effect of composition of poly(acrylic acid)-gelatin hydrogel on gentamicin sulphate release: in vitro. *Biomaterials*. 2003;24(4):527–36. [PubMed: 12437947]
44. Peng KT, Chen CF, Chu IM, et al. Treatment of osteomyelitis with teicoplanin-encapsulated biodegradable thermosensitive hydrogel nanoparticles. *Biomaterials*. 2010;31(19):5227–36. [PubMed: 20381140]
45. Ter Boo GJ, Schmid T, Zderic I, et al. Local application of a gentamicin-loaded thermo-responsive hydrogel allows for fracture healing upon clearance of a high *Staphylococcus aureus* load in a rabbit model. *Eur Cell Mater*. 2018;35:151–64. [PubMed: 29498410]
46. Schwarz EM, McLaren AC, Sculco TP, et al. Adjuvant antibiotic-loaded bone cement: Concerns with current use and research to make it work. *J Orthop Res*. 2021;39(2):227–39. [PubMed: 31997412]
47. Inceoglu S, Botimer G, Maskiewicz VK. Novel microcomposite implant for the controlled delivery of antibiotics in the treatment of osteomyelitis following total joint replacement. *J Orthop Res*. 2021;39(2):365–75. [PubMed: 33222231]
48. Padrao T, Coelho CC, Costa P, Alegrete N, Monteiro FJ, Sousa SR. Combining local antibiotic delivery with heparinized nanohydroxyapatite/collagen bone substitute: A novel strategy for osteomyelitis treatment. *Mater Sci Eng C Mater Biol Appl*. 2021;119:111329. [PubMed: 33321574]
49. Zazo H, Colino CI, Lanao JM. Current applications of nanoparticles in infectious diseases. *J Control Release*. 2016;224:86–102. [PubMed: 26772877]
50. Lee S, Stubelius A, Hamelmann N, Tran V, Almutairi A. Inflammation-Responsive Drug-Conjugated Dextran Nanoparticles Enhance Anti-Inflammatory Drug Efficacy. *ACS Appl Mater Interfaces*. 2018;10(47):40378–87. [PubMed: 30067018]
51. Hodgson K, Morris J, Bridson T, Govan B, Rush C, Ketheesan N. Immunological mechanisms contributing to the double burden of diabetes and intracellular bacterial infections. *Immunology*. 2015;144(2):171–85. [PubMed: 25262977]
52. Saidykhan L, Abu Bakar MZ, Rukayadi Y, Kura AU, Latifah SY. Development of nanoantibiotic delivery system using cockle shell-derived aragonite nanoparticles for treatment of osteomyelitis. *Int J Nanomedicine*. 2016;11:661–73. [PubMed: 26929622]
53. Vergidis P, Rouse MS, Euba G, et al. Treatment with linezolid or vancomycin in combination with rifampin is effective in an animal model of methicillin-resistant *Staphylococcus aureus* foreign body osteomyelitis. *Antimicrob Agents Chemother*. 2011;55(3):1182–6. [PubMed: 21189340]
54. Schaad HJ, Chuard C, Vaudaux P, Waldvogel FA, Lew DP. Teicoplanin alone or combined with rifampin compared with vancomycin for prophylaxis and treatment of experimental foreign body infection by methicillin-resistant *Staphylococcus aureus*. *Antimicrob Agents Chemother*. 1994;38(8):1703–10. [PubMed: 7985998]
55. Kutter E, De Vos D, Gvasalia G, et al. Phage therapy in clinical practice: treatment of human infections. *Curr Pharm Biotechnol*. 2010;11(1):69–86. [PubMed: 20214609]

56. Furfaro LL, Payne MS, Chang BJ. Bacteriophage Therapy: Clinical Trials and Regulatory Hurdles. *Front Cell Infect Microbiol.* 2018;8:376. [PubMed: 30406049]
57. Kishor C, Mishra RR, Saraf SK, Kumar M, Srivastav AK, Nath G. Phage therapy of staphylococcal chronic osteomyelitis in experimental animal model. *Indian J Med Res.* 2016;143(1):87–94. [PubMed: 26997019]
58. Warnke PH, Springer IN, Russo PA, et al. Innate immunity in human bone. *Bone.* 2006;38(3):400–8. [PubMed: 16263346]
59. Maisetta G, Batoni G, Esin S, et al. In vitro bactericidal activity of human beta-defensin 3 against multidrug-resistant nosocomial strains. *Antimicrob Agents Chemother.* 2006;50(2):806–9. [PubMed: 16436752]
60. Zhu C, Tan HL, Cheng T, et al. Human beta-defensin 3 inhibits antibiotic-resistant *Staphylococcus* biofilm formation. *J Surg Res.* 2013;183(1):204–13. [PubMed: 23273885]
61. Zhu C, Bao NR, Chen S, Zhao JN. The mechanism of human beta-defensin 3 in MRSA-induced infection of implant drug-resistant bacteria biofilm in the mouse tibial bone marrow. *Exp Ther Med.* 2017;13(4):1347–52. [PubMed: 28413476]
62. Johnson CT, Wroe JA, Agarwal R, et al. Hydrogel delivery of lysostaphin eliminates orthopedic implant infection by *Staphylococcus aureus* and supports fracture healing. *Proc Natl Acad Sci U S A.* 2018;115(22):E4960–E4969. [PubMed: 29760099]
63. Becker SC, Roach DR, Chauhan VS, et al. Triple-acting Lytic Enzyme Treatment of Drug-Resistant and Intracellular *Staphylococcus aureus*. *Sci Rep.* 2016;6:25063. [PubMed: 27121552]
64. Haddad Kashani H, Fahimi H, Dasteh Goli Y, Moniri R. A Novel Chimeric Endolysin with Antibacterial Activity against Methicillin-Resistant *Staphylococcus aureus*. *Front Cell Infect Microbiol.* 2017;7:290. [PubMed: 28713777]
65. Narasimhaswamy N, Bairy I, Shenoy G, Bairy L. In vitro activity of recombinant lysostaphin in combination with linezolid, vancomycin and oxacillin against methicillin-resistant *Staphylococcus aureus*. *Iran J Microbiol.* 2017;9(4):208–12. [PubMed: 29238455]
66. Bastos MD, Coutinho BG, Coelho ML. Lysostaphin: A Staphylococcal Bacteriolysin with Potential Clinical Applications. *Pharmaceuticals (Basel).* 2010;3(4):1139–61. [PubMed: 27713293]





**Figure 1.**  
Flow diagram of literature search process

**Table 1**

Common causes of pyogenic vertebral osteomyelitis

Pyogenic Vertebral Osteomyelitis	
Gram Positive Bacteria	Gram Negative Bacteria
Staphylococcus aureus	Escherichia coli
Staphylococcus epidermidis	Pseudomonas aeruginosa
Streptococcus sp.	Proteus mirabilis
Enterococcus sp.	

**Table 2**

Common causes of granulomatous vertebral osteomyelitis

<b>Granulomatous Vertebral Osteomyelitis</b>	
<b>Organism</b>	<b>Endemic Locations</b>
Mycobacterium Tuberculosis	Developing Countries and “high risk” populations of the immunocompromised, homeless, and healthcare employees
<b>Atypical Causes</b>	
Brucella	Zoonotic and human transmission in the Mediterranean, Arabian peninsula, Central America, and Eastern Europe
Actinomyces	Natural Flora found in the oral, gastrointestinal, and genitourinary tracts
Nocardia	Saprophytic bacteria found in soil internationally