



OPEN ACCESS

# Microsporidial myositis, keratitis and hypercalcaemia in a cystic fibrosis lung transplant recipient

Anna Louise Watson <sup>1</sup>, Marko Matic,<sup>2</sup> Thomas Robertson,<sup>3</sup> Alexandra Gabrielle Ann Stewart <sup>4</sup>

<sup>1</sup>General Medicine & Infectious Diseases, Royal Brisbane and Women's Hospital, Brisbane, Queensland, Australia

<sup>2</sup>Nuclear Medicine, Royal Brisbane and Women's Hospital, Brisbane, Queensland, Australia

<sup>3</sup>Pathology, Royal Brisbane and Women's Hospital, Brisbane, Queensland, Australia

<sup>4</sup>Infectious Diseases, Royal Brisbane and Women's Hospital, Brisbane, Queensland, Australia

## Correspondence to

Dr Anna Louise Watson; [anna.watson2@health.qld.gov.au](mailto:anna.watson2@health.qld.gov.au)

Accepted 10 June 2022

## SUMMARY

A man in his 50s was admitted with 4 months of myalgia, headaches, hypercalcaemia and declining renal function on a background of lung transplantation for cystic fibrosis 5 years prior. MRI confirmed myositis and a muscle biopsy revealed invasive muscular microsporidial infection. Positron emission tomography(PET)/CT revealed widespread dissemination of the infection. Albendazole was commenced and after a 1 week systemic inflammatory response syndrome, the patient made a significant recovery and was discharged home. PCR testing confirmed the species as *Anncaliia algerae*, which is known to infect mosquitoes, larvae and contaminate water supplies. This case highlights the need to relentlessly pursue a diagnosis and to consider atypical pathology in immune compromised patients. A tissue sample yielded highly beneficial and unexpected results. A multispecialty approach was essential given the varied infection manifestations, which included myositis, keratitis and possible central nervous system, vocal cord, parapharyngeal and renal involvement.

## BACKGROUND

This case highlights the identification and treatment of disseminated microsporidiosis with the *Anncaliia algerae* species (previously *Brachiola algerae*). Reported cases are limited, many of which have been fatal, so we wish to document both a rare illness and successful treatment outcome.<sup>1,2</sup>

Microsporidia have been reclassified from protozoa to fungi and have emerged as an opportunistic infection first highlighted during the HIV/AIDS epidemic.<sup>3–4</sup> While it can infect immune competent hosts, it is increasingly prevalent and potentially fatal in the malignancy, autoimmune and transplant populations.<sup>5</sup> Over 1400 species exist and at least 17 are known to be human pathogens; the implicated species from this case, *A. algerae*, has been isolated in the gut of mosquitoes and larvae.<sup>6,7</sup> Human acquisition of microsporidia remains unclear, although animals are hosts and interspecies transmission via inhalation or ingestion of water contaminated with spores is likely.<sup>8</sup>

## CASE PRESENTATION

A man in his 50s was admitted to hospital with declining renal function and 4 months of generalised myalgia, weakness and bilateral hand and wrist swelling. He also reported mild dysphagia, early morning headaches, nausea and blurred vision in the left eye. He described chills, but no fevers, sweats or weight loss. Medical history included a

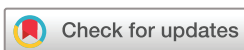bilateral sequential lung transplantation for cystic fibrosis-related bronchiectasis 5 years earlier, stage 3 chronic kidney disease (CKD) from repeated prerenal injury, post-transplant diabetes mellitus, chronic migraines and osteoporosis. Regular medications included calcitriol 0.25 µg daily, calcium carbonate 1500 mg daily, cholecalciferol 25 µg daily, furosemide 40 mg daily, lercanidipine 20 mg daily, prazosin 5 mg two times per day, methyldopa 250 mg three times a day, metoprolol 50 mg two times per day, insulin aspartate subcut eight units three times a day, insulin protaphane eight units daily, sodium chloride 600 mg daily, tacrolimus 4 mg two times per day, mycophenolate sodium 720 mg two times per day, prednisolone 7.5 mg daily, Bactrim DS ½ tab two times weekly, azithromycin 250 mg three times weekly, Aranesp weekly, denosumab 60 mg 6 monthly, Creon pro re nata and 3 monthly botulinum toxin injections. The maintenance prednisolone dose had been increased to 17.5 mg daily for several weeks to treat myalgia.

The patient resided on a rural property performing plant revegetation, which involved soil exposure, as well as digging out a self-composting toilet. He drank rainwater, which was UV filtered prior to consumption. Pets included dogs and horses. There was no recent overseas travel and no family history of malignancy or autoimmune disease.

On examination, he was afebrile, respiratory rate 20 breaths per minute, SpO<sub>2</sub> 100% on room air and hypertensive at 150/90 mm Hg. There was bilateral dorsal hand swelling, nil synovitis and muscle compartments were soft and non-tender. Muscle pain was elicited on passive stretching. There were no rashes, lymphadenopathy or hepatosplenomegaly. Signs of meningism were absent and neurological examination was unremarkable. Besides mild hypovolaemia, the remainder of the general examination was unremarkable.

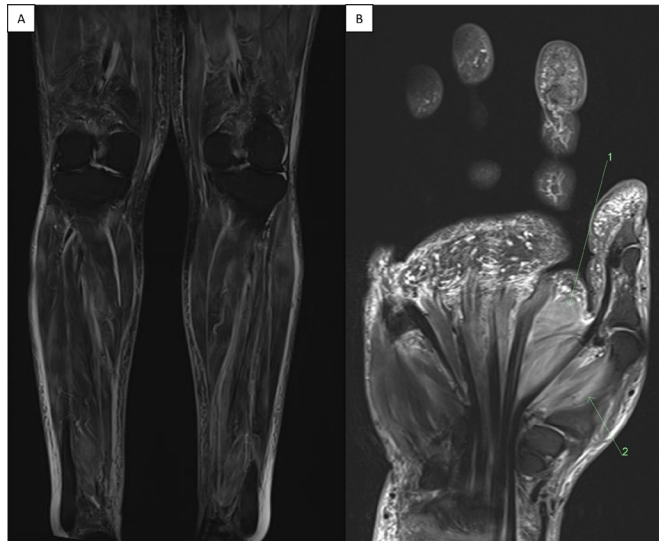## INVESTIGATIONS

Investigations revealed a creatinine of 426 µmol/L (60–110), estimated glomerular filtration rate 13 mL/min, lactate dehydrogenase 374 U/L (120–250), corrected calcium 2.95 mmol/L (2.1–2.6), parathormone (PTH) 1 pmol/L (2–9.3), haemoglobin 98 g/L (135–180), white cell count 7.7×10<sup>9</sup>/L,<sup>4–11</sup> lymphocytes 0.19×10<sup>9</sup>/L,<sup>1–4</sup> platelets 242×10<sup>9</sup>/L (140–400) and creatine kinase (CK) 578 U/L (46–171). C reactive protein was 138 mg/L (normal <5 mg/L) and erythrocyte sedimentation rate 30 mm/hour (<12 mm/hour). One



© BMJ Publishing Group Limited 2022. Re-use permitted under CC BY-NC. No commercial re-use. See rights and permissions. Published by BMJ.

**To cite:** Watson AL, Matic M, Robertson T, et al. *BMJ Case Rep* 2022;**15**:e250643. doi:10.1136/bcr-2022-250643



**Figure 1** (A) Coronal short tau inversion recovery (STIR) demonstrates heterogeneous high signal throughout the imaged lower limb musculature and subcutaneous tissue, corresponding to diffuse oedema. (B) Fat suppressed T2-weighted sequences show diffuse high signal within the intrinsic muscles of the left hand. This is most prominent in the highlighted transverse head of adductor pollicis (1) and opponens pollicis (2), which correlates to focal hypermetabolism seen on fluorodeoxyglucose (FDG) positron emission tomography (PET).

month prior, corrected calcium was 3.26 mmol/L and creatinine 290  $\mu$ mol/L.

CT scan of the head, chest, abdomen and pelvis was largely unremarkable besides chronic sinusitis.

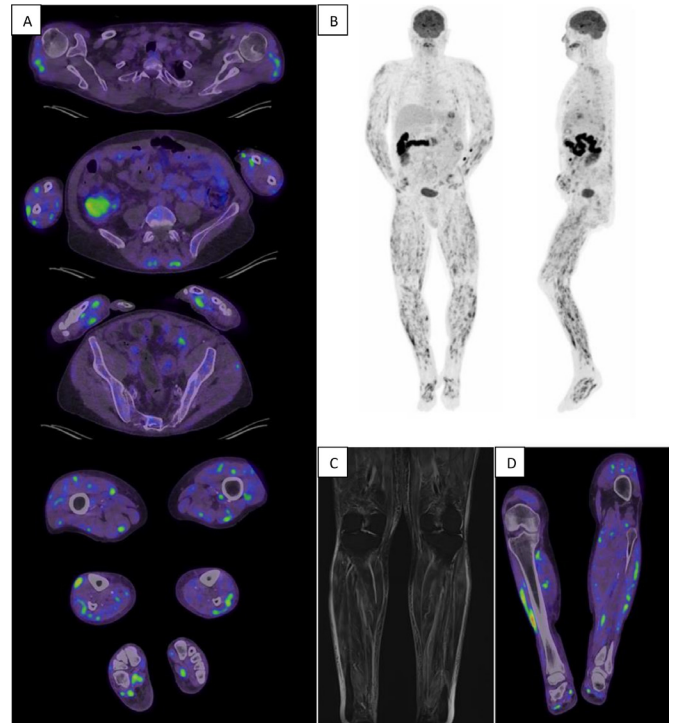
Fevers to 38.3°C developed on day 8 (D+8) and persisted for over 2 weeks. No infective process was identified despite multiple sets of blood, urine and mycobacterial cultures. Lumbar puncture (LP) had an opening pressure of 25 mm Hg with normal cerebrospinal fluid biochemistry, cell count, microscopy and negative cryptococcal antigen. Repeat 1,25-dihydroxyvitamin D off supplementation was 163 pmol/L (60–110) and parathormone 0.7 L (2–9.3) with a concurrent corrected calcium of 2.84 mmol/L.

MRI of the brain, upper and lower limbs showed non-specific scattered white matter lesions, widespread myositis in all intrinsic muscles of the left hand and extensive multifocal myositis in the lower limbs (figure 1). The vastus lateralis was identified for a muscle biopsy, which was performed on D+12.

Positron emission tomography (PET)/CT revealed innumerable fluorodeoxyglucose (FDG) avid intramuscular lesions throughout the body, most marked in limbs, having varying FDG avidity (mildly to intensely avid), with extensive subcutaneous oedema on low-dose CT (figure 2) as well as lateral oropharyngeal and vocal cord region uptake.

A renal biopsy was performed, showing acute tubular injury superimposed on a background of severe cortical atrophy and global glomerulosclerosis. Microscopy and Ziehl-Neelsen stains were negative for infection.

Muscle biopsy results returned 1 week later. Microscopy identified patchy mononuclear cell inflammation associated with foci of muscle fibre necrosis. Intracellular aggregates as well as extracellular spore-like organisms with a diameter of up to 3  $\mu$ m consistent with microsporidia were present in areas of muscle inflammation (figures 3–5). Moderate red staining on Gomori



**Figure 2** (A) Serial axial-fused fluorodeoxyglucose (FDG) positron emission tomography (PET)/CT images show innumerable foci of moderate-to-intense FDG uptake (up to an SUVmax of 9.0) within most muscle compartments in both upper and lower limbs, as well as the paraspinal muscles. These hypermetabolic intramuscular lesions represent biopsy proven microsporidial myositis. (B) Coronal and sagittal maximum intensity projection PET images demonstrate extensive multifocal FDG avidity throughout the musculature of the upper and lower limbs, with relative thoracoabdominal sparing. (C) Heterogeneous high STIR signal is seen throughout the imaged lower limb musculature and subcutaneous soft tissue on MRI, corresponding to diffuse oedema. (D) The regions of intramuscular oedema correlate to increased metabolism seen on fused FDG PET/CT imaging.

trichrome staining was evident. PCR testing identified the species as *A. algerae*.

Ocular examination elucidated bilateral white punctate epithelial infiltrates suggestive of microsporidial keratitis. Lesions were debrided and microscopy of the corneal scrapings demonstrated intracellular organisms present as multiple spores within microcysts highlighted on Grocott and Giemsa stains confirming microsporidiosis and PCR testing positive.

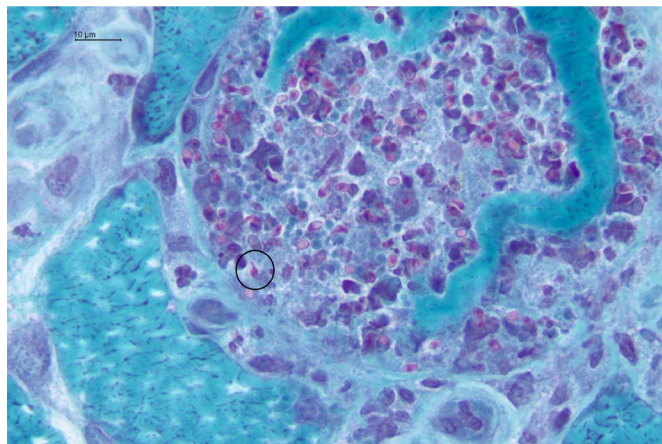
## DIFFERENTIAL DIAGNOSIS

This case remained a diagnostic dilemma with a seemingly poor prognosis despite good health and excellent quality of life several months prior. Key aspects to consider were the subacute but progressive nature of the illness and recognising the degree of immunodeficiency in the host.

Differential diagnoses for the myositis included a paraneoplastic, infective or an autoimmune process. Performing MRI and achieving a muscle biopsy with skilled histopathology review was crucial in achieving the correct diagnosis. PET/CT was performed to investigate for occult malignancy, vasculitis or granulomatous disease and was useful in clarifying the extent of infection and providing a baseline for response to treatment.

Refractory hypercalcaemia was unusual aspect of the case. Differentials for PTH-independent hypercalcaemia include





**Figure 3** Microsporidia spores bursting out of a skeletal muscle fibre. One spore has been captured with its polar tubule expelled (circle). (Gomori trichrome stain, ×1000 magnification).

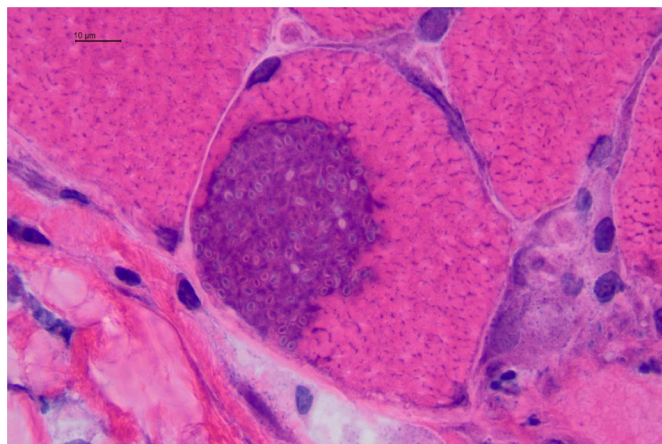
malignancy, granulomatous disease, vitamin A or D intoxication and hyperthyroidism. The elevated 1,25-hydroxyvitamin D persisting after cessation of calcitriol was suggestive of a granulomatous process, as can occur with sarcoidosis or atypical infections such as disseminated mycobacterial or fungal infection.

Renal function continued to deteriorate despite euvolaemia, appropriate calcineurin levels and the exclusion of obstruction. Microsporidial infection and refractory hypercalcaemia likely contributed to acute tubular injury and the background changes of severe cortical atrophy provided prognostic value, prompting workup for dialysis.

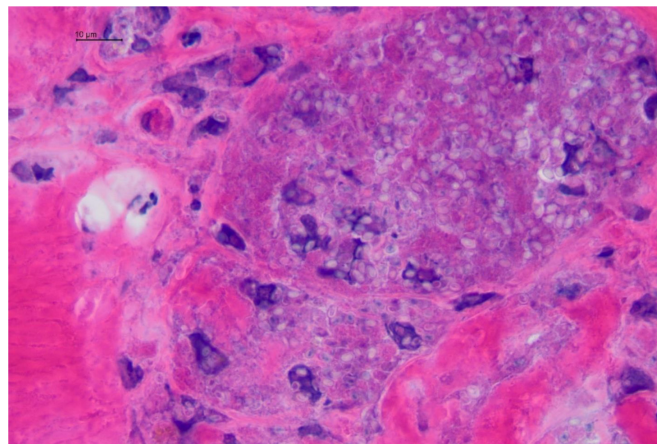
Severe early morning headaches were suggestive of raised intracranial pressure, although there was no papilloedema on funduscopy and MRI and LP excluded a space occupying lesion or meningitis. The patient suffered from chronic migraines likely exacerbated by keratitis and subsequent albendazole. Infectious keratitis can be bacterial, viral, fungal or parasitic in aetiology; however, the characteristic white punctate epithelial infiltrates seen on ocular examination are typical of microsporidia.

## TREATMENT

Initial treatment included intravenous fluid and analgesia. No antibiotics were administered given clinical stability and



**Figure 4** Intracellular proliferating microsporidia in an intact skeletal muscle fibre (centre). A necrotic fibre with some spores is seen at bottom right. (H&E, ×1000 magnification).



**Figure 5** Microsporidia among necrotic cellular debris and mononuclear inflammatory cells, mainly macrophages. (H&E, ×1000 magnification).

zoledronic acid was administered two times for hypercalcaemia without effect. Once muscle biopsy results confirmed microsporidiosis, antifungal treatment with albendazole 400 mg medication taken by mouth two times per day was commenced. Worsening fevers, rigours, myalgia, headaches and vomiting ensued for 5 days with new diarrhoea and anaemia requiring red blood cell transfusion. While the headaches were severe and potentially exacerbated by albendazole, it was continued as was the optimal antifungal agent. The keratitis was debrided and topical ofloxacin and celluvisc applied with a plan for fumagillin if infection reoccurred. Immunosuppression was reduced with prednisolone weaned to 7.5 mg daily, mycophenolate 540 mg two times per day and a reduced tacrolimus level target of five to six.

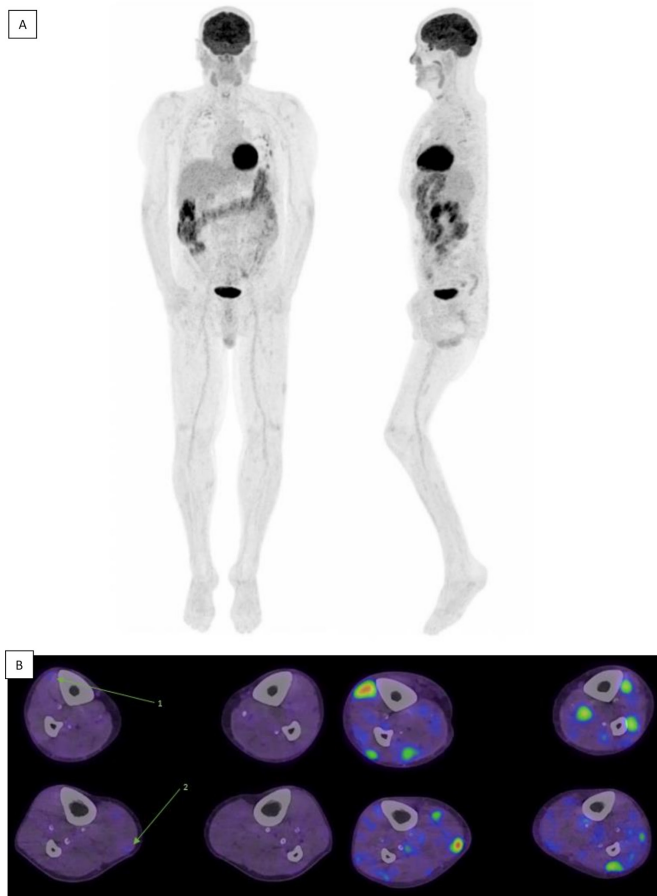
## OUTCOME AND FOLLOW-UP

Clinical improvement was seen after 7 days with defervescence, reduced subcutaneous oedema, myalgia and headaches. CK and calcium normalised and the patient was discharged home.

Significant nausea and diarrhoea prompted an endoscopy 4 weeks later; results were unremarkable and albendazole was continued with a planned duration of 6–12 months. Unless a microsporidial source can be identified and eradicated, ongoing exposure to microsporidium is likely and long-term secondary prophylaxis will be required. A repeat PET/CT scan performed 3 months into treatment showed a near complete metabolic response (figure 6). Multispecialty outpatient follow-up is arranged and planning for intermittent haemodialysis is underway given the Stage 5 CKD.

## DISCUSSION

While there are no published guidelines for the treatment of microsporidiosis, albendazole is effective against most species except *Enterocytozoon bieneusi*, for which fumagillin is an alternative. Treatment duration is not defined; however, in this case duration will be guided by clinical response, for example, resolving myalgia and keratitis, inflammatory markers and repeat PET imaging. Given severe infection generally occurs in patients infected with HIV with a CD4 < 100 cells/µL, the disseminated nature of infection reflects profound immunosuppression. In HIV with commencement of antiretroviral therapy, albendazole is recommended for a minimum of 6 months after a CD4 > 200 cells/µL is achieved.



**Figure 6** Repeat fluorodeoxyglucose (FDG) positron emission tomography (PET)/CT to assess treatment response following 90 days of albendazole therapy demonstrates a near complete metabolic response. (A) Maximum intensity projections show resolution of virtually all previously seen FDG avid intramuscular lesions. (B) Comparing post (left) and pre (right) treatment axial fused FDG PET/CT images, only several sparse foci of minimal FDG uptake remain. The most prominent residual lesions; right tibialis anterior (arrow 1) and medial gastrocnemius (arrow 2), are both less avid than mediastinal blood pool.

Reduction in immune suppression is an important factor in the successful treatment of microsporidiosis.<sup>8,9</sup> This requires a careful assessment of the risk–benefit balance in patients who require ongoing immunosuppression, such as in transplant recipients. When immune reconstitution cannot be achieved, prolonged treatment for months with a consideration for secondary prophylaxis given the risk of a chronic carrier state or reinfection is prudent.

In cases of treatment failure or relapse despite albendazole therapy, fumagillin has been added to the regimen with clinical success.<sup>9</sup> Minimising soil exposure, eradicating mosquito breeding grounds and preventing house water contamination with mosquito larvae to avoid reinfection is advised; acknowledging the exact mechanism of acquisition is still uncertain.<sup>10</sup>

To our knowledge, there are no documented case reports of hypercalcaemia associated with microsporidiosis. Granulomatous disorders associated with fungal infection can cause hypercalcaemia through excessive 1–25-hydroxyvitamin D production, which is the proposed mechanism in this case.

Given the disseminated nature of infection a multimodal approach with input from nephrology, endocrinology, lung transplant, rheumatology, infectious diseases, neurology, ear,

nose and throat and ophthalmology was required. Various species of microsporidium have a predilection for particular infective phenotypes and *A. algerae* is known to cause keratitis and myositis.<sup>11</sup> In this case, there was possible central nervous system, vocal cord, parapharyngeal and renal involvement despite the inability to identify the organism in these tissues. The pronounced systemic response with myalgia, headaches and fevers after commencement of albendazole was likely due to widespread microorganism death and lysis of infected myositis.

There are several case reports of fatal microsporidial myositis in immunocompromised hosts over the past two decades and rates are likely higher given the elusive diagnosis. Further research is required to clarify acquisition, identify high-risk patients, outline preventative measures and to raise awareness given the high mortality rates in the expanding immunocompromised population.

### Patient's perspective

I was frustrated after 3 months of worsening muscle fatigue, pain and myalgia and several different arthritis blood tests and general practitioner visits. One of my regular transplant blood tests revealed I had an acute kidney injury and dangerously high calcium levels. I was off to hospital to further investigate the problems under the renal doctors. I was most concerned about my kidneys and calcium levels at that stage and so were the doctors. We ran through all the same blood tests for arthritis and autoimmune diseases with negative results, something was wrong, and the Doctors and I knew there was a problem but what? So, the barrage of tests began, to the credit of all those involved. My kidneys and calcium levels were stubborn and did not change for 3 weeks, which was making the diagnosis difficult. Then finally, the muscle biopsy returned the answer of microsporidium infection.

By this stage, I was very sick. I was sleeping, fatigued, nauseous and in constant muscle pain. At this stage, even holding a drink was a challenge, not much fun to be around. The debridement of my left eyeball was the last straw as the fungus had infiltrated my cornea, but we had an answer, and this was a positive in myself and my wife's eyes. We made plans to get home after 1 month in hospital. Then my next challenge.

After being bedridden for a month with a parasitic whole body muscle infection, I had lost 10 kg and a lot of my strength and muscle. I was constantly nauseous and suffering continual bouts of diarrhoea. Just being able to eat has been a challenge but I am getting better and progressing every day.

I have to thank the persistence and collaborative efforts of the multidisciplinary team whom diagnosed my problem. This could have definitely been a different story if my symptoms were left unchecked or to a less experienced health system.

**Acknowledgements** The authors would like to acknowledge the following for their contribution to patient care: The Royal Brisbane & Women's Hospital Nephrology, Rheumatology, Endocrinology, Infectious Diseases, Neurology, Ear, Nose and Throat and Ophthalmology Units, The Prince Charles Hospital Lung Transplant Unit and Dr Matthew R. Watts for his expertise on microsporidiosis.

**Contributors** ALW: providing patient care and writing of the manuscript. MM: providing radiology images and captions. TR: reviewing histopathology of muscle biopsies, and provided images with captions, reviewing and editing the manuscript. AGAS: providing patient care, oversight to case report planning, reviewing and editing the manuscript.

**Funding** The authors have not declared a specific grant for this research from any funding agency in the public, commercial or not-for-profit sectors.

**Competing interests** None declared.

## Learning points

- ▶ Microsporidiosis is an emerging infectious disease in the malignancy, autoimmune and transplant population.
- ▶ Infection can be fatal without prompt diagnosis and treatment.
- ▶ Disseminated infection can present with a broad range of manifestations.
- ▶ Hypercalcaemia can be a due to disseminated fungal infection.
- ▶ Tissue samples can provide highly beneficial and unexpected results.

**Patient consent for publication** Consent obtained directly from patient(s)

**Provenance and peer review** Not commissioned; externally peer reviewed.

**Open access** This is an open access article distributed in accordance with the Creative Commons Attribution Non Commercial (CC BY-NC 4.0) license, which permits others to distribute, remix, adapt, build upon this work non-commercially, and license their derivative works on different terms, provided the original work is properly cited and the use is non-commercial. See: <http://creativecommons.org/licenses/by-nc/4.0/>.

Case reports provide a valuable learning resource for the scientific community and can indicate areas of interest for future research. They should not be used in isolation to guide treatment choices or public health policy.

**ORCID iDs**

Anna Louise Watson <http://orcid.org/0000-0003-0138-5224>

Alexandra Gabrielle Ann Stewart <http://orcid.org/0000-0002-3266-3250>

**REFERENCES**

- 1 Watts MR, Chan RCF, Cheong EYL, *et al.* *Anncaliia algerae* Microsporidial Myositis. *Emerg Infect Dis* 2014;20:185–91.
- 2 Coyle CM, Weiss LM, Rhodes LV, *et al.* Fatal myositis due to the microsporidian *Brachiola algerae*, a mosquito pathogen. *N Engl J Med* 2004;351:42–7.
- 3 Corradi N, Keeling PJ. Microsporidia: a journey through radical taxonomical revisions. *Fungal Biol Rev* 2009;23:1–8.
- 4 Desportes I, Le Charpentier Y, Galian A, *et al.* Occurrence of a new microsporidan: Enterocytozoon bienewisi n.g., N. sp., in the enterocytes of a human patient with AIDS. *J Protozool* 1985;32:250–4.
- 5 Didier ES, Weiss LM. Microsporidiosis: current status. *Curr Opin Infect Dis* 2006;19:485–92.
- 6 Fayer R, Santin-Duran M. Epidemiology of microsporidia in human infections. In: Weiss LM, Becnel JJ, eds. *Microsporidia: pathogens of opportunity*. New York: Academic, 2014. : 135–64p.
- 7 Vavra J, Undeen AH, sp Nalgeraen. *Nosema algerae* n. sp. (Cnidospora, Microsporida) a pathogen in a laboratory colony of *Anopheles stephensi* Liston (Diptera, Culicidae). *J Protozool* 1970;17:240–9.
- 8 Watts MR, Chan RCF, Cheong EYL, *et al.* *Anncaliia algerae* microsporidial myositis. *Emerg Infect Dis* 2014;20:185–91.
- 9 Boileau M, Ferreira J, Ahmad I, *et al.* Successful Treatment of Disseminated *Anncaliia algerae* Microsporidial Infection With Combination Fumagillin and Albendazole. *Open Forum Infect Dis* 2016;3:ofw158.
- 10 US Centers for Disease Control and Prevention. Rainwater collection. Available: <https://www.cdc.gov/healthywater/drinking/private/rainwater-collection.html> [Accessed 6 Apr 2022].
- 11 Han B, Weiss LM. Microsporidia: obligate intracellular pathogens within the fungal Kingdom. *Microbiol Spectr* 2017;5.

Copyright 2022 BMJ Publishing Group. All rights reserved. For permission to reuse any of this content visit <https://www.bmj.com/company/products-services/rights-and-licensing/permissions/>  
BMJ Case Report Fellows may re-use this article for personal use and teaching without any further permission.

Become a Fellow of BMJ Case Reports today and you can:

- ▶ Submit as many cases as you like
- ▶ Enjoy fast sympathetic peer review and rapid publication of accepted articles
- ▶ Access all the published articles
- ▶ Re-use any of the published material for personal use and teaching without further permission

**Customer Service**

If you have any further queries about your subscription, please contact our customer services team on +44 (0) 207111 1105 or via email at [support@bmj.com](mailto:support@bmj.com).

Visit [casereports.bmj.com](http://casereports.bmj.com) for more articles like this and to become a Fellow