

# Tenosynovitis of a digit due to *Erysipelothrix rhusiopathiae*: case report and review of the literature

K. Tolis<sup>1</sup>, S. Spyridonos<sup>1</sup>, S. Tsiplakou<sup>2</sup> and E. Fandridis<sup>1</sup>

1) Hand Surgery, Upper Limb and Microsurgery Department and 2) Microbiology Department, General Hospital KAT, Kifissia, Greece

## Abstract

*Erysipelothrix rhusiopathiae* is a Gram-positive bacterium that in humans causes skin infections, such as erysipeloid, as a result of direct contact with contaminated animals or their waste or products. We present the first reported case of tenosynovitis of a finger in a 30-year-old woman. New Microbes and New Infections © 2015 The Authors. Published by Elsevier Ltd on behalf of European Society of Clinical Microbiology and Infectious Diseases.

**Keywords:** Animal infection, erysipeloid, gram positive, hand infection, sheath decompression

**Original Submission:** 1 March 2015; **Revised Submission:** 3 October 2015; **Accepted:** 7 October 2015

**Article published online:** 20 October 2015

**Corresponding author:** K. Tolis, Hand Surgery, Upper Limb and Microsurgery Department, General Hospital KAT, Epidamnou 53-55, Athens 11254, Greece  
E-mail: [dctolis@gmail.com](mailto:dctolis@gmail.com)

## Introduction

*Erysipelothrix rhusiopathiae* is a Gram-positive bacterium that is mainly responsible for skin infection, mostly erysipeloid, in humans. The infection derives from direct contact with infected animals, usually domestic swine, and their products or wastes. We report a rare case of a 30-year-old woman with tenosynovitis of her right middle finger.

## Case presentation

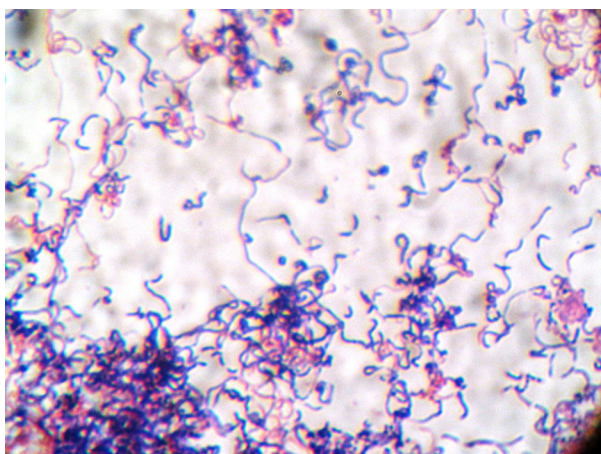
A 30-year-old Nigerian woman was admitted to our department with a medical history of swollen and painful middle finger of her right hand, which had progressively worsened over the last 3 days. No fever other constitutional symptoms were detected. She reported a recent penetrating trauma by a fish bone. No systemic diseases were documented.

Physical examination revealed edema, pain at rest, warmth and a reddish middle finger with extension to the volar and

dorsal area of her hand. Skin decolourisation was not diagnostic for erysipeloid at that time. Although the range of motion of the interphalangeal and metacarpophalangeal joints was completely restricted, no vascular impairment was documented. Her peripheral white blood cell count was 13 300/μL (71% neutrophils, 17.8% lymphocytes, 10.1% monocytes), and C-reactive protein was 0.33 mg/dL (normal range, 0.5–0.7 mg/dL). All other blood tests had results within normal ranges. The diagnosis was tenosynovitis of both the flexor and extensor mechanisms of the middle digit. Surgical decompression and debridement comprised the treatment of choice.

Under brachial block, a straight incision was performed dorsally, while a Bruner incision was preferred for the palmar area. During dissection, a serous fluid, but no pus, was collected and sent for culture. Copious irrigation with saline and hydrogen peroxide was performed during surgical exploration. Empirical intravenous antibiotic therapy was initiated immediately after surgery, including cefuroxime (750 mg/8 hours), ciprofloxacin (500 mg/12 hours) and clindamycin (600 mg/8 hours).

Fluid culture revealed *Enterococcus faecalis* in the first 24 hours, while a Gram-positive bacterium grew after 48 hours (Fig. 1), which proved to be *Erysipelothrix rhusiopathiae*. The pathogen was sensitive to penicillin, ampicillin, imipenem, cefuroxime, ceftriaxone, clindamycin and linezolid, while being resistant to vancomycin, teicoplanin, trimethoprim–sulfamethoxazole and tetracycline. The patient continued antibiotic



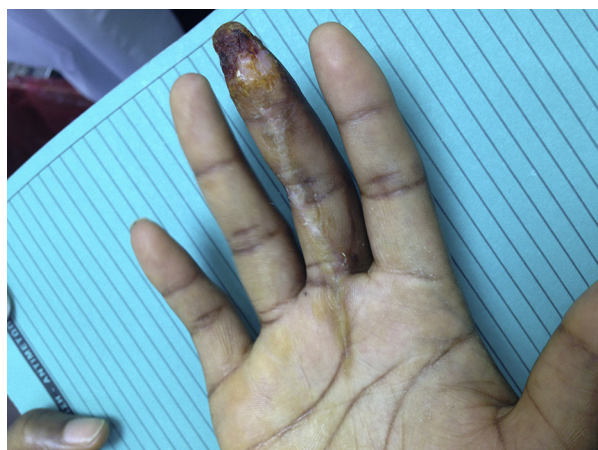**FIG. 1.** Gram's stain, high power showing gram-positive filaments typical of *Erysipelothrix rhusiopathiae*.

therapy for 2 weeks, followed by 2 weeks of oral antibiotics after being discharged from hospital.

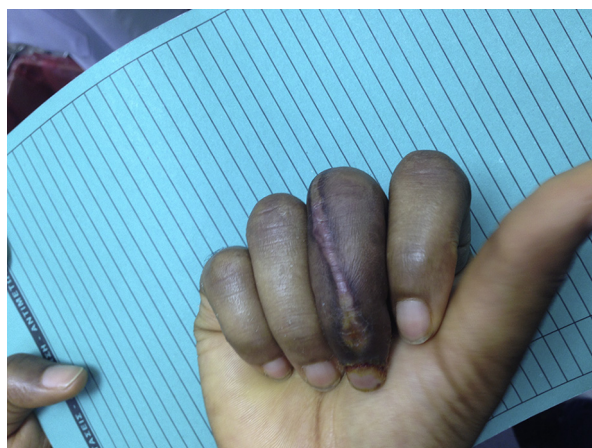
Within the 3 months' follow-up, the inflammation markers were within the normal range, and the patient regained mobility in her digit after an intensive physiotherapy programme (Figs. 2 and 3). No signs of recurrence of the disease or of osteomyelitis were detected during follow-up.

## Discussion

*Erysipelothrix rhusiopathiae* was first isolated in 1876 by Koch [1] in a mouse. Not until 1884 did Rosenbach establish it as a human pathogen. It is considered to be a Gram-positive,



**FIG. 2.** Palmar view of middle finger. No signs of infection are observed. Superficial pulp skin necrosis and slight stiffness of proximal interphalangeal joint can be seen.



**FIG. 3.** Dorsal view of middle finger. Flexion was restored to near-normal function 3 months after surgery.

capsulated saprophyte, with worldwide spread and affecting mostly domestic and wild animals. *Erysipelothrix* [2] is referred to as an occupational bacteria because its contact with infected animals or their waste causes a variety of clinical syndromes. Sheep, chickens, rodents, shellfish, turkeys and ducks are usual hosts, but domestic swine is the dominant reservoir for the microorganism. It is not only professional workers [3], such as fishermen, farmers or butchers, who are considered to be at high risk when in close contact with infected animals. Infection can also be accidental [4], the result of its ability to remain viable in water and animal products, such as ham, or in fish for a long period without forming spores [5]. Human-to-human infection has not been reported.

Erysipeloid is the most common form of infection in humans. It is a mild, cutaneous infection, lasting between 2 and 4 weeks and usually self-limiting. Lesions are confined to fingers and hands, which are being swollen and painful, with spreading at the periphery and decolourization of the central area [6]. Systemic effects are rare, although lymphadenopathy and lymphangitis are detected in one third of patients [7]. Adjacent arthritis may occur. The diffuse cutaneous form is even rarer, combined with systemic symptoms such as fever, severe headache and even polyarthritis. Recurrence is more often compared to erysipeloid. The most severe form of infection, though the rarest, due to *Erysipelothrix* is septicæmia, which is almost always related to endocarditis. The aortic valve [8] is mostly affected, with 35% of patients requiring replacement. Mortality is up to 40%, regardless of antibiotic treatment. Risk factors for bacteraemia include diabetes, immunosuppression, alcoholism [9] or renal failure as well as infancy.

Although rarely mentioned in the orthopaedic literature, reports from the last decade show that *Erysipelothrix*

*rhusiopathiae* is considered to be a causative bacteria for reactive arthritis [10], osteomyelitis [10], prosthetic infection [11] and spondylitis [12]. It has also caused septic arthritis after arthroscopic reconstruction of an anterior cruciate ligament [13]. Therefore, tenosynovitis is a rare form of erysipeloid.

Although it is a known occupational pathogen, its infections are often misdiagnosed. In cases of erysipeloid, biopsy samples should be taken of the entire thickness of the dermis, as the bacterium lies in the deeper layers of the skin. When sepsis or endocarditis is diagnosed, a standard blood culture should be performed. Specimens must be put in an infusion broth of 1% glucose at room temperature until reaching the laboratory. Identification should be based on Gram stain, morphology, motility, and hemolytic and biochemical properties, especially production of H<sub>2</sub>S [2]. Generally *Erysipelothrix* should not be confused with *Actinomyces*, *Lactobacillus*, *Streptococcus*, *Listeria monocytogenes* or *Enterococcus* spp.

Penicillin, cephalosporins, fluoroquinolones and lincosamides are the main antibiotic categories used for treatment against infections due to *Erysipelothrix*. The bacterium is highly resistant to aminoglycosides [2], vancomycin, sulfonamides, streptomycin and trimethoprim–sulfamethoxazole. Resistance to vancomycin is endogenous as a result of the *vanC* gene. Susceptibility varies amongst chloramphenicol, tetracyclines and erythromycin. Penicillin G [14] is considered the drug of choice, in doses varying from 12 × 10<sup>6</sup> to 20 × 10<sup>6</sup> U/day. Duration of treatment period depends on whether or not the infection is systemic. In cases of bacteraemia or endocarditis, 4 to 6 weeks of continuous antibiotic therapy is considered an effective treatment period. In complicated cases [15] or in cases of immediate recurrence of the disease, antibiotics can be administered for up to 16 weeks.

Orthopaedic surgeons should be aware of infections due to *Erysipelothrix rhusiopathiae*, bearing in mind the close correlation between certain professions and animals, domestic or wild. Systemic or not, such infections must be identified immediately in order to prevent severe complications such as endocarditis. Prophylactic measures can reduce occupational exposure and minimize the possible transmission of the pathogen to humans.

## Conflict of interest

None declared.

## References

- [1] Wood RL. *Erysipelothrix* infection. In: Hubbert WT, McCulloch WF, Schnurrenberger PR, editors. *Diseases transmitted from animals to man*. 6th ed. Springfield, IL: Thomas; 1975. p. 271–81.
- [2] Brooke CJ, Riley TV. *Erysipelothrix rhusiopathiae*: bacteriology, epidemiology and clinical manifestations of an occupational pathogen. *J Med Microbiol* 1999;48:789–99.
- [3] Reboli AC, Farrar WE. *Erysipelothrix rhusiopathiae*: an occupational pathogen. *Clin Microbiol Rev* 1989;2:354–9.
- [4] Jones N, Khoosal M. *Erysipelothrix rhusiopathiae*: septicemia in a neonate. *Clin Infect Dis* 1997;24:511.
- [5] Wood RL. Erysipeloid. In: Leman AD, Straw BE, Mengeling WL, D’Allaire S, Taylor DJ, editors. *Diseases of swine*. 7th ed. Ames: Iowa State University Press; 1992. p. 475–86.
- [6] King PF. Erysipeloid. Survey of 115 cases. *Lancet* 1946;2:196–8.
- [7] Nelson E. 500 cases of erysipeloid. *Rocky Mountain Med J* 1955;52:40–2.
- [8] Hill DC, Ghassemian JN. *Erysipelothrix rhusiopathiae* endocarditis: clinical features of an occupational disease. *South Med J* 1997;90:1147–8.
- [9] Campbell MD, Cowan M. Case report: septicemia and aortic valve endocarditis due to *Erysipelothrix rhusiopathiae* in a homeless man. *Case Rep Infect Dis* 2013;2013:923034.
- [10] Mukhopadhyay C, Shah H, Vandana KE, Munim F, Vijayan S. A child with *Erysipelothrix* arthritis—beware of the little known. *Asian Pac J Trop Biomed* 2012;2:503–4.
- [11] Hocqueloux L, Poisson DM, Sunder S, Guilbert S, Pruzuck T. Septic arthritis caused by *Erysipelothrix rhusiopathiae* in a prosthetic knee joint. *J Clin Microbiol* 2010;48:333–5.
- [12] Andrychowski J, Jasielski P, Netczuk T, Czernicki Z. Epyema in spinal canal in thoracic region, abscesses in paravertebral space, spondylitis: in clinical course of zoonosis *Erysipelothrix rhusiopathiae*. *Eur Spine J* 2012;21(Suppl. 4):S557–63.
- [13] Vallianatos PG, Tilentzoglou AC, Koutsoukou AD. Septic arthritis caused by *Erysipelothrix rhusiopathiae* infection after arthroscopically assisted anterior cruciate ligament reconstruction. *Arthroscopy* 2003;19:26.
- [14] Poretz DM. *Erysipelothrix rhusiopathiae*. In: Mandell GL, Douglas Jr RG, Bennett JE, editors. *Principles and practice of infectious diseases*. 2nd ed. New York: J. Wiley & Sons; 1985. p. 1185–6.
- [15] Hjetland R, Søggen E, Våge V. *Erysipelothrix rhusiopathiae*: a cause of erysipeloid and endocarditis. *Tidsskr Nor Laegeforen* 1995;115:2780–2.