

Ameloblastic Fibro-Odontoma: A Journey of Progression?

Karpagaselvi Sanjai, Lokesh Papiiah Reddy, Keshavaiah Roopavathi, Harish Kumar Muniswamy

Department of Oral Pathology, Vydehi Institute of Dental Sciences and Research Centre, Bengaluru, Karnataka, India

Abstract

A 19-year-old male patient reported to dental OPD of our institution with a swelling in the posterior part of the mandible on the left side. The patient gave a history of gradual increase in the size of swelling for 7 years. The patient also had a radiograph and histopathology slides from his previous dental visit at another facility. The radiograph revealed a well-circumscribed radiolucency with an impacted tooth (38). Histopathology slides showed features of an ameloblastic fibroma (AF). The patient had deferred the treatment for 5 years since he was young and reported to our OPD due to increase in the size of the swelling over the past few weeks. The present radiographs revealed radiolucency with radiopacity. Excisional biopsy was performed and the histopathological examination revealed an Ameloblastic fibro odontoma. This case report is to document and highlight the possible progression of AF to Ameloblastic fibro-odontoma.

Keywords: Ameloblastic fibro-dentinoma, ameloblastic fibroma, ameloblastic fibro-odontoma and complex odontoma

Address for correspondence: Dr. Karpagaselvi Sanjai, Department of Oral Pathology, Vydehi Institute of Dental Sciences and Research Centre, Bengaluru, Karnataka, India.

E-mail: selvisanjai@gmail.com

Submitted: 11-Jun-2021, **Revised:** 19-Oct-2021, **Accepted:** 29-Oct-2021, **Published:** 28-Feb-2022

INTRODUCTION

Ameloblastic fibroma (AF) and Ameloblastic fibro-odontoma (AFO) are described as benign mixed odontogenic tumors of epithelial and mesenchymal origin. AF was first described by Kruse in 1891, whereas AFO was first described by Hooker in 1967 as Ameloblastic odontoma.^[1] WHO classification (1971) suggested that the term Ameloblastic odontoma was inappropriate. They put forth the term “Ameloblastic fibro-odontoma” for noninvasive odontogenic tumors showing features of both AF and complex odontoma, histopathologically. It was classified under mixed odontogenic tumors along with AF and ameloblastic fibro-dentinoma (AFD), in 1992 WHO classification.^[1,2]

WHO (2005) classification defined AF and AFO as benign neoplasms composed of proliferating odontogenic epithelium in a cellular ectomesenchymal tissue (AF) with later having varying degree of inductive changes and dental hard tissue enamel and dentin formation (as in a complex odontoma).^[3]

AF and AFO have been described as asymptomatic slow-growing tumors of the jaw in children. While AF is more likely to occur in the first two decades of life, AFO occurs in the age range of 8–12 years with slight male predilection. Radiographically, both occur as unilocular or multilocular radiolucency, though AFO shows varying degree of radiopacities.^[3,4]

This is an open access journal, and articles are distributed under the terms of the Creative Commons Attribution-NonCommercial-ShareAlike 4.0 License, which allows others to remix, tweak, and build upon the work non-commercially, as long as appropriate credit is given and the new creations are licensed under the identical terms.

For reprints contact: WKHLRPMedknow_reprints@wolterskluwer.com

How to cite this article: Sanjai K, Reddy LP, Roopavathi K, Muniswamy HK. Ameloblastic fibro-odontoma: A journey of progression? J Oral Maxillofac Pathol 2022;26:S40-5.

Access this article online

Quick Response Code:



Website:

www.jomfp.in

DOI:

10.4103/jomfp.jomfp_184_21

According to the literature, there is a dispute whether the mixed odontogenic tumors AF, ameloblastic odontoma and complex odontoma are either separate neoplastic entities or a hamartoma, representing different stages of development of the single entity, that is maturation of AF to complex odontoma over a period of time.^[4-7]

Here, we document a case, which for 6 years progressed from AF to AFO with brief discussion on histopathogenesis.

CASE REPORT

A 19-year-old male patient reported to our dental OPD in January 2020 with a chief complaint of swelling and pain involving the posterior part of the left mandible for 6 years with occasional discharge extra orally.

On elaborating the history, the swelling was first noticed about 6 years ago, initially as small and painless mass, which gradually progressed. In October 2015, the patient had visited a dental hospital in Kolkata. After the investigations and radiography, incisional biopsy was performed. Permanent mandibular right first and second molar were also removed. The patient was suggested to undergo further investigations and excisional biopsy. However, the same was deferred by the patient/his guardians as the swelling was small and the patient was young at that time. The patient was asymptomatic except for the gradual increase in the size of the swelling. In the last 2 years, the patient started experiencing occasional pain and discharge through an extraoral sinus opening on the left side of the face.

On general clinical examination, the patient was conscious, well oriented with vital signs within the normal limits. On extraoral examination, a diffuse swelling was seen in relation to the left middle and lower 1/3rd of the face, which was firm in consistency, measuring 6 cm × 5.9 cm extra orally [Figure 1]. Lateral to the corner of the mouth, 1 cm lower, the skin over the swelling showed a scar. Intraoral inspection revealed an ulceroproliferative growth measuring 6.5 cm × 4.8 cm × 4.4 cm. The lesion extended from the distal aspect of 35 till the anterior faucial pillar, obliterating the buccal vestibule and displacing the tongue toward the right side of the oral cavity [Figure 2]. The swelling was firm, tender and erythematous with Grayish black pigmented areas. The premolars adjoining the swelling were grade III mobile.

The previous orthopantomogram (OPG) revealed an unilocular radiolucent lesion involving the posterior part of the left mandible with an impacted 38 [Figure 3].

The patient was subjected to OPG and contrast-enhanced computed tomography (CECT) of the head and neck. The present OPG showed an ill-defined radiolucent area with radiopaque flecks, with impacted 38 near the lower border of the mandible [Figure 4]. The CECT showed well defined, multilocular, expansile, solid and partly cystic lesion with multiple calcifications around unerupted 38 [Figures 5 and 6]. Provisional diagnosis of ameloblastic fibrodentinoma/odontoma was reached.

Incisional biopsy slides from the year 2015 were reviewed. The hemotoxylin and eosin (H and E) stained section of the specimen revealed the presence of odontogenic epithelial cells in the form of strands, cords and follicles resembling developing enamel organs. The connective tissue was fibro-myxomatous resembling dental papilla-like tissue [Figure 7]. These findings were suggestive of AF.

On intraoperative examination, the surgeon felt that tumor mass was adherent to the submandibular salivary gland and lymph node. Hence, the patient was subjected to hemi-mandibulectomy along with level Ia and Ib clearance. The entire specimen was fixed in 10% formal saline, processed and sectioned for further microscopic examination.

The H and E section showed strands cords and follicle of odontogenic epithelial cells, some of the follicles showed peripheral tall columnar cells with central stellate reticulum-like cells [Figure 8]. The connective tissue was delicate and composed of thin collagen fibers and stellate-shaped fibroblasts. Some of the areas resembled dental papilla-like tissue [Figure 9]. Areas of basophilic amyloid-like matrix [Figure 10] were seen along with areas of dentinoid [Figures 11 and 12]. The center of the lesion showed plenty of dentine/dentinoid-like area [Figure 13]. The submandibular gland and lymph node did not show any pathology. Based on these features, final diagnosis of AFO was made.

DISCUSSION

Benign mixed odontogenic tumors include AF, AFD, AFO and the two odontomas (complex and compound).^[2] While AF shows odontogenic islands in an ectomesenchymal connective tissue, all others show, in addition, dental hard tissue like enamel or dentin in various stages of differentiation and maturation.^[1,3]

The “continuum concept” proposed by Cahn and Blum explains that AF matures over a period of time into AFO/

AFD and finally results into the formation of a complex odontoma, a hamartoma.^[6] According to this concept,

the AF should occur at younger age followed by AFO or AFD in slightly older children and finally with odontomas occurring in late childhood. However, the clinical data of these odontogenic tumors do not support this concept, as they do not occur in the same order. Furthermore, cases of

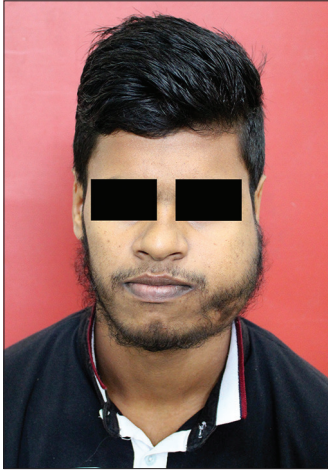

Figure 1: Clinical image shows swelling in relation to left middle and lower 1/3rd of the face

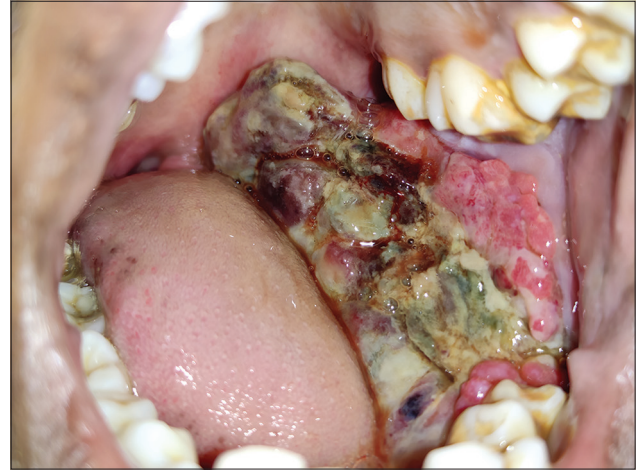

Figure 2: Clinical image shows intraoral ulceroproliferative growth extending from distal aspect of 35 till left retromolar region, obliterating buccal vestibule

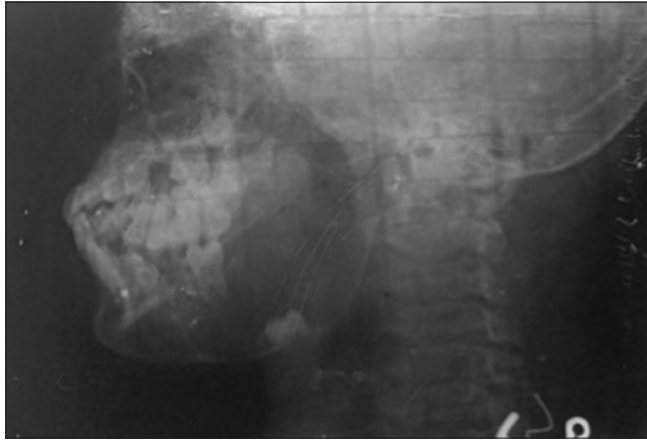


Figure 3: Orthopantomogram(OPG) taken in year 2015 reveals radiolucent lesion involving the posterior part of the left mandible with impacted 38

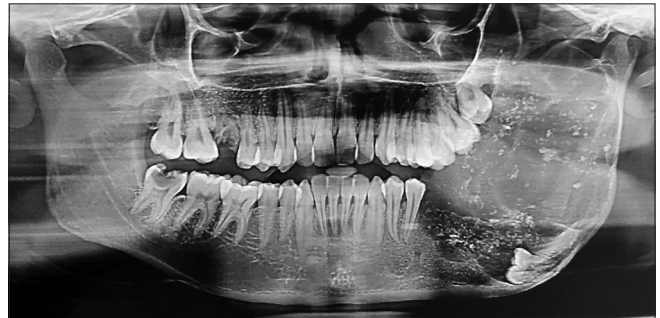

Figure 4: Orthopantomogram(OPG) taken in 2020 shows an ill-defined multilocular radiolucent area with radiopaque flecks, with impacted 38 near the lower border of the mandible

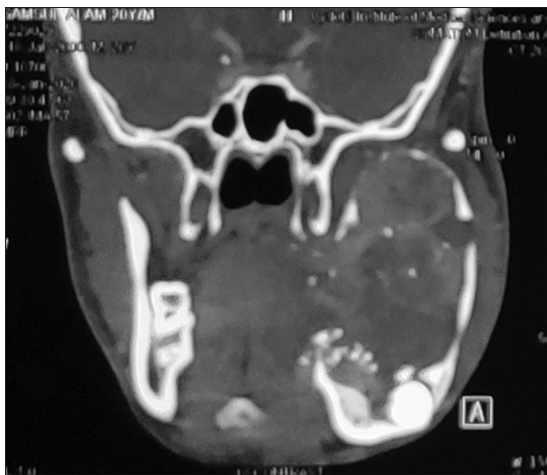


Figure 5: The Contrast-Enhanced Computed Tomography (CECT) showed well defined, multilocular,expansile solid and partly cystic lesion with multiple calcifications around unerupted 38

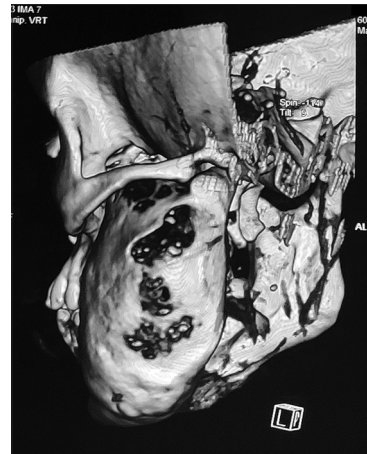

Figure 6: The Contrast-Enhanced Computed Tomography shows 3D Reconstructive image of involved area

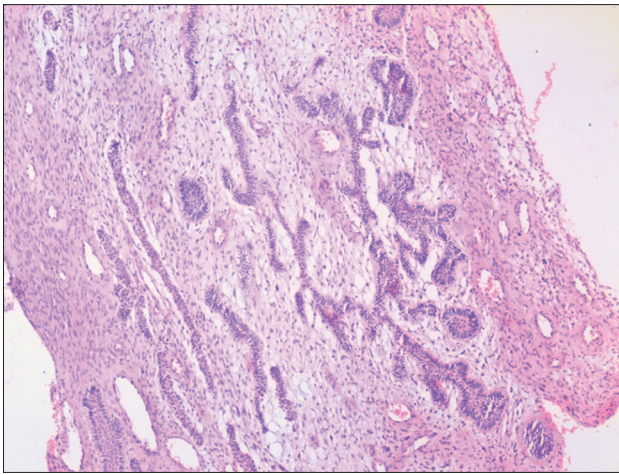


Figure 7: Histopathological image of the specimen taken in year 2015 reveals presence of odontogenic epithelial cells in cords and strands in primitive ectomesenchyme like areas.(H&E stain, x100)

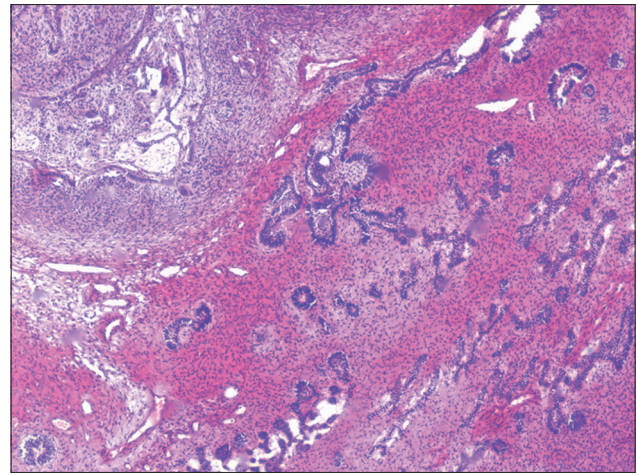


Figure 8: Histopathological image of the excisional biopsy specimen shows strands, cords and follicle of odontogenic epithelial cells in ectomesenchyme like areas. (H&E, stain, x50)

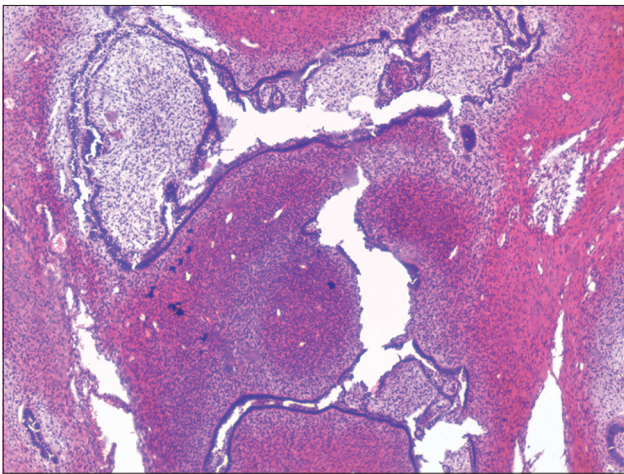


Figure 9: Histopathological image of the excisional biopsy specimen shows strands, cords of odontogenic epithelial cells in dental papilla like areas. (H&E, stain, x50)

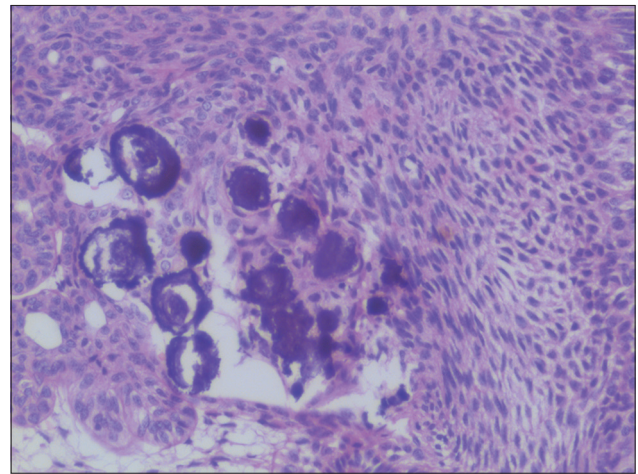


Figure 10: Histopathological image of the excisional biopsy specimen shows basophilic enameloid like matrix. (H&E, stain, x200)

residual or recurrent AF do not differentiate or mature into advanced odontogenic tumors with histodifferentiation like AFO/AFD.^[5,7]

While there is ongoing debate whether mixed odontogenic lesions are interrelated, majority of authors accept that AFOs and odontomas go through mineralization and calcification without occurring as *de novo*.^[2,5,8] Hence, common idea propagated is both AF and AFO can be part of developing odontome.

Trodahl was first to describe two lesions which have histopathological features similar to AF, one as the early noncalcified, developing stage of odontoma and the other as actual neoplastic lesion AF.^[9] This was supported by Hansen and Ficcaro, who hypothesized that some of AF might represent the early stage of

developing odontomas.^[10] Similarly, Gardner described two types of AFO, one which is a developing complex odontoma (DCO), a hamartoma which will have similar histopathological features to the neoplastic type of AFO.^[11]

Slootweg on basis of his review of cases, however, described AF as a neoplasm and AFO, an immature complex odontoma (part of developing odontome), hence a hamartoma.^[5]

According to Philipsen *et al.*, mixed odontogenic tumors are either neoplastic or hamartomatous DCO. They consider AF and AFD as neoplasm, as there exist no proof that AF or AFD progresses. However they too, do not consider AFO as a tumor, but rather as a stage preceding the complex odontoma of the DCO.^[8]

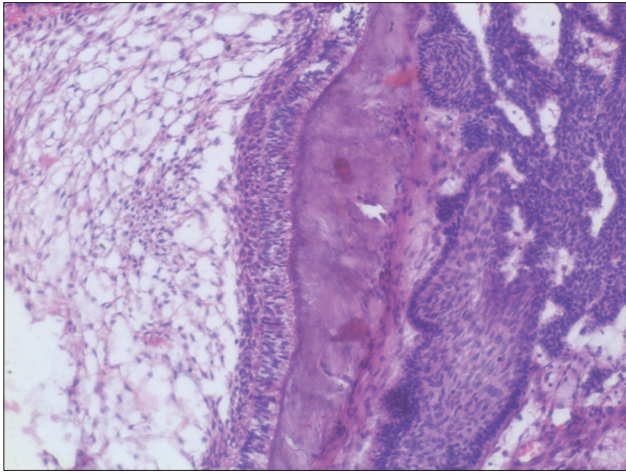


Figure 11: Histopathological image of the excisional biopsy specimen shows plenty of dentine/dentinoid. (H&E, stain, x200)

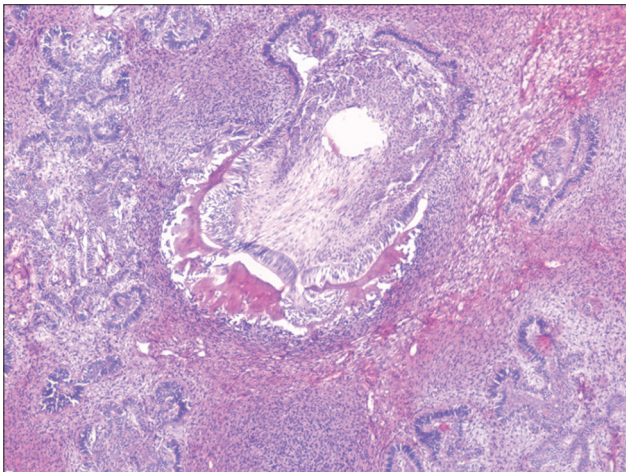


Figure 12: Histopathological image of the excisional biopsy specimen shows plenty of dentine/dentinoid like area surrounded by odontogenic cells. (H&E, stain, x100)

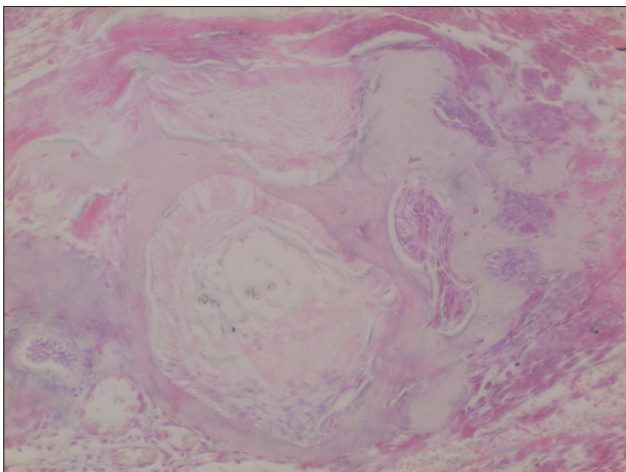


Figure 13: Histopathological image of the excisional biopsy specimen shows plenty of dentine/dentinoid like area in the centre of the lesion. (H&E, stain, x400)

After reviewing clinical and radiographic features of 162 cases, Buchner *et al.*, proposed that there are two variants of AF, with lesions occurring in patients with age >22 years that is an age beyond odontogenesis to be considered as neoplastic and in younger patients, i.e., during odontogenesis may be either true neoplasms or odontomas in early stages of development. Both the variants have similar histopathology, though clinical and radiologic characteristics can be some help of differentiating between the two. Asymptomatic small unilocular lesions with minimal or no bone expansion are likely to be developing odontomas, whereas neoplastic variants are large, expansile osteolytic lesions.^[12]

While they have similar hypothesis for AFO and believe that some of the cases of AFO reported in literature might be developing odontomas, however, they cannot be differentiated from the neoplastic AFO.^[4]

According to WHO classification (2017) of Head and Neck tumors, ameloblastic fibrodentinoma and AFO are no longer considered as separate entities but as part of the spectrum of histological changes seen in a developing odontoma.^[13] This might hold true for some of the small-size AFO described in the literature, as they actually full fill the criteria of developing odontomes. However, this classification does not take into account clinical and radiographic evidence of large lesions of AFO, which are documented in literature, causing jaw bone deformity and destruction, unlike the hamartomatous odontoma which do not have growth potential.^[8,12,14]

The neoplastic behavior of AFO has been recently emphasized with some authors pointing out that erroneous reporting of some odontomas as AFO in past literature might be the reason for the confusion.^[14,15] Histopathological features of hypocellular dental papilla-like areas without lobular architecture with drumstick-like odontogenic epithelium (AF) and randomly distributed enamel and dentine favors AFO diagnosis, unlike odontoma which shows lobular areas with central hard tissue formation and peripheral AF-like areas. In cases where there is the overlap of histopathological features combination of clinical features like the size of the lesion (>2.1 cm) and age of presentation (<13.5) years might help to differentiate neoplastic AFO from developing odontoma.^[15]

The treatment of AFO depends on clinical features. Due to a noninvasive growth of the disease during the period of odontogenesis, conservative surgical approach with

enucleation remains the gold standard. Large extensive, destructive lesions are treated by surgical resection of the involved jaw. Furthermore, as there are reports of recurrences and malignant transformation into ameloblastic fibro-odontosarcoma, it is essential to have a regular follow-up.^[14,16]

To summarize the patient was diagnosed at age of 14 years with AF on the basis of radiographic and histopathological evidence of incisional biopsy, which might not have been representative of the entire lesion. After deferring the treatment for 5 years, when he reported to our institute for further treatment, the present-day radiographic investigation indicated extensive osteolytic lesion with radiopaque calcification, which was histopathologically diagnosed as AFO. A similar case involving 6-year-old child for 18 months is reported in the literature on basis of initial biopsy report, without initial radiographic or incisional biopsy slide evidence.^[17] while the summarised evidence of the present case may indicate the possible progression of AF to AFO, it definitely proves the neoplastic behavior of AFO.

The patient was treated by hemimandibulectomy with free fibula flap reconstruction and titanium plates. The patient is periodically followed up with no evidence of recurrence 18 months postoperatively.

Declaration of patient consent

The authors certify that they have obtained all appropriate patient consent forms. In the form the patient (s) has/have given his/her/their consent for his/her/their images and other clinical information to be reported in the journal. The patients understand that their names and initials will not be published and due efforts will be made to conceal their identity, but anonymity cannot be guaranteed.

Financial support and sponsorship

Nil.

Conflicts of interest

There are no conflicts of interest.

REFERENCES

1. Reichart PA, Philipsen HP. Odontogenic Tumors and Allied Lesions. London: Quintessence; 2004. p. 133-9.
2. Kramer IR, Pindborg JJ, Shear M. Histological Typing of Odontogenic Tumors. 2nd ed. Berlin: Springer-Verlag; 1992.
3. Takeda Y, Tomich CE. Ameloblastic fibro-odontoma. In: Barnes L, Eveson JW, Reichart P, Sidransky D, editors. Pathology and Genetics of Head and Neck Tumours. Lyon: IARC Press; 2005. p. 308-9.
4. Buchner A, Kaffe I, Vered M. Clinical and radiological profile of ameloblastic fibro-odontoma: An update on an uncommon odontogenic tumor based on a critical analysis of 114 cases. *Head Neck Pathol* 2013;7:54-63.
5. Slootweg PJ. An analysis of the interrelationship of the mixed odontogenic tumors—ameloblastic fibroma, ameloblastic fibro-odontoma, and the odontomas. *Oral Surg Oral Med Oral Pathol* 1981;51:266-76.
6. Cahn LR, Blum T. Ameloblastic odontoma: Case report critically analyzed. *J Oral Surg* 1952;10:169-70.
7. Eversole LR, Tomich CE, Cherrick HM. Histogenesis of odontogenic tumors. *Oral Surg Oral Med Oral Pathol* 1971;32:569-81.
8. Philipsen HP, Reichart PA, Praetorius F. Mixed odontogenic tumours and odontomas. Considerations on interrelationship. Review of the literature and presentation of 134 new cases of odontomas. *Oral Oncol* 1997;33:86-99.
9. Trodahl JN. Ameloblastic fibroma. A survey of cases from the armed forces institute of pathology. *Oral Surg Oral Med Oral Pathol* 1972;33:547-58.
10. Hansen LS, Ficarra G. Mixed odontogenic tumors: An analysis of 23 new cases. *Head Neck Surg* 1988;10:330-43.
11. Gardner DG. The mixed odontogenic tumors. *Oral Surg Oral Med Oral Pathol* 1984;58:93.
12. Buchner A, Vered M. Ameloblastic fibroma: A stage in the development of a hamartomatous odontoma or a true neoplasm? Critical analysis of 162 previously reported cases plus 10 new cases. *Oral Surg Oral Med Oral Pathol Oral Radiol* 2013;116:598-606.
13. El-Naggar AK, Chan JK, Grandis JR, Takata T, Slootweg P, editors. WHO Classification of Head and Neck Tumours. Odontogenic and Maxillofacial Bone Tumours. Ch. 8. 4th ed. Lyon: IARC; 2017. p. 205-60.
14. Chrcanovic BR, Gomez RS. Ameloblastic fibrodentinoma and ameloblastic fibro-odontoma: An updated systematic review of cases reported in the Literature. *J Oral Maxillofac Surg* 2017;75:1425-37.
15. Soluk-Tekkesin M, Vered M. Ameloblastic Fibro-Odontoma: At the Crossroad Between "Developing Odontoma" and "True Odontogenic Tumour. *Head and Neck Pathol* 2021;15:1202-11.
16. Ferreira GZ, Danieletto Zanna CF, Iwaki Filho L, Lustosa RM, Jacomacci WP, Gonçalves ES. Ameloblastic fibroodontoma in a child patient: Case report and literature review. *Res., Soc. Dev* 2021;10:e26610212430.
17. Nandini DB, Reddy PB, Singh WR, Singh KS. Ameloblastic fibro-odontoma or complex odontoma masquerading as gingival enlargement. *J Indian Soc Periodontol* 2021;25:438-42.