

CASE REPORT

Posterior reversible encephalopathy syndrome postpartum

Lise Hald Nielsen¹, Brian Stausbøl Grøn² & Per Glud Ovesen¹

¹Department of Gynaecology and Obstetrics, Aarhus University Hospital, Brendstrupgaardsvej 100, Skejby, Aarhus 8200, Denmark

²Centre of MR Research, Aarhus University Hospital, Brendstrupgaardsvej 100, Skejby, Aarhus 8200, Denmark

Correspondence

Lise Hald Nielsen, Fredensborgparken 11, 8260 Viby J, Denmark. Tel: +0045+ 53 34 77 35; Fax: 0045+ 7845 3450; E-mail: lihn@clin.au.dk

Funding Information

No sources of funding were declared for this study

Received: 21 May 2014; Revised: 13

November 2014; Accepted: 7 December

2014

Clinical Case Reports 2015; 3(4): 266–270

doi: 10.1002/ccr3.218

Address of the institutions at which the work was carried out: Department of Gynaecology and obstetrics, Aarhus University Hospital, Skejby, Brendstrupgaardsvej 100, 8200 Aarhus N, Denmark.

Introduction

Preeclampsia is an insidious disease occurring in 4–7% of all pregnancies. Many organ systems are involved in this syndrome, including the central nervous system (CNS). PE can develop in pregnancy, during delivery and postpartum. Postpartum it is seen in the first days after delivery.

In this case, we will focus on the posterior reversible encephalopathy syndrome (PRES) which is sometimes also seen in PE and eclampsia.

Image diagnostics such as computer tomography (CT) and magnetic resonance imaging (MRI) of the CNS performed on patients with PE and eclampsia have revealed PRES in several cases; these instances are possibly a variant of hypertensive encephalopathy [1]. Approximately 1/3 of the patients have normal or slightly elevated blood pressure [2–5]. Like for PE, the most common symptoms of PRES are headache, visual abnormalities (cortical blindness, blurred vision, photophobia, hemianopia), and

Key Clinical Message

Preeclampsia (PE) should be considered in women with headache who are in gestational week 20 or more, are in labor, or have recently given birth. Early diagnosis is essential to arrest disease progression and further prognosis in PE.

Keywords

Eclampsia, hypertension in pregnancy, posterior reversible encephalopathy syndrome, postpartum preeclampsia.

seizures. Nausea and altered mental state or confusion are also common in PRES [3, 4, 6–8].

Typical signs of PRES are best detected by T2-weighted and fluid-attenuated inversion recovery (FLAIR) MRI, which is the golden standard. CT scans only reveal 50% of the lesions [7]. Typical findings are symmetric edema involving the white matter of the posterior regions of the cerebral hemispheres. White matter lesions in the occipital lobes, posterior parietal lobes, and posterior temporal lobes, in that order, are classic findings. Lesions in the frontal lobes, cerebellum, and pons may be seen, but seem to be minor and only visible in addition to injuries in the other brain structures mentioned above [1, 3–6].

The past 20 years have seen much research into the pathogenesis [1] and discussion whether PRES always is a part of the clinical picture of preeclampsia. Definitive, convincing answers are still missing.

We must remember that PE can be present in many atypical ways, and therefore be very insidious; and it may

suddenly take a very rapid course. Fast diagnosis is of outmost importance. We here describe a case with postpartum PRES that underscores the urgency of rapid intervention.

Case Presentation

A 35-year-old woman had her third uncomplicated pregnancy and birth. The birth lasted approximately 2.5 h with a short bearing down period. She gave birth at the hospital, but was discharged from hospital 6 h postpartum because there had been no complications during childbirth. Nine hours postpartum while she was sitting down at home during breastfeeding, she felt a strong “snap” in her head followed by severe headache, nausea, and photophobia. She was admitted to the hospital with a suspected cerebral catastrophe.

The highest systolic blood pressure measured was 169 mm Hg. and seen in association with the acute phase. A few hours later, systolic blood pressure was back normal. She was conscious and not confused. At the neurological department, a brain CT and MRI scans showed no signs of subarachnoidal bleeding or intracranial vascular complications and she was transferred to the obstetrical department. The first blood tests provided only sparse suggestion of possible Preeclampsia-/HELLP-syndrome with slightly reduced platelets and marginally elevated liver enzymes. Plasma urate was 0.38 mmol/L when the patient was admitted to the hospital. In the next 24 h, plasma urate rose to 0.51 mmol/L. There was 1 + protein by urine dipstick-testing Table 1.

Two and a half hours after admission the patient developed generalized seizures and treatment with intravenous magnesium sulfate was commenced in accordance with national guidelines. (Intravenous bolus of 100 mL = 20 mmol infused over 5 min and a maintenance dose, infusion speed 20 mL/h, in 24 h after the last seizure) [9].

Ultrasound examination of the pre- and intracerebral vessels was performed and revealed no signs of vessel

spasms or stenosis. Emergency MR angiography showed high signal changes in the FLAIR-sequence, especially localized as subcortical edema in the parietooccipital lobes bilaterally and in the pons (Fig. 1). This was deemed compatible with PRES. It was reasoned that the patient had PRES due to eclampsia. Multidisciplinary treatment was given by obstetricians and neurologists.

Retrospective review of patient records showed that blood pressure on arrival at the maternity ward, just before giving birth, had been 159/104 mm Hg. Blood pressure was supposedly interpreted as elevated due to labor and because there had been no symptoms or signs of PE in previous pregnancies, it was not taken seriously.

The patient stayed hospitalized under close observation. She was discharged on the third day postpartum. By then her blood tests were about to normalize, there were no nausea, photophobia, or confusion and the clinical examination was normal except from a slightly elevated blood pressure. The patient was recommended to get her blood pressure checked by her own general practitioner.

Differential Diagnosis

- Subarachnoid hemorrhage due to the symptoms of acute headache and the feeling of a snap in the head. Two of the most common symptoms for a typical subarachnoid hemorrhage.
- Intracerebral catastrophes such as cerebral thrombosis and sinus thrombosis due to nausea, dizziness, and vomiting. Symptoms like that can be caused by some thrombosis depending on location, but typically there would be motor deficits as well. Pregnant women, or women in the puerperal period are at higher risk.
- HELLP. Preeclampsia can develop into HELLP, a syndrome characterized by hemolysis, elevated liver enzymes, and low platelets.
- Migraine due to headache and nausea.

Follow-up

The patient was contacted 4 months after discharge. She reported that the headache had just recently disappeared and her blood pressure had normalized. (Home measured blood pressures between 100–110 mmHg systolic and 70–80 mmHg diastolic.) She returned to her job shortly after.

Discussion

Posterior reversible encephalopathy syndrome is seen, not only in relation to preeclampsia, but in a variety of diseases/conditions. The most common conditions are post-transplant conditions, during immunosuppressant

Table 1. Blood- and Urine tests.

	When admitted to hospital	24 h later
Lactate dehydrogenase (105–205)	267 (U/L)	248 (U/L)
Alkaline phosphatase (35–105)	127 (U/L)	114 (U/L)
C-Reactive protein (<8)	8.7 (mg/L)	17.9 (mg/L)
Hemoglobin (7.3–9.5)	8.4 (mmol/L)	7.6 (mmol/L)
Platelets (165–400)	136 (10 ⁹ /L)	150 (10 ⁹ /L)
Urate (0.15–0.35)	0.38 (mmol/L)	0.51 (mmol/L)
Urine dip-stick	1+	

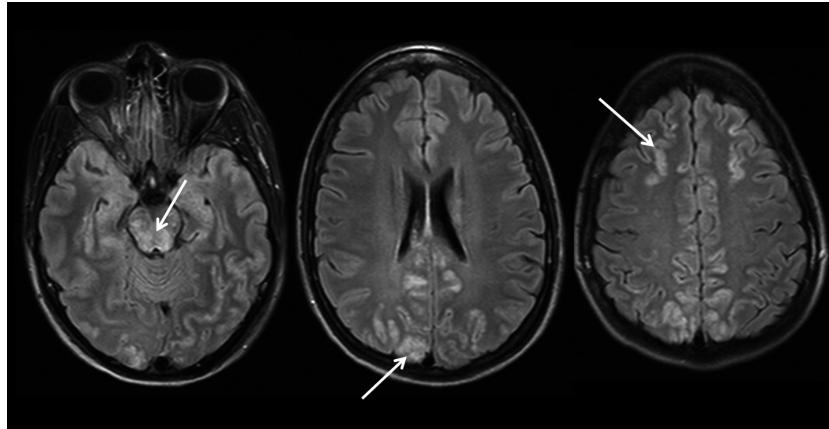


Figure 1. Magnetic resonance imaging with T2-flair-weighted images showing the typically hyperintense bilateral lesions indicating vasogenic edema in the parietooccipital regions as well as less common lesions in the frontal regions and brain stem (arrows).

treatment, infection/sepsis, autoimmune diseases, and during cancer chemotherapy [3–6, 8]. The degree of inflammatory response and multiorgan involvement is an interesting common feature. The immune response is highly activated/modified with increased levels of cytokines, a degree of renal dysfunction, vasoconstriction, coagulation system alterations (thrombocytopenia), and endothelial dysfunction.

Despite massive research the exact pathogenesis for PE is unresolved, but similarities with the above mentioned conditions are suggestive.

Pathogenesis of PRES is thought to be multifactorial yet two different theories are dominating and still being debated. The hyper perfusion theory, also called the “Vasogenic theory,” and “The hypo perfusion/ischemic theory,” also called the “Cytotoxic theory”.

The vasogenic theory is considered to be the most likely and accepted cause of PRES. The theory suggests that due to errors in the central nervous system (CNS) blood pressure auto regulation, and lack of sympathetic innervation of vessels emanating from basilar and vertebral arteries, blood flow in the CNS will increase. This causes elevated capillary filtration pressure and damage to the capillary wall, eventually leading to increased blood–brain barrier permeability and the consequence is cerebral edema [2, 3, 10]. Whether other factors, such as “toxic cytokines,” play a role is still uncertain.

Posterior reversible encephalopathy syndrome is also seen in patients without hypertension and thus makes the assumption of another theory reasonable; “The cytotoxic theory.”

It is thought that patients with chronic hypertension have hypertrophic artery walls, including in the CNS, causing reduced permeability of the blood–brain barrier. Patients with preeclampsia do not have this compensatory effect and even small increases in blood pressure, can

cause them to respond with increased permeability of the blood–brain barrier [2, 3].

The above theory can be relevant in our patient’s case since blood pressure had been normal throughout the pregnancy. In the acute phase, systolic blood pressure was 169 mmHg and diastolic blood pressure was normal. Later, blood pressure was measured even lower (Table 2).

Blood pressure was recognized elevated for the first time in relation to the birth. It was assumed, it was because the patient was in advanced labor.

A recent study [4] and a review by Feske [11] suggests that most patients with eclampsia will have changes compatible with PRES once diagnosed by appropriate image diagnostics such as MRI in T2 FLAIR-sequence but yet Wagner *et al.* [12] think we should reserve MRI imaging for patients with atypical presentations.

Ekawa *et al.* [13] recommend MRI scans of all asymptomatic patients with severe pregnancy-induced hypertension, and if cerebral changes, as edema, are located immediate delivery should be considered to prevent the development of eclamptic seizures. This solution had not been for the benefit of our patient as her high blood pressure was undetected and because she had already delivered.

Table 2. Patient information.

Age	35
Pregestational BMI	20.2
Parity	2
Gestational week for delivery	40+5
BP (early pregnancy)	112/89
BP (during delivery)	159/104
BP (in association with acute headache)	169/86
BP (when admitted to hospital)	150/90
BP (after addition)	100–110/70–80

Whether PRES leaves clinical and radiological sequel, even though the syndrome is called “reversible,” is still being debated. A study has shown that patients with pre-eclampsia have a milder form of PRES, with fewer sequela, compared to PRES triggered by other factors [6] and small follow-up studies have shown that changes on MRI are reversible [1, 8, 12, 14]. In a new review concentrating on this point authors agrees with these observations [15].

On the other hand retrospective studies have found permanent changes on MRI. Some studies have shown that irreversibility depends on severity of the acute phase, assessed on the clinical signs, including the number of seizures, but also based on primary MRI findings. In these studies, it looked like ischemic changes were more consistent with cytotoxic edema [11, 13, 14].

Delayed recognition of PRES causes secondary complications such as status epilepticus, intracranial hemorrhage, and ischemic infarction [6, 8, 10, 15], thus it seems to be of great importance to find the cause triggering the seizures and minimize number of seizures as far as possible, no matter what the underlying cause is. To do that, and optimize the diagnostic procedure it is important that there is close corporation between professionals and specialists in the acute phase. The patient in our case study had several brain scans in the first hospitalization hours precluding serious differential diagnoses. Therefore, it was reasonable to start treatment with magnesium sulfate quite fast when the patient got seizures.

Fast diagnosis is also of great importance when it comes to reassure the couple, who are probably very sensitive and anxious because they have just become parents.

Seen from our point of view, it is still uncertain whether PRES is always a part of the picture in PE and perhaps even two sides of the same matter. It is relevant to find out because it seems that the sequel may persist for a long period of time, and we need to clarify the extent of focus the specific, independent, diagnosis “PRES” deserve in the clinic, when it comes to PE.

Take Home Messages

- 1 PE can be very unpredictable and manifests in many atypical ways.
- 2 We have to remember it postpartum at all times.
- 3 Attention should be drawn to the blood pressure during birth. Blood samples and repeated blood pressure measurements to be taken if the blood pressure is elevated.
- 4 Exclude differential diagnosis as fast as possible. Fast initiation of proper treatment may be crucial for the outcome.

5 The increase/change in blood pressure and not so much the absolute blood pressure is the peculiarity in PRES. Awareness should be drawn to blood pressure changes.

All authors and staff, in position to control this case report activity, have disclosed that they have no financial relationships with, or financial interests in, any commercial organization pertaining to this educational activity.

Conflict of Interest

None declared.

References

1. Hinchey, J., C. Chaves, B. Appignani, J. Breen, L. Pao, A. Wang, et al. 1996. A reversible posterior leukoencephalopathy syndrome. *N. Engl. J. Med.* 334:494–500.
2. Cipolla, M. J. 2007. Cerebrovascular function in pregnancy and eclampsia. *Hypertension* 50:14–24.
3. Pedraza, R., P. E. Marik, and J. Varon. 2009. Posterior reversible encephalopathy syndrome: a review. *Crit. Care Shock* 12:135–143.
4. Brewer, J., M. Y. Owens, K. Wallace, A. A. Reeves, R. Morris, M. Khan, et al. 2013. Posterior reversible encephalopathy syndrome in 46 of 47 patients with eclampsia. *Am. J. Obstet. Gynecol.* 208:468.e1–468.e6.
5. Bartyński, W. S. 2008. Posterior reversible encephalopathy syndrome, part 1: fundamental imaging and clinical features. *AJNR Am. J. Neuroradiol.* 29:1036–1042.
6. Liman, T. G., G. Bohner, P. U. Heuschmann, M. Scheel, M. Endres, and E. Siebert. 2012. Clinical and radiological differences in posterior reversible encephalopathy syndrome between patients with preeclampsia-eclampsia and other predisposing diseases. *Eur. J. Neurol.* 19:935–943.
7. Roth, C., and A. Ferbert. 2010. Posterior reversible encephalopathy syndrome: long-term follow-up. *J. Neurol. Neurosurg. Psychiatry* 81:773–777.
8. Fugate, J. E., D. O. Claassen, H. J. Cloft, D. F. Kallmes, O. S. Kozak, and A. A. Rabinstein. 2010. Posterior reversible encephalopathy syndrome: associated clinical and radiologic findings. *Mayo Clin. Proc.* 85:427–432.
9. Guidelines. Hypertension og præeklamsi. 2012; Available at: <http://www.dsog.dk/sandbjerg/>.
10. Bartyński, W. S. 2008. Posterior reversible encephalopathy syndrome, part 2: controversies surrounding pathophysiology of vasogenic edema. *AJNR Am. J. Neuroradiol.* 29:1043–1049.
11. Feske, S. K. 2011. Posterior reversible encephalopathy syndrome: a review. *Semin. Neurol.* 31:202–215.
12. Wagner, S. J., L. A. Acquah, E. P. Lindell, I. M. Craici, M. T. Wingo, C. H. Rose, et al. 2011. Posterior reversible encephalopathy syndrome and eclampsia: pressing the case

- for more aggressive blood pressure control. *Mayo Clin. Proc.* 86:851–856.
13. Ekawa, Y., M. Shiota, T. Tobiume, M. Shimaoka, M. Tsuritani, Y. Kotani, et al. 2012. Reversible posterior leukoencephalopathy syndrome accompanying eclampsia: correct diagnosis using preoperative MRI. *Tohoku J. Exp. Med.* 226:55–58.
 14. Zeeman, G. G., J. L. Fleckenstein, D. M. Twickler, and F. G. Cunningham. 2004. Cerebral infarction in eclampsia. *Am. J. Obstet. Gynecol.* 190:714–720.
 15. Postma, I. R., S. Slager, H. P. Kremer, J. C. de Groot, and G. G. Zeeman. 2014. Long-term consequences of the posterior reversible encephalopathy syndrome in eclampsia and preeclampsia: a review of the obstetric and nonobstetric literature. *Obstet. Gynecol. Surv.* 69:287–300.