



Contents lists available at ScienceDirect

International Journal of Surgery Case Reports

journal homepage: www.casereports.com

Squamous cell carcinoma of the middle rectum: Report of a case and literature overview



Stefano Scaringi, Damiano Bisogni*, Luca Messerini, Paolo Bechi

Second General Surgery, Department of Surgery and Translational Medicine, Careggi Teaching Hospital, Florence, Italy

ARTICLE INFO

Article history:

Received 12 August 2014
 Received in revised form 25 October 2014
 Accepted 29 October 2014
 Available online 5 November 2014

Keywords:

Squamous cell carcinoma
 Middle rectum
 Synchronous ureteral tumor
 Radiotherapy

ABSTRACT

INTRODUCTION: Squamous-cell carcinoma (SCC) of the middle rectum is a rare disease with an estimated incidence of 0.1–0.25/1000 colorectal neoplasms. Literature is represented essentially by case report and short series, and only seventy-six cases of colorectal squamous carcinoma have been documented in literature.

PRESENTATION OF CASE: We report the case of a SCC of the middle rectum, associated to an ureteral inverted papilloma, occurred in a patient with a past history of prostate cancer treated with prostatectomy and radiotherapy.

DISCUSSION: Colorectal squamous-cell carcinoma is a rare disease. This localization is more frequent than the right colon, but no more epidemiological informations are actually available apart from a slight predominance of the female sex. Risk factors for SCC of the rectum are unknown and many hypotheses have been evocated. Because of its rarity, the interpretation of available information is clouded by a lack of uniformity in diagnosis and treatment.

CONCLUSION: Treatment of SCC remains very challenging, and the acquisition of more consistent data is needed.

© 2014 The Authors. Published by Elsevier Ltd. on behalf of Surgical Associates Ltd. This is an open access article under the CC BY-NC-ND license (<http://creativecommons.org/licenses/by-nc-nd/3.0/>).

1. Introduction

Squamous cell carcinoma (SCC) of the middle rectum is a rare disease with an estimated incidence of 0.1–0.25/1000 colorectal neoplasms. Literature is represented essentially by case report and short series. Since Schmidtmann in 1919 reported the first case SCC of the colon,¹ 76 cases of colorectal squamous carcinoma have been documented. Risk factors for SCC of the rectum are unknown and many hypotheses have been evocated. Because of its rarity, the interpretation of available information is clouded by a lack of uniformity in diagnosis and treatment.²

We present a case of SCC of the middle rectum, associated to an ureteral inverted papilloma, occurred in a patient with a past history of prostate cancer treated with prostatectomy and radiotherapy.

2. Presentation of case

A 73-year-old man consulted to emergencies for peri-anal pain. He was complaining for pelvic discomfort and constipation associated to rectal bleeding from about 8 months. He had a family history of colonic malignancy and a past history of prostate cancer (pT3N1), treated with prostatectomy, hormonal therapy and radiotherapy

seven years before. Physical examination was normal, while rectal exploration demonstrates a mass involving half circumference of the middle rectum on the posterior and left aspect of the pelvis. Blood samples showed a moderate anemia with hemoglobin at 11.2 g/dl. Colonoscopy revealed a large lesion of the middle rectum, at 7 cm from the anus (Fig. 1); the underlying mucosa, as well as the anus were normal. Biopsies demonstrate a squamous cell carcinoma. Trans rectal ultrasound revealed a contact of the tumor with the left aspect of the pelvis and enlarged lymph nodes. The CT scan confirmed the local extension, demonstrating the absence of distant or nodal metastasis, while a solid lesion of the right ureter close to the right iliac cross, suggestive for urotelial neoplasm was incidentally founded (Fig. 2).

After multidisciplinary discussion neoadjuvant treatment was excluded because of the previous radiotherapy for prostate cancer. The patient was addressed to surgical treatment. A lower anterior resection with total mesorectal excision combined to the right ureteral resection was performed. Histology confirmed an atypical squamous cell rectal cancer, that was classified pT3N1, and an inverted papilloma of the right ureter (Fig. 3). Post-operative outcome was uneventful. Patient died 4 months later for local recurrence and distant dissemination (nodal and pulmonary).

3. Discussion

Colorectal squamous cell carcinoma is a rare disease. The first case of SCC of the rectum was described by Raiford in 1933.¹ This

* Corresponding author. Tel.: +39 0557947991.

E-mail address: bisognifelice@libero.it (D. Bisogni).

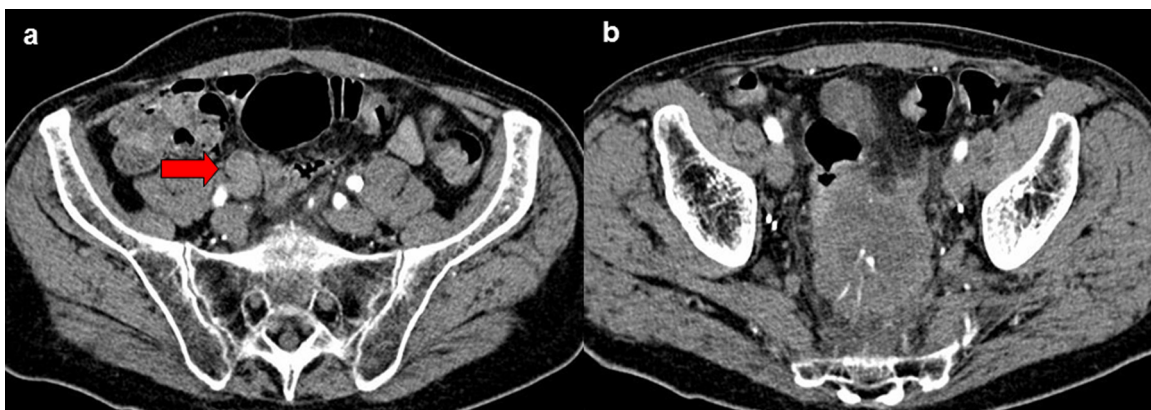


Fig. 1. Vegetating and partly ulcerated lesion of middle rectum. The cancer has spread to several centimeters into the rectum, occupying more than half of the circumference.

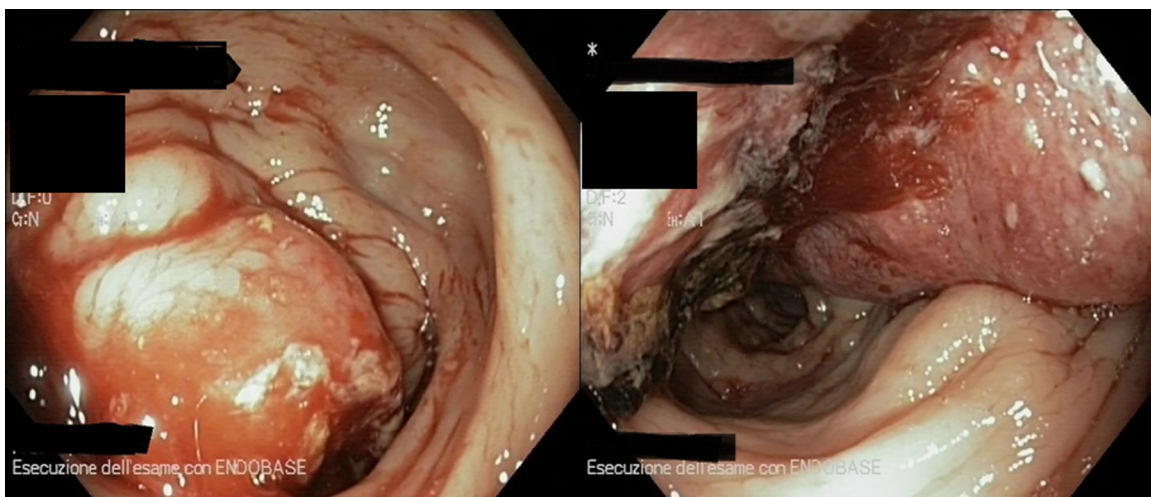


Fig. 2. (A) CT scan showing solid lesion of the right ureter close to the right iliac cross, suggestive for urotelial neoplasm. (B) CT scan showing the presence of middle rectum lesion, involving more than half of the circumference. Evidence of possible involvement of the lymph nodes of mesorectum.

localization is more frequent than the right colon, but no more epidemiological informations are actually available apart from a slight predominance of the female sex.^{1,2}

The aetiopathogenicity of SCC is unknown, but several causes have been evocated. It is general opinion that the radiation

exposure might play a role in inducing metaplasia and cancer degeneration. In the present report radiotherapy could be evocated because of the radiant exposure for the treatment of prostate cancer seven years before. Moreover, the presence of a synchronous pelvic tumor in the same irradiated field (inverted papilloma of

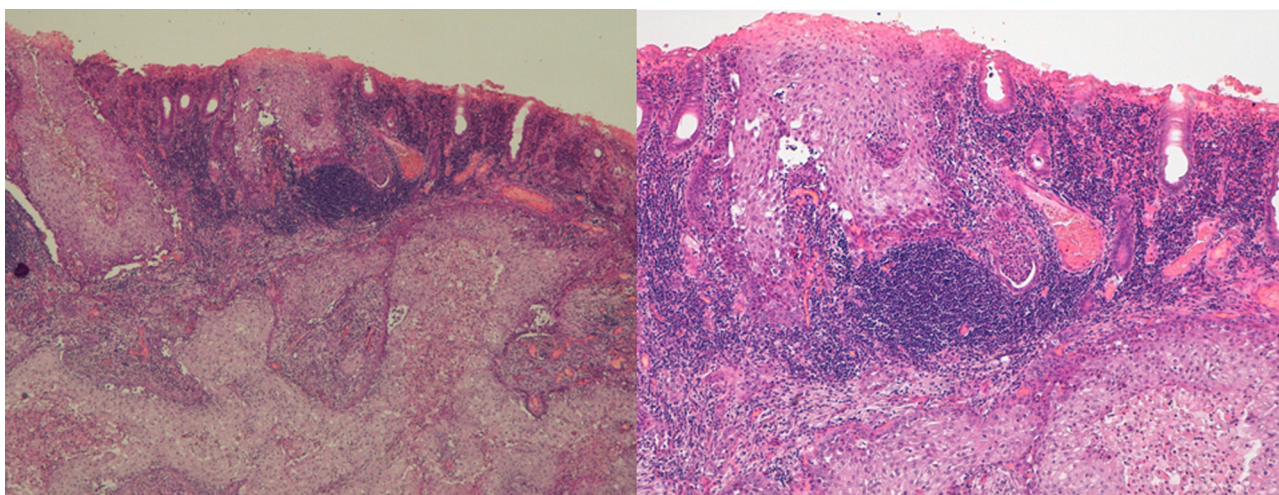


Fig. 3. Squamous epithelial cells in the context of glandular mucosa infiltrating the submucosa. The simple tubular glands show superficial hyperkeratinization. Evidence of extensive infiltration of lympho-monocytic cells in the submucosa (hematoxylin–eosin $\times 20$).

the right ureter), allow us to support this hypothesis. However other mechanisms of inflammation (inflammatory bowel disease or infections) could be equally involved.² Another mechanisms evocated is the possible differentiation from pluripotent stem cells or the squamous differentiation from adenoma and adenocarcinoma.³ As well, Michelassi suggested that epithelial damage may induce proliferation of uncommitted basal cells into squamous cells, with subsequent malignant transformation.⁴ Finally we have to mention that some histological reviews of adenocarcinomas have demonstrated areas of squamous differentiation, suggesting that SCC may arise from preexisting adenomas or adenocarcinomas.^{5,6} Nevertheless, a critical analysis of risk factors for SCC is still impossible.

The clinical presentation of SCC is similar to that of adenocarcinoma of the rectum but treatment and prognosis are not so well known. In 1979 Williams proposed four criteria to be fulfilled for a correct diagnosis of SCC: absence of extension of the tumor from the anal squamous epithelium; absence of evidence of squamous cell carcinoma of any other primary site; absence of squamous-lined fistula tract to the affected bowel; confirmation of SCC by histological examination (without glandular differentiation).⁶ We found, including our report, 76 cases described as clinical cases or little series of colorectal squamous carcinoma, that accomplished these criteria.

As well as for rectal adenocarcinoma, diagnosis is made by endoscopy with biopsies. Some considerations have to be made regarding the histology, because of the importance of differentiating this form of cancer from other rectal tumors. As suggested by Nahas immunohistochemistry helps to differentiate rectal from anal tumor, notably the cytocheratins CAM 5.2 is able to stains rectal SCC but not anal SCC.⁷ Pre-operative staging includes trans-rectal ultrasound, MRI and CT scan. As well as for rectal adenocarcinoma, trans-rectal ultrasound and MRI should be preferred for T and N staging.

As showed in two recent reviews of the literature, treatment is far to be assessed.^{1,2} Many treatment have been proposed depending by tumor location, TNM stage, age of the patient and presence of comorbidities (chemotherapy or radiotherapy alone or in combination, local excision or surgical excision alone or in combination with chemo-radiotherapy).⁸ Most authors believe that surgery is the gold standard, however, following the axiom with rectal adenocarcinoma and considering the efficacy of chemoradiotherapy alone for SCC of the anus,⁹ it seems reasonable to regard with attention to pre-operative neoadjuvant radio-chemotherapy. This is well represented in two different publications^{10,11} about SCC of the rectum. Surgery alone could be reserved for patients who cannot undergo neoadjuvant treatment. The issue of which chemotherapeutic regimen to use in combination with radiotherapy, has not been evaluated for SCC of the rectum. Nevertheless, following the paradigm of the effectiveness in the treatment of SCC of the anus, most appropriate drugs are mitomycin C and cisplatin both combined with fluorouracil and radiotherapy. However, as demonstrated by Ajani^{12–14} in a randomized controlled trial, there is no difference in survival, local recurrence and distant metastasis among the two groups for patients affected by SCC of the anus. As consequence, the most appropriate surgical strategy appears to be the result of the better treatment combination of rectal adenocarcinoma and SCC of the anus.

In conclusion, as a result of this lack of knowledge, treatment of SCC remains very challenging, and the acquisition of more

consistent data is needed. Patients should be addressed to hospitals at high volume of colorectal procedure, in order to assess the best standard of care.

Conflict of interest

The authors declare no conflicts of interest.

Funding

The authors declare no source of funding for their research.

Ethical approval

Written informed consent was obtained from the patient for publication of this case report and accompanying images. A copy of the written consent is available for review by the Editor-in-Chief of this journal on request.

Author contributions

All authors contributed to the manuscript as follow: Stefano Scaringi contributed to conception, editing and revision; Damiano Bisogni contributed to acquisition of data and revision; Luca Messerini contributed to histological revision and editing; Paolo Bechi contributed revision and final approval of the version to be published.

References

- Kassir R, Baccot S, Bouarioua N, et al. Squamous cell carcinoma of middle rectum: literature review. *Int J Surg Case Rep* 2014;**5**:86–90.
- Dyson T, Draganov PV. Squamous cell cancer of the rectum. *World J Gastroenterol* 2009;**15**:4380–6.
- Ouban A, Nawab RA, Coppola D. Diagnostic and pathogenetic implications of colorectal carcinomas with multidirectional differentiation: a report of 4 cases. *Clin Colorectal Cancer* 2002;**1**:243–8.
- Michelassi F, Mishlove LA, Stipa F, et al. Squamous-cell carcinoma of the colon. Experience at the University of Chicago, review of the literature, report of two cases. *Dis Colon Rectum* 1988;**31**:228–35.
- Jaworski RC, Biankin SA, Baird PJ. Squamous cell carcinoma in situ arising in inflammatory cloacogenic polyps: report of two cases with PCR analysis for HPV DNA. *Pathology* 2001;**33**:312–4.
- Williams GT, Blackshaw AJ, Morson BC. Squamous carcinoma of the colorectum and its genesis. *J Pathol* 1979;**129**:139–47.
- Nahas CS, Shia J, Joseph R, et al. Squamous-cell carcinoma of the rectum: a rare but curable tumor. *Dis Colon Rectum* 2007;**50**:1393–400.
- Anagnostopoulos G, Sakorafas GH, Kostopoulos P, et al. Squamous cell carcinoma of the rectum: a case report and review of the literature. *Eur J Cancer Care (Engl)* 2005;**14**:70–4.
- Nigro ND, Seydel HG, Considine B, et al. Combined preoperative radiation and chemotherapy for squamous cell carcinoma of the anal canal. *Cancer* 1983;**51**:1826–9.
- Clark J, Cleator S, Goldin R, et al. Treatment of primary rectal squamous cell carcinoma by primary chemoradiotherapy: should surgery still be considered a standard of care. *Eur J Cancer* 2008;**44**:2340–3.
- Rasheed S, Yap T, Zia A, et al. Chemo-radiotherapy: an alternative to surgery for squamous cell carcinoma of the rectum – report of six patients and literature review. *Colorectal Dis* 2009;**11**:191–7.
- Raiford TS. Epitheliomata of the lower rectum and anus. *Surg Gynecol Obstet* 1933;**57**:21–35.
- Ajani JA, Winter KA, Gunderson LL, et al. Fluorouracil, mitomycin, and radiotherapy vs fluorouracil, cisplatin, and radiotherapy for carcinoma of the anal canal: a randomized controlled trial. *JAMA* 2008;**299**:1914–21.
- Wang JF, Wang ZX, Xu XX, Wang C, Liu JZ. Primary rectal squamous cell carcinoma treated with surgery and radiotherapy. *World J Gastroenterol* 2014;**20**(April (14)):4106–9.

Open Access

This article is published Open Access at sciendo.com. It is distributed under the [IJSCR Supplemental terms and conditions](#), which permits unrestricted non commercial use, distribution, and reproduction in any medium, provided the original authors and source are credited.