

Received: 2019.08.14
Accepted: 2019.11.14
Published: 2019.12.01

Ulinastatin Reduces the Severity of Intestinal Damage in the Neonatal Rat Model of Necrotizing Enterocolitis

Authors' Contribution:
Study Design A
Data Collection B
Statistical Analysis C
Data Interpretation D
Manuscript Preparation E
Literature Search F
Funds Collection G

B 1 **Shuxia Liang**
C 2 **Panjian Lai**
D 2 **Xiaobing Li**
E 3 **Jie Xu**
E 2 **Yunguang Bao**
F 4 **Yuanshu Fang**
AG 5 **Mingxing Ding**

1 Department of Ophthalmology, Jinhua Hospital of Zhejiang University, Jinhua, Zhejiang, P.R. China
2 Department of Pediatrics, Jinhua Hospital of Zhejiang University, Jinhua, Zhejiang, P.R. China
3 Operating Room, Jinhua Hospital of Zhejiang University, Jinhua, Zhejiang, P.R. China
4 Department of Laboratory Animals Center, Jinhua Institute for Food and Drug Control, Jinhua, Zhejiang, P.R. China
5 Medical Molecular Biology Laboratory, School of Medicine, Jinhua Polytechnic, Jinhua, Zhejiang, P.R. China

Corresponding Author: Mingxing Ding, e-mail: mxding99@163.com

Source of support: This work was funded by Experimental Animals Science and Technology Project of Zhejiang Province in China (2017C37116) and Jinhua Science and Technology Research Project (2015-3-010)

Background: Ulinastatin is a protease inhibitor derived from urine that has shown anti-inflammatory effects in human disease, including in sepsis. Necrotizing enterocolitis (NEC) is a common gastrointestinal disease in premature infants. Our aim was to explore the effects of ulinastatin on a neonatal NEC rat model.

Material/Methods: Forty-five neonatal rats were divided into 3 groups: normal control; NEC+sepsis-induced kidney injury (SIRS); NEC/SIRS+ulinastatin. The NEC/SIRS model was induced by injection of intraperitoneal saline, enteral formula feeding, hypoxia-hyperoxide, and cold stress exposure. The NEC/SIRS neonatal rats were perfused with ulinastatin at a dose of 10 000 u/kg/day. Giemsa staining and hematoxylin and eosin (H&E) were performed to evaluate the severity of intestinal damage. To assess intestinal cell apoptosis, we examined the expression of caspase-3 by TUNEL staining and western blot analysis. Intestinal levels of inflammatory cytokines (IL-1 β , IL-6, and TNF- α) were examined using ELISA assay.

Results: Rats in the NEC treated with ulinastatin group had better physiological status and histological score compared to the NEC/SIRS group. Ulinastatin reduced NEC-induced weight loss. Macroscopic and microscopic morphology analyses showed that rats in the NEC treated with ulinastatin group had lower severity of intestinal damage compared to the NEC/SIRS group. TUNEL staining and caspase-3 expression detection results revealed that ulinastatin significantly inhibited intestinal cell apoptosis of NEC. Furthermore, ulinastatin decreased the intestinal levels of IL-1 β , IL-6, and TNF- α in NEC.

Conclusions: Ulinastatin could ameliorate the severity of intestinal damage in NEC and possess anti-apoptosis and anti-inflammation effects.

MeSH Keywords: **Enterocolitis, Necrotizing • Infant, Newborn • Inflammation**

Abbreviations: **NEC** – necrotizing enterocolitis; **SIRS** – sepsis-induced kidney injury; **ELISA** – enzyme-linked immunosorbent assay; **H&E** – hematoxylin and eosin; **TNF- α** – tumor necrosis factor- α ; **IL-1 β** – interleukin1 β ; **IL-6** – interleukin 6; **TUNEL** – transferase mediated dUTP nick end labeling

Full-text PDF: <https://www.medscimonit.com/abstract/index/idArt/919413>

 2916

 1

 5

 45



Background

Necrotizing enterocolitis (NEC) is a common gastrointestinal disorder in premature infants [1], with high neonatal morbidity (2–7%) and mortality (15–30%) [2]. The pathogenesis of NEC is characterized by intestinal inflammation, which can progress to systemic infection, induce multiple organ failure, and ultimately lead to death [3,4]. In China, the preterm birth rate is as high as 7.1%. Premature infants with NEC usually have low birth weight and young gestational age [5]. Though the much improvement of neonatal care has greatly improved the survival rate of premature infants, the risk of NEC is also increasing [6]. Thus, novel treatment options are expected to assist treat and prevent the development and progression of the disease [7].

Increased intestinal cell shedding is one of the early changes in the intestinal mucosa of NEC [8,9]. Exfoliated gut cells die through the process of cell apoptosis, which causes bacteria to metastasize in the intestinal monolayer and activate the host's immune system. Therefore, inhibiting apoptosis will reduce the incidence and severity of NEC. Inflammation is a crucial factor in the progression of NEC [10]. Increased inflammatory cytokines such as tumor necrosis factor (TNF- α), interleukins (IL-1 β , IL-6) aggravate intestinal mucosal injury [11]. It has been confirmed elevated levels of TNF- α in plasma of infant with NEC [12]. The pathogenesis of NEC is complex and varies greatly. To understand the disease, the researchers studied tissues removed from NEC patients. However, since these tissues are obtained in the late stages of NEC, it is difficult to study clues leading to pathogenic events in NEC. Thus, animal models have been widely applied used to determine the role of inflammatory mediators in NEC [13].

Ulinastatin, a trypsin inhibitor, consists of a glycoprotein consisting of 143 amino acids [14,15]. Ulinastatin was originally obtained by separation and purification from human urine. It has been well recognized that ulinastatin has anti-inflammatory and anti-apoptotic properties, which has been used to treat sepsis, shock, acute pancreatitis and so on [16–18]. To our knowledge, our study is the first to explore the effect of ulinastatin in the NEC/SIRS rat model.

In our study, we hypothesized that ulinastatin could reduce the intestinal damage of NEC/SIRS rat model by anti-inflammatory and anti-apoptotic properties.

Material and Methods

Experimental animals

Thirty Sprague-Dawley adult rats, including 20 females and 10 males, were purchased from Shanghai Slack Laboratory

Animals Co., Ltd. (China). All rats were housed in a suitable environment of 20–26°C and 40–70% humidity. After adaptive feeding for 1 week, the rats were caged (male to female ratio 2: 1). On the 22nd day, 5 female rats gave birth to 45 mice for further experiments. Our study was approved by the Ethics Committee of Jinhua Polytechnic.

Experimental groups

The 45 neonatal rats were randomly divided into 3 groups. 1) Normal control (NC) group (n=15): the rats were routinely fed without any intervention or stimulation. 2) NEC+SIRS group (n=15): The rats were injected with intraperitoneal saline, fed with intestinal formula milk, exposed hypoxia-high oxygen and cold stress. That is to say, neonatal rats were in turn placed 100% CO₂ for 10 minutes, 4°C for 5 minutes, 97% O₂ for 5 minutes, twice a day for 3 consecutive days, and injected saline into the peritoneal cavity. Based on the successful construction of the NEC model, the SIRS model was established. 3) NEC/SIRS+ulinastatin treatment group (n=15): After successfully constructing NEC/SIRS model, neonatal rats were perfused with ulinastatin at a dose of 10 000 u/kg/day, once a day for 3 consecutive days.

NEC/SIRS evaluation and tissue preparation

The changes in general conditions and body mass parameters of all neonatal rats were observed. The physiological status scores were recorded (0 to 12 scores), including appearance, behavior, and neurological function [19]. General conditions include mental, reaction, activity status, food intake, bloating, vomiting, stomach retention, changes in stool characteristics, etc. The weight of rats was measured every day.

The following 2 or more items are diagnosed as SIRS [20]: 1) hyperthermia or low body temperature; 2) tachycardia; 3) accelerated breathing or assisted ventilation; 4) leukocytosis or reduction. Considering that the heart rate of newborn rats was greatly disturbed by the environment and the body temperature was not easy to measure, our study measured the respiratory and white blood cell counts. If reaching or exceeding 2 times of the normal value of these 2 items, it was regarded as SIRS.

After euthanizing the rats, the gastrointestinal tissues (end of the duodenum to the ileocecal intestine) were removed. The intestines were evaluated and scored, including bowel appearance, tension, contractility, and so on. To determine the changes in intestinal pathology of NEC rats, light microscopy of intestinal tissue was performed. The intestinal pathology was scored by the standard double-blind method [21], as follows: 0 points: intact intestinal mucosa, normal tissue structure; 1 point: slight submucosal and/or lamina propria separating and swelling; 2 points: moderate submucosal and/or lamina

propria, submucosal and/or muscular edema; 3 points: severe submucosal and/or lamina propria, submucosal and/or muscular edema, local villi detachment; 4 points: Intestinal villi disappear with intestinal necrosis. A pathological score ≥ 2 points was considered as NEC.

Giemsa staining

The cells from intestinal tissues of newborn rats were fixed using Carnoy fixative. Then, the cells were stained with Giemsa and observed under an optical microscopy (200 \times).

Histology

Intestinal tissues of newborn rats were fixed in 10% formalin solution for 24–48 hours. Next, the tissues were dehydrated by 70%, 80%, 90%, 95%, 100% ethanol I, 100% ethanol II for 52 minutes, respectively. Then, the dehydrated tissues were immersed transparently through xylene I and xylene II for 52 minutes, respectively. After being immersed in wax, the tissues were embedded and sliced. The section thickness was 4 μ m. After the sections were placed in a 60°C box for 6–12 hours, the tissues were subjected to H&E staining. After dewaxing to water, the section was stained with hematoxylin dye solution for 20 minutes at room temperature and eosin solution for 1 minute. After dehydration and transparency, the sections were taken out and sealed with a neutral balsam.

Transferase mediated dUTP nick end labeling (TUNEL) staining

TUNEL staining of the intestinal tissue sections was performed. After dewaxing to water, the section was added with 20 μ g/mL of proteinase K (positive control group was added with protease K containing 10 μ g/mL DNase) at 37°C for 20 minutes. After that, the section was added with an appropriate amount of TUNEL assay solution (Beyotime, Hunan, China), and incubated at 37°C for 60 minutes in the dark. The section was washed 3 times with phosphate buffered saline (PBS) for 10 minutes each time, air-dried and sealed with anti-fluorescence quencher sealer.

Western blotting analysis

Tissue samples were lysed using 200 μ L of lysate (Beyotime, Hunan, China) supplemented with protease inhibitor (Bimake, Shanghai, China) and allowed to stand on ice for 20 minutes. After repeated centrifugation at 4°C, centrifugation at 13 000 rpm for 30 minutes, the supernatant was taken. The extracted protein samples were added to 6 \times loading buffer, denatured at 100°C for 5 minutes, and collected by brief centrifugation. After determining the protein concentration, the protein was separated by polyacrylamide gel electrophoresis and then transferred to a PVDF membrane (Millipore,

Bedford, MA, USA). The PVDF membrane was immersed in a blocking solution containing 5% skim milk powder or 5% bovine serum albumin (BSA) and blocked at room temperature for 2 hours. Next, the PVDF membrane was incubated with primary antibodies including rabbit anti-caspase-3 (Cat No.96645; 1: 1000; Cell Signaling Technology, Danvers, MA, USA) and rat anti- β -actin (Cat No.ab8226; 1: 5000; Abcam, Danvers, MA, USA) overnight at 4°C and then incubated with secondary antibody for 2 hours at room temperature. The protein was visualized through the ECL kit. β -actin served as an internal control.

Enzyme-linked immunosorbent assay (ELISA)

Inflammatory cytokine tumor necrosis factor- α (TNF- α), interleukin1 β (IL-1 β), and interleukin 6 (IL-6) levels were harvested from the supernatant of rat intestinal tissue and were measured using the rat TNF- α ELISA test kit (MultiSciences Biotech Co., Ltd., Zhejiang, China), rat IL-1 β ELISA test kit (MultiSciences Biotech Co., Ltd., Zhejiang, China) and rat IL-6 ELISA test kit (MultiSciences Biotech Co., Ltd., Zhejiang, China).

Statistical analysis

All statistical analyses were performed using Graphpad Prism 7.0 (San Diego, CA, USA). Data were expressed as the mean \pm standard deviation (SD). The differences between 2 groups were compared using Student's *t*-test. *P*-value <0.05 was considered statistically significant.

Results

Ulinastatin reduced weight loss and ameliorates intestinal injury in NEC/SIRS

Rats in the NEC/SIRS model group with or without ulinastatin treatment had weight loss, while rats in the normal control group had weight gain (Figure 1A). However, we found that ulinastatin reduced NEC/SIRS-induced weight loss. We recorded the physiological status scores of each group of rats (Table 1). Ulinastatin improved the physiological status of NEC/SIRS rats.

The respiratory rates of newborn rats in the NEC/SIRS model group were both higher than that in the normal control group, and the mouth was often breathing. Furthermore, the results of Giemsa staining showed that the number of white blood cells in the NEC/SIRS model group was much larger than that of the normal control group. These results confirmed that the rats in the NEC/SIRS model group met SIRS diagnostic criteria. However, we found that in the NEC/SIRS model group, neutrophils were increased, and basophils were decreased after ulinastatin treatment (Figure 1C). Therefore, ulinastatin improved SIRS symptom of newborn rats.

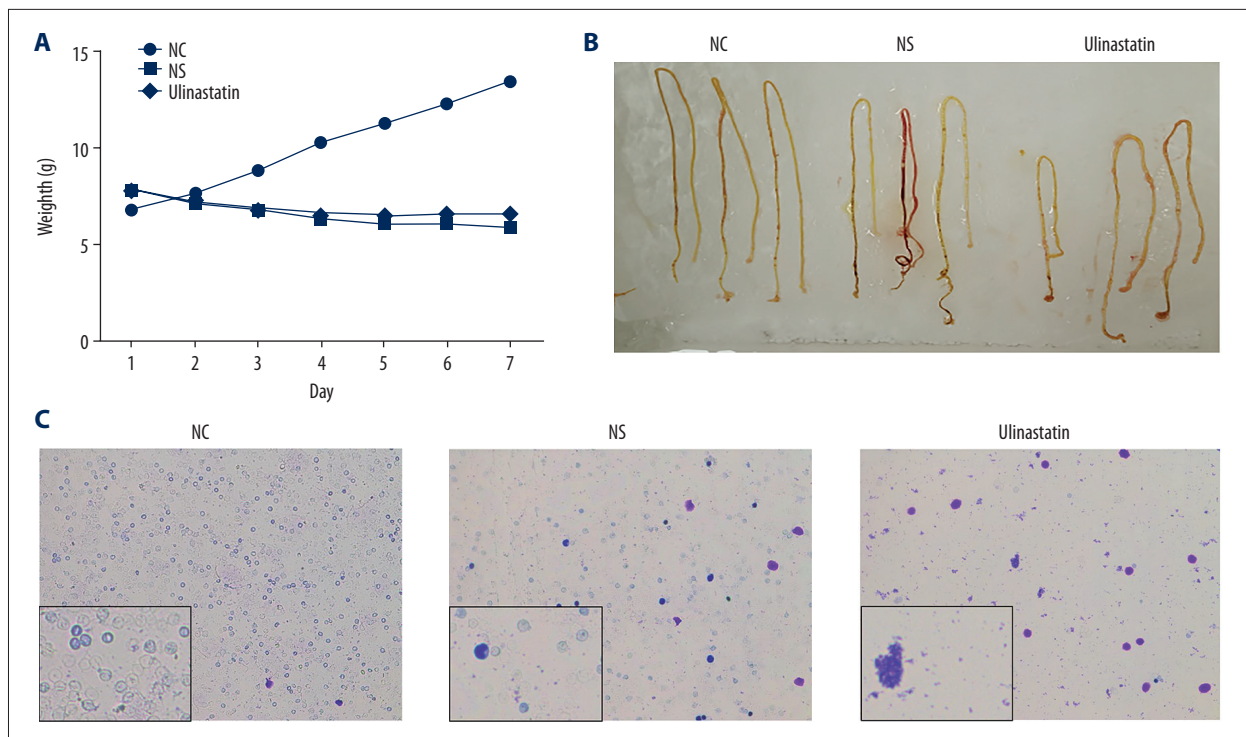


Figure 1. Weight changes, macroscopic and microscopic morphological analyses of gut tissue changes of newborn rats. **(A)** Weight changes for newborn rats in each group. **(B)** Macroscopic morphological analyses of the gut for newborn rats in each group. **(C)** Microscopic morphological analyses of the gut for newborn rats in each group using Giemsa staining (200 \times). Blue-purple is basophilic, and lavender is neutrophil. NEC – necrotizing enterocolitis; NC – normal control; NS – necrotizing enterocolitis/sepsis-induced kidney injury; ulinastatin, necrotizing enterocolitis/sepsis-induced kidney injury+ulinastatin.

Table 1. Physiological status and histological score of newborn rats ($\bar{x}\pm s$).

| Group | Physiological status score | Histological score |
|-------------|----------------------------|--------------------|
| NC | 0.2 \pm 0.22 | 0.2 \pm 0.42 |
| NS | 0.44 \pm 0.78 | 3.4 \pm 0.52 |
| Ulinastatin | 0.31 \pm 0.39 | 1.3 \pm 0.48 |

NC – normal control; NS – necrotizing enterocolitis/sepsis-induced kidney injury; ulinastatin, necrotizing enterocolitis/sepsis-induced kidney injury+ulinastatin.

Next, we analyzed the macroscopic and microscopic morphology of the gastrointestinal tract for rats in each group. We found that rats in the NEC group developed extensive intestinal lesions, similar to the pathological changes in neonatal NEC. Macroscopically, in the NEC group, we observed severe inflammation, discoloration, and bleeding in the intestines. The appearance of the intestine of the NEC group ranged from pink/red to deep purple/black. In the rats of normal control groups, the appearance of the normal intestine was yellow/green (Figure 1B). To confirm the severity of NEC,

we performed histological analysis of the intestine. Those with a pathological score of ≥ 2 were considered to be NEC positive (Table 1). Histological analysis showed significant pathological changes in the intestinal structure of the NEC group. As shown in Figure 2, H&E staining results showed that in the NC group, the structure of the intestine was clear and normal; the epithelium was intact and continuous; the glands were arranged regularly; the villi were high; and the mucosa, submucosa and lamina propria were free from congestion and edema and fracture separation. In the NEC model group, intestinal tissue necrosis was severe; glandular disorder, disappearance; villus edema, uneven, partial necrosis or disappearance of the villus; thinning or even rupture of the muscular layer, severe edema of the lamina propria and submucosa. In the NEC model with ulinastatin group, mild to moderate congestion and edema, villus edema, and slightly disordered glandular structure were observed in the intestinal mucosa and submucosa. Above results revealed that ulinastatin ameliorated intestinal injury in NEC.

Ulinastatin reduced apoptosis of intestinal cells in NEC/SIRS rats

To investigate the effect of ulinastatin on apoptosis of intestinal cells in NEC rats, TUNEL staining was performed. The results

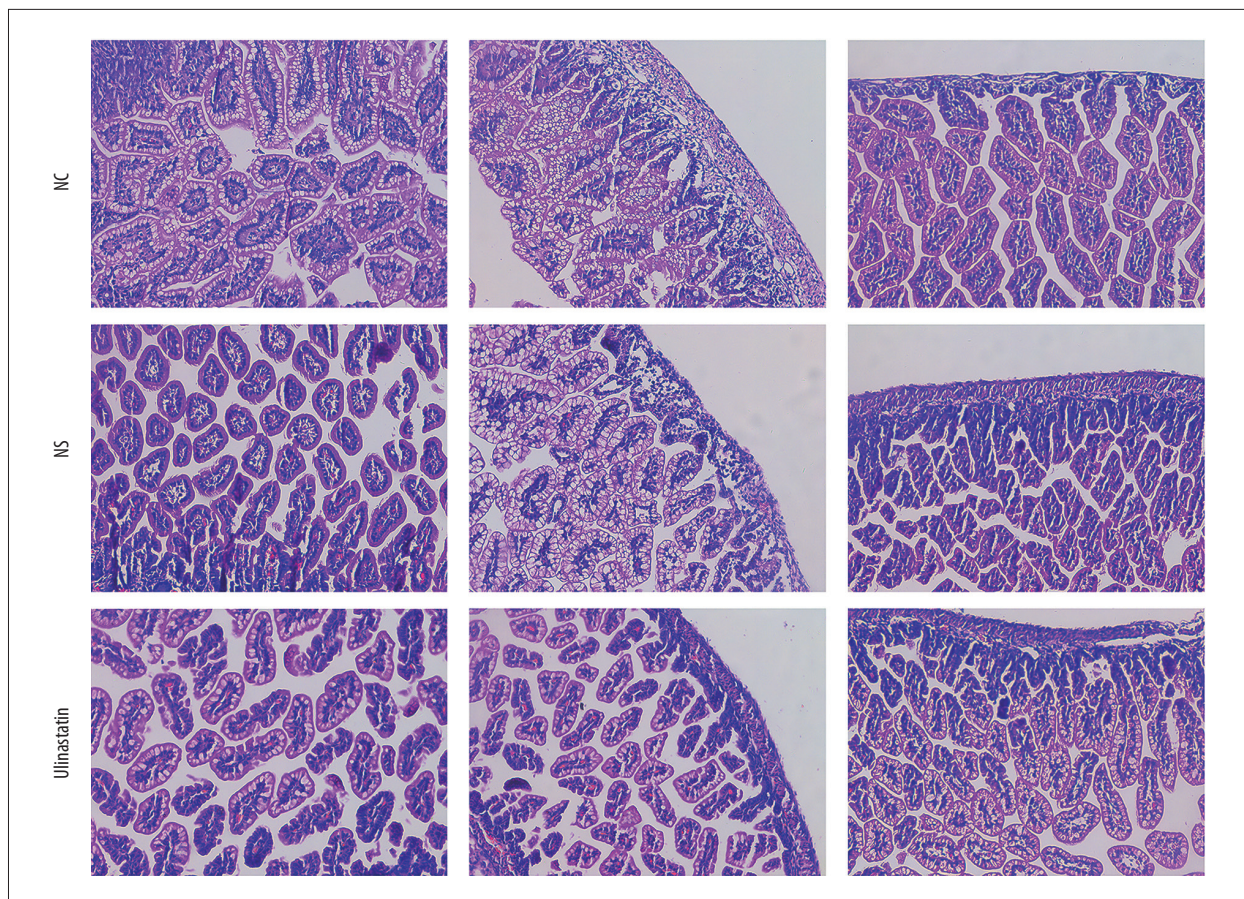


Figure 2. Representative sections of intestinal tissues of neonatal rats were stained with H&E (400 \times). Abbreviations: NEC, necrotizing enterocolitis; NC, normal control; NS, necrotizing enterocolitis/sepsis-induced kidney injury; ulinastatin, necrotizing enterocolitis/sepsis-induced kidney injury+ulinastatin; H&E – hematoxylin and eosin.

showed that there were more apoptotic cells in the NEC/SIRS model group than in the normal control group. Moreover, we found that apoptotic cells in the NEC/SIRS model treated with ulinastatin group were significantly inhibited compared to the NEC/SIRS model group (Figure 3A, 3B). We also examined the expression of caspase-3 of intestinal tissues of neonatal rats for each group. The results showed that caspase-3 expression in the NEC/SIRS model group was significantly higher than that in the normal control group (Figure 4). Furthermore, we found that caspase-3 expression in the NEC/SIRS model treated with ulinastatin group was lower than that in the NEC/SIRS model group. Therefore, ulinastatin reduced caspase-3 expression in NEC rats. These results revealed that ulinastatin reduces apoptosis of intestinal cells in NEC rats.

Ulinastatin suppressed inflammation cytokine IL-1 β , IL-6 and TNF- α levels in NEC/SIRS rats

To observe the anti-inflammation effects of ulinastatin on NEC rats, we examined inflammatory cytokines including IL-1 β , IL-6, and TNF- α from rat intestinal tissues using ELISA. The results

showed that the expression levels of IL-1 β , IL-6, and TNF- α in the NEC/SIRS group were significantly higher than those in the normal control group (Figures 5A–5C). Furthermore, ulinastatin significantly inhibited the expression levels of IL-1 β , IL-6, and TNF- α in NEC models. Therefore, ulinastatin could possess anti-inflammation effects on NEC.

Discussion

In this study, we successfully established neonatal NEC rat model. Our findings revealed that administration of ulinastatin reduced NEC-induced weight loss. Furthermore, ulinastatin could improve intestinal injury caused by formula feeding and hypoxia stress as well as cold stimulation, suggesting that ulinastatin can reduce the degree of histological injury in the NEC rat model. We further investigated that enteral administration of ulinastatin could reduce apoptosis and intestinal inflammation. Thus, ulinastatin could possess anti-apoptosis and anti-inflammation effects on NEC.

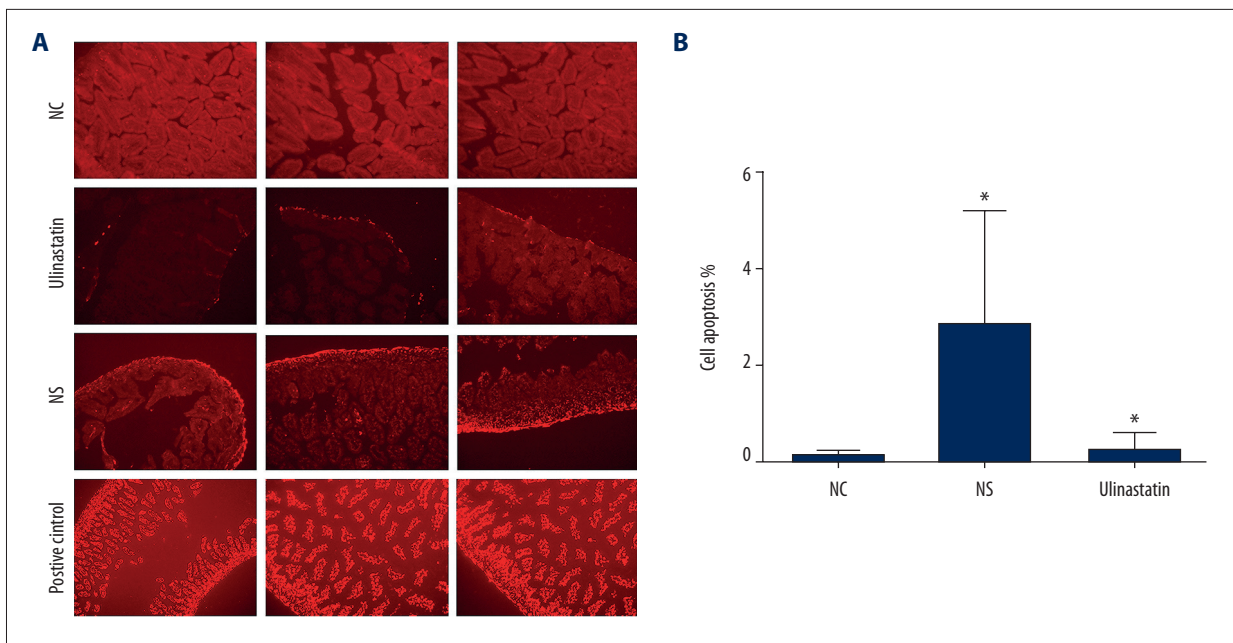


Figure 3. Ulinastatin reduces apoptosis of intestinal cells in NEC rats. **(A)** Representative sections of intestinal tissues of neonatal rats for each group were stained with TUNEL staining ($\times 200$). The nucleus was stained red. **(B)** Cell apoptosis rate was calculated for each group. NEC – necrotizing enterocolitis; NC – normal control; NS – necrotizing enterocolitis/sepsis-induced kidney injury; ulinastatin, necrotizing enterocolitis/sepsis-induced kidney injury+ulinastatin; TUNEL – transferase mediated dUTP nick end labeling. * *P*-value < 0.05 .

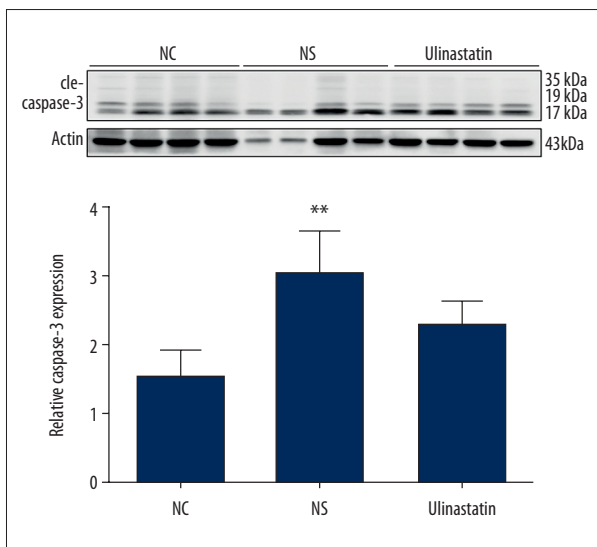


Figure 4. Western blotting analysis showing caspase-3 expression of intestinal tissues of neonatal rats for each group. Actin was used as an internal control. NEC – necrotizing enterocolitis; NC – normal control; NS – necrotizing enterocolitis/sepsis-induced kidney injury; ulinastatin, necrotizing enterocolitis/sepsis-induced kidney injury+ulinastatin. ** *P*-value < 0.01 .

In our study, the neonatal rat NEC model was constructed to reflex complex factors in human through enteral formula feeding, hypoxia-hyperoxide exposure, and cold stress [25,26]. Experimental animal models and human epidemiological analyses have shown that formula feeding, intestinal hypoxic ischemic injury and abnormal bacterial colonization are in association with an increased risk of NEC. However, it is still very difficult to fully reflect these complex factors in animal models [3,22,23]. Although it has been recognized that NEC development in human is more complex than in rat models, and the pathophysiology of rat models may be a little different from human, the premature rat model based on formula feeding and hypoxic stress on intestinal damage has been considered a successful NEC model [24]. Therefore, our neonatal rat NEC model can adequately reflex complex factors in human. Our results showed that ulinastatin reduced weight loss and ameliorated intestinal injury the neonatal rat NEC model, suggesting that ulinastatin might possess potential to treat NEC.

We found that TUNEL staining was reduced and caspase-3 expression was decreased in NEC model treated with ulinastatin [32,33]. The result revealed that ulinastatin treatment reduces intestinal cell apoptosis of NEC. It has been confirmed that intestinal apoptosis is a pivotal process in the pathogenesis of NEC [27–29]. Apoptosis is thought to be the earliest histopathological change in NEC intestinal tissue [8]. Histopathological analysis revealed significant epithelial cell

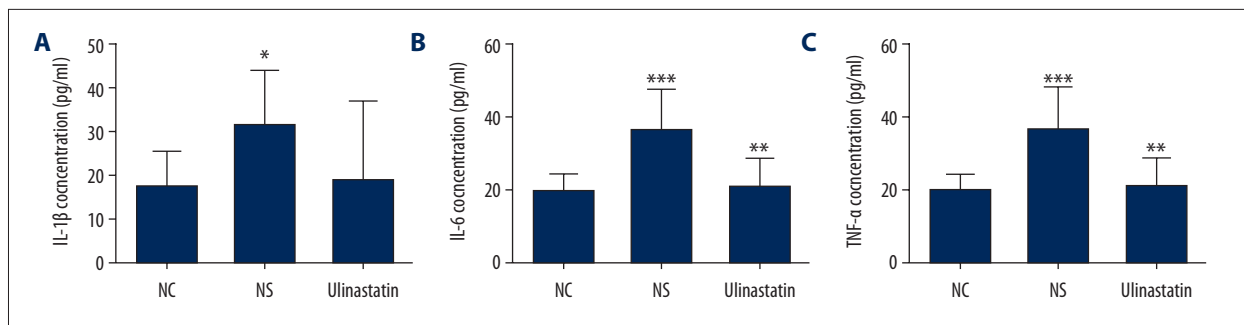


Figure 5. ELISA analysis showing inflammation cytokine IL-1 β , IL-6, and TNF- α levels in NEC rats. (A) IL-1 β . (B) IL-6. (C) TNF- α . NEC – necrotizing enterocolitis; NC – normal control; NS – necrotizing enterocolitis/sepsis-induced kidney injury; ulinastatin, necrotizing enterocolitis/sepsis-induced kidney injury+ulinastatin; ELISA – enzyme-linked immunosorbent assay; IL-1 β – interleukin 1 β ; IL-6 – interleukin 6; TNF- α – tumor necrosis factor- α . * *P*-value <0.05; ** *P*-value <0.01; *** *P*-value <0.001.

apoptosis in the intestinal tissues of preterm infants with NEC. Abnormally active apoptosis is a main cause of deterioration of intestinal mucosal barrier function [30,31]. Hence, inhibition of apoptosis will reduce the incidence and severity of NEC. Our findings revealed that ulinastatin protects the intestinal epithelium by inhibiting epithelial cell apoptosis.

Our findings showed that ulinastatin reduced the intestinal levels of the pro-inflammatory cytokines IL-1 β , IL-6, and TNF- α . In the intestinal tissues of NEC rats, we observed a significant increase in IL-1 β , IL-6, and TNF- α levels. Obviously, a severe inflammatory process occurred in NEC rats, destroying the intestinal structure. These results indicated that administration of ulinastatin reduces pro-inflammatory cytokines at the intestinal level associated with NEC. Inflammation is known to be a key factor in the pathogenesis of NEC [11], as abnormally activated intestinal immune system plays a role in the pathogenesis of NEC [34]. A few different pro-inflammatory and anti-inflammatory mediators have been identified to be associated with NEC. It has been reported that innate immune responses are characterized by activated pro-inflammatory cytokines in intestinal tissues, including TNF- α , IL-1 β , and IL-6 [1,13]. TNF- α is a key immunoregulatory cytokine that functions in triggering a series of immune responses. In addition, TNF- α stimulates the production of other cytokines (such as IL-1 and IL-6), and aggravates intestinal mucosal damage. Increased levels of TNF- α and IL-6 have been demonstrated in the intestinal ileum of NEC [26]. TNF- α , IL-1 β , and IL-6 are main cytokines associated with inflammatory responses [35]. During the inflammatory response, TNF- α is initially released and regulates IL-6 levels [36]. Ulinastatin has been confirmed to have a strong anti-inflammatory effect [37–39]. Studies have found that ulinastatin inhibits TNF- α and IL-6 levels in sepsis [40,41]. In addition, ulinastatin inhibits lipopolysaccharide-induced up-regulation of TNF- α and macrophage-induced IL-1 β and IL-6 [42].

Ulinastatin may be resistant to diabetes-induced cardiomyocyte inflammation and apoptosis [43]. Therefore, our results demonstrated that ulinastatin could have potential anti-inflammatory properties in the intestine of NEC rats by reducing the activation of pro-inflammatory cytokines.

However, there are several limitations in this study. This was a study in an animal model, and the findings require further validation by both *in vitro* and *in vivo* studies and human toxicity testing. In 2008, Zani et al. evaluated the neonatal rat model of NEC. Although they found that this was a good model of macroscopic and histological intestinal damage, they cautioned that this was just a model and the findings did not reflect the pathogenesis of any specific human disease [19]. Importantly, premature rats are used in the model of NEC immediately after they are born and before the intestine has been colonized by bacteria, which is a limitation to the applicability of the rat model to clinical NEC. However, NEC occurs after approximately 7–10 days of age in humans, which is after the intestine has been fully colonized with intestinal flora [44]. Thus, there is no perfect animal model of human disease, which is why the findings should not lead to clinical recommendations without further clinical studies [45].

Conclusions

In our study, we observed the effects of ulinastatin in the treatment of neonatal NEC rat model. Our findings revealed that ulinastatin could ameliorate the severity of intestinal damage in NEC and possess anti-apoptosis and anti-inflammation effects on NEC.

Conflicts of interest

None.

References:

- Nino DF, Sodhi CP, Hackam DJ: Necrotizing enterocolitis: New insights into pathogenesis and mechanisms. *Nat Rev Gastroenterol Hepatol*, 2016; 13: 590–600
- Talavera MM, Bixler G, Cozzi C et al: Quality improvement initiative to reduce the necrotizing enterocolitis rate in premature infants. *Pediatrics*, 2016; 137(5): pii: e20151119
- Tanner SM, Berryhill TF, Ellenburg JL et al: Pathogenesis of necrotizing enterocolitis: Modeling the innate immune response. *Am J Pathol*, 2015; 185: 4–16
- MohanKumar K, Namachivayam K, Song T et al: A murine neonatal model of necrotizing enterocolitis caused by anemia and red blood cell transfusions. *Nat Commun*, 2019; 10: 3494
- Shen H, Lei Y, He X et al: Role of lactadherin in intestinal barrier integrity in experimental neonatal necrotizing enterocolitis. *J Cell Biochem*, 2019; 120(12): 19509–17
- Liu J, Li Y, Feng Y et al: Patterned progression of gut microbiota associated with necrotizing enterocolitis and late onset sepsis in preterm infants: A prospective study in a Chinese neonatal intensive care unit. *Peer J*, 2019; 7: e7310
- Xue R, Jiang J, Dong B et al: DJ-1 activates autophagy in the repression of cardiac hypertrophy. *Arch Biochem Biophys*, 2017; 633: 124–32
- Jilling T, Lu J, Jackson M, Caplan MS: Intestinal epithelial apoptosis initiates gross bowel necrosis in an experimental rat model of neonatal necrotizing enterocolitis. *Pediatr Res*, 2004; 55: 622–29
- Zhou Y, Li Y, Zhou B et al: Inflammation and apoptosis: Dual mediator role for Toll-like receptor 4 in the development of necrotizing enterocolitis. *Inflamm Bowel Dis*, 2017; 23: 44–56
- Gopalakrishna KP, Macadangang BR, Rogers MB et al: Maternal IgA protects against the development of necrotizing enterocolitis in preterm infants. *Nat Med*, 2019; 25: 1110–15
- Li B, Saka R, Takama Y et al: Recombinant human soluble thrombomodulin reduces the severity and incidence of necrotizing enterocolitis in a newborn rat model. *Surg Today*, 2019; 49(11): 971–76
- Tayman C, Aydemir S, Yakut I et al: TNF-alpha blockade efficiently reduced severe intestinal damage in necrotizing enterocolitis. *J Invest Surg*, 2016; 29: 209–17
- De Plaen IG: Inflammatory signaling in necrotizing enterocolitis. *Clin Perinatol*, 2013; 40: 109–24
- Liu W, Pang G, Wang S, Sun A: Protective effect of ulinastatin on severe pulmonary infection under immunosuppression and its molecular mechanism. *Exp Ther Med*, 2017; 14: 3583–88
- Zhao Y, Cai H, Zhou P et al: Protective effect of ulinastatin on hepatic ischemia reperfusion injury through autophagy activation in Chang liver cells. *J Cell Biochem*, 2019; 120: 14960–70
- Feng Z, Shi Q, Fan Y et al: Ulinastatin and/or thymosin alpha1 for severe sepsis: A systematic review and meta-analysis. *J Trauma Acute Care Surg*, 2016; 80: 335–40
- Han D, Shang W, Wang G et al: Ulinastatin- and thymosin alpha1-based immunomodulatory strategy for sepsis: A meta-analysis. *Int Immunopharmacol*, 2015; 29: 377–82
- Moggia E, Koti R, Belgaumkar AP et al: Pharmacological interventions for acute pancreatitis. *Cochrane Database Syst Rev*, 2017; 4: Cd011384
- Zani A, Cordischi L, Cananzi M et al: Assessment of a neonatal rat model of necrotizing enterocolitis. *Eur J Pediatr Surg*, 2008; 18: 423–26
- Doi K, Leelahavanichkul A, Yuen PS, Star RA: Animal models of sepsis and sepsis-induced kidney injury. *J Clin Invest*, 2009; 119: 2868–78
- Shiou SR, Yu Y, Chen S et al: Erythropoietin protects intestinal epithelial barrier function and lowers the incidence of experimental neonatal necrotizing enterocolitis. *J Biol Chem*, 2011; 286: 12123–32
- Pajares M, Rojo AI, Arias E et al: Transcription factor NFE2L2/NRF2 modulates chaperone-mediated autophagy through the regulation of LAMP2A. *Autophagy*, 2018; 14: 1310–22
- Neu J, Walker WA: Necrotizing enterocolitis. *N Engl J Med*, 2011; 364: 255–64
- Barlow B, Santulli TV: Importance of multiple episodes of hypoxia or cold stress on the development of enterocolitis in an animal model. *Surgery*, 1975; 77: 687–90
- Xiao S, Li Q, Hu K et al: Vitamin A and retinoic acid exhibit protective effects on necrotizing enterocolitis by regulating intestinal flora and enhancing the intestinal epithelial barrier. *Arch Med Res*, 2018; 49: 1–9
- Nakame K, Kaji T, Mukai M et al: The protective and anti-inflammatory effects of glucagon-like peptide-2 in an experimental rat model of necrotizing enterocolitis. *Peptides*, 2016; 75: 1–7
- Chatterton DE, Nguyen DN, Bering SB, Sangild PT: Anti-inflammatory mechanisms of bioactive milk proteins in the intestine of newborns. *Int J Biochem Cell Biol*, 2013; 45: 1730–47
- Fawley J, Cuna A, Menden HL et al: Single-immunoglobulin interleukin-1-related receptor regulates vulnerability to TLR4-mediated necrotizing enterocolitis in a mouse model. *Pediatr Res*, 2018; 83: 164–74
- Yuan Y, Ding D, Zhang N et al: TNF-alpha induces autophagy through ERK1/2 pathway to regulate apoptosis in neonatal necrotizing enterocolitis model cells IEC-6. *Cell Cycle*, 2018; 17: 1390–402
- Good M, Sodhi CP, Egan CE et al: Breast milk protects against the development of necrotizing enterocolitis through inhibition of Toll-like receptor 4 in the intestinal epithelium via activation of the epidermal growth factor receptor. *Mucosal Immunol*, 2015; 8: 1166–79
- Li P, Fu D, Sheng Q et al: TUDCA attenuates intestinal injury and inhibits endoplasmic reticulum stress-mediated intestinal cell apoptosis in necrotizing enterocolitis. *Int Immunopharmacol*, 2019; 74: 105665
- McElroy SJ, Castle SL, Bernard JK et al: The ErbB4 ligand neuregulin-4 protects against experimental necrotizing enterocolitis. *Am J Pathol*, 2014; 184: 2768–78
- Yan X, Managlia E, Liu SX et al: Lack of VEGFR2 signaling causes maldevelopment of the intestinal microvasculature and facilitates necrotizing enterocolitis in neonatal mice. *Am J Physiol Gastrointest Liver Physiol*, 2016; 310: G716–25
- Lim JC, Golden JM, Ford HR: Pathogenesis of neonatal necrotizing enterocolitis. *Pediatr Surg Int*, 2015; 31: 509–18
- Mann DL: Inflammatory mediators and the failing heart: Past, present, and the foreseeable future. *Circ Res*, 2002; 91: 988–98
- Kocabas E, Sarikcioglu A, Aksaray N et al: Role of procalcitonin, C-reactive protein, interleukin-6, interleukin-8 and tumor necrosis factor-alpha in the diagnosis of neonatal sepsis. *Turk J Pediatr*, 2007; 49: 7–20
- Liang Y, Peng Q, Wang K et al: A novel mutation in the SLC26A4 gene in a Chinese family with non-syndromic hearing loss and enlarged vestibular aqueduct. *Int J Pediatr Otorhinolaryngol*, 2018; 107: 97–100
- Liu D, Yu Z, Yin J et al: Effect of ulinastatin combined with thymosin alpha1 on sepsis: A systematic review and meta-analysis of Chinese and Indian patients. *J Crit Care*, 2017; 39: 259–66
- Luo Y, Che W, Zhao M: Ulinastatin post-treatment attenuates lipopolysaccharide-induced acute lung injury in rats and human alveolar epithelial cells. *Int J Mol Med*, 2017; 39: 297–306
- Yang B, Gao M, Wang K et al: Intraintestinal administration of ulinastatin protects against sepsis by relieving intestinal damage. *J Surg Res*, 2017; 211: 70–78
- Zhang Y, Chen H, Li YM et al: Thymosin alpha1- and ulinastatin-based immunomodulatory strategy for sepsis arising from intra-abdominal infection due to carbapenem-resistant bacteria. *J Infect Dis*, 2008; 198: 723–30
- Li ST, Dai Q, Zhang SX et al: Ulinastatin attenuates LPS-induced inflammation in mouse macrophage RAW264.7 cells by inhibiting the JNK/NF-kappaB signaling pathway and activating the PI3K/Akt/Nrf2 pathway. *Acta Pharmacol Sin*, 2018; 39: 1294–304
- Wang WK, Lu QH, Wang X et al: Ulinastatin attenuates diabetes-induced cardiac dysfunction by the inhibition of inflammation and apoptosis. *Exp Ther Med*, 2017; 14: 2497–504
- Sodhi C, Richardson W, Gripar S, Hackam DJ: The development of animal models for the study of necrotizing enterocolitis. *Dis Model Mech*, 2008; 1: 94–98
- Lu P, Sodhi CP, Jia H et al: Animal models of gastrointestinal and liver diseases. Animal models of necrotizing enterocolitis: Pathophysiology, translational relevance, and challenges. *Am J Physiol Gastrointest Liver Physiol*, 2014; 306: G917–28