

REVIEW: Current understanding of the pathogenesis of Fuchs' endothelial corneal dystrophy

Gargi Gouranga Nanda, Debasmitta Pankaj Alone

School of Biological Sciences, National Institute of Science Education and Research (NISER) Bhubaneswar, HBNI, P.O. Bhipur-Padanpur, Jatni, Khurda, Odisha, India

Fuchs' endothelial corneal dystrophy (FECD) is the most prominent reason for corneal-endothelial transplantations across the globe. The disease pathophysiology manifests through a combination of various genetic and non-heritable factors. This review provides a comprehensive list of known genetic players that cause FECD, and discusses the prominent pathological features that participate in disease progression, such as channel dysfunction, abnormal extracellular matrix deposition, RNA toxicity, oxidative stress, and apoptosis. Although current practices to correct visual acuity involve surgical intervention, this review also discusses the scope of various non-surgical therapeutics to remedy FECD.

Fuchs' endothelial corneal dystrophy (FECD, OMIM: 136800) is an age-related disorder that affects individuals, especially women, older than 40 years of age [1-3]. It typically follows an autosomal-dominant pattern of inheritance, with symptoms that include decreased visual acuity, hazy cornea, poor night-vision, and pain during blinking [1,2,4], that precipitate into progressive deterioration of the innermost layer of the cornea (endothelium) and wart-like excrescences (guttatae) on its surface. Although the primary cause of this disease is unknown, clinical samples exhibit significant endothelial cell loss, edematous cornea, and a thickening in the endothelial basement Descemet's membrane [4,5]. These manifestations disturb corneal deturgescence, resulting in suboptimal endothelial membrane function [6]. FECD is also the most frequent reason for corneal transplantations; more than 17,000 surgeries were performed in 2016 in the United States to correct edematous cornea associated with FECD (2016 Eye Banking Statistical Report, Eye Bank Association of America).

Two kinds of FECD manifestations are observed based on their age of onset: early onset FECD (3 to 40 years) and late onset FECD (older than 40 years). Each evinces distinct clinical differences [7-9]. In comparison to the 3- to 9- μ m total thickness of Descemet's membrane in infants [10], early onset FECD cases show the thickest Descemet's membrane

of about 35 μ m with deeper and discontinuous corneal guttae [8]. However, late onset FECD cases have slightly increased thickening of Descemet's membrane (22 μ m), but with generally shallow and continuous guttae, and an additional posterior banded layer in comparison to that of healthy elderly adults with 12- to 19- μ m-thick Descemet's membrane [8,10,11]. Owing to these manifestations, early onset FECD is considered the more severe of the two, and although rare, is inherited solely in individuals with a familial predisposition. Late onset FECD is, in comparison, less severe and more frequent, and inherited sporadically.

This review discusses various risk factors, and their pathological contribution associated with the progression of FECD. The review also focuses on recent advances in surgical and noninvasive techniques developed to restore vision deprived due to the disease. Finally, the review draws attention to unanswered questions, the answers to which would improve the current understanding of FECD.

Prevalence: Owing to the late onset nature and variable clinical presentation, diagnosis of FECD at an early stage is difficult. This limits the availability of accurate prevalence or incidence figures for the disease. A global survey conducted across 116 countries reported that most of the corneal transplantations (39% of 184,576) performed in 2012 were to correct FECD alone [12]. Such procedures were most frequently observed in countries such as the United States, Canada, Denmark, and the United Kingdom. According to a statistical report released by the Eye Bank Association of America (EBAA) for 2016, FECD accounted for 93% of the total corneal transplantations performed to correct endothelial

Correspondence to: Debasmitta Pankaj Alone, School of Biological Sciences, Molecular Genetics Laboratory, NISER, P.O. Bhipur-Padanpur, Jatni, Khurda, Odisha, India 752050; email: debasmitta@niser.ac.in

cell failure (2016 Eye Banking Statistical Report, Eye Bank Association of America).

Several prevalence studies over the past few decades have reported a high incidence of FECD in Caucasians. In one of the earliest studies, scientists categorized the severity of corneal guttae on a scale of 0–5 (0 being the least severe and 5 being the most severe), by observing their density through a slit-lamp microscope [13]. They reported that about 3.9% of Americans older than 40 years of age had Grade 2 (1- to 2-mm confluent zone of corneal guttae) or more severe cases of corneal guttae. Only occasional cases of primary corneal guttae progress to exhibiting decompensated endothelium and thickened Descemet's membrane [14], which serve as an essential clinical hallmark for a predisposition to FECD. When Krachmer and colleagues examined 228 relatives of 64 FECD probands, they found 37% (49/132) were older than 40 years of age, and had Grade 2 or worse edematous corneal endothelial dystrophy [15]. Both studies equivocally reported a strong correlation between increasing severity and age, and a higher susceptibility among Caucasian women. In a survey conducted on Tangier Island, in the United States, researchers reported that 11% of the entire population (535 inhabitants as of 2011) had FECD, and all those affected were older than 50 years of age [16]. Researchers conducting a cohort study in Reykjavik, Iceland, also declared similar prevalence rates, where more women (11%) than men (7%) had primary corneal guttae [17].

Contrasting with Caucasians, in whom the prevalence of FECD is starkly higher, Asian populations show fewer cases of FECD. The Kumejima study in Japan recorded the lowest FECD prevalence: Only 4% (124/3060) of the population older than 40 years had Grade 1 or higher primary corneal guttae [18]. In a comparative study between two Asian populations, researchers found that about 6.7% of Chinese Singaporeans (n=465) and 3.7% of Japanese (n=299) were older than 50 years and had primary corneal guttae [19]. India has the second highest rate for per-capita corneal transplantations performed globally [12]: About 11–16% of endothelial keratoplasty procedures were performed on FECD cases over a span of 5 to 6 years [20,21]. From these studies, late onset and female dominance for FECD have been established; however, the reason is not completely understood.

Genetics of FECD: FECD is a multigenic disorder that imparts complex pathophysiology. These diverse genetic factors either develop sporadically or have a familial predisposition. To identify these factors, researchers have resorted to two different techniques: genetic linkage analysis and genome-wide association studies (GWASs). The former examines multigenerational families with at least more than

one affected member to identify the chromosomal region co-inherited among affected individuals. GWASs use data from a large cohort of non-related individuals with and without the disease to identify specific genetic variants associated with the disease phenotype.

Thus far, researchers have identified eight different genetic loci that cosegregate with FECD, either through linkage analysis or a GWAS (Appendix 1). The International Committee for Classification of Corneal Dystrophies (IC3D) categorized these loci into FECD 1–8 [22]. Genes encoding collagen (*COL8A2*; OMIM: 120252), transcription factors (*TCF4*, OMIM: 602228, *ZEB1*, OMIM: 189909), sodium borate transporter (*SLC4A11*; OMIM: 610206), and glutamate decarboxylase (*AGBL1*; OMIM: 615496) fall under the loci FECD1, 3, 6, 4, and 8, respectively, although researchers have yet to identify genes from the remaining loci.

Increasing genetic complexity and cost-effective genotyping techniques have resulted in several projects identifying new risk factors for FECD. Genes, such as *KN motif and ankyrin repeat domains 4* (*KANK4*; OMIM: 614612), *ATPase Na⁺/K⁺ transporting subunit beta* (*ATP1B1*; OMIM: 182330), *laminin subunit gamma 1* (*LAMC1*; OMIM: 150290), *lipoxygenase homology domains 1* (*LOXHD1*; OMIM: 613072), and *myotonic dystrophy type 1 protein kinase* (*DMPK*; OMIM: 605377), were recently identified through a GWAS, linkage analysis, or candidate gene studies [23,24,25]. However, these genes have not been unclassified by IC3D into individual FECD loci. In the following subsections, each genetic factor is discussed in short summaries.

COL8A2—Multigenerational familial studies discovered the first FECD locus at the chromosomal position 1p34.3–p32.3 (FECD1), where researchers identified pathogenic mutations in the collagen gene *COL8A2* (Appendix 1) [26–33]. Mutations positioned in the triple helical domain of $\alpha 2$, p.Leu450Trp and p.Gln455Lys, alter the structure and composition of Descemet's membrane, leading to the early onset type of FECD [28,29,31]; the latter mutation is present in almost all the early onset cases in English and Korean populations [28,31]. Endothelial guttae, aberrant collagenous deposition, and swollen endoplasmic reticulum (ER) were characteristic of a homozygous mutant (p.Gln455Lys/p.Gln455Lys) mouse model for early onset FECD [34]. Other mutations identified in different studies were either polymorphic or non-pathogenic [27,29,30]. These studies provided a crucial insight into the phenotypic repercussions on the corneal endothelium of accumulated mutations in *COL8A2*, and can help devise better preventive measures to curb disease progression. Despite various attempts, researchers have failed to identify any mutations and polymorphisms in the *COL8A2*

gene among late onset FECD cases, suggesting its genetic involvement is exclusive to early onset cases [27,35].

TCF4—*TCF4*, encodes E2–2 protein, a group of E protein transcription factors known for cellular growth and differentiation, and is the only gene studied extensively in FECD cases from various ethnic backgrounds. After performing a GWAS, Baratz and colleagues first identified a strong association between the polymorphic marker rs613872 within an intron of the *TCF4* gene and FECD [36]. This association was later confirmed by several replication studies in American [16,37] and Australian [38,39] ethnic populations, but was not polymorphic among Chinese, where two other polymorphisms, rs17089887 and rs17089925, in close linkage disequilibrium (LD) with each other, were found to be associated with FECD [40]. Subsequent studies reported a microsatellite region comprising CTG trinucleotide repeats (TNRs) in the fourth intron of the *TCF4* gene to be abnormally expanded and segregated among most patients with FECD. This genetic signature for FECD is most prominent in Caucasians, with 80% penetrance [41,42], followed by Germans (77% [43]), Australians (51% [44]), and Asians (Chinese, 43% [45], and Indians, 34% [46]).

SLC4A11—FECD shares several phenotypic similarities with other endothelial (posterior) corneal dystrophies, such as congenital hereditary endothelial dystrophy (CHED, OMIM: 121700) and posterior polymorphous corneal dystrophy (PPCD, OMIM: 122000) [47,48]. Therefore, it is convenient to hypothesize that clinical manifestations of these corneal dystrophies may share modifications of similar genes [49,50].

SLC4A11 is the only member of the solute carrier 4 (SLC4) borate transporter family of proteins that conducts Na⁺-coupled H⁺ flux and OH⁻ transport [51]. Scientists have also reported the active participation of SLC4A11 in water resorption through the basolateral surface of the endothelium to maintain deturgescence [52]. Mutations in this protein result in either a swollen cornea, in the case of corneal dystrophies, such as CHED (OMIM: 217700) [53] and FECD4 (OMIM: 613268) [50,54], or fluid imbalance in the inner ear, in the case of the hearing disorder Harboyan syndrome (OMIM: 217400) [49]. Therefore, it is not surprising to find hearing disabilities in patients with corneal dystrophies [49,55]. In an Indo-Chinese FECD cohort, four likely loss-of-function mutations in *SLC4A11* (p.Glu399Lys, p.Gly709Glu, p.Thr754Met, and c.99–100delTC) were uncovered by Vithana et al. [56].

A comparative assay between FECD and CHED-causing *SLC4A11* mutants in transformed human embryonic kidney (HEK) cells revealed that FECD mutants (p.Glu399Lys, p.Gly709Glu, and p.Thr754Met) in heterozygous condition

drastically reduced the cell surface population of wild-type SLC4A11 proteins. In contrast, the cell surface efficiency of wild-type (WT) SLC4A11 proteins is unaffected by the coexpressing CHED2-causing mutants (p.Glu143Lys, p.Cys386Arg, and p.Arg755Trp) [57]. ER retention of WT/FECD heterodimers explains the dominant nature of FECD. Given the differences, the two diseases also share a similar phenotype when these mutants are expressed homozygously, and the mutant homodimers are intracellularly retained, leading to a severely dysfunctional corneal endothelial pump function. Further studies to strategize methods that can rescue these phenotypes (to an extent) by supplementing wild-type SLC4A11 peptides may help these patients avoid corneal transplantation.

ZEB1—Similar to *SLC4A11*, mutations in the transcription factor *Zinc finger E-Box binding homeodomain 1* (*ZEB1*) have been associated by researchers with FECD6 (OMIM: 613270) and posterior polymorphous corneal dystrophy (PPCD3, OMIM: 609141). Nonsense or truncating mutations identified in this gene are a significant contributor for PPCD, which is more severe than FECD [58–61]. As FECD has phenotypic similarities to PPCD, scientists also found missense mutations in FECD case-control studies, some of which were intolerant according to Sorting Intolerant From Tolerant (SIFT) and PolyPhen analysis (Appendix 1). Of these mutations, p.Gln840Pro cosegregated with the FECD7 (OMIM: 613271) locus on chromosome 9 in a multigenerational family, and increased disease severity in 7/12 individuals [58]. These studies suggested that PPCD and FECD could be allelic variants of a continuum of diseases in which genes interact to modulate the expressivity of the phenotype [58].

AGBL1—*ATP/GTP binding protein-like 1* (*AGBL1*) is a deglutamylase enzyme, which removes polyglutamate residues during post-transcriptional modification of proteins. *AGBL1* was identified as a candidate gene during serial analysis of gene expression (SAGE) analysis of FECD tissues where the gene's transcript levels differed significantly from those of the control specimens [62]. To find a unique genetic candidate for FECD, scientists performed linkage analysis in a multigenerational family, and found a nonsense mutation (p.Arg1028X) in the *AGBL1* gene that partially cosegregated with FECD. Upon scanning the entire gene, the authors also found a missense mutation, p.Cys990Ser, unique to the FECD cohort. Both mutations ablated the interaction between *AGBL1* and *TCF4* proteins [63], the exact nature of which is open for investigation. This study led to identifying the associated genetic loci as *FECD8* (OMIM: 615523). *AGBL1* also surfaced in the latest GWAS study with a modest association

[23]. Due to lack of replication studies in other cohorts that can substantiate the presence of these mutations in FECD-affected individuals, the true contribution of the *AGBL1* gene in causing this disease is open for further investigation.

KANK4, LAMC1, and ATP1B1—In addition to *TCF4*, a subsequent GWAS conducted by Afshari et al. (with 1,404 European FECD cases and 2,564 age- and race-matched controls) identified three novel loci, [rs79742895](#) (*KANK4*), [rs3768617](#) (*LAMC1*), and [rs1200114](#) (*ATP1B1*) linked with FECD [23]. These corresponding genes aid in maintaining corneal deturgescence by regulating routine fluid transport, intercellular contact, and tissue integrity. Improper functioning of these activities could lead to FECD-like symptoms. Therefore, replication studies in other populations and investigations to explore the genes' role in the disease pathomechanism are warranted (**Appendix 1**).

LOXHDI—The protein encoded by *lipoxigenase homology domains 1* (*LOXHDI*) is involved in sensory perception of sound, and targeting other proteins to the plasma membrane. Therefore, missense mutations affecting the conserved domains lead to a progressive form of auditory defect: autosomal recessive deafness (*DFNB77*, OMIM: [613079](#)) [64,65]. When scientists investigated the FECD3 locus (previously designated as FECD2) in a multigenerational pedigree, they found a missense mutation in *LOXHDI* to be the sole causative factor for the disease phenotype [24]. They further found 15 more unique missense mutations in a larger cohort of 207 unrelated patients with FECD, which were absent in 384 control chromosomes. Three of these mutant proteins (p.Arg157Cys, p.Arg547Cys, and p.Arg751Trp) formed intracellular aggregates in in vitro transformed cells. As the study could not provide one allele in the *LOXHDI* gene that cosegregated in the FECD pedigree, replication studies are necessary to associate the variants in this gene with the disease. Therefore, IC3D has not included *LOXHDI* as an official genetic candidate in the FECD3 locus.

DMPK—Expanded repeats in the 3'-untranslated region (UTR) of the *dystrophia myotonica-protein kinase* (*DMPK*) gene cause the neurodegenerative disorder myotonic dystrophy type 1 (DM1). Other disorders that are the result of repeat expansions in non-coding regions of associated genes include myotonic dystrophy (DM1 and DM2), fragile X-associated tremor/ataxia syndrome (FXTAS), and *C9ORF72* (OMIM: [614260](#)) associated amyotrophic lateral sclerosis and frontotemporal dementia (*C9ORF72* ALS/FTD). Owing to FECD's association with the expanded repeats in *TCF4*, the disorder is now categorized as a trinucleotide-repeat expansion disorder. In a comorbidity study-type setting, researchers investigated 13 patients with DM1, and reported that 46%

also had FECD. This finding indicates that apart from *TCF4*, individuals with FECD could also harbor expansions elsewhere in genome, in this case, the *DMPK* gene, thus making it a novel genetic candidate for FECD [25,66]. With further studies, other repercussions of these expansions in non-ocular tissues can be assessed.

Non-heritable risk factors: FECD is a complex disorder that is hypothesized to progress due to the combined effect of genetic and environmental risk factors. Recognizing these factors will profoundly benefit patients and clinicians to avert or dampen disease progression. Apart from genetic players, the most consistent risk factors are age and gender, where individuals older than 40 years and women are most susceptible to this disease [67]. A recent GWAS provided the first evidence of gender-specific genetic risk factors, where the associated genes *TCF4* and *LAMC1* imparted higher FECD risk in men and women, respectively [23]. However, it is unclear why this discrepancy exists.

Smoking is another factor that researchers have consistently associated with increasing FECD severity. In the Reykjavik eye study, scientists found that Icelanders who smoked 20 or more cigarette packs per year doubled their risk of having corneal guttae older than 50 years of age [17]. In another study, scientists reaffirmed this association in Americans, and reported that smoking increased their chances of having FECD by 30% [67]. Other factors assayed in these studies included exposure to ultraviolet (UV) light, diabetes, bodyweight, and body-mass index (BMI). Reports indicated that although previous exposure to UV light for more than 4 h daily (when younger than 50 years) can lead to lens opacification [68], the exposure does not increase the chances of developing corneal guttae [17]. These reports rejected the speculations drawn from the prevalence data that tropical countries are prone to higher FECD prevalence due to intensive UV exposure. Researchers also showed an independent association of diabetes with increased central corneal thickness, but the association did not affect FECD severity [67]. However, higher bodyweight and BMI acted as protective factors that reduced the chances of developing corneal guttae [17].

Interpreting the molecular mechanism: Each of these risk factors, both genetic and environmental, individually contribute to disease progression, thus making the pathomechanism of FECD complex. In the following sections, the known molecular pathways affected during FECD are discussed.

Channelopathy and pump dysfunction—The primary function of the cornea is to maintain deturgescence, which is corneal hydration, thickness, and transparency. The corneal

endothelium plays a significant role in carrying out this function; therefore, deterioration of the corneal endothelium can cause the characteristic corneal edema seen in FECD.

Aqueous humor present in the anterior chamber (the space between the cornea and the lens) bathes the cornea with solutes and nutrients, which leaks through the selective barrier of endothelial cells into the avascular cornea [69]. Corneal stroma tends to absorb water, which flows through the endothelium driven by the intraocular pressure. Acting like a hydrogel, the endothelium must strike a balance between water imbibing and pumping out, to avoid stromal swelling. Swelling pressure isotherm maintains this equilibrium [70]. When this isotherm is disturbed, the stroma gorges an unquantified amount of aqueous humor that increases the inter-collagen-fibrillar distance, and causes corneal opacification. A healthy stroma counteracts this uncontrolled swelling by implementing the pump leak system of the endothelium [71]. The presence of active Na-K ATPase pumps on the endothelial surface drains the excess aqueous humor when it senses increased stromal pressure, by lowering osmolarity at the basolateral endothelium [71,72]. A dysfunctional pump and barrier system can disturb the corneal deturgescence, and cause edema. FECD is a case of channelopathy where disease-causing mutations accumulate secondary outcomes where ion channels, such as solute carrier family 4 member 11 (SLC4A11), Na⁺, K⁺ transporting ATPase (Na⁺/K⁺ ATPase), aquaporin 1 (AQP-1), and monocarboxylate transporters (MCTs), either are dysfunctional or are less populated on the cell membrane.

SLC4A11 is a densely populated corneal endothelium (CE) membrane borate pump [52]. Its malfunction has been associated with numerous endothelial dysfunctions, such as CHED [53], FECD [50,57], and sensorineural hearing disorder [73]. The majority of the FECD-associated mutations (p.Glu399Lys, p.Gly709Lys, and p.Thr754Met) in this gene are housed in structurally conserved residues [74], which result in loss of function due to ER retention of these misfolded proteins [75]. Other mutations (Gly709Glu) cause membrane expression of partially functional SLC4A11 [57]. Methylation studies also indicated decreased membrane expression of SLC4A11, due to hypermethylation of its promoter in FECD tissues [76]. It ultimately results in failed transport of Na⁺ coupled OH⁻ transport [51], and NH₃:2H⁺ cotransport [77]. Recent studies have reported that ammonia transported by SLC4A11 is essential for ATP generation via glutaminolysis using the Na⁺/K⁺ ATPase system [78], which, in turn, acts as an accessory energy source for the corneal endothelium. Therefore, stripping off the functional units of this membrane protein puts the endothelium under tremendous pressure that

initiates a cascade of downstream pathological effects leading to its apoptosis [79].

Na⁺/K⁺ ATPase is a holoenzyme with two components: subunits α_1 and β_1 , present in the basolateral region of the corneal endothelium. Abundant transcripts of the β_1 subunit are necessary to assemble functional enzyme molecules in the ER [80,81]. The β_1 encoding gene, *ATP1B1*, is genetically associated with FECD [23]. A significant drop in its transcript level showed a steady decline in the Na⁺/K⁺ ATPase density in late onset FECD endothelial cells [82,83]. In neuronal cell lines, researchers induced *nuclear respiratory factor 1* (*NRF-1*) by administering potassium chloride to successfully restore the expression of Na⁺/K⁺ ATPase subunits [84]. Topical application of steroids, such as dexamethasone, on corneal endothelial cells also increased the expression and activity of Na⁺/K⁺ ATPase [85]. These molecules can be used as potential pharmacological interventions to improve the condition of energy-deprived endothelial cells of patients with FECD.

Other endothelial pump systems significantly downregulated in FECD tissues are aquaporin AQP-1 [86,87] and the monocarboxylate transporters MCT1 and MCT4 [83]. When epigenetic signatures were studied, researchers found that most of the water transport and fluid transport genes were hypomethylated in their gene bodies in FECD tissues [76]. These reports cumulatively indicated that the FECD condition severely curbs the basic functioning of the endothelium by reducing the expression of channel proteins.

Epithelial to mesenchymal transition—Corneal endothelial lining and stroma secrete a patterned layer of extracellular matrix (ECM), called Descemet's membrane. In a healthy infant cornea, banded fibrils on the anterior zone of Descemet's membrane are the thickest, and apparently, then maintain the thickness [10]. In the case of an endotheliopathic cornea like that in FECD, scientists have reported excessive collagenous and fibrillar deposition [11], which reflects as wart-like excrescences under the slit-lamp microscope [8]. Extensive studies on the structure and composition of Descemet's membrane in FECD have reported significant upregulation of several ECM components, such as collagen subtypes I, III, and XVI; fibronectin; and agrin [88,89]. The initial pathogenic indication of FECD involves thick deposition of fibronectin, followed by deregulated expression of laminin and type IV collagen in the posterior face of Descemet's membrane in advanced stages [88].

Although the reason for excessive ECM deposition on Descemet's membrane is obscure, researchers believe that epithelial-mesenchymal transition (EMT) inducer genes might be responsible. During advanced stages of degeneration, the

corneal endothelium undergoes fibroblastic changes, such as abnormal deposition of fibrotic ECM, without changing its endothelial phenotype [90]. Investigations on immortalized FECD lines suggested that increased ZEB1 and Snail1 proteins lead to excessive ECM production through the transforming growth factor beta (TGF- β) pathway. Both proteins mediate EMT in various tissues [91]. After supplementing the immortalized FECD (iFECD) cells with inhibitors for TGF- β type I, researchers could suppress ECM overexpression [92]. There are also reports about the overexpression of TGF- β induced protein (TGF- β Ip) and clusterin (CLU) in the corneal endothelium [38,89,93]. These initial insights into progressive alterations in the ECM deposits by the FECD-affected endotheliopathic cornea have broadened our current understanding of the pathology to develop therapeutic targets against it.

RNA toxicity and RAN translation—The association of *TCF4* expansion repeats with FECD has provoked three burning questions among researchers: 1) What is the underlying pathological mechanism? 2) What is the copy number of repeats that cause toxicity? 3) Does the TNR affect *TCF4* expression? The pathological outcomes of repeat-expansion diseases can be explained by two distinct mechanisms: the toxicity of RNA repeats and the toxicity of repeat-associated non-ATG (RAN) translation, or a combination of the two. Whether these pathological pathways are coregulated in FECD is still an open-ended question.

The post-transcriptionally processed repeat expansions sequester splice-machinery proteins, such as MBNL1 and MBNL2, which physically appear as RNA foci in FECD cells [25,94,95]. This sequestration alters the concentration of correctly spliced transcripts of their target genes. FECD shares these pathological events with myotonic dystrophy type 1 (DM1) where expanded CTG trinucleotide repeats (present in the 3'-UTR of the *DMPK* gene) sequester MBNL1 into RNA foci, and cause abnormal RNA processing [96,97]. RNaseq transcriptome analysis performed with FECD and control tissue samples identified 18/24 overlapping transcriptional events with DM1 splicing changes [94]. Further, the reports of the *DMPK* expansions observed in FECD cases [25,66] have confirmed FECD as a TNR-mediated RNA pathology disorder. Future studies are essential to investigate the impact of the repeat expansions in the *DMPK* and *TCF4* genes on the severity of FECD.

Researchers have performed multiple tests to identify the disease-causing threshold of TNRs in FECD. In the first few studies, an arbitrary limit of 50 TNRs was considered disease-causing. Using fluorescence in situ hybridization (FISH) and multiple cell lines with varying copy number

genotypes, researchers have ascertained that >32 TNRs is sufficient to form RNA foci in nuclei [98,99]. However, validating these pathological thresholds in FECD tissues in the future will help provide more insights. Owing to the TNRs' nature as a master regulator of genes, researchers have also explored the possibility of non-coding TNR expansion to modulate *TCF4* expression. They speculated that these non-coding expanded repeats would result in insufficient TCF4 to regulate the expression of essential genes and transcription factors, and cascade down to cause FECD [36,100,101]. However, given the complex transcript variants of *TCF4*, it is difficult to ascertain the same.

Alternatively, these expanded repetitive stretches of nucleotides elicit RAN translation, in which it allows the ribosomes to translate the expanded repeats in multiple reading frames to produce multiple homopolymeric or dipeptide repeat-containing proteins. The RAN peptides thus produced can disrupt cellular functions by forming nuclear and cytoplasmic inclusions that contribute to disease pathogenesis through various mechanisms, including proteasome impairment, endoplasmic reticulum stress, nucleolar stress, nucleocytoplasmic transport defects, alterations of the nuclear lamina, mis-splicing, mitochondrial dysfunction, and oxidative stress [102-105]. Recent evidence of RAN translation products in FECD-affected corneal tissues having expanded CTG repeats [106] has put FECD in the types of other repeat expansion disorders, such as spinocerebellar ataxia types 8 (SCA8), SCA31, familial forms of amyotrophic lateral sclerosis, frontotemporal dementia, fragile X tremor/ataxia syndrome (FXTAS), Huntington disease (HD), and myotonic dystrophy type 2 (DM2). The toxicity induced by the RNA and protein gain of function mechanism has resulted in these serious neurodegenerative disorders, whereas apart from atrophied corneal endothelial cells, neurodegeneration in FECD has not been reported.

Mitochondrial pathology—Corneal endothelial cells are metabolically demanding due to the constant flux of ions and fluids; thus, these cells are the most populated with mitochondria in comparison to all other ocular tissues. FECD is a result of heightened oxidative stress in decompensated corneal endothelial cells with an inefficient mitochondrial system [107]. Features pathognomonic of compromised mitochondria in iFECD lines and ex vivo specimens include increased mitochondrial DNA damage, decreased mitochondrial membrane potential, and mitochondrial fragmentation [108,109].

Electron microscopy of the FECD endothelium showed that the remaining mitochondria in the surviving cells were overtaxed, to produce cytochrome oxidase activity products

[110]. These mitochondria fail to recover entirely from an external oxidative insult (such as exposure to hydrogen peroxide or menadione) compared to their healthy counterparts [108]. These overburdened mitochondria succumb to mitophagy (mitochondrial fragmentation), owing to decreased Mitofusin-2 (Mfn2) expression, which is necessary to maintain a healthy mitochondrial turnover [109]. The mitochondrial transcripts, essential to curb the increased reactive oxygen species (ROS), are also depleted systematically in FECD [62], which could be a consequence of their hyper-methylated promoters [76].

To salvage the surviving endothelial cells, it is necessary to stop the rapid decline of the mitochondrial mass in these cells. Therefore, researchers are targeting to stabilize cardiolipin (a phospholipid present in the inner mitochondrial wall) to restore ATP production. Elamipretide is a synthetic mitochondria-targeted tetrapeptide (SS-31) that ameliorates mitochondrial dysfunction by preventing peroxidation of cardiolipin [111]. Stealth Biotherapeutics is in Phase II trials to test the efficacy of this drug on patients with FECD (ClinicalTrials.gov Identifier: NCT02653391).

Oxidative stress response and apoptosis—Due to the localization and function of the cornea, it is regularly exposed to sunlight and atmospheric oxygen, mainly dioxygen, which produce ROS. Oxidative stress response in FECD is a consequence arising from the accumulation of mutations, channelopathy, ER stress, and RNA toxicity. When cells fail to clear the excessive ROS adequately, an imbalance is created in the oxidant–antioxidant level that elevates oxidative stress. Primary cellular scrubbers (antioxidants) that clean oxidative waste products are superoxide dismutases (cytosolic and mitochondrial), catalase, glutathione peroxidase, and glutathione reductase. Their transcript levels are severely low in FECD cases [62]. The transcription factor NRF2 plays a significant role in the expression of these antioxidants during an oxidative insult. When in the cytosol, NRF2 is in the inactive state as the NRF2-KEAP1 complex. Upon oxidation, active NRF2 dissociates and translocates to the nucleus with a transcriptional coactivator and stabilizer molecule, DJ-1 (also known as PARK7; Parkinsonism associated deglycase) [112]. In FECD cells, DJ-1 levels are severely decreased, which, consequently, fail to activate the antioxidant genes [113]. In addition, depletion of SLC4A11 from the cell surface affects cell viability and NRF2 functionality [114]. Targeting these genes to thwart corneal degeneration will be therapeutically beneficial [115,116].

Unfolded protein response (UPR) also elevates oxidative stress in FECD specimens, which is evident from the rough and enlarged endoplasmic reticulum of the endothelial cells

[117]. Deregulated transcript levels of UPR markers, such as *GRP78* (OMIM: 138120), *phospho-eIF2 α* (OMIM: 609234), *CHOP* (OMIM: 126337), *EDEM3* (OMIM: 610214), *SCAP* (OMIM: 601510), *SEL1L* (OMIM: 602329), *HSPA5* (OMIM: 138120), and *PFDN5* (OMIM: 604899), in the affected tissues further validate this finding [83,117]. Activation of UPR can be due to several reasons: accumulation of misfolded mutant proteins, inefficient anterograde/retrograde transportation, and oxidative imbalance. These processes are the result of genetic or environmental predisposition. Although it is not essential for them to co-occur, individually or in combination, they can cause oxidative stress and apoptosis of the endothelial cells, a feature quite evident in every FECD specimen examined thus far.

In previous sections, how various mutations in the conserved regions of *SLC4A11* (failed surface-localization), *LOXHD1* (cytoplasmic aggregates formation), and *COL8A2* (recreation of early onset FECD phenotype in the knock-in mouse model) lead to FECD phenotype through ER retention was discussed [24,34,56]. Although these mutations share only a limited genetic load to cause FECD, repercussions of UPR are evident in every FECD affected tissue sample. Okumura and colleagues addressed this by reporting an enhanced expression of TGF- β isoforms (*TGF- β 1* OMIM: 190180 and *TGF- β 2* OMIM: 190220) and their receptors (*TGF- β R1* OMIM: 190181 and *TGF- β R2* OMIM: 190182), which chronically overload the ER with ECM proteins (fibronectin and collagen type 1), and consequently, elicit UPR and apoptotic pathways [118]. Targeting these receptors with therapeutic inhibitors to block the TGF- β pathway has suppressed aggresome accumulation and apoptosis in iFECD lines [118].

Oxidative stress in these decompensated endothelial cells tends to accumulate irreparable DNA damage, such as oxidative DNA lesions (8-hydroxy-2'-deoxyguanosine) [107]. Such damage stops the proliferative capacity of these cells, and leads to premature senescence and p53-mediated apoptosis [119]. Reports suggested that cells overexpress clusterin in response to cytotoxic stress in early and late onset FECD [120]. Researchers also speculated that the accumulation of extracellular clusterin and TGF- β Ip in cells are likely to scavenge the aberrant ECM to promote intercellular cell-substratum adhesive interactions, and maintain integrity in the disease-stricken decaying tissue [93,121,122].

To summarize, various genetic and environmental stressors accumulate spontaneous mutations over a period. Depending on the site of mutagenesis, they can lead to cell toxicity (aberrant protein folding), nuclear toxicity (RNA foci formation), or deregulation of essential genes involved

in maintaining crucial corneal endothelial functions, such as hydration, fluid flux, mitochondria-mediated ATP generation, DNA repair, and antioxidant production. One or several of these events can co-occur, to bring out the pathophysiological etiology of FECD (Figure 1). Understanding the pathomechanism can allow investigators to design symptom-specific therapeutics that can avert or delay the progression of FECD.

Contemporary treatment procedures for FECD: Patients with FECD often complain of blurred vision, light scattering, watery eyes, and corneal haze. As these symptoms worsen in the sixth to seventh decade of life, corneal transplantation becomes inevitable. Previously, surgeons performed penetrating keratoplasty (PK) to replace the entire thickness cornea. However, this gold-standard technique has limitations: long visual recovery, persistent epithelial defect, suture trauma, and recurrent refractive surgery to correct postoperative ametropia. For the past two decades, ophthalmologists around the world have practiced modifications of endothelial keratoplasty (EK), where only the endothelial layer is replaced, or descemetorhexis, in which only Descemet's membrane is stripped off.

Current surgical techniques—Surgical modifications of endothelial keratoplasty include posterior lamellar keratoplasty (PLK), deep lamellar endothelial keratoplasty (DLEK), (femtosecond) Descemet stripping (automated) endothelial keratoplasty (DSEK/DSAEK/FS-DSEK), and Descemet membrane endothelial keratoplasty (DMEK). DSAEK has been the treatment choice in the past decade for patients with endothelial failure. This technique has decreased the rejection rate, intraoperative and postoperative complications, and astigmatism, and produced faster visual recovery with more consistent results, compared with PK [123-125]. In DMEK, Descemet's membrane, along with the endothelium, is replaced [126]. This technique has improved outcomes over DSAEK in rejection rates and visual recovery, but is not recommended in all cases of endothelial dysfunction. In addition to these techniques, Descemetorhexis without EK has recently been employed to treat FECD [127-129].

Non-surgical interventions—Although surgeons have improved on the postoperative challenges, surgical procedures are always physically and mentally arduous, with the patient having to bear the shortcomings in their twilight years. Koizumi and colleagues effaced these surgical pitfalls when they introduced a revolutionary eye drop formula containing a Rho-kinase (ROCK) inhibitor (Y-27632) that completely regenerated the apoptotic and terminally differentiated corneal endothelial cells in monkeys to restore vision [130].

Okumura and colleagues scrapped off the corneal endothelial layer to demonstrate a corneal endothelial dystrophy animal model, and injected cultured monkey corneal endothelial cells (MCEncs), suspended in culture media supplemented with Y-27632 (ROCK inhibitor), into the anterior chamber. After allowing the cells to settle for 3 h in the face-down anesthetized monkey, they observed a reattached endothelium through the slit-lamp microscope. When monitored for a year, these healthy endothelial cells restored vision and maintained transparency, without any side effects of the drug in the monkeys. The researchers found similar results for implanting human corneal endothelial cells (HCEncs) in these primates [131].

After obtaining necessary approval from institutional committees to use Y-27632 in eye drops for treating corneal endothelial dystrophies in humans, the researchers administered this eye drop (6 times daily for 7 days) to a 52-year-old male Japanese patient with advanced FECD [130]. At follow-up after 6 months, the patient showed pronounced improved vision. Although there were no side effects for 2 years, the endothelial cells did not repopulate on the guttae. Randomized clinical trials are necessary before this drug can be used. Even with these reservations, applications of ROCK inhibitor as a potential noninvasive therapy for FECD is promising. ROCK inhibitor (Y-27632) eye drops uplift the mitotic block to regenerate the patient's endothelial cells in situ. A recent review summarized the potent therapies for FECD [132].

However, if the regenerated endothelial cells develop pathogenic nuclear foci due to expanded TNRs, an unhealthy layer of endothelium will repopulate, which might degenerate over time. Hu and colleagues addressed this issue by administering antisense oligonucleotides against expanded CUG repeats (within TCF4 pre-mRNA) to block RNA foci in patient-derived cells [133]. Post-treatment, these cells significantly reduced the number of RNA foci, and partially restored the alternative splicing events of *MBNL1*, *IN2*, and *ADD3* genes; however, it remains to be seen whether RNA foci by itself are pathogenic, or bring about their effect through RAN peptides. Both methods, ROCK inhibitor eye drops and antisense oligonucleotides, are promising, noninvasive therapeutic techniques, and it remains to be seen whether if used in combination, they can overcome each other's limitations.

Unanswered questions: Most of the literature discussed in this review comprised genetic information biased to Caucasians with American and European descent. Whereas extensive reports have suggested ethnic diversities impart significant impact across the globe [134-139]. Several replication studies have observed differences in allele distribution for polymorphic disease markers in different populations [40,46,140].

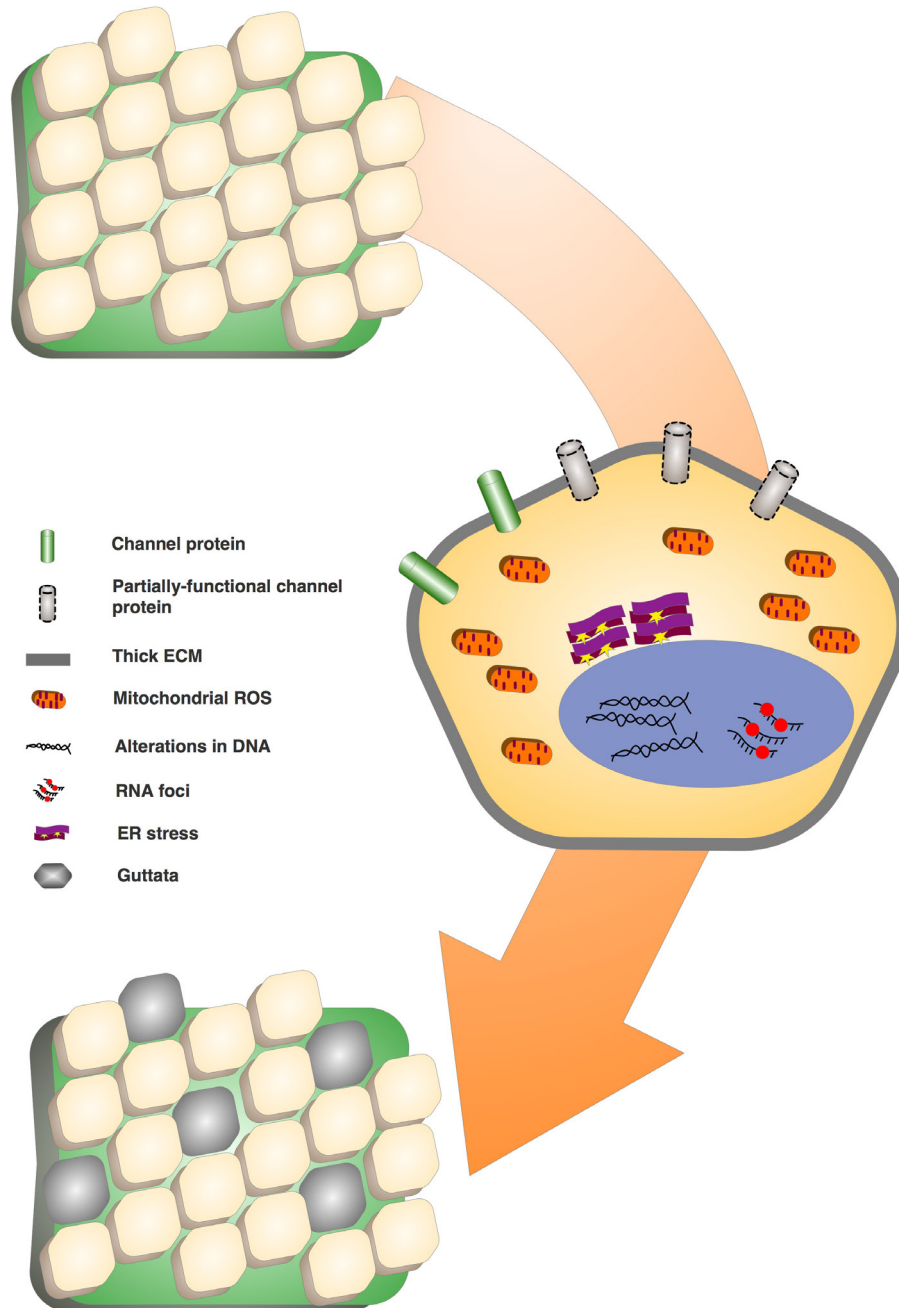


Figure 1. Pathomechanisms in FECD. Alterations in DNA, such as mutations or polymorphic variations, cause several deregulatory events. Post-transcriptional byproducts of expanded repeats in the *TCF4* and *DMPK* genes sequester splice-machinery proteins (MBNL-1) that elevate RNA toxicity and mis-spliced transcript levels. Channel and pump proteins, such as SLC4A11, MCTs, Na^+/K^+ ATPases, and aquaporins, are sub-optimally functional, or show reduced surface density, which affect the basic endothelial pump–barrier function. Increased endoplasmic reticulum (ER) stress elicits unfolded protein response and oxidative stress, which cause mitochondrial fragmentation and DNA lesions. Cells produce excessive and abnormal extracellular matrix materials that thicken Descemet’s membrane and form guttae. Progressive escalation of these processes causes apoptosis, and depletes most of the endothelial population.

This lack of ethnically rich information regarding diseases should encourage researchers to carry out population-specific genetic evaluations in their respective populations.

Based on recent reports, introns [141] and DNA methylation hotspots at TNR stretches [142] confer regulatory roles. Therefore, it would be interesting to elaborately assess the functional roles of genetically associated intronic polymorphisms in FECD pathogenesis. Owing to the significant penetrance of TNRs among various populations across the globe [142,143], understanding the functional implications of these accumulated repeats in non-ocular tissues to demonstrate secondary complications becomes essential. The current plethora of information obtained for FECD pathogenesis has undoubtedly broadened the understanding of several genetic and physiologic players. However, many significant unanswered questions related to the pathology of expanded trinucleotide repeats, the effect of collagen deposition on corneal functioning, and the contribution of various genetic factors (such as *KANK4*, *ATP1B1*, *LAMC1*, and *ZEB1*) in FECD disease progression, remain, which are currently under investigation in various laboratories across the globe.

Concluding remarks: Fuchs' endothelial corneal dystrophy is an autosomal dominant disorder with heterogeneous genetic and uninherited risk factors. Over the past two decades, extensive studies have been performed to understand its complex pathogenesis. Now, with continuous progress in surgical advancement and noninvasive therapies, treating this disorder has come close to becoming a reality.

APPENDIX 1. COMPREHENSIVE LIST OF CHROMOSOMAL LOCI AND THE GENETIC VARIATIONS ASSOCIATED WITH FECD.

To access the data, click or select the words “[Appendix 1.](#)”

ACKNOWLEDGMENTS

The authors are grateful to the study participants that have volunteered for the various genetic and non-genetic studies conducted worldwide to better understand the various physiologic manifestations presented by FECD. The current study is funded by National Institute of Science Education and Research (NISER; Khurda, Odisha, India), Department of Atomic Energy (Mumbai, Maharashtra, India) and Indian Council of Medical Research, from the Project No. 5/4/6/03/Oph./2015-NCD-II (Ansari Nagar, New Delhi, India).

REFERENCES

1. Magovern M, Beauchamp GR, McTigue JW, Fine BS, Baumiller RC. Inheritance of Fuchs' combined dystrophy. *Ophthalmology* 1979; 86:1897-923. [PMID: 399801].
2. Rosenblum P, Stark WJ, Maumenee IH, Hirst LW, Maumenee AE. Hereditary Fuchs' Dystrophy. *Am J Ophthalmol* 1980; 90:455-62. [PMID: 6968504].
3. Wilson SE, Bourne WM. Fuchs' dystrophy. *Cornea* 1988; 7:2-18. [PMID: 3280235].
4. Cross HE, Maumenee AE, Cantolino SJ. Inheritance of Fuchs' endothelial dystrophy. *Arch Ophthalmol* 1971; 85:268-72. [PMID: 5313141].
5. Mustonen RK, McDonald MB, Srivannaboon S, Tan AL, Doubrava MW, Kim CK. In vivo confocal microscopy of Fuchs' endothelial dystrophy. *Cornea* 1998; 17:493-503. [PMID: 9756443].
6. Wilson SE, Bourne WM, O'Brien PC, Brubaker RF. Endothelial function and aqueous humor flow rate in patients with Fuchs' dystrophy. *Am J Ophthalmol* 1988; 106:270-8. [PMID: 3262306].
7. Bourne WM, Johnson DH, Campbell RJ. The ultrastructure of Descemet's membrane. III. Fuchs' dystrophy. *Arch Ophthalmol* 1982; 100:1952-5. [PMID: 6983339].
8. Gottsch JD, Zhang C, Sundin OH, Bell WR, Stark WJ, Green WR. Fuchs corneal dystrophy: aberrant collagen distribution in an L450W mutant of the COL8A2 gene. *Invest Ophthalmol Vis Sci* 2005; 46:4504-11. [PMID: 16303941].
9. Zhang C, Bell WR, Sundin OH, De La Cruz Z, Stark WJ, Green WR, Gottsch JD. Immunohistochemistry and electron microscopy of early-onset fuchs corneal dystrophy in three cases with the same L450W COL8A2 mutation. *Trans Am Ophthalmol Soc* 2006; 104:85-97. [PMID: 17471329].
10. Murphy C, Alvarado J, Juster R. Prenatal and postnatal growth of the human Descemet's membrane. *Invest Ophthalmol Vis Sci* 1984; 25:1402-15. [PMID: 6511224].
11. Xia D, Zhang S, Nielsen E, Ivarsen AR, Liang C, Li Q, Thomsen K, Hjortdal JO, Dong M. The Ultrastructures and Mechanical Properties of the Descemet's Membrane in Fuchs Endothelial Corneal Dystrophy. *Sci Rep* 2016; 6:23096-[PMID: 26980551].
12. Gain P, Jullienne R, He Z, Aldossary M, Acquart S, Cognasse F, Thuret G. Global Survey of Corneal Transplantation and Eye Banking. *JAMA Ophthalmol* 2016; 134:167-73. [PMID: 26633035].
13. Lorenzetti DW, Uotila MH, Parikh N, Kaufman HE. Central cornea guttata. Incidence in the general population. *Am J Ophthalmol* 1967; 64:1155-8. [PMID: 6072991].
14. Adamis AP, Filatov V, Tripathi BJ, Tripathi RC. Fuchs' endothelial dystrophy of the cornea. *Surv Ophthalmol* 1993; 38:149-68. [PMID: 8235998].
15. Krachmer JH, Purcell JJ Jr, Young CW, Bucher KD. Corneal endothelial dystrophy. A study of 64 families. *Arch Ophthalmol* 1978; 96:2036-9. [PMID: 309758].

16. Eghrari AO, McGlumphy EJ, Iliff BW, Wang J, Emmert D, Riazuddin SA, Katsanis N, Gottsch JD. Prevalence and severity of fuchs corneal dystrophy in Tangier Island. *Am J Ophthalmol* 2012; 153:1067-72. [PMID: 22321803].
17. Zoega GM, Fujisawa A, Sasaki H, Kubota A, Sasaki K, Kitagawa K, Jonasson F. Prevalence and risk factors for cornea guttata in the Reykjavik Eye Study. *Ophthalmology* 2006; 113:565-9. [PMID: 16581419].
18. Higa A, Sakai H, Sawaguchi S, Iwase A, Tomidokoro A, Amano S, Araie M. Prevalence of and risk factors for cornea guttata in a population-based study in a southwestern island of Japan: the Kumejima study. *Arch Ophthalmol* 2011; 129:332-6. [PMID: 21402991].
19. Kitagawa K, Kojima M, Sasaki H, Shui YB, Chew SJ, Cheng HM, Ono M, Morikawa Y, Sasaki K. Prevalence of primary cornea guttata and morphology of corneal endothelium in aging Japanese and Singaporean subjects. *Ophthalmic Res* 2002; 34:135-8. [PMID: 12097795].
20. Pandrowala H, Bansal A, Vemuganti GK, Rao GN. Frequency, distribution, and outcome of keratoplasty for corneal dystrophies at a tertiary eye care center in South India. *Cornea* 2004; 23:541-6. [PMID: 15256989].
21. Mohamed A, Chaurasia S, Murthy SI, Ramappa M, Vaddavalli PK, Taneja M, Garg P, Chinta S, Basu S, Rathi VM, Sangwan VS. Endothelial Keratoplasty: A Review of Indications at a Tertiary Eye Care Centre in South India. *Asia-Pac J Ophthalmol* 2014; 3:207-10. [PMID: 26107758].
22. Weiss JS, Moller HU, Aldave AJ, Seitz B, Bredrup C, Kivela T, Munier FL, Rapuano CJ, Nischal KK, Kim EK, Sutphin J, Busin M, Labbe A, Kenyon KR, Kinoshita S, Lisch W. IC3D classification of corneal dystrophies—edition 2. *Cornea* 2015; 34:117-59. [PMID: 25564336].
23. Afshari NA, Igo RP Jr, Morris NJ, Stambolian D, Sharma S, Pulagam VL, Dunn S, Stamler JF, Truitt BJ, Rimmler J, Kuot A, Croasdale CR, Qin X, Burdon KP, Riazuddin SA, Mills R, Klebe S, Minear MA, Zhao J, Balajonda E, Rosenwasser GO, Baratz KH, Mootha VV, Patel SV, Gregory SG, Bailey-Wilson JE, Price MO, Price FW Jr, Craig JE, Fingert JH, Gottsch JD, Aldave AJ, Klintworth GK, Lass JH, Li YJ, Iyengar SK. Genome-wide association study identifies three novel loci in Fuchs endothelial corneal dystrophy. *Nat Commun* 2017; 8:14898. [PMID: 28358029].
24. Riazuddin SA, Parker DS, McGlumphy EJ, Oh EC, Iliff BW, Schmedt T, Jurkunas U, Schleif R, Katsanis N, Gottsch JD. Mutations in LOXHD1, a recessive-deafness locus, cause dominant late-onset Fuchs corneal dystrophy. *Am J Hum Genet* 2012; 90:533-9. [PMID: 22341973].
25. Mootha VV, Hansen B, Rong Z, Mammen PP, Zhou Z, Xing C, Gong X. Fuchs' Endothelial Corneal Dystrophy and RNA Foci in Patients With Myotonic Dystrophy. *Invest Ophthalmol Vis Sci* 2017; 58:4579-85. [PMID: 28886202].
26. Afshari NA, Li YJ, Pericak-Vance MA, Gregory S, Klintworth GK. Genome-wide linkage scan in fuchs endothelial corneal dystrophy. *Invest Ophthalmol Vis Sci* 2009; 50:1093-7. [PMID: 18502986].
27. Aldave AJ, Rayner SA, Salem AK, Yoo GL, Kim BT, Saecedian M, Sonmez B, Yellore VS. No pathogenic mutations identified in the COL8A1 and COL8A2 genes in familial Fuchs corneal dystrophy. *Invest Ophthalmol Vis Sci* 2006; 47:3787-90. [PMID: 16936088].
28. Biswas S, Munier FL, Yardley J, Hart-Holden N, Perveen R, Cousin P, Sutphin JE, Noble B, Batterbury M, Kieley C, Hackett A, Bonshek R, Ridgway A, McLeod D, Sheffield VC, Stone EM, Schorderet DF, Black GC. Missense mutations in COL8A2, the gene encoding the alpha2 chain of type VIII collagen, cause two forms of corneal endothelial dystrophy. *Hum Mol Genet* 2001; 10:2415-23. [PMID: 11689488].
29. Gottsch JD, Sundin OH, Liu SH, Jun AS, Broman KW, Stark WJ, Vito EC, Narang AK, Thompson JM, Magovern M. Inheritance of a novel COL8A2 mutation defines a distinct early-onset subtype of fuchs corneal dystrophy. *Invest Ophthalmol Vis Sci* 2005; 46:1934-9. [PMID: 15914606].
30. Kobayashi A, Fujiki K, Murakami A, Kato T, Chen LZ, Onoe H, Nakayasu K, Sakurai M, Takahashi M, Sugiyama K, Kanai A. Analysis of COL8A2 gene mutation in Japanese patients with Fuchs' endothelial dystrophy and posterior polymorphous dystrophy. *Jpn J Ophthalmol* 2004; 48:195-8. [PMID: 15175909].
31. Mok JW, Kim HS, Joo CK. Q455V mutation in COL8A2 is associated with Fuchs' corneal dystrophy in Korean patients. *Eye (Lond)* 2009; 23:895-903. [PMID: 18464802].
32. Riazuddin SA, Eghrari AO, Al-Saif A, Davey L, Meadows DN, Katsanis N, Gottsch JD. Linkage of a mild late-onset phenotype of Fuchs corneal dystrophy to a novel locus at 5q33.1-q35.2. *Invest Ophthalmol Vis Sci* 2009; 50:5667-71. [PMID: 19608540].
33. Yellore VS, Rayner SA, Emmert-Buck L, Tabin GC, Raber I, Hannush SB, Stulting RD, Sampat K, Momi R, Principe AH, Aldave AJ. No pathogenic mutations identified in the COL8A2 gene or four positional candidate genes in patients with posterior polymorphous corneal dystrophy. *Invest Ophthalmol Vis Sci* 2005; 46:1599-603. [PMID: 15851557].
34. Jun AS, Meng H, Ramanan N, Matthaei M, Chakravarti S, Bonshek R, Black GC, Grebe R, Kimos M. An alpha 2 collagen VIII transgenic knock-in mouse model of Fuchs endothelial corneal dystrophy shows early endothelial cell unfolded protein response and apoptosis. *Hum Mol Genet* 2012; 21:384-93. [PMID: 22002996].
35. Hemadevi B, Srinivasan M, Arunkumar J, Prajna NV, Sundarasan P. Genetic analysis of patients with Fuchs endothelial corneal dystrophy in India. *BMC Ophthalmol* 2010; 10:3. [PMID: 20144242].
36. Baratz KH, Tosakulwong N, Ryu E, Brown WL, Branham K, Chen W, Tran KD, Schmid-Kubista KE, Heckenlively JR, Swaroop A, Abecasis G, Bailey KR, Edwards AO. E2-2 protein and Fuchs's corneal dystrophy. *N Engl J Med* 2010; 363:1016-24. [PMID: 20825314].
37. Stamler JF, Roos BR, Wagoner MD, Goins KM, Kitzmann AS, Riley JB, Stone EM, Fingert JH. Confirmation of the association between the TCF4 risk allele and Fuchs endothelial

- corneal dystrophy in patients from the Midwestern United States. *Ophthalmic Genet* 2013; 34:32-4. [PMID: 22998502].
38. Kuot A, Hewitt AW, Griggs K, Klebe S, Mills R, Jhanji V, Craig JE, Sharma S, Burdon KP. Association of TCF4 and CLU polymorphisms with Fuchs' endothelial dystrophy and implication of CLU and TGFBI proteins in the disease process. *European journal of human genetics Eur J Hum Genet* 2012; 20:632-8. [PMID: 22234156].
 39. Mackey DA, Warrington NM, Hewitt AW, Oates SK, Yazar S, Soloshenko A, Crawford GJ, Mountain JA, Pennell CE. Role of the TCF4 gene intronic variant in normal variation of corneal endothelium. *Cornea* 2012; 31:162-6. [PMID: 22146553].
 40. Thalamuthu A, Khor CC, Venkataraman D, Koh LW, Tan DT, Aung T, Mehta JS, Vithana EN. Association of TCF4 gene polymorphisms with Fuchs' corneal dystrophy in the Chinese. *Invest Ophthalmol Vis Sci* 2011; 52:5573-8. [PMID: 21659310].
 41. Wieben ED, Aleff RA, Tosakulwong N, Butz ML, Highsmith WE, Edwards AO, Baratz KH. A common trinucleotide repeat expansion within the transcription factor 4 (TCF4, E2-2) gene predicts Fuchs corneal dystrophy. *PLoS One* 2012; 7:e49083-[PMID: 23185296].
 42. Mootha VV, Gong X, Ku HC, Xing C. Association and familial segregation of CTG18.1 trinucleotide repeat expansion of TCF4 gene in Fuchs' endothelial corneal dystrophy. *Invest Ophthalmol Vis Sci* 2014; 55:33-42. [PMID: 24255041].
 43. Foja S, Luther M, Hoffmann K, Rupprecht A, Gruenauer-Kloevekorn C. CTG18.1 repeat expansion may reduce TCF4 gene expression in corneal endothelial cells of German patients with Fuchs' dystrophy. *Graefes's archive for clinical and experimental ophthalmology = Albrecht Von Graefes Arch Klin Exp Ophthalmol* 2017; 255:1621-31. [PMID: 28608272].
 44. Kuot A, Hewitt AW, Snibson GR, Souzeau E, Mills R, Craig JE, Burdon KP, Sharma S. TGC repeat expansion in the TCF4 gene increases the risk of Fuchs' endothelial corneal dystrophy in Australian cases. *PLoS One* 2017; 12:e0183719-[PMID: 28832669].
 45. Xing C, Gong X, Hussain I, Khor CC, Tan DT, Aung T, Mehta JS, Vithana EN, Mootha VV. Transethnic replication of association of CTG18.1 repeat expansion of TCF4 gene with Fuchs' corneal dystrophy in Chinese implies common causal variant. *Invest Ophthalmol Vis Sci* 2014; 55:7073-8. [PMID: 25298419].
 46. Nanda GG, Padhy B, Samal S, Das S, Alone DP. Genetic association of TCF4 intronic polymorphisms, CTG18.1 and rs17089887, with Fuchs' endothelial corneal dystrophy in an Indian population. *Invest Ophthalmol Vis Sci* 2014; 55:7674-80. [PMID: 25342617].
 47. Weiss JS, Moller HU, Lisch W, Kinoshita S, Aldave AJ, Belin MW, Kivela T, Busin M, Munier FL, Seitz B, Sutphin J, Bredrup C, Mannis MJ, Rapuano CJ, Van Rij G, Kim EK, Klintworth GK. The IC3D classification of the corneal dystrophies. *Cornea* 2008; 27:Suppl 2S1-83. [PMID: 19337156].
 48. McCartney AC, Kirkness CM. Comparison between posterior polymorphous dystrophy and congenital hereditary endothelial dystrophy of the cornea. *Eye (Lond)* 1988; 2:63-70. [PMID: 3261696].
 49. Desir J, Moya G, Reish O, Van Regemorter N, Deconinck H, David KL, Meire FM, Abramowicz MJ. Borate transporter SLC4A11 mutations cause both Harboyan syndrome and non-syndromic corneal endothelial dystrophy. *J Med Genet* 2007; 44:322-6. [PMID: 17220209].
 50. Riazuddin SA, Vithana EN, Seet LF, Liu Y, Al-Saif A, Koh LW, Heng YM, Aung T, Meadows DN, Eghrari AO, Gottsch JD, Katsanis N. Missense mutations in the sodium borate cotransporter SLC4A11 cause late-onset Fuchs corneal dystrophy. *Hum Mutat* 2010; 31:1261-8. [PMID: 20848555].
 51. Jalimarada SS, Ogando DG, Vithana EN, Bonanno JA. Ion transport function of SLC4A11 in corneal endothelium. *Invest Ophthalmol Vis Sci* 2013; 54:4330-40. [PMID: 23745003].
 52. Vilas GL, Loganathan SK, Liu J, Riau AK, Young JD, Mehta JS, Vithana EN, Casey JR. Transmembrane water-flux through SLC4A11: a route defective in genetic corneal diseases. *Hum Mol Genet* 2013; 22:4579-90. [PMID: 23813972].
 53. Vithana EN, Morgan P, Sundaresan P, Ebenezer ND, Tan DT, Mohamed MD, Anand S, Khine KO, Venkataraman D, Yong VH, Salto-Tellez M, Venkatraman A, Guo K, Hemadevi B, Srinivasan M, Prajna V, Khine M, Casey JR, Inglehearn CF, Aung T. Mutations in sodium-borate cotransporter SLC4A11 cause recessive congenital hereditary endothelial dystrophy (CHED2). *Nat Genet* 2006; 38:755-7. [PMID: 16767101].
 54. Soumitra N, Loganathan SK, Madhavan D, Ramprasad VL, Arokiasamy T, Sumathi S, Karthiyayini T, Rachapalli SR, Kumaramanickavel G, Casey JR, Rajagopal R. Biosynthetic and functional defects in newly identified SLC4A11 mutants and absence of COL8A2 mutations in Fuchs endothelial corneal dystrophy. *J Hum Genet* 2014; 59:444-53. [PMID: 25007886].
 55. Stehouwer M, Bijlsma WR, Van der Lelij A. Hearing disability in patients with Fuchs' endothelial corneal dystrophy: unrecognized co-pathology? *Clin Ophthalmol* 2011; 5:1297-301. [PMID: 21966205].
 56. Vithana EN, Morgan PE, Ramprasad V, Tan DT, Yong VH, Venkataraman D, Venkatraman A, Yam GH, Nagasamy S, Law RW, Rajagopal R, Pang CP, Kumaramanickavel G, Casey JR, Aung T. SLC4A11 mutations in Fuchs endothelial corneal dystrophy. *Hum Mol Genet* 2008; 17:656-66. [PMID: 18024964].
 57. Vilas GL, Loganathan SK, Quon A, Sundaresan P, Vithana EN, Casey J. Oligomerization of SLC4A11 protein and the severity of FECD and CHED2 corneal dystrophies caused by SLC4A11 mutations. *Hum Mutat* 2012; 33:419-28. [PMID: 22072594].

58. Riazuddin SA, Zaghoul NA, Al-Saif A, Davey L, Diplas BH, Meadows DN, Eghrari AO, Minear MA, Li YJ, Klintonworth GK, Afshari N, Gregory SG, Gottsch JD, Katsanis N. Missense mutations in TCF8 cause late-onset Fuchs corneal dystrophy and interact with FCD4 on chromosome 9p. *Am J Hum Genet* 2010; 86:45-53. [PMID: 20036349].
59. Vincent AL, Niederer RL, Richards A, Karolyi B, Patel DV, McGhee CN. Phenotypic characterisation and ZEB1 mutational analysis in posterior polymorphous corneal dystrophy in a New Zealand population. *Mol Vis* 2009; 15:2544-53. [PMID: 19997581].
60. Liskova P, Tuft SJ, Gwilliam R, Ebenezer ND, Jirsova K, Prescott Q, Martincova R, Pretorius M, Sinclair N, Boase DL, Jeffrey MJ, Deloukas P, Hardcastle AJ, Filipiec M, Bhattacharya SS. Novel mutations in the ZEB1 gene identified in Czech and British patients with posterior polymorphous corneal dystrophy. *Hum Mutat* 2007; 28:638-647. [PMID: 17437275].
61. Krafchak CM, Pawar H, Moroi SE, Sugar A, Lichter PR, Mackey DA, Mian S, Nairus T, Elnor V, Schteingart MT, Downs CA, Kijek TG, Johnson JM, Trager EH, Rozsa FW, Mandal MN, Epstein MP, Vollrath D, Ayyagari R, Boehnke M, Richards JE. Mutations in TCF8 cause posterior polymorphous corneal dystrophy and ectopic expression of COL4A3 by corneal endothelial cells. *Am J Hum Genet* 2005; 77:694-708. [PMID: 16252232].
62. Gottsch JD, Bowers AL, Margulies EH, Seitzman GD, Kim SW, Saha S, Jun AS, Stark WJ, Liu SH. Serial analysis of gene expression in the corneal endothelium of Fuchs' dystrophy. *Invest Ophthalmol Vis Sci* 2003; 44:594-9. [PMID: 12556388].
63. Riazuddin SA, Vasanth S, Katsanis N, Gottsch JD. Mutations in AGBL1 cause dominant late-onset Fuchs corneal dystrophy and alter protein-protein interaction with TCF4. *Am J Hum Genet* 2013; 93:758-64. [PMID: 24094747].
64. Edvardson S, J alas C, Shaag A, Zenvirt S, Landau C, Lerer I, Elpeleg O. A deleterious mutation in the LOXHD1 gene causes autosomal recessive hearing loss in Ashkenazi Jews. *Am J Med Genet A* 2011; 155A:1170-2. [PMID: 21465660].
65. Grillet N, Schwander M, Hildebrand MS, Sczaniecka A, Kolatkar A, Velasco J, Webster JA, Kahrizi K, Najmabadi H, Kimberling WJ, Stephan D, Bahlo M, Wiltshire T, Tarantino LM, Kuhn P, Smith RJ, Muller U. Mutations in LOXHD1, an evolutionarily conserved stereociliary protein, disrupt hair cell function in mice and cause progressive hearing loss in humans. *Am J Hum Genet* 2009; 85:328-37. [PMID: 19732867].
66. Gattley D, Zhu AY, Stagner A, Terry MA, Jun AS. Fuchs endothelial corneal dystrophy in patients with myotonic dystrophy: a case series. *Cornea* 2014; 33:96-8. [PMID: 24270677].
67. Zhang X, Igo RP Jr, Fondran J, Mootha VV, Oliva M, Hammersmith K, Sugar A, Lass JH, Iyengar SK. Fuchs' Genetics Multi-Center Study G. Association of smoking and other risk factors with Fuchs' endothelial corneal dystrophy severity and corneal thickness. *Invest Ophthalmol Vis Sci* 2013; 54:5829-35. [PMID: 23882692].
68. Katoh N, Jonasson F, Sasaki H, Kojima M, Ono M, Takahashi N, Sasaki K. Reykjavik Eye Study G. Cortical lens opacification in Iceland. Risk factor analysis—Reykjavik Eye Study. *Acta Ophthalmol Scand* 2001; 79:154-9. [PMID: 11284753].
69. Fischbarg J. Water channels and their roles in some ocular tissues. *Mol Aspects Med* 2012; 33:638-41. [PMID: 22819922].
70. Hedbys BO, Dohlman CH. A new method for the determination of the swelling pressure of the corneal stroma in vitro. *Exp Eye Res* 1963; 2:122-9. [PMID: 13963667].
71. Maurice DM. The location of the fluid pump in the cornea. *J Physiol* 1972; 221:43-54. [PMID: 5016991].
72. Dikstein S, Maurice DM. The metabolic basis to the fluid pump in the cornea. *J Physiol* 1972; 221:29-41. [PMID: 4259586].
73. Lopez IA, Rosenblatt MI, Kim C, Galbraith GC, Jones SM, Kao L, Newman D, Liu W, Yeh S, Pushkin A, Abuladze N, Kurtz I. Slc4a11 gene disruption in mice: cellular targets of sensorineural abnormalities. *J Biol Chem* 2009; 284:26882-96. [PMID: 19586905].
74. Badior KE, Alka K, Casey JR. SLC4A11 Three-Dimensional Homology Model Rationalizes Corneal Dystrophy-Causing Mutations. *Hum Mutat* 2017; 38:279-88. [PMID: 27925686].
75. Vilas GL, Morgan PE, Loganathan SK, Quon A, Casey JR. A biochemical framework for SLC4A11, the plasma membrane protein defective in corneal dystrophies. *Biochemistry* 2011; 50:2157-69. [PMID: 21288032].
76. Khuc E, Bainer R, Wolf M, Clay SM, Weisenberger DJ, Kemmer J, Weaver VM, Hwang DG, Chan MF. Comprehensive characterization of DNA methylation changes in Fuchs endothelial corneal dystrophy. *PLoS One* 2017; 12:e0175112. [PMID: 28384203].
77. Zhang W, Ogando DG, Bonanno JA, Obukhov AG. Human SLC4A11 Is a Novel NH₃/H⁺ Co-transporter. *J Biol Chem* 2015; 290:16894-905. [PMID: 26018076].
78. Zhang W, Li H, Ogando DG, Li S, Feng M, Price FW Jr, Tennessen JM, Bonanno JA. Glutaminolysis is Essential for Energy Production and Ion Transport in Human Corneal Endothelium. *EBioMedicine* 2017; 16:292-301. [PMID: 28117276].
79. Liu J, Seet LF, Koh LW, Venkatraman A, Venkataraman D, Mohan RR, Praetorius J, Bonanno JA, Aung T, Vithana EN. Depletion of SLC4A11 causes cell death by apoptosis in an immortalized human corneal endothelial cell line. *Invest Ophthalmol Vis Sci* 2012; 53:3270-9. [PMID: 22447871].
80. Rajasekaran SA, Gopal J, Willis D, Espineda C, Twiss JL, Rajasekaran AK. Na,K-ATPase beta1-subunit increases the translation efficiency of the alpha1-subunit in MSV-MDCK cells. *Mol Biol Cell* 2004; 15:3224-32. [PMID: 15133131].
81. Vagin O, Tokhtaeva E, Sachs G. The role of the beta1 subunit of the Na,K-ATPase and its glycosylation in cell-cell adhesion. *J Biol Chem* 2006; 281:39573-87. [PMID: 17052981].

82. McCartney MD, Robertson DP, Wood TO, McLaughlin BJ. ATPase pump site density in human dysfunctional corneal endothelium. *Invest Ophthalmol Vis Sci* 1987; 28:1955-62. [PMID: 2824399].
83. Jalimarada SS, Ogando DG, Bonanno JA. Loss of ion transporters and increased unfolded protein response in Fuchs' dystrophy. *Mol Vis* 2014; 20:1668-79. [PMID: 25548511].
84. Johar K, Priya A, Wong-Riley MT. Regulation of Na⁽⁺⁾/K⁽⁺⁾-ATPase by nuclear respiratory factor 1: implication in the tight coupling of neuronal activity, energy generation, and energy consumption. *J Biol Chem* 2012; 287:40381-90. [PMID: 23048038].
85. Hatou S. Hormonal regulation of Na⁺/K⁺-dependent ATPase activity and pump function in corneal endothelial cells. *Cornea* 2011; 30:Suppl 1S60-6. [PMID: 21912233].
86. Kenney MC, Atilano SR, Zorapapel N, Holguin B, Gaster RN, Ljubimov AV. Altered expression of aquaporins in bullous keratopathy and Fuchs' dystrophy corneas. *J Histochem Cytochem* 2004; 52:1341-50. [PMID: 15385580].
87. Macnamara E, Sams GW, Smith K, Ambati J, Singh N, Ambati BK. Aquaporin-1 expression is decreased in human and mouse corneal endothelial dysfunction. *Mol Vis* 2004; 10:51-6. [PMID: 14758337].
88. Goyer B, Theriault M, Gendron SP, Brunette I, Rochette PJ, Proulx S. Extracellular Matrix and Integrin Expression Profiles in Fuchs Endothelial Corneal Dystrophy Cells and Tissue Model. *Tissue Eng Part A* 2018; 24:607-15. [PMID: 28726551].
89. Weller JM, Zenkel M, Schlotzer-Schrehardt U, Bachmann BO, Tourtas T, Kruse FE. Extracellular matrix alterations in late-onset Fuchs' corneal dystrophy. *Invest Ophthalmol Vis Sci* 2014; 55:3700-8. [PMID: 24833739].
90. Kawaguchi R, Saika S, Wakayama M, Ooshima A, Ohnishi Y, Yabe H. Extracellular matrix components in a case of retrocorneal membrane associated with syphilitic interstitial keratitis. *Cornea* 2001; 20:100-3. [PMID: 11188990].
91. Miyazono K. Transforming growth factor-beta signaling in epithelial-mesenchymal transition and progression of cancer. *Proc Jpn Acad, Ser B, Phys Biol Sci* 2009; 85:314-23. [PMID: 19838011].
92. Okumura N, Minamiyama R, Ho LT, Kay EP, Kawasaki S, Tourtas T, Schlotzer-Schrehardt U, Kruse FE, Young RD, Quantock AJ, Kinoshita S, Koizumi N. Involvement of ZEB1 and Snail1 in excessive production of extracellular matrix in Fuchs endothelial corneal dystrophy. *Lab Invest* 2015; 95:1291-304. [PMID: 26302187].
93. Jurkunas UV, Bitar M, Rawe I. Colocalization of increased transforming growth factor-beta-induced protein (TGFB1p) and Clusterin in Fuchs endothelial corneal dystrophy. *Invest Ophthalmol Vis Sci* 2009; 50:1129-36. [PMID: 19011008].
94. Wieben ED, Aleff RA, Tang X, Butz ML, Kalari KR, Highsmith EW, Jen J, Vasmatzis G, Patel SV, Maguire LJ, Baratz KH, Fautsch MP. Trinucleotide Repeat Expansion in the Transcription Factor 4 (TCF4) Gene Leads to Widespread mRNA Splicing Changes in Fuchs' Endothelial Corneal Dystrophy. *Invest Ophthalmol Vis Sci* 2017; 58:343-52. [PMID: 28118661].
95. Du J, Aleff RA, Soragni E, Kalari K, Nie J, Tang X, Davila J, Kocher JP, Patel SV, Gottesfeld JM, Baratz KH, Wieben ED. RNA toxicity and missplicing in the common eye disease fuchs endothelial corneal dystrophy. *J Biol Chem* 2015; 290:5979-90. [PMID: 25593321].
96. Mankodi A, Urbinati CR, Yuan QP, Moxley RT, Sansone V, Krym M, Henderson D, Schalling M, Swanson MS, Thornton CA. Muscleblind localizes to nuclear foci of aberrant RNA in myotonic dystrophy types 1 and 2. *Hum Mol Genet* 2001; 10:2165-70. [PMID: 11590133].
97. Yamashita Y, Matsuura T, Shinmi J, Amakusa Y, Masuda A, Ito M, Kinoshita M, Furuya H, Abe K, Ibi T, Sahashi K, Ohno K. Four parameters increase the sensitivity and specificity of the exon array analysis and disclose 25 novel aberrantly spliced exons in myotonic dystrophy. *J Hum Genet* 2012; 57:368-74. [PMID: 22513715].
98. Zarouchlioti C, Sanchez-Pintado B, Hafford Tear NJ, Klein P, Liskova P, Dulla K, Semo M, Vugler AA, Muthusamy K, Dudakova L, Levis HJ, Skalicka P, Hysi P, Cheetham ME, Tuft SJ, Adamson P, Hardcastle AJ, Davidson AE. Antisense Therapy for a Common Corneal Dystrophy Ameliorates TCF4 Repeat Expansion-Mediated Toxicity. *Am J Hum Genet* 2018; 102:528-39. [PMID: 29526280].
99. Jain A, Vale RD. RNA phase transitions in repeat expansion disorders. *Nature* 2017; 546:243-7. [PMID: 28562589].
100. Li YJ, Minear MA, Rimmler J, Zhao B, Balajonda E, Hauser MA, Allingham RR, Eghrari AO, Riazuddin SA, Katsanis N, Gottsch JD, Gregory SG, Klintworth GK, Afshari NA. Replication of TCF4 through association and linkage studies in late-onset Fuchs endothelial corneal dystrophy. *PLoS One* 2011; 6:e18044-[PMID: 21533127].
101. Soliman AZ, Xing C, Radwan SH, Gong X, Mootha VV. Correlation of Severity of Fuchs Endothelial Corneal Dystrophy With Triplet Repeat Expansion in TCF4. *JAMA Ophthalmol* 2015; 133:1386-91. [PMID: 26401622].
102. Kwon I, Xiang S, Kato M, Wu L, Theodoropoulos P, Wang T, Kim J, Yun J, Xie Y, McKnight SL. Poly-dipeptides encoded by the C9orf72 repeats bind nucleoli, impede RNA biogenesis, and kill cells. *Science* 2014; 345:1139-45. [PMID: 25081482].
103. Freibaum BD, Lu Y, Lopez-Gonzalez R, Kim NC, Almeida S, Lee KH, Badders N, Valentine M, Miller BL, Wong PC, Petrucelli L, Kim HJ, Gao FB, Taylor JP. GGGGCC repeat expansion in C9orf72 compromises nucleocytoplasmic transport. *Nature* 2015; 525:129-33. [PMID: 26308899].
104. Tao Z, Wang H, Xia Q, Li K, Li K, Jiang X, Xu G, Wang G, Ying Z. Nucleolar stress and impaired stress granule formation contribute to C9orf72 RAN translation-induced cytotoxicity. *Hum Mol Genet* 2015; 24:2426-41. [PMID: 25575510].
105. Oh SY, He F, Krans A, Frazer M, Taylor JP, Paulson HL, Todd PK. RAN translation at CGG repeats induces ubiquitin proteasome system impairment in models of fragile X-associated

- tremor ataxia syndrome. *Hum Mol Genet* 2015; 24:4317-26. [PMID: 25954027].
106. Soragni E, Petrosyan L, Rinkoski TA, Wieben ED, Baratz KH, Fautsch MP, Gottesfeld JM. Repeat-Associated Non-ATG (RAN) Translation in Fuchs' Endothelial Corneal Dystrophy. *Invest Ophthalmol Vis Sci* 2018; 59:1888-96. [PMID: 29677349].
 107. Jurkunas UV, Bitar MS, Funaki T, Azizi B. Evidence of oxidative stress in the pathogenesis of fuchs endothelial corneal dystrophy. *Am J Pathol* 2010; 177:2278-89. [PMID: 20847286].
 108. Halilovic A, Schmedt T, Benischke AS, Hamill C, Chen Y, Santos JH, Jurkunas UV. Menadione-Induced DNA Damage Leads to Mitochondrial Dysfunction and Fragmentation During Rosette Formation in Fuchs Endothelial Corneal Dystrophy. *Antioxid Redox Signal* 2016; 24:1072-83. [PMID: 26935406].
 109. Benischke AS, Vasanth S, Miyai T, Katikireddy KR, White T, Chen Y, Halilovic A, Price M, Price F Jr, Liton PB, Jurkunas UV. Activation of mitophagy leads to decline in Mfn2 and loss of mitochondrial mass in Fuchs endothelial corneal dystrophy. *Sci Rep* 2017; 7:6656-[PMID: 28751712].
 110. Tuberville AW, Wood TO, McLaughlin BJ. Cytochrome oxidase activity of Fuchs' endothelial dystrophy. *Curr Eye Res* 1986; 5:939-47. [PMID: 3026733].
 111. Birk AV, Liu S, Soong Y, Mills W, Singh P, Warren JD, Seshan SV, Pardee JD, Szeto HH. The mitochondrial-targeted compound SS-31 re-energizes ischemic mitochondria by interacting with cardiolipin. *J Am Soc Nephrol* 2013; 24:1250-61. [PMID: 23813215].
 112. Malhotra D, Thimmulappa R, Navas-Acien A, Sandford A, Elliott M, Singh A, Chen L, Zhuang X, Hogg J, Pare P, Tuder RM, Biswal S. Decline in NRF2-regulated antioxidants in chronic obstructive pulmonary disease lungs due to loss of its positive regulator, DJ-1. *Am J Respir Crit Care Med* 2008; 178:592-604. [PMID: 18556627].
 113. Malhotra JD, Miao H, Zhang K, Wolfson A, Pennathur S, Pipe SW, Kaufman RJ. Antioxidants reduce endoplasmic reticulum stress and improve protein secretion. *Proc Natl Acad Sci USA* 2008; 105:18525-30. [PMID: 19011102].
 114. Guha S, Chaurasia S, Ramachandran C, Roy S. SLC4A11 depletion impairs NRF2 mediated antioxidant signaling and increases reactive oxygen species in human corneal endothelial cells during oxidative stress. *Sci Rep* 2017; 7:4074-[PMID: 28642546].
 115. Liu C, Liu X, Qi J, Pant OP, Lu CW, Hao J. DJ-1 in Ocular Diseases: A Review. *Int J Med Sci* 2018; 15:430-5. [PMID: 29559831].
 116. Liu XF, Zhou DD, Xie T, Malik TH, Lu CB, Li HJ, Wang F, Shu C, Liu C, Lu CW, Hao JL. Nrf2, a Potential Therapeutic Target against Oxidative Stress in Corneal Diseases. *Oxid Med Cell Longev* 2017; 2017:2326178-[PMID: 29209447].
 117. Engler C, Kelliher C, Spitze AR, Speck CL, Eberhart CG, Jun AS. Unfolded protein response in fuchs endothelial corneal dystrophy: a unifying pathogenic pathway? *Am J Ophthalmol* 2010; 149:194-202. [PMID: 20103053].
 118. Okumura N, Hashimoto K, Kitahara M, Okuda H, Ueda E, Watanabe K, Nakahara M, Sato T, Kinoshita S, Tourtas T, Schlotzer-Schrehardt U, Kruse F, Koizumi N. Activation of TGF-beta signaling induces cell death via the unfolded protein response in Fuchs endothelial corneal dystrophy. *Sci Rep* 2017; 7:6801-[PMID: 28754918].
 119. Matthaei M, Meng H, Meeker AK, Eberhart CG, Jun AS. Endothelial Cdkn1a (p21) overexpression and accelerated senescence in a mouse model of Fuchs endothelial corneal dystrophy. *Invest Ophthalmol Vis Sci* 2012; 53:6718-27. [PMID: 22956607].
 120. Jurkunas UV, Bitar MS, Rawe I, Harris DL, Colby K, Joyce NC. Increased clusterin expression in Fuchs' endothelial dystrophy. *Invest Ophthalmol Vis Sci* 2008; 49:2946-55. [PMID: 18378577].
 121. Wilson MR, Easterbrook-Smith SB. Clusterin is a secreted mammalian chaperone. *Trends Biochem Sci* 2000; 25:95-8. [PMID: 10694874].
 122. Poon S, Easterbrook-Smith SB, Rybchyn MS, Carver JA, Wilson MR. Clusterin is an ATP-independent chaperone with very broad substrate specificity that stabilizes stressed proteins in a folding-competent state. *Biochemistry* 2000; 39:15953-60. [PMID: 11123922].
 123. Melles GR, Lander F, Rietveld FJ. Transplantation of Descemet's membrane carrying viable endothelium through a small scleral incision. *Cornea* 2002; 21:415-8. [PMID: 11973393].
 124. Terry MA, Ousley PJ. Deep lamellar endothelial keratoplasty in the first United States patients: early clinical results. *Cornea* 2001; 20:239-43. [PMID: 11322409].
 125. Gorovoy MS. Descemet-stripping automated endothelial keratoplasty. *Cornea* 2006; 25:886-9. [PMID: 17102661].
 126. Ham L, Dapena I, van Luijk C, van der Wees J, Melles GR. Descemet membrane endothelial keratoplasty (DMEK) for Fuchs endothelial dystrophy: review of the first 50 consecutive cases. *Eye (Lond)* 2009; 23:1990-8. [PMID: 19182768].
 127. Borkar DS, Veldman P, Colby KA. Treatment of Fuchs Endothelial Dystrophy by Descemet Stripping Without Endothelial Keratoplasty. *Cornea* 2016; 35:1267-73. [PMID: 27310885].
 128. Moloney G, Petsoglou C, Ball M, Kerdraon Y, Hollhumer R, Spiteri N, Beheregaray S, Hampson J, D'Souza M, Deva-sahayam RN. Descemetorhexis Without Grafting for Fuchs Endothelial Dystrophy-Supplementation With Topical Ripasudil. *Cornea* 2017; 36:642-8. [PMID: 28476048].
 129. Davies E, Jurkunas U, Pineda R 2nd. Predictive Factors for Corneal Clearance After Descemetorhexis Without Endothelial Keratoplasty. *Cornea* 2018; 37:137-40. [PMID: 29053562].
 130. Koizumi N, Okumura N, Ueno M, Nakagawa H, Hamuro J, Kinoshita S. Rho-associated kinase inhibitor eye drop treatment as a possible medical treatment for Fuchs corneal dystrophy. *Cornea* 2013; 32:1167-70. [PMID: 23715376].

131. Okumura N, Sakamoto Y, Fujii K, Kitano J, Nakano S, Tsujimoto Y, Nakamura S, Ueno M, Hagiya M, Hamuro J, Matsuyama A, Suzuki S, Shiina T, Kinoshita S, Koizumi N. Rho kinase inhibitor enables cell-based therapy for corneal endothelial dysfunction. *Sci Rep* 2016; 6:26113-[\[PMID: 27189516\]](#).
132. Okumura N, Hayashi R, Koizumi N. Perspective of Future Potent Therapies for Fuchs Endothelial Corneal Dystrophy. *Open Ophthalmol J* 2018; 12:154-63. [\[PMID: 30123380\]](#).
133. Hu J, Rong Z, Gong X, Zhou Z, Sharma VK, Xing C, Watts JK, Corey DR, Mootha VV. Oligonucleotides targeting TCF4 triplet repeat expansion inhibit RNA foci and mis-splicing in Fuchs' dystrophy. *Hum Mol Genet* 2018; 27:1015-26. [\[PMID: 29325021\]](#).
134. Mahr MA, Baratz KH, Hodge DO, Erie JC. Racial/Ethnic Differences in Rates of Penetrating or Endothelial Keratoplasty for Fuchs Endothelial Corneal Dystrophy Among US Medicare Beneficiaries. *JAMA Ophthalmol* 2016; 134:1178-80. [\[PMID: 27533017\]](#).
135. Moller S, Koczan D, Serrano-Fernandez P, Zettl UK, Thiesen HJ, Ibrahim SM. Selecting SNPs for association studies based on population frequencies: a novel interactive tool and its application to polygenic diseases. *In Silico Biol* 2004; 4:417-27. [\[PMID: 15506992\]](#).
136. Cross DS, Ivacic LC, Stefanski EL, McCarty CA. Population based allele frequencies of disease associated polymorphisms in the Personalized Medicine Research Project. *BMC Genet* 2010; 11:51-[\[PMID: 20565774\]](#).
137. Ding K, Kullo IJ. Geographic differences in allele frequencies of susceptibility SNPs for cardiovascular disease. *BMC Med Genet* 2011; 12:55-[\[PMID: 21507254\]](#).
138. Mori M, Yamada R, Kobayashi K, Kawaida R, Yamamoto K. Ethnic differences in allele frequency of autoimmune-disease-associated SNPs. *J Hum Genet* 2005; 50:264-6. [\[PMID: 15883854\]](#).
139. Hofer T, Ray N, Wegmann D, Excoffier L. Large allele frequency differences between human continental groups are more likely to have occurred by drift during range expansions than by selection. *Ann Hum Genet* 2009; 73:95-108. [\[PMID: 19040659\]](#).
140. Minear MA, Li YJ, Rimmler J, Balajonda E, Watson S, Allingham RR, Hauser MA, Klintworth GK, Afshari NA, Gregory SG. Genetic screen of African Americans with Fuchs endothelial corneal dystrophy. *Mol Vis* 2013; 19:2508-16. [\[PMID: 24348007\]](#).
141. Padhy B, Hayat B, Nanda GG, Mohanty PP, Alone DP. Pseudoexfoliation and Alzheimer's associated CLU risk variant, rs2279590, lies within an enhancer element and regulates CLU, EPHX2 and PTK2B gene expression. *Hum Mol Genet* 2017; 26:4519-29. [\[PMID: 28973302\]](#).
142. Gijssels I, Van Mossevelde S, van der Zee J, Sieben A, Engelborghs S, De Bleecker J, Ivanoiu A, Deryck O, Edbauer D, Zhang M, Heeman B, Baumer V, Van den Broeck M, Mattheijssens M, Peeters K, Rogeva E, De Jonghe P, Cras P, Martin JJ, de Deyn PP, Cruts M, Van Broeckhoven C. The C9orf72 repeat size correlates with onset age of disease, DNA methylation and transcriptional downregulation of the promoter. *Mol Psychiatry* 2016; 21:1112-24. https://www.ncbi.nlm.nih.gov/entrez/query.fcgi?cmd=Retrieve&db=PubMed&list_uids=26481318&dopt=Abstract[\[PMID: 26481318\]](#).
143. Krishnan J, Athar F, Rani TS, Mishra RK. Simple sequence repeats showing 'length preference' have regulatory functions in humans. *Gene* 2017; 628:156-61. [\[PMID: 28712775\]](#).

Articles are provided courtesy of Emory University and the Zhongshan Ophthalmic Center, Sun Yat-sen University, P.R. China. The print version of this article was created on 5 June 2019. This reflects all typographical corrections and errata to the article through that date. Details of any changes may be found in the online version of the article.