

# Early Glottic Squamous Cell Carcinoma in a 16-Year-Old: Case Report, Review of the Literature and Pediatric Head and Neck Radiotherapy Guidelines

Rajesh Balakrishnan<sup>a</sup> Qamruzzaman Chowdhury<sup>a, c</sup>  
Mohammed Astefchar Hussain<sup>c</sup> Muhammad Masudul Hassan Arup<sup>c</sup>  
Nizamul Haque<sup>c</sup> Fariah Sharmeen<sup>a</sup> Arunangshu Das<sup>a</sup> Bidoura Naznin<sup>b</sup>

Departments of <sup>a</sup>Radiotherapy and Oncology and <sup>b</sup>Pathology, Square Hospital, and  
<sup>c</sup>Department of Radiation Oncology, National Institute of Cancer Research and Hospital,  
Dhaka, Bangladesh

## Key Words

Laryngeal tumors · Children · Pediatric radiotherapy planning · Human papillomavirus

## Abstract

Squamous cell carcinoma in children and adolescents is extremely rare. Less than 80 case reports have been reported in the literature since it was first reported in 1868. In this article, we intend to report a case where a 16-year-old girl who presented with complaints of change in voice was found to have early-stage vocal cord carcinoma on evaluation.

© 2015 S. Karger AG, Basel

## Introduction

The first reported case of head and neck squamous cell carcinoma was described by Rehn in 1868 [1]. Since then, a total of 91 cases have been reported in the literature until 2012 [2]. Laryngeal cancers constitute <0.1% of all head and neck malignancies [3]. Unlike in adults, there is no male predominance, and it is almost equal among both sexes. It is difficult to diagnose laryngeal carcinoma in children because of several reasons, such as poor index

of suspicion, difficulty to perform endoscopic procedures in this patient group, and several benign conditions presenting with similar symptoms. Because of these reasons, most children present with advanced disease. In this article, we report a girl who presented with hoarseness of voice and was diagnosed to have early glottic cancer.

### Case Report

A 16-year-old Bangladeshi girl presented to our hospital with hoarseness of voice which had been gradually worsening over the past 4 months. She was treated earlier by the local physician with antibiotics. On evaluation with a fiberoptic endoscopy, she was found to have a polyp in the anterior 2/3 of the right vocal cord with impaired right vocal cord mobility. She underwent excision of the polyp, and subsequent histopathology showed well-differentiated squamous cell carcinoma. She was then referred to the oncology clinic for further management.

She had no history of using tobacco or consuming alcohol. She had a history of exposure to passive smoke. She did not have a past history of any laryngeal surgery or exposure to radiation/carcinogenic agents; there was no family history of malignancy either. A computed tomography scan of the neck showed an irregularity of the right vocal cord, and no neck nodes were seen. Her biopsy slides were reviewed, and the diagnosis of carcinoma was confirmed (fig. 1). Her disease was staged as T2N0M0 well-differentiated squamous cell carcinoma of the larynx.

She was planned for radical radiotherapy. The treatment fields were as per the standard guidelines for a T2 vocal cord. The superior border was 1 cm above the thyroid cartilage, the inferior border at the lower edge of cricoid cartilage, anteriorly in air, and the posterior border was kept at the anterior border of vertebral bodies (fig. 2). Neck nodes were not prophylactically treated as the incidence of nodal positivity is <2% in T2 lesions. The organs at risk that were taken into consideration were the parotids and spinal cord. The dose received by breasts and thyroid glands was also estimated for documentation purposes. She did not receive any concurrent chemotherapy in view of early disease. She was then treated with radical radiotherapy (66 Gy in 33 fractions, 2 Gy per fraction, 5 days a week over 6 1/2 weeks) using 6 MV photons in a linear accelerator. During her treatment, lead apron was used to cover the thorax to prevent scatter dose radiation. She tolerated the radiotherapy well and is on a regular follow-up. She had no disease recurrence on her last follow-up.

### Discussion

Carcinoma of the larynx is usually seen in adults, and it is rare in children. The most common laryngeal neoplasm in children is laryngeal papillomatosis, which is benign. The other differentials for laryngeal neoplasms in children include hemangiomas, squamous cell carcinoma, minor salivary gland tumors, and sarcomatous tumors.

The delay in diagnosis of laryngeal tumors in children is mainly due to poor index of suspicion among the clinicians and attribution of hoarseness of voice as normal change seen during puberty, or it is misdiagnosed as upper respiratory tract infection or voice abuse [3]. A high index of suspicion is necessary to diagnose these tumors early in childhood, and it is necessary to refer a child who has persistent hoarseness lasting >2 weeks regardless of age to a specialist for fiberoptic endoscopic evaluation of the larynx [4]. Vocal folds are the most

common site of involvement followed by the supraglottic and then the subglottic location [5].

The major risk factor for developing SCC of the larynx in childhood is exposure to radiation of the head and neck region [6]. Other risk factors include smoking, exposure to passive smoke, exposure to chemicals, and family history of malignancy. Our patient had none of the above except for exposure to passive smoke. Recently, human papillomavirus (HPV) infection (16, 18, and 33) [7, 8], HPV-induced genome mutation, and chromosomal translocation (t 15;19) [9] have been found to have a role in the development of these tumors in adolescence. The HPV typing or cytogenic evaluation was not done in our case as it is not available in our country.

There are no universal guidelines on the stage-wise treatment of laryngeal carcinomas in children. However, it has been reported in case series that even though these tumors are aggressive in children, they respond to treatment in a similar way to adults [10].

Early-stage tumors could be treated with stripping (T1a), laser excision (T1), or radical radiotherapy (T1/T2), and advanced tumors might need to have a multidisciplinary approach (surgery, radiation, and chemotherapy) either concurrently or sequentially. Radiation therapy is preferred for early-stage lesions as it preserves the voice, reduces the risk of recurrences and repeated biopsies, which are commonly seen with vocal cord stripping [11]. This allows keeping surgery as a salvage option for disease recurrence.

Pediatric head and neck radiotherapy planning is difficult when compared to adults as they are generally infrequent, and we are much more used to applying planning templates, which take little adjustment to produce a good plan in children. Mostly, children present with large tumors and the treated volume is large. The normal tissue in the irradiated volume is at risk for developing complications, and the tolerance doses for critical organs such as brain, arteries, and heart are lower than for the same tissue in adults, making the treatment planning challenging.

In children, critical structures like bone, genitals, and vertebral bodies, which we commonly ignore in adults, need to be treated with care. For example, in children, bone growth is arrested if more than about 10 Gy is given, or they can become infertile if doses to the ovaries and testes are 6–10 and 1–2 Gy, respectively, or develop dental caries/maldevelopment of the jaw if the dentition receives a >10-Gy dose [12]. When treating targets near the vertebral bodies in children, we have the unique requirement to increase our treatment fields to uniformly treat the entire vertebral body so as not to cause differential bone growth. This requirement can sometimes hamper our ability to spare other nearby normal organs.

Most of the time, we need to decide during planning whether the child requires multiple treatment fields, whether noncoplanar beams might help or whether treatment with intensity-modulated radiation therapy or protons might be beneficial. The use of specialized treatment techniques enables to adequately treat the target volume while keeping normal structures below their tolerance dose and ideally as low as possible. The low doses produced by scatter, beam exits, and leakage are the major source of risk for second malignancy (SM). This theory has implicated intensity-modulated radiation therapy, multibeam treatment plans, and neutron production during proton therapy in increasing the risk for SM. This concern of SM has led to the hesitation in using newer technologies even though the benefits of target conformity and normal tissue sparing are greater. Understanding the mechanisms, risks, and role of radiation therapy in the production of SM will enable us to make better decisions while making treatment plans [13].

Radiation therapy can induce endocrine deficiencies, facial growth retardation, dental anomalies, and neurocognitive dysfunction depending of the tissue irradiated. The risk of development of secondary malignancies is about 1.7% at 10 years [14]. The use of a large

dose per fraction (>250 cGy/fraction) could also lead to chondronecrosis or esophageal stenosis [15]. The occurrence of these side effects with the exception of development of secondary malignancies happens during the first decade following treatment.

## Conclusion

The management of laryngeal tumors in children is challenging, and an early diagnosis is the key to achieve a meaningful survival. The risk and benefits of treatment options should be weighed carefully to balance the treatment outcome and the functional outcome. It is necessary to follow up these children long-term to recognize the late effects such as endocrine abnormalities earlier. The role of vaccination with HPV is still not proven to be beneficial in reducing the incidence of these tumors in children.

## Statement of Ethics

Written consent was obtained from the patient and her parent. A copy of the consent form is with the author if necessary.

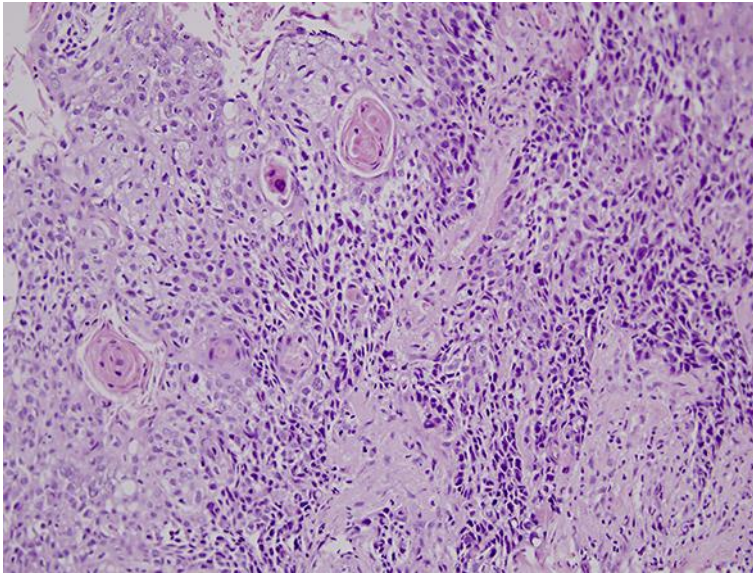
## Disclosure Statement

The authors have no conflicts of interest to declare.

## References

- 1 Rehn H: Cancer of the vestibule and vocal cords in a 3 years old boy. *Arch Pathol Anat Physiol Klin Med* 1868;43:129.
- 2 Naik SM, Nanjundappa A, et al: Paediatric laryngeal malignancies: current management protocols and review of literature. *Int J Phonosurg Laryngol* 2012;2:62–65.
- 3 Rastogi M, Srivastava M, et al: Laryngeal carcinoma in a 13 years old child. *Oral Oncol Extra* 2005;41:207–210.
- 4 Fong VH, Rizal Wong IF, Sani MA, et al: Laryngeal squamous cell carcinoma in a 15 years old. *Brunei Int Med J* 2014;10:42–45.
- 5 Gaylis B, Hayden RE, et al: Recurrent respiratory papillomatosis: progression to invasion and malignancy. *J Otolaryngol* 1991;12:104–112.
- 6 Majoris M, Devine KD, et al: Malignant transformation of benign laryngeal papillomas in children after radiation therapy. *Surg Clin North Am* 1963;43:1049–1061.
- 7 Simon M, Kahn T, Schneider A, et al: Laryngeal carcinoma in a 12-year-old child. Association with human papillomavirus 18 and 33. *Arch Otolaryngol Head Neck Surg* 1994;120:277–282.
- 8 Joos B, Joos N, et al: Laryngeal squamous cell carcinoma in a 13 year-old child associated with human papillomaviruses 16 and 18: a case report and review of the literature. *Head Neck Pathol* 2009;3:37–41.
- 9 Vargas SO, French CA, Faul PN, et al: Upper respiratory tract carcinoma with chromosomal translocation 15;19: evidence for a distinct disease entity of young patients with a rapidly fatal course. *Cancer* 2001;92:1195–1203.
- 10 Gindhart TD, Johnston WH, Chism SE, et al: Carcinoma of the larynx in childhood. *Cancer* 1980;46:1683–1687.
- 11 GarciaSerra A, Hinerman RW, et al: Radiotherapy for carcinoma in situ of the true vocal cords. *Head Neck* 2002;24:390–394.
- 12 Throp N: Basic principles of paediatric radiotherapy. *Clin Oncol* 2013;25:3–10.
- 13 Olch AJ: Paediatric Radiotherapy: Planning and Treatment. Boca Raton, CRC Press, 2013.
- 14 Paulino AC, Simon JH, et al: Long term effects in children treated with radiotherapy for head and neck rhabdomyosarcoma. *Int J Radiat Oncol Biol Phys* 2000;48:1489–1495.

- 15 Stell PM, Morrison MD: Radiation necrosis of the larynx: etiology and management. Arch Otolaryngol 1973;98:111–113.



**Fig. 1.** Histopathological section showing squamous cell carcinoma in a biopsy specimen. HE, original. ×20.

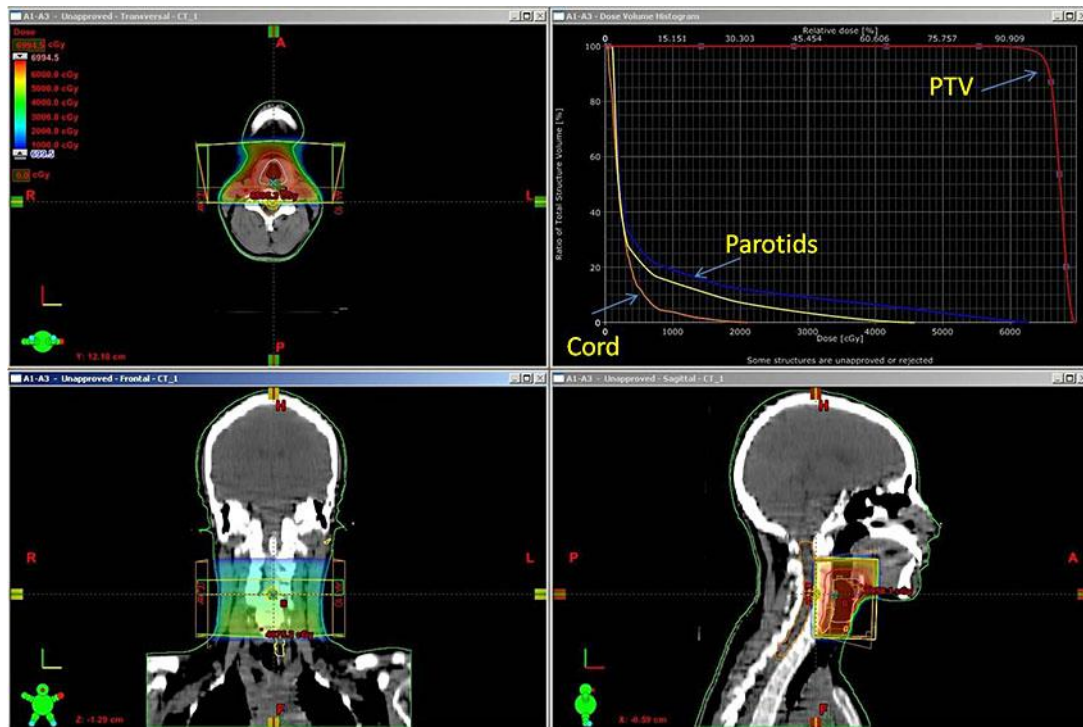


Fig. 2. Radiotherapy treatment fields and dose volume histogram.