

Cite this article as: Veenis JF, Birim O, Brugts JJ. Pulmonary artery pressure telemonitoring by CardioMEMS in a patient pre- and post-left ventricular assist device implantation. *Eur J Cardiothorac Surg* 2019;56:809–10.

Pulmonary artery pressure telemonitoring by CardioMEMS in a patient pre- and post-left ventricular assist device implantation

Jesse F. Veenis^a, Ozcan Birim^b and Jasper J. Brugts^{a,*}

^a Department of Cardiology, Erasmus MC, University Medical Center Rotterdam, Rotterdam, Netherlands

^b Department of Cardio-Thoracic Surgery, Erasmus MC, University Medical Center Rotterdam, Rotterdam, Netherlands

* Corresponding author. Department of Cardiology, Erasmus University Medical Centre, Dr. Molewaterplein 40, 3015 GD Rotterdam, Netherlands. Tel: +31-614229373; e-mail: j.brugts@erasmusmc.nl (J.J. Brugts).

Received 14 November 2018; received in revised form 25 January 2019; accepted 30 January 2019

Abstract

We present a case to demonstrate the feasibility of pulmonary artery monitoring with the CardioMEMS sensor for the preoperative optimization of patients with end-stage heart failure undergoing LVAD surgery. Additionally, we demonstrate the feasibility of combining two state-of-the-art techniques by integrating haemodynamic feedback from CardioMEMS and static pump settings of an LVAD. CardioMEMS aids in the remote monitoring of LVAD patients with the potential of identifying complications, pump dysfunction or filling status alterations.

Keywords: Heart failure • CardioMEMS • Telemonitoring • Left ventricular assist device • HeartMate3

INTRODUCTION

Currently, CardioMEMS is used for the remote monitoring of patients with chronic heart failure (HF) [1, 2], and has been applied, to a certain extent, in patients from the CHAMPION trial who required LVAD implantation or in patients post-LVAD implantation [3, 4]. However, we hypothesize that haemodynamic

data from the CardioMEMS system can be used to optimize patient haemodynamics pre-LVAD implantation, in addition to echocardiographic and clinical parameters. We believe that lowering pulmonary artery pressure (PAP), ideally aiming for a mean PAP (mPAP) <25mmHg, which is an indication of optimal decongestion of the right ventricle (RV), is the best way to proceed towards surgery.

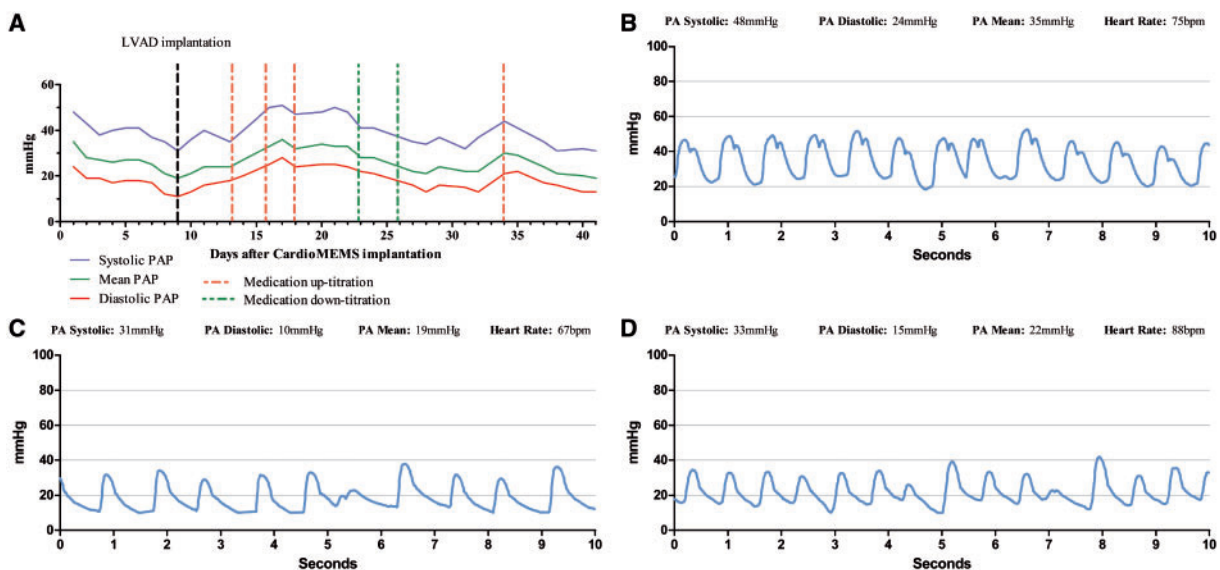


Figure 1: (A) Daily PAPs, prior and post-LVAD implantation. (B) PAP reading shortly after CardioMEMS implantation, showing a clear notch, indicating severe mitral valve insufficiency. (C) PAPs, after optimization; PAPs are within the target range, and the notch has disappeared. (D) PAPs, after LVAD implantation, showing that the CardioMEMS provides a good quality signal after LVAD implantation. LVAD: left ventricular assist device; PA: pulmonary artery; PAP: pulmonary artery pressure.

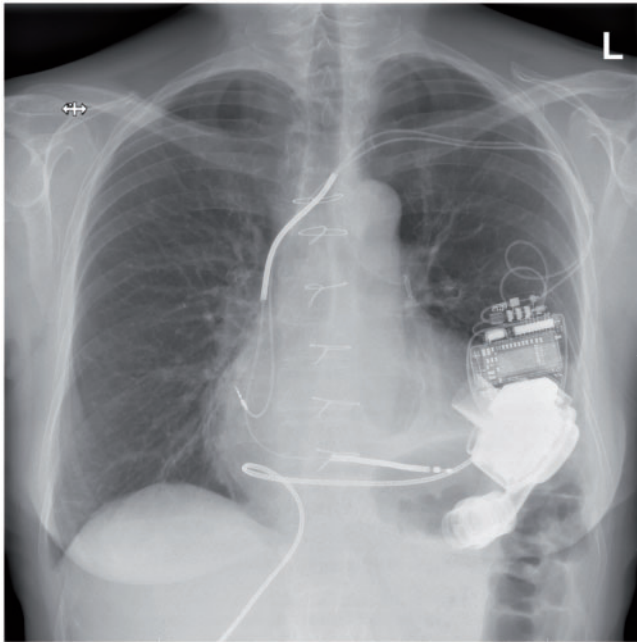


Figure 2: Chest X-ray, showing the HeartMate3, CardioMEMS and biventricular ICD. ICD: implantable cardioverter-defibrillator.

PATIENT DEMONSTRATION

We present a 62-year-old female, with a history of severe HF due to familial, dilated, non-ischaemic cardiomyopathy and implantation of a biventricular implantable cardioverter-defibrillator (ICD). Patient was admitted for progressive end-stage HF with elevated filling pressures, despite optimal medical treatment. An initial echocardiogram showed an ejection fraction of 20%, severe mitral valve insufficiency (MI), a tricuspid valve regurgitation gradient of 31 mmHg and a dilated vena cava.

At admission, the patient was in INTERMACS class 2, and was initially optimized using inotropic (enoximone) and intravenous diuretics in order to achieve an euolemic state. This was, however, hindered by renal insufficiency and inotrope-induced non-sustained ventricular tachycardia. Based on physical and laboratory findings (pulse 60/min, blood pressure 90/50 mmHg, central venous pressure (CVP) not elevated, signs of oedema absent, N-terminal prohormone of brain natriuretic peptide (NT-proBNP) was 470 pmol/L (at administration 1182 pmol/L)), patient was deemed to be in an optimal state, was screened and accepted for LVAD implantation as bridge-to-candidacy (as an adenocarcinoma polyp was recently removed from her colon), with an EUROMACS-RHF risk-score of 4.

At this moment, the implanted CardioMEMS system showed an elevated mPAP (35 mmHg), and a notch, indicating severe MI (Fig. 1B). An echocardiogram showed severe, eccentric MI. mPAP (Fig. 1A) was monitored to optimize the patient's fluid state by titrating diuretics in order to manage the combination of low-output HF and renal insufficiency. mPAP was optimized to 19 mmHg (Fig. 1C), and on echocardiogram, the MI appeared to be reduced to mild-to-moderate. Inotropic support was discontinued, and the INTERMACS class improved to 4, reducing the EUROMACS-RHF risk-score to 0 preoperatively.

LVAD implantation was successful performed (Fig. 2) 17 days after CardioMEMS implantation. Postoperatively, haemodynamic support was quickly phased out, without signs of RV failure. No

interference between the LVAD, hospital equipment and the CardioMEMS system was observed. PAP was elevated as a result of transfusions after implantation, and continued to rise as a sign of congestion. The PAPs were used to optimize HF therapy (up-titrating diuretics, mineralocorticoid receptor antagonists (MRA) and renin-angiotensin-system (RAS)-blockers), resulting in a normalization of the PAPs (Fig. 1D), and MI reduced to mild on echocardiography. The patient remained stable without complications and was discharged on LVAD support in good clinical condition.

DISCUSSION

The CardioMEMS device provides haemodynamic information on a daily basis, which can be used by the treating clinician for patient management. The use of this additional mode of haemodynamic feedback will change the way clinicians work. Weekly monitoring of the haemodynamic parameters allows for timely reaction on haemodynamic changes and medication to be adjusted accordingly, providing truly individualized therapy [2]. CardioMEMS is a very safe system, with only 1% of patients developing device-related complications, and the most common complication is bleeding at the puncture site after implantation, which is easily managed [1].

In pre-LVAD management, clinical signs, laboratory results and echocardiography are currently used to guide pre-LVAD optimization. However, data describing the accuracy of these techniques are lacking. Additional daily haemodynamic information is very important to achieving true pre-LVAD optimization, as has been shown in our case. Thus, unloading the RV and kidney could potentially reduce the preoperative risk for RV and kidney failure.

Currently, post-implantation monitoring is limited to pump-controller defined parameters, which display fixed number of rotations, calculated pump flow and pulse index. Adding haemodynamic changes measured with the CardioMEMS could lead to earlier detection of complications, such as major bleeding, tamponade, RV-failure, decompensation or arrhythmia. Earlier detection facilitates earlier treatment, potentially improving outcome.

Currently, this new technology is only used in clinical trials. However, the combination of CardioMEMS and LVAD could enable telemonitoring of patients who have undergone LVAD implantation.

Conflict of interest: none declared.

REFERENCES

- [1] Abraham WT, Stevenson LW, Bourge RC, Lindenfeld JA, Bauman JG, Adamson PB. Sustained efficacy of pulmonary artery pressure to guide adjustment of chronic heart failure therapy: complete follow-up results from the CHAMPION randomised trial. *Lancet* 2016;387:453–61.
- [2] Brugts JJ, Manintveld OC, van Mieghem N. Remote monitoring of pulmonary artery pressures with CardioMEMS in patients with chronic heart failure and NYHA class III: first experiences in the Netherlands. *Neth Heart J* 2018;26:55–7.
- [3] Feldman DS, Moazami N, Adamson PB, Vierecke J, Raval N, Shreenivas S *et al.* The utility of a wireless implantable hemodynamic monitoring system in patients requiring mechanical circulatory support. *ASAIO J* 2018; 64:301–8.
- [4] Kilic A, Katz JN, Joseph SM, Brisco-Bacik MA, Uriel N, Lima B *et al.* Changes in pulmonary artery pressure before and after left ventricular assist device implantation in patients utilizing remote haemodynamic monitoring. *ESC Heart Fail* 2018;6:138–45.