

## A benign presentation of primary ductal adenocarcinoma of lacrimal gland: A rare malignancy

Lindfay Laura Lau, Chong Ka Lung,  
Syed Shoeb Ahmad

A 34-year-old patient with a swelling over the upper eyelid for nearly 1 year was seen in our clinic. The history, examination and investigations were suggestive of a benign lacrimal gland tumor. The tumor and lacrimal gland were resected. Subsequent histopathological examination revealed the tumor was a primary ductal adenocarcinoma of the lacrimal gland. This is a very rare tumor with less than half a dozen cases reported so far. This case report is being presented to highlight an unusual presentation of this rare malignancy.

**Key words:** Eyelids, lacrimal gland, neoplasms

Tumors originating from the lacrimal gland account for nearly 10% of all orbital tumors.<sup>[1,2]</sup> Epithelial tumors constitute about one-third of lacrimal gland tumors.<sup>[3]</sup> Of these epithelial tumors, the most common are a pleomorphic adenoma, adenoid cystic carcinoma, and not otherwise specified adenocarcinoma.<sup>[3]</sup> Subtypes of lacrimal gland adenocarcinoma such as primary ductal adenocarcinoma are extremely rare; with less than a dozen cases reported so far. Herein, we report a patient diagnosed with primary ductal adenocarcinoma of the lacrimal gland, who had an unusually benign presentation.

### Case Report

A 34-year-old lady was referred to our clinic with a history of progressive, painless swelling over the right lateral upper eyelid, for the past 1 year. She also had mild blurring of vision; without any diplopia. There were no systemic symptoms including loss of appetite, loss of weight, fever or a headache. No significant medical, surgical or family history could be elicited.

On examination, her uncorrected vision in the right eye was 6/10, while in the left eye was 6/6. Intraocular pressures in the right and left eyes were 12 mmHg and 14 mmHg, respectively. There was a prominent swelling over the superotemporal

aspect of the right eyebrow measuring 3 cm × 2 cm in size [Fig. 1]. Palpation of the mass indicated a smooth surface, firm in consistency, and nontender. The margins of the swelling were well defined. It was not attached to the skin but was adherent to the underlying structures, rendering it relatively immobile. Pulsation and transillumination were absent. The orbital rim was palpable and regular. Hertel exophthalmometry was 17 mm on the right and 16 mm on the left. The right eyeball was slightly displaced inferiorly.

Anterior and posterior segment examination was normal in both eyes. Systemic examination revealed no abnormality. The provisional diagnosis was a benign lacrimal gland tumor due to the long history, absence of pain, or any systemic features.

A computed tomography (CT) scan of the orbit and brain, with contrast, showed a well-defined regular homogenous enhancement of lacrimal gland mass measuring 2.8 cm × 1.8 cm × 2.0 cm within the superolateral part of the right orbit [Fig. 2]. There was no extraconal, intraconal, intracranial, intraocular, or paranasal sinus involvement. No bony erosions were noted.

A resection of the tumor and the lacrimal gland was performed on February 8, 2013, through a subbrow incision. A well demarcated solid mass was observed intraoperatively.

Subsequent histopathological examination (HPE) demonstrated nodules of tumor cells with large, vesicular nuclei, and prominent nucleoli with frequent mitoses within the central area of the collecting lacrimal ducts [Fig. 3]. The tumor cells were positive for epithelial membrane antigen (EMA), Ckit (CD117), and periodic acid-Schiff (PAS/D) but negative for S100 protein, cytokeratin-20 and Melan A. Thus, a diagnosis of primary adenocarcinoma of the lacrimal gland was made.

Postoperatively, the right upper eyelid swelling resolved uneventfully. The patient refused radiotherapy as she was pregnant during that period. Two months postexcision, a repeat CT brain, and orbit were done and showed diffuse enhancing soft tissue around the right orbit, which suggested inflammatory activity [Fig. 4]. So far, the patient has been well, and there is no sign of recurrence or metastasis.

### Discussion

Lacrimal gland fossa lesions may be divided into three categories: Inflammatory, lymphoproliferative, and epithelial lesions.<sup>[3]</sup> Among epithelial lesions, 55% are benign, and 45% are malignant.<sup>[1]</sup> Furthermore, among the malignancies, adenoid cystic carcinoma is the most frequently found (66%), followed by a carcinoma-ex-pleomorphic adenoma (18%), primary adenocarcinoma (9%), and mucoepidermoid carcinoma (3%), in that order.<sup>[1]</sup>

This is an open access article distributed under the terms of the Creative Commons Attribution-NonCommercial-ShareAlike 3.0 License, which allows others to remix, tweak, and build upon the work non-commercially, as long as the author is credited and the new creations are licensed under the identical terms.

For reprints contact: reprints@medknow.com

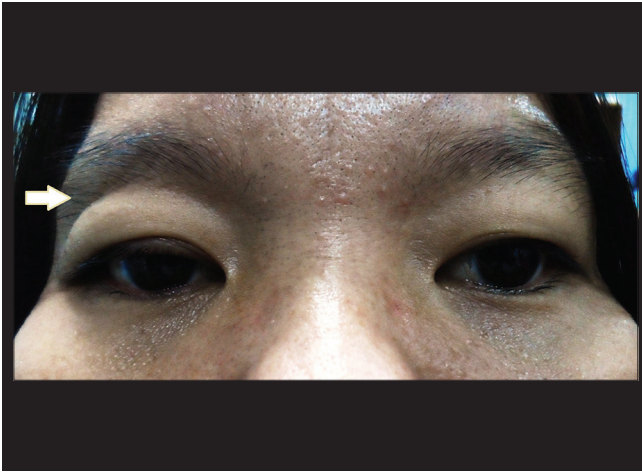
**Cite this article as:** Lau LL, Lung CK, Ahmad SS. A benign presentation of primary ductal adenocarcinoma of lacrimal gland: A rare malignancy. Indian J Ophthalmol 2015;63:856-8.

Access this article online	
<b>Quick Response Code:</b>	<b>Website:</b> www.ijo.in
	<b>DOI:</b> 10.4103/0301-4738.171969
	<b>PMID:</b> 26669339

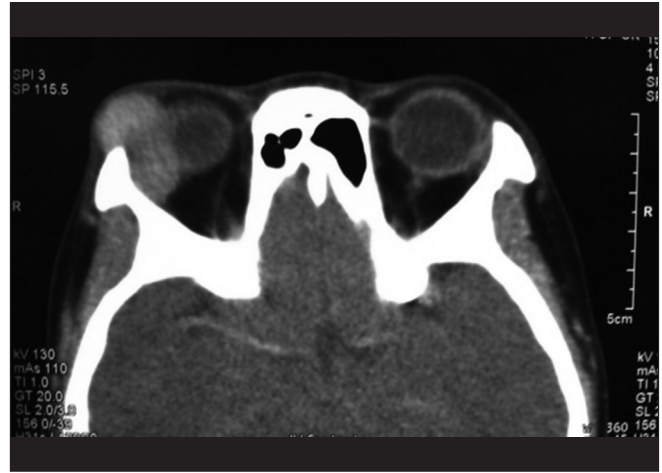Department of Ophthalmology, Queen Elizabeth Hospital, Kota Kinabalu, Malaysia

**Correspondence to:** Dr. Syed Shoeb Ahmad, Department of Ophthalmology, Queen Elizabeth Hospital, Kota Kinabalu, 88586, Malaysia. E-mail: syedshoebahmad@yahoo.com

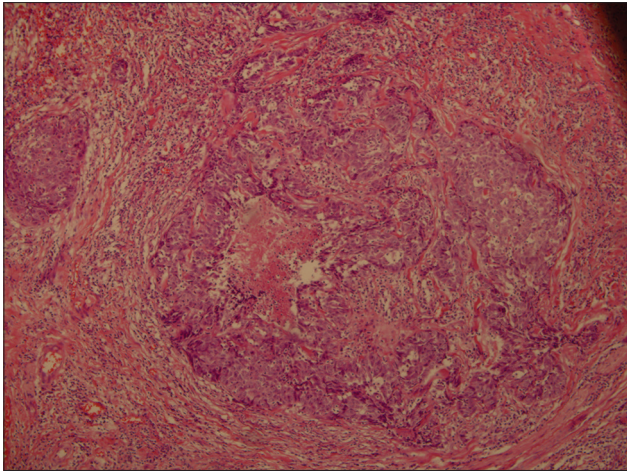
Manuscript received: 29.05.15; Revision accepted: 14.09.15



**Figure 1:** Fullness of the right eye upper lid



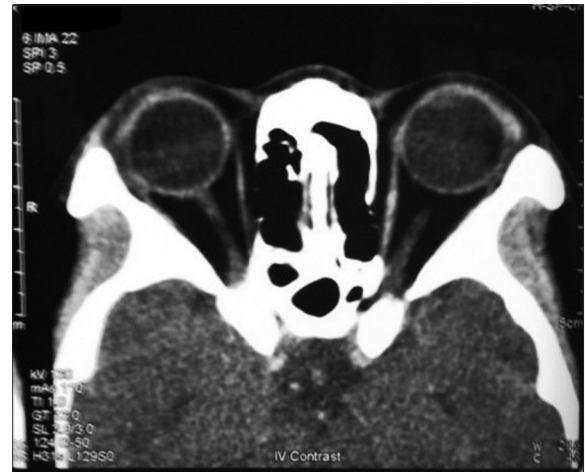**Figure 2:** Computed tomography-scan showing the lacrimal gland tumor



**Figure 3:** Histopathological examination of the lacrimal gland tumor (×10)

Primary ductal adenocarcinoma in the lacrimal glands is extremely rare, very aggressive and carries a poor prognosis.<sup>[3-5]</sup> This tumor arises in the upper eyelid and usually presents as a mass accompanied by symptoms such as rapid growth, pseudoptosis, exophthalmos, dystopia, pain, and reduced visual acuity.<sup>[1,2]</sup> However, patients with this disease are usually symptomless initially, leading them to be diagnosed at an advanced stage. Radiological features which suggest malignancy are bony erosion, the irregular margin of the mass and focal calcification within the lesion.<sup>[2]</sup> However, primary adenocarcinomas frequently present as well demarcated cystic lesions misleading the examiner into diagnosing it as benign.<sup>[1]</sup>

In this case, the patient did not have typical clinical features of a lacrimal gland malignancy. Usually, malignant lesions of the lacrimal gland are characterized by a rapid growth in <6 months, ptosis, ocular motility disturbances, diplopia, and bone erosion on radiographs.<sup>[1]</sup> The presence of pain in malignant tumors is another characteristic feature.<sup>[2,6,7]</sup> Her CT orbit had shown a well-defined regular homogenous enhancement of lacrimal gland mass but with no radiological features of malignancy. In this case, HPE played a very important role to make the precise diagnosis. Immunohistochemistry has been successfully utilized in the diagnosis of many adnexal tumors. However, since, primary ductal adenocarcinoma of the lacrimal gland is very rare, only a few markers have been reported. These include



**Figure 4:** Postoperative computed tomography-scan of the orbit

EMA, carcinoembryonic antigen, matrix metalloproteinases-2, 9, and 13, cytokeratin 7 and proto-oncogene human epidermal growth factor receptor-2/neu.<sup>[1,3,8]</sup>

Currently, there is no clear protocol for treatment of primary ductal adenocarcinoma of the lacrimal gland due to the infrequent occurrence of this disease.<sup>[1]</sup> However, in the majority of cases of lacrimal gland malignancies, the optimal treatment plan is complete removal of the tumor, orbital bone resection, and maintaining health and intact vision of the patient's eye. In cases, where the tumor extends outside the orbit or is widely infiltrating the orbital structures, palliative treatment in the form of radiotherapy, or local resection can be done. If incompletely removed, the recurrence rate is high, and the disease can progress rapidly and may be fatal.<sup>[6]</sup> Thus, it has been recommended that radical excision of the lesion is essential to prevent such recurrence or progression. An *en bloc* resection of the orbital tumor and contents, together with orbitectomy, is considered to be the most logical and effective method of treatment. In our case, as the tumor was suspected to be benign we performed a local resection of the tumor along with the lacrimal gland.

## Conclusion

This case report seems to confirm the features of primary

adenocarcinoma of the lacrimal gland, which is an extremely rare tumor. However, it also shows that this condition can have features mimicking a benign tumor.

#### Declaration of patient consent

The authors certify that they have obtained all appropriate patient consent forms. In the form, the patient(s) has/have given his/her/their consent for his/her/their images and other clinical information to be reported in the journal. The patients understand that their names and initials will not be published, and due efforts will be made to conceal their identity, but anonymity cannot be guaranteed.

#### Acknowledgments

The authors would like to thank the Head of the Ophthalmology Department, Queen Elizabeth Hospital for permission to present this case.

#### Financial support and sponsorship

Nil.

#### Conflicts of interest

There are no conflicts of interest.

## References

1. Baek SO, Lee YJ, Moon SH, Kim YJ, Jun YJ. Primary adenocarcinoma of the lacrimal gland. *Arch Plast Surg* 2012;39:578-80.
2. von Holstein SL, Coupland SE, Briscoe D, Le Tourneau C, Heegaard S. Epithelial tumours of the lacrimal gland: A clinical, histopathological, surgical and oncological survey. *Acta Ophthalmol* 2013;91:195-206.
3. Damasceno RW, Holbach LM. Primary ductal adenocarcinoma of the lacrimal gland: Case report. *Arq Bras Oftalmol* 2012;75:64-6.
4. Krishnakumar S, Subramanian N, Mahesh L, Mohan ER, Biswas J. Primary ductal adenocarcinoma of the lacrimal gland in a patient with neurofibromatosis. *Eye (Lond)* 2003;17:843-5.
5. Katz SE, Rootman J, Dolman PJ, White VA, Berean KW. Primary ductal adenocarcinoma of the lacrimal gland. *Ophthalmology* 1996;103:157-62.
6. Wright JE, Stewart WB, Krohel GB. Clinical presentation and management of lacrimal gland tumours. *Br J Ophthalmol* 1979;63:600-6.
7. Wright JE, Rose GE, Garner A. Primary malignant neoplasms of the lacrimal gland. *Br J Ophthalmol* 1992;76:401-7.
8. Nasu M, Haisa T, Kondo T, Matsubara O. Primary ductal adenocarcinoma of the lacrimal gland. *Pathol Int* 1998;48:981-4.