

CASE REPORT

Open Access



Vernal keratoconjunctivitis in twins: case report and literature review

Maria Cristina Artesani^{1*}, Mariacristina Esposito², Maurizio Mennini¹, Marco Andreani³, Franco Locatelli⁴, Luca Buzzonetti² and Alessandro Fiocchi¹

Vernal keratoconjunctivitis (VKC) is a chronic bilateral seasonal allergic inflammatory disease with a prevalence of < 1 case out of 10,000 in Europe [1], which occurs mainly in pediatric age. The diagnosis is generally confirmed by the finding at the ocular examination of conjunctival hyperemia, papillary hypertrophy in the tarsal conjunctiva, giant papillae and Trantas dots in the limbus region.

Few studies evaluated the association of specific HLA genes with VKC. In an Italian pediatric study, HLA class I A32 was found more frequent in familiar than sporadic forms of VKC [2]. In another pediatric population, patients with VKC presented more frequently HLA-DRB1*01 and DRB1*16, while the DRB1*13 was negatively associated with VKC. The DRB1*01 and DRB1*16 families of alleles are in strong linkage disequilibrium (LD) with the DQB1*05 allele, that was found significantly more frequent in VKC patients than in controls [3]. In this context, HLA analysis of monozygotic twin patients with VKC may provide useful information to clarify the haplotypes potentially implicated in the pathogenesis of the disease. Furthermore, differently from previous reported data, in our investigation we applied a next generation sequencing (NGS) typing approach to determine the different HLA alleles of class I and II present in the studied patients.

After obtaining the informed consent from patients and their parents and the approval of our local Ethics Committee, we describe here the assessment of HLA in a couple of monozygotic twins and in their father, all with VKC. Two 10-years-old Caucasian male

monozygotic twins with history of mild intermittent allergic rhinoconjunctivitis to dust mites, as determined by positive skin prick testing, came to our observation due to the appearance of bilateral conjunctivitis in spring-summer time which responded only to steroid topic therapy. The patients complained of ocular itching, burning, watering and mucoid stringy discharge and intense photophobia. On slit-lamp examination, the children showed conjunctival hyperemia, papillary hypertrophy, giant papillae and Tranta's nodules (Fig. 1 a, b). Vernal keratoconjunctivitis was diagnosed and the disease activity was graded, according to the Bonini VKC severity score [4], as severe (grade 3) for both twins. A successful topical immunosuppressant therapy with cyclosporin 1% was initiated. Their father was diagnosed with VKC, while their mother had no ocular symptoms or signs. We performed the HLA typing at high resolution of the DNA of the two patients and of all the family members available, by NGS.

DNA samples were extracted using an EZ1 DSP DNA Blood kit (Qiagen - Thermo Fisher Scientific Waltham, Massachusetts, USA) on an automatic EZ1 Advanced XL instrument (Qiagen- Thermo Fisher Scientific Waltham, Massachusetts, USA) from peripheral blood samples. HLA genotyping was obtained after a library preparation, using the AllType kit (One Lambda, Canoga Park, California) and run on the Ion Torrent S5 XL platform (Thermo Fisher Scientific Waltham, Massachusetts, USA). These kits use a single multiplexed polymerase chain reaction (PCR) to amplify the full HLA-A/B/C/DQA1/DPA1 gene sequences and from exon 2 to the 3'UTR of the HLADRB1/3/4/5/DQB1/DPB1 genes. Reads were analyzed using the HLA Type-Stream Visual Software (TSV) (One Lambda), ver. 1.1.0.27232.

* Correspondence: mariac.artesani@opbg.net

¹Translational Specialized Pediatrics Research Area, Allergic Diseases Research Unit, Bambino Gesù Children's Hospital, IRCCS, Piazza San'Onofrio, 4, 00165 Rome, Italy

Full list of author information is available at the end of the article



© The Author(s). 2021 **Open Access** This article is licensed under a Creative Commons Attribution 4.0 International License, which permits use, sharing, adaptation, distribution and reproduction in any medium or format, as long as you give appropriate credit to the original author(s) and the source, provide a link to the Creative Commons licence, and indicate if changes were made. The images or other third party material in this article are included in the article's Creative Commons licence, unless indicated otherwise in a credit line to the material. If material is not included in the article's Creative Commons licence and your intended use is not permitted by statutory regulation or exceeds the permitted use, you will need to obtain permission directly from the copyright holder. To view a copy of this licence, visit <http://creativecommons.org/licenses/by/4.0/>. The Creative Commons Public Domain Dedication waiver (<http://creativecommons.org/publicdomain/zero/1.0/>) applies to the data made available in this article, unless otherwise stated in a credit line to the data.

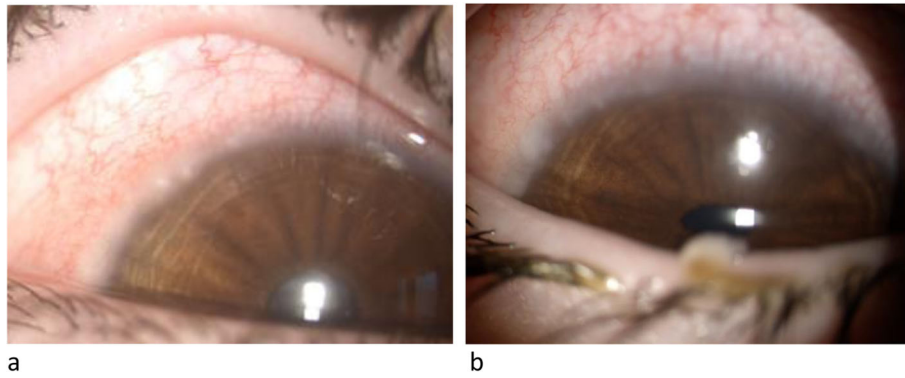


Fig. 1 Slit-lamp examination, twin n.1 (a) and twin n.2 (b)

Table 1 HLA typing, at high resolution of the DNA of the two patients and of all the family members, by next generation sequencing (NGS) by haplotype segregation

Family Relationship	Haplotype	HLA-A*	HLA-B*	HLA-C*	HLA-DRB1*	HLA-DQB1*	HLA-DRB3*	HLA-DQA1*	HLA-DPB1*
Father	a	03:01:01	35:01:01	04:01:01	01:01:01	05:01	–	01:01:01	04:02P
Father	b	03:01:01	35:01:01	07:04:01	11:01:01	03:01P	02:02:01	05:05:01	04:01P
Mother	c	32:01:01	15:17:01	07:01:02	13:02:01	06:04:01	03:01:01	01:02:01	04:01P
Mother	d	01:01:01	18:01:01	12:03:01	11:04:01	03:01P	02:02:01	05:05:01	14:01P
Patient 1	a	03:01:01	35:01:01	04:01:01	01:01:01	05:01	–	01:01:01	04:02P
Patient 1	c	32:01:01	15:17:01	07:01:02	13:02:01	06:04:01	03:01:01	01:02:01	04:01P
Patient 2	a	03:01:01	35:01:01	04:01:01	01:01:01	05:01	–	01:01:01	04:02P
Patient 2	c	32:01:01	15:17:01	07:01:02	13:02:01	06:04:01	03:01:01	01:02:01	04:01P

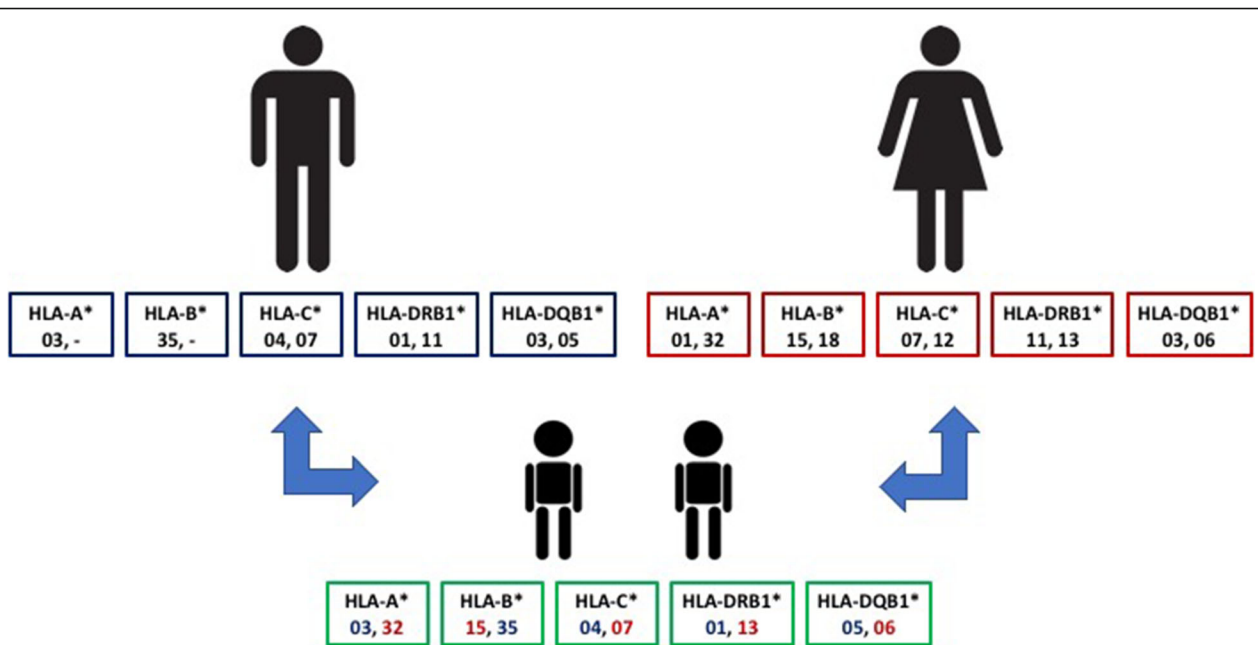


Fig. 2 Familiar HLA typing

The twins' haplotype is presented in detail in Table 1, reporting the different whole HLA haplotypes of all the different family members investigated. The patients presented three different HLA alleles reported to be strongly associated with the developing of VKC: DQB1*05:01:01 and HLA-DRB1*01:01:01 alleles, inherited from the father, also affected by VKC, and the HLA-A*32:01:01 allele, present in the mother haplotype (Fig. 2). The mother presents also the HLA-DRB1*13:02:01 allele, considered protective for VKC [2].

As reported by Zicari et al., DQB1*05 has been already associated to VKC, both in presence of DRB1*01 and DRB1*16 families of alleles typed at low resolution [3]. It is well known from the literature that these two families of alleles are in strong LD with DQB1*05:01 and DQB1*05:02, respectively, specified as DRB1*01:01-DQB1*05:01 and DRB1*16:01-DQB1*05:02.

VKC is an immune-based disorder, most likely with a genetic predisposition [5], but many questions about its pathogenesis remain still unanswered [6]. Further studies need to be carried out to elucidate the full spectrum of immune-genetics of VKC in order to obtain a real stratification of risk. At the moment, our case report suggests that the presence of VKC cases in families should be valorized and approached as a potentially genetically determined condition.

To identify other similar cases, a search of Medline via PubMed and Google Scholar was conducted using the following search strings: "keratoconjunctivitis" or "vernal" or "vernal keratoconjunctivitis" AND "twins". The search was restricted to scientific literature published up to January 2021. We identified four reports of VKC in twins, but three of them did not evaluated the relevance of HLA assessment [7–9].

So only one case report described the assessment of HLA haplotypes A2, A11, B27, B61, DR1, and DR4 in a couple of twins affected by atopic dermatitis, allergic rhino-conjunctivitis and food allergy, but it is not possible to deduce from the text whether the described conjunctivitis could be a VKC or just an allergic conjunctivitis [10].

So far, at our knowledge, this is the first description of HLA haplotypes through NGS approach in twins with VKC.

Acknowledgments

Not applicable.

Authors' contributions

MCA, the corresponding author, analyzed and interpreted the patient data and is the main contributor in writing the manuscript, ME performed the ocular examination, MM was a major contributor in writing the manuscript, MA performed the HLA examination and was a major contributor in writing the manuscript; FL, LB, AF have drafted the work. All authors read and approved the final manuscript.

Funding

Authors disclose any financial support for the manuscript.

Availability of data and materials

The datasets generated during and/or analysed during the current study available from the corresponding author on reasonable request.

Declarations

Competing interests

Authors disclose any Conflict of interests related to the manuscript content.

Author details

¹Translational Specialized Pediatrics Research Area, Allergic Diseases Research Unit, Bambino Gesù Children's Hospital, IRCCS, Piazza San'Onofrio, 4, 00165 Rome, Italy. ²Ophthalmology Department, Bambino Gesù Children's Hospital, IRCCS, Rome, Italy. ³Laboratory of Immunogenetics of Transplant, Department of Pediatric Hematology/Oncology and of Cell and Gene Therapy, Bambino Gesù Children's Hospital, IRCCS, Rome, Italy. ⁴Department of Pediatric Hematology/Oncology and of Cell and Gene Therapy, Bambino Gesù Children's Hospital, IRCCS, Rome, Italy.

Received: 17 March 2021 Accepted: 17 May 2021

Published online: 12 June 2021

References

- Vichyanond P, Pacharn P, Pleyer U, Leonardi A. Vernal keratoconjunctivitis: a severe allergic eye disease with remodeling changes. *Pediatr Allergy Immunol.* 2014;25(4):314–22. <https://doi.org/10.1111/pai.12197>.
- Pucci N, Azari C, Vierucci A. La cheratoconjuntivite vernal. *Riv Immunol Allergol Pediatr.* 2007;2:37–44.
- Zicari AM, Mora B, Lollobrigida V, Occasi F, Cesoni Marcelli A, Megjorni F, et al. Immunogenetic investigation in vernal keratoconjunctivitis. *Pediatr Allergy Immunol.* 2014;25(5):508–10. <https://doi.org/10.1111/pai.12231>.
- Bonini S, Sacchetti M, Mantelli F, Lambiase A. Clinical grading of vernal keratoconjunctivitis. *Curr Opin Allergy Clin Immunol.* 2007;7(5):436–41. <https://doi.org/10.1097/ACI.0b013e3282efb726>.
- Bonini S, Bonini S, Lambiase A, Magrini L, Rumi C, del Prete G, et al. Vernal keratoconjunctivitis: a model of 5q cytokine gene cluster disease. *Int Arch Allergy Immunol.* 1995;107(1–3):95–8. <https://doi.org/10.1159/000236942>.
- Zicari AM, Brindisi G, De Castro G, Lollobrigida V, Nebbioso M, Duse M. Is oxidative stress involved in vernal keratoconjunctivitis? Results from a pilot study in children. *Pediatr Allergy Immunol.* 2020;31(Suppl 26):52–6. <https://doi.org/10.1111/pai.13382>.
- Rosenthal WN, Insler MS. Vernal keratoconjunctivitis: new corneal findings in fraternal twins. *Cornea.* 1984-1985;3(4):288–90.
- Al-Okour KR, Odat TA. Vernal keratoconjunctivitis clinical features and complications in 123 patients in Gaza strip. *JRMS.* 2014;21(1):55–62. <https://doi.org/10.12816/0002580>.
- Darrell RW. Superior limbic keratoconjunctivitis in identical twins. *Cornea.* 1992;11(3):262–3. <https://doi.org/10.1097/00003226-199205000-00013>.
- Murakami Y, Matsui S, Kijima A, Kitaba S, Murota H, Katayama I. Cedar pollen aggravates atopic dermatitis in childhood monozygotic twin patients with allergic rhino conjunctivitis. *Allergol Int.* 2011;60(3):397–400. <https://doi.org/10.2332/allergolint.10-CR-0268>.

Publisher's Note

Springer Nature remains neutral with regard to jurisdictional claims in published maps and institutional affiliations.

Ready to submit your research? Choose BMC and benefit from:

- fast, convenient online submission
- thorough peer review by experienced researchers in your field
- rapid publication on acceptance
- support for research data, including large and complex data types
- gold Open Access which fosters wider collaboration and increased citations
- maximum visibility for your research: over 100M website views per year

At BMC, research is always in progress.

Learn more biomedcentral.com/submissions

